

EDITORIAL

What do Steven Spielberg, Mel Gibson and Emperor Hadrian have in common? Frank's sign and the link with coronary artery disease

 Vasiliki Tsampasian^{1,2}, Vassilios S Vassiliou^{1,2,*},[†] and Natasha Corballis^{1,2}
¹Department of Cardiology, Norwich Medical School, University of East Anglia, Norwich, UK, ²Norfolk and Norwich University Hospital, Norwich, UK

*Correspondence address. Second Floor, Bob Champion Research and Education, Colney Lane, Norwich NR4 7UQ, UK. E-mail: v.vassiliou@uea.ac.uk

It is well known that coronary artery disease remains one of the most common causes of morbidity and mortality worldwide. Thousands of people undergo investigations daily to explore the possibility of having coronary artery disease. With increasing demand, the range of available investigations to encompass both anatomical and functional tests for ischaemia has expanded in the last two decades. This, however, comes at the risk of replacing clinical acumen. Thus, the very first question a physician needs to answer has remained the same: What is the patient's risk of having coronary artery disease?

In 1973, when the available tests were very limited, Dr Sanders T. Frank observed a common sign between 20 patients that had presented with angina: the diagonal earlobe crease [1]. After publishing this case series in the *New England Journal of Medicine*, the sign is often called after his eponym. The sign is a deep wrinkle that can present unilaterally or bilaterally and extends from the tragus to the auricle at a 45° angle, as depicted in Figure 1. The pathophysiology of the sign has remained a mystery for some time, with theories trying to explain the mechanism of its formation. A recent histological study by Stoyanov *et al.* supports the hypothesis that the presence of Frank's sign is directly associated with atherosclerosis as the location of the line is formed prenatally and is therefore vulnerable to hypoxia-reoxygenation injury [2]. Other theories support that it represents premature ageing and loss of elastic fibres [3, 4].

The sign has attracted significant attention for its potential link with the presence of coronary artery disease [3, 5]. In this

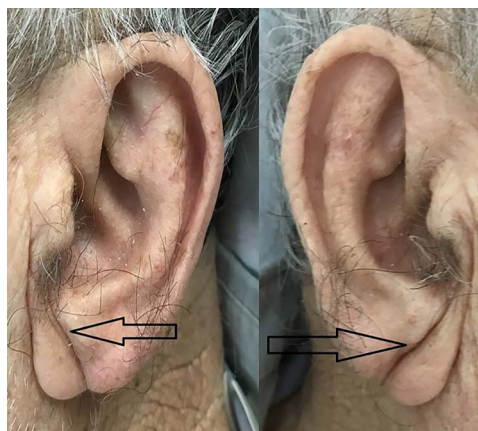


Figure 1: Frank sign observed as a diagonal earlobe crease, marked here with arrows. From Lin AN, Lin K, Kyaw H, Abboud J. A Myth Still Needs to be Clarified: A Case Report of the Frank's Sign. *Cureus*. 2018;10(1):3–7. Reproduced with permission.

issue of *Oxford Medical Case Reports*, Elawad and Albashir present a case report of a 56-year-old man admitted with anterior ST-segment elevation myocardial infarction [6]. He was noted to have ear lobe creases (Frank's sign) bilaterally. This complements several case reports that have illustrated the presence of Frank's sign in patients with coronary artery disease

[†]Vassilios S Vassiliou, <http://orcid.org/0000-0002-4005-7752>
[†]This Editorial refers to the Case Report by Elawad O, Albashir A. Frank's sign: A dermatological marker for ischemic heart disease published by OMCR.

Received: August 31, 2021. Accepted: September 4, 2021

 © The Author(s) 2020. Published by Oxford University Press. All rights reserved. For Permissions, please email: journals.permissions@oup.com

 This is an Open Access article distributed under the terms of the Creative Commons Attribution Non-Commercial License (<http://creativecommons.org/licenses/by-nc/4.0/>), which permits non-commercial re-use, distribution, and reproduction in any medium, provided the original work is properly cited. For commercial re-use, please contact journals.permissions@oup.com



Figure 2: A sculpture of the Roman Emperor Hadrian, located at the British Museum (Asset number 33340001). Image reproduced from the British Museum with permission.

[3, 7–10]. However, there is still much controversy regarding its clinical relevance and predictive value. A study by Wang *et al.* that included 558 patients demonstrated that Frank's sign was independently associated with a risk of coronary artery disease [11] supported by a more recent single-blind cross-sectional study that included 1000 patients. Frank's sign showed a significant association with cardiovascular events with reported sensitivity of 43% and specificity of 70% [12] (Rodríguez-Lopez). Other studies, however, show a weaker association [13].

Despite the questionable sensitivity of the sign, the undeniable fact is that Frank's sign has been documented throughout history, from the ancient Romans to Renaissance art, right through to modern-day popular culture. From the Roman Emperor Hadrian, whose sculptures around the world portray a right-sided earlobe crease as shown in Figure 2, to the portrait of Cardinal Trevisan during the Renaissance [14, 15].

Although Frank's sign may yield low sensitivity, looking for it is a free, feasible and easy way to obtain an additional clinical clue about the risk profile of a patient that presents with chest pain, in an era where clinical examination skills are sometimes being neglected due to the wealth of investigative tests available. The case by Elawad and Albashir reminds us that a cardiovascular clinical examination is only completed with a good look at patient's ears!

ACKNOWLEDGEMENT

VT and NC are supported by an NIHR Academic Clinical Fellowship.

CONFLICT OF INTEREST STATEMENT

VV has no conflict of interest.

REFERENCES

1. Frank ST. Aural sign of coronary-artery disease. *N Engl J Med* 1973;289:327–8.
2. Stoyanov GS, Dzhenkov D, Petkova L, Sapundzhiev N, Georgiev S. The histological basis of Frank's Sign. *Head Neck Pathol* [Internet] 2021;15:402–7 Available from: <https://doi.org/10.1007/s12105-020-01205-4>.
3. George Griffing MD. Frank's Sign. *N Engl J Med* 2014;370:e15.
4. Higuchi Y, Maeda T, Guan JZ, Oyama J, Sugano M, Makino N. Diagonal earlobe crease are associated with shorter telomere in male Japanese patients with metabolic syndrome - a pilot study. *Circ J* 2009;73:274–9.
5. Agouridis AP, Elisaf MS, Nair DR, Mikhailidis DP. Ear lobe crease: a marker of coronary artery disease? *Arch Med Sci* 2015;11:1145–55.
6. Elawad O, Albashir A. Frank's sign: a dermatological marker for ischemic heart disease. *Oxf Med Case Reports* 9:367–8.
7. Lee KG. Frank's sign – a dermatological link to coronary artery disease? *Med J Malaysia* 2017;72:195–6.
8. Lin AN, Lin K, Kyaw H, Abboud J. A myth still needs to be clarified: a case report of the Frank's Sign. *Cureus* 2018;10:3–7.
9. Chauhdary WA, Rubel AR, Bashir A, Hla Aye MT, Javed N, Soe ZN *et al.* Earlobe crease (Frank's sign) and coronary heart disease. *Qjm* 2020;113:902.
10. Ono R, Iwahana T, Kobayashi Y. Frank's sign in recurrent triple-vessel disease. *BMJ Case Rep* 2020;13:1–2.
11. Wang Y, Mao LH, Jia EZ, Li ZY, Ding XQ, Ge PC *et al.* Relationship between diagonal earlobe creases and coronary artery disease as determined via angiography. *BMJ Open* 2016;6:1–9.
12. Rodríguez-López C, Garlito-Díaz H, Madroñero-Mariscal R, Sánchez-Cervilla PJ, Graciani A, López-Sendón JL *et al.* Earlobe crease shapes and cardiovascular events. *Am J Cardiol* [Internet] 2015 [cited 2021 Aug 30];116:286–93. Available from: <http://www.ajconline.org/article/S0002914915011200/fulltext>.
13. Więckowski K, Gallina T, Surdacki A, Chyrchel B. Diagonal earlobe crease (Frank's Sign) for diagnosis of coronary artery disease: a systematic review of diagnostic test accuracy studies. *J Clin Med* 2021;10:2799.
14. Galassi FM, Borghi C, Ballestriero R, Habicht ME, Henneberg M, Rühli FJ. Palaeopathology of the earlobe crease (Frank's sign): new insights from Renaissance art. *Int J Cardiol* [Internet] 2017;236:82–4. Available from: <http://dx.doi.org/10.1016/j.ijcard.2017.02.128>.
15. Diagonal earlobe crease (Frank's sign) | Stanford Medicine 25 | Stanford Medicine [Internet]. California, USA. Available from: <https://stanfordmedicine25.stanford.edu/blog/archive/2015/what-is-the-name-of-this-sign.html>