



Contents lists available at ScienceDirect

International Journal of Surgery Case Reports

journal homepage: www.casereports.com

A case of single-incision laparoscopic surgery for a bleeding Meckel's diverticulum diagnosed pre-operatively by double-balloon endoscopy



Toshio Shiraishi^{a,*}, Tetsuro Tominaga^a, Takashi Nonaka^a, Kouki Wakata^a, Masaki Kunizaki^a, Shuichi Tobinaga^a, Yoriyoshi Sumida^a, Shigekazu Hidaka^a, Naoe Kinoshita^b, Terumitsu Sawai^c, Takeshi Nagayasu^a

^a Department of Surgery, Division of Surgical Oncology, Nagasaki University Graduate School of Biological Sciences, Japan

^b Department of Pathology, Division of Surgical Oncology, Nagasaki University Graduate School of Biological Sciences, Japan

^c Cardiopulmonary Rehabilitation Science, Division of Surgical Oncology, Nagasaki University Graduate School of Biological Sciences, Japan

ARTICLE INFO

Article history:

Received 26 October 2016

Received in revised form 20 February 2017

Accepted 20 February 2017

Available online 22 February 2017

Keywords:

Meckel's diverticulum

Single-port laparoscopic surgery

Bleeding

Case report

ABSTRACT

INTRODUCTION: Meckel's diverticulum (MD) is a congenital true diverticulum that is residual yolk duct tissue, and some cases with complications require surgery. It has been reported that laparoscopic surgery is effective for patients with an MD.

PRESENTATION OF CASE: A 79-year-old man with melena visited our hospital. Upper gastrointestinal series and colonoscopy showed no bleeding lesion. Double-balloon endoscopy was then performed to examine the small intestine. The examination showed a large diverticulum 80 cm proximal to the ileocecal valve and a circular ulcer. MD resection was performed using single-incision laparoscopic surgery (SILS) technique through a 3-cm zig-zag incision in the umbilicus. Three ports were inserted for the scope and forceps devices. The MD was located 80 cm proximal to the ileocecal valve. There were no other intestinal lesions. From the wound, the lesion could be easily moved outside the body. The MD including the ulcer lesion was then resected. The patient's postoperative course was good, and he rarely felt wound pain. He started dietary intake three days after surgery and was discharged from hospital eight days after surgery.

DISCUSSION: SILS technique has attracted attention in the field of laparoscopic surgery. Using a single port with multiple working channels, SILS can reduce the number of incisions and the rates of incisional hernia port site-related complications, as well as improve cosmesis.

CONCLUSION: A definite diagnosis of an MD was made by double-balloon endoscopy preoperatively. The SILS approach was effective for cosmesis, postoperative pain, and a shortened hospital stay.

© 2017 The Author(s). Published by Elsevier Ltd on behalf of IJS Publishing Group Ltd. This is an open access article under the CC BY-NC-ND license (<http://creativecommons.org/licenses/by-nc-nd/4.0/>).

1. Introduction

Meckel's diverticulum (MD) is a common anomaly of the gastrointestinal tract [1]. Most patients with MD are asymptomatic, but some patients develop bleeding, inflammation, and perforation that requires surgical treatment [2]. In general, it has often been reported that the diagnosis of MD is difficult [2]. However,

with improvements in endoscopic technique, the rate of a confirmed diagnosis of MD may increase [3,4]. In regard to the surgical approach, less invasive surgery, such as laparoscopic surgery, is reported to be effective for patients with MD [5]. A case of bleeding due to MD that was diagnosed preoperatively using double-balloon endoscopy and in which single-incision laparoscopic surgery (SILS) was performed is reported. The work has been reported according to the SCARE criteria [6].

Abbreviations: SILS, single port laparoscopic surgery; MD, Meckel's diverticulum; CT, computed tomography.

* Corresponding author at: Division of Surgical Oncology, Department of Surgery, Nagasaki University Graduate School of Biological Sciences, 1-7-1 Sakamoto, Nagasaki 852-8501, Japan.

E-mail addresses: tshiraishi@nagasaki-u.ac.jp (T. Shiraishi), tomitetsu2000@yahoo.co.jp (T. Tominaga), tnonaka@nagasaki-mc.com (T. Nonaka), kou-waka@hotmail.co.jp (K. Wakata), kunisakimasaki2002@yahoo.co.jp (M. Kunizaki), sh.toby577@gmail.com (S. Tobinaga), y-sumida@nagasaki-u.ac.jp (Y. Sumida), hidaka-s@nagasaki-u.ac.jp (S. Hidaka), daimonji@nagasaki-u.ac.jp (N. Kinoshita), sawai@nagasaki-u.ac.jp (T. Sawai), nagayasu@nagasaki-u.ac.jp (T. Nagayasu).

2. Presentation of case

A 79-year-old man with anemia and melena visited our hospital. He had received chemotherapy for diffuse large B-cell lymphoma. In the emergency room, his blood pressure and heart rate were 105/55 mmHg and 108/min, respectively. He had pain in the left side of the abdomen. There was no muscular guarding or rebound tenderness. Laboratory data showed severe anemia, and his hemoglobin level was 7.4 g/dl (Table 1). Abdominal computed tomography (CT) showed a high density of bowel fluid in the dis-

<http://dx.doi.org/10.1016/j.ijscr.2017.02.037>

2210-2612/© 2017 The Author(s). Published by Elsevier Ltd on behalf of IJS Publishing Group Ltd. This is an open access article under the CC BY-NC-ND license (<http://creativecommons.org/licenses/by-nc-nd/4.0/>).

Table 1
Laboratory data on admission.

Peripheral blood	
RBC	2.39 × 10 ⁴ /mm ³
Hg	7.4 g/dl
Hct	22.8%
WBC	3900/mm ³
Plt	10.4 × 10 ⁴ /mm ³
Biochemistry	
T-Bil	0.4 mg/dl
AST	23 IU/l
ALT	18 U/l
LDH	274 IU/l
ALP	245 U/l
Na	139 mg/dl
K	4.7 mg/dl
Cl	105 mg/dl
BUN	17 mg/dl
Cr	1.18 mg/dl
TP	6.2 g/dl
Alb	4.1 g/dl
CRP	6.2 g/dl

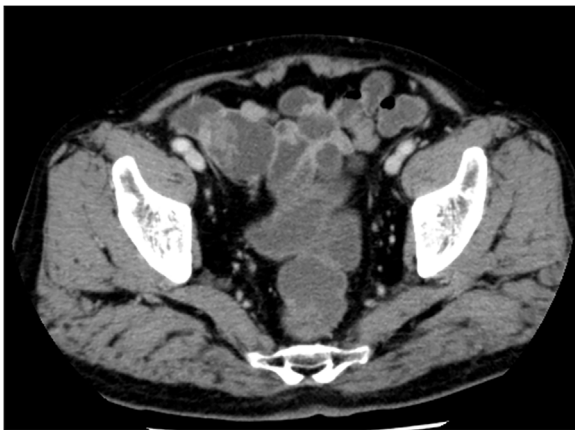

Fig. 1. Abdominal CT on admission. Abdominal CT shows high-density bowel fluid in the distal side of the ileum. There is no ascites, and no other suspicious bleeding points are seen.

tal side of the ileum (Fig. 1). Upper gastrointestinal series and colonoscopy were performed first, but no bleeding lesion, such as a gastric ulcer or a colonic diverticulum, was found. Thus, double-balloon endoscopy was performed to examine the small intestine. The examination showed a large diverticulum, 80 cm proximal to the ileocecal valve, and there was also a circular ulcer at the entrance of the diverticulum (Fig. 2a). No bleeding could be seen, but naked vessels were seen and clipped (Fig. 2b). The patient was diagnosed with bleeding due to an MD. The MD was then resected using SILS technique.

A 3-cm zig-zag incision was placed in the umbilicus. Then, EZ access® (Hakko-medical, Tokyo, Japan) was inserted through the wound. Three ports were used, one for the scope and two for handling forceps (Fig. 3a). First, the whole abdomen was observed; there was no ascites or adhesions. The ileum end was then identified, and the oral side of the ileum was examined gently. A Meckel's diverticulum was found 80 cm proximal to the ileocecal valve (Fig. 3b). There were no other abnormal lesions in the remaining intestine. The MD was easily elevated to the abdominal wall, and the pneumoperitoneum and intra-abdominal activity were thus stopped. From the first 3-cm wound, the lesion was easily moved outside the body. The wall of the middle of the diverticulum was hard due to the ulcer. The vitelline artery and vein were identified and ligated. The MD including the ulcer lesion was then resected

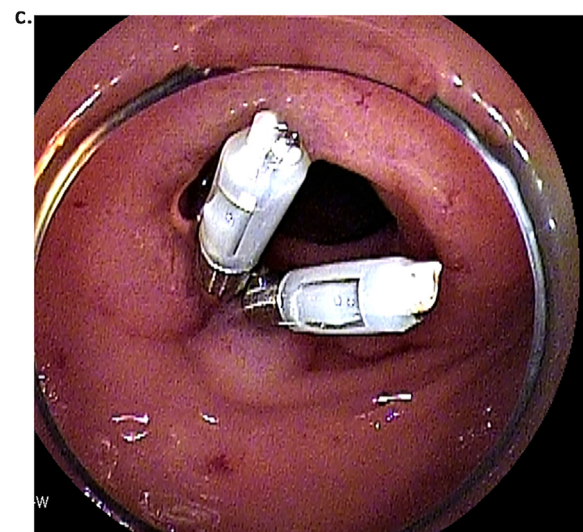
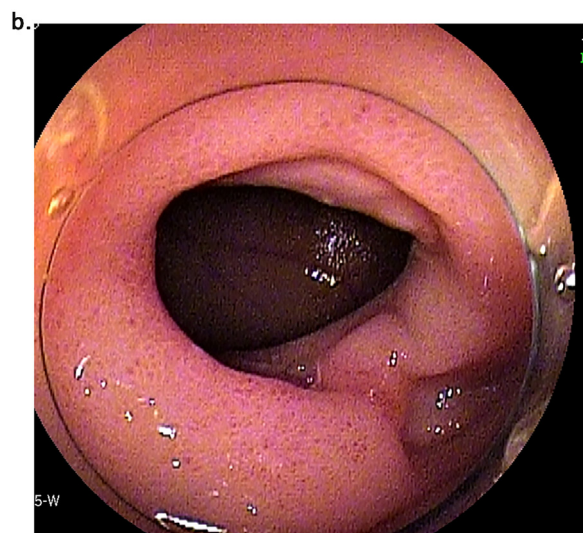
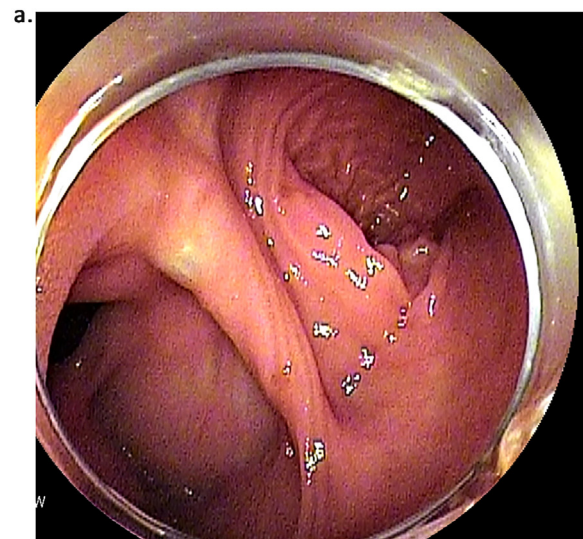


Fig. 2. Double-balloon endoscopy. Double-balloon endoscopy shows the large diverticulum 80 cm oral to the ileocecal valve (Fig. 2a). There is a circular ulcer at the entrance of the diverticulum. Naked vessels are seen, and the vessels are clipped (Fig. 2b, c).

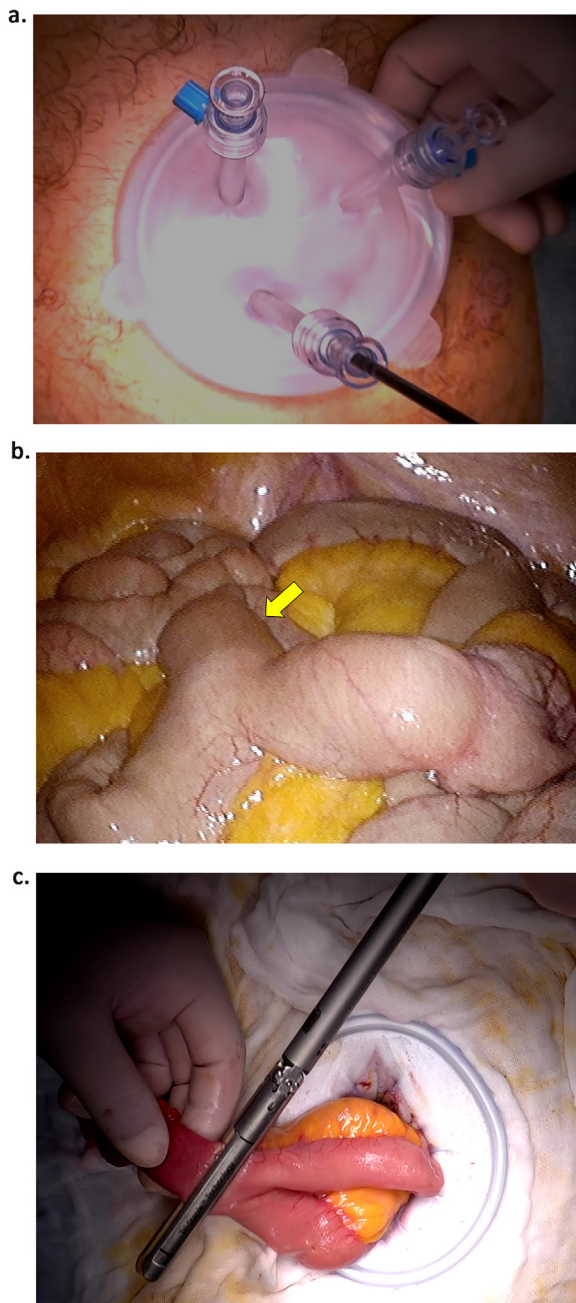


Fig. 3. Operative findings. A 3-cm incision was placed in the umbilicus. EZ access® was then inserted through the wound (Fig. 3a). Meckel's diverticulum is present 80 cm oral to the ileocecal valve (arrow) (Fig. 3b). From the first 3-cm wound, the lesion can be easily moved outside the body. Then, the Meckel's diverticulum including the ulcer lesion is resected by Endo GIA purple 60® (Fig. 3c).

by Endo GIA purple 60® (Covidien, MA, USA) (Fig. 3c). Additional suturing was performed by 4-0 silk on the stapler line.

The resected specimen showed a circular ulcer in the Meckel's diverticulum that might have caused the bleeding (arrow) (Fig. 4a). On pathology, ulcer formation was seen in the MD (arrow) (Fig. 4b). Ulcer formation and pyloric glands were evident, but there were no atypical cells in the specimens (Fig. 4b, c)

The patient's postoperative course was good, and he rarely felt wound pain. He started dietary intake three days after the operation and was discharged from hospital eight days after the operation.

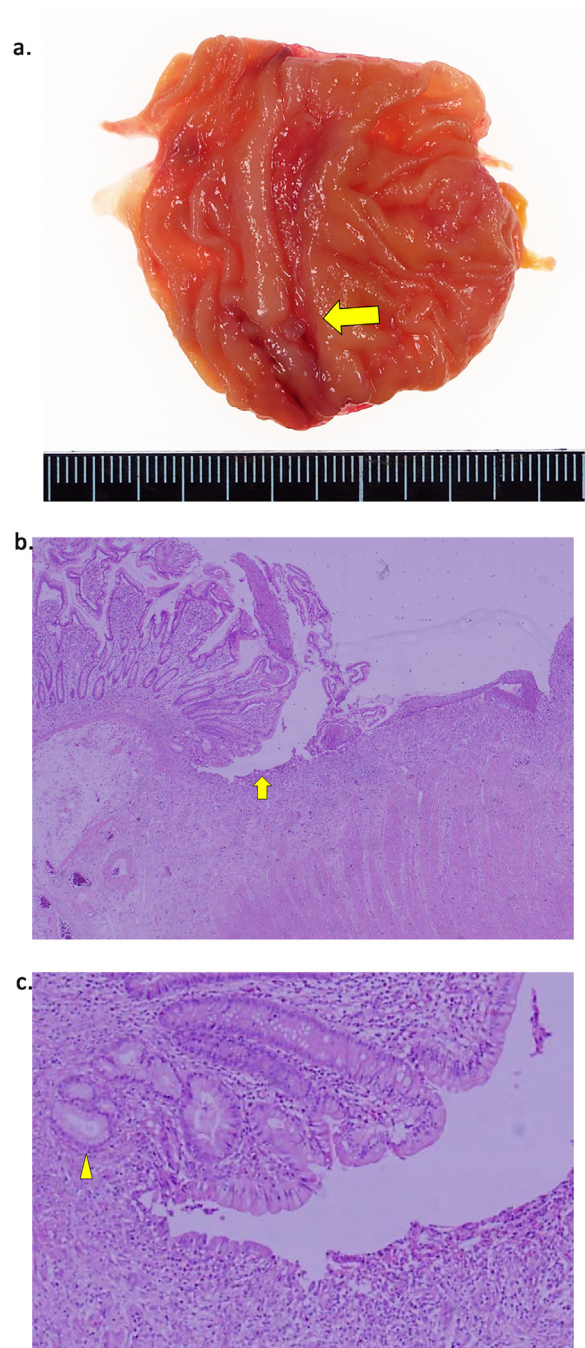


Fig. 4. Excised specimen and pathological findings. The resected specimen shows a circular ulcer in the Meckel's diverticulum that might have caused the bleeding (arrow) (Fig. 4a). On pathology, ulcer formation is seen in the MD (arrow) (Fig. 4b). There is ectopic gastric mucosa, but no atypical cells in the specimens (arrow head 3c).

3. Discussion

MD is a congenital true diverticulum that is residual tissue of the fetal yolk duct [2]. The prevalence of MD is reported to be 0.6% to 4% of the population [2]. Most patients are asymptomatic, and complicated cases that require treatment are rare [1]. In previous reports, symptomatic cases, such as those with gastrointestinal bleeding, diverticulitis, intestinal obstruction, invagination, or perforation accounted for 4–16% of all MD cases [2,7–9].

MD commonly exists at the anti-mesenteric border of the ileum, and 90% are located within 90 cm oral to the ileocecal valve [10].

In the present case, the MD was opposite the mesentery, 80 cm proximal to the ileocecal valve.

Histologically, 50% of cases contain ectopic gastric, pancreatic, jejunal, or duodenal epithelium. In the present case, pyloric glands could be seen in the specimen [8].

As in the present case, MD could be a suspected cause of melena that may not be detected by upper gastrointestinal endoscopy and colonoscopy, but its definite diagnosis is sometimes difficult [10]. Abdominal enhanced CT or angiography could reveal extravasation, except for cases with bleeding of less than 0.5 ml per min [11].

Some reports have shown that ^{99m}Tc scintigraphy may be effective for detection of MD [2]. However, the sensitivity was relatively low (62.5%), and MD cases without or with little ectopic gastric mucosa could be pseudo-negative.

Today, thanks to the improvements in endoscopy, double-balloon endoscopy has been performed for the diagnosis or treatment of such rare cases [3]. The length of double-balloon endoscopy is commonly about 2 m, and some pull-on techniques can reach more advanced lesions, so that most MDs, which can be located within 90 cm of the ileocecal valve, can be detected [3,4]. In the present case, the MD was located 80 cm from the ileocecal valve and was diagnosed pre-operatively, which enabled planned single-port surgery. Some cases that bleed continuously or in whom it is difficult to stop the bleeding require surgery. In the present case, continuous blood transfusion was needed due to the bleeding. Laparoscopic surgery has been reported to be effective for a complicated MD, not only for its cosmetic value and lesser invasiveness, but also for finding other bleeding lesions [5].

There has been a recent trend towards scarless surgery, and SILS technique has attracted attention in the field of laparoscopic surgery [12]. Using a single port with multiple working channels, SILS can reduce the number of incisions and improve cosmesis and the rates of incisional hernia and port site-related complications [13–15]. A recent meta-analysis comparing SILS and traditional multi-port laparoscopy showed that SILS had less blood loss, shorter time to flatus, shorter hospital stay, and smaller incision [16]. As in the present case, in regard to laparoscopic surgery for MD, SILS has been reported to be as effective as multiport surgery.

4. Conclusion

A case of single-incision laparoscopic diverticulectomy for a bleeding MD was presented. We could diagnose the lesion by double-balloon endoscopy preoperatively. Thus we could performed planned SILS approach, which was effective for cosmesis, postoperative pain, and a short hospital stay.

Consent

Written consent from the patient to publish a case report has been obtained.

Conflict of interest

None.

Funding

This study was not supported by any grant.

Ethical approval

Not applicable.

Author contributions

Toshio Shiraishi, Tetsuro Tominaga, Takashi Nonaka, were responsible for the study concept. Kouki Wakata, Masaki Kunizaki, Shuichi Tobinaga, Yoriyama Sumida, and Shigekazu Hidaka collaborated in the patient's medical care. Terumitsu Sawai, Takeshi Nagayasu reviewed the manuscript.

Guarantor

Tetsuro Tominaga.

References

- [1] S. Soderlund, Meckel's diverticulum: a clinical and histologic study, *Acta Chir. Scand.* 248 (1959) 141–143.
- [2] J. Sagar, V. Kumar, D.K. Shah, Meckel's diverticulum: a systemic review, *J. R. Soc. Med.* 99 (2006) 501–505.
- [3] K. Uehara, Y. Yoshioka, T. Ebata, et al., Combination therapy with single incision laparoscopic surgery and double-balloon endoscopy for small intestine bleeding: report of three cases, *Surg. Today* 43 (2013) 1062–1065.
- [4] K. Taniuchi, H. Tanaka, S. Iwamura, et al., Meckel's diverticulum preoperatively diagnosed by double-balloon endoscopy, *Intern. Med.* 51 (2012) 1023–1026.
- [5] K.A. Ruscher, J.N. Fisher, C.D. Hyghes, et al., National trends in the surgical management of Meckel's diverticulum, *J. Pediatr. Surg.* 46 (2011) 893–896.
- [6] R.A. Agha, A.J. Fowler, A. Saetta, et al., The SCARE statement: consensus-based surgical case report guidelines, *Int. J. Surg.* 34 (2016) 180–186.
- [7] J. Dumper, S. Mackenzie, P. Mitchell, et al., Complications of Meckel's diverticula in adults, *Can. J. Surg.* 49 (2006) 353–357.
- [8] J.J. Cullen, K.A. Kelly, C.R. Moir, et al., Surgical management of Meckel's diverticulum, *Ann. Surg.* 220 (1994) 564–569.
- [9] D. St-Vil, M.L. Brandt, S. Panic, et al., Meckel's diverticulum in children – a 20 years review, *J. Pediatr. Surg.* 220 (1991) 564–569.
- [10] M.J. Schwartz, J.H. Lewis, Meckel's diverticulum: pit falls in scintigraphic detection in the adult, *Am. J. Gastroenterol.* 79 (1984) 611–618.
- [11] U. Keisuke, Y. Yuichiro, E. Tomoki, et al., Combination therapy with single incision laparoscopic surgery and double-balloon endoscopy for small intestinal bleeding: report of three cases, *Surg. Today* 43 (2013) 1062–1065.
- [12] M. Nisreen, D.S. Keller, E.M. Haas, Review of single incision laparoscopic surgery in colorectal surgery, *World J. Gastroenterol.* 14 (2015) 10824–10829.
- [13] Y.H. Tam, K.W. Chen, Y.S. Wong, et al., Single-incision laparoscopic surgery in diagnosis and treatment for gastrointestinal bleeding of obscure origin in children, *Surg. Laparosc. Endosc. Percutan. Tech.* 23 (2013) 106–108.
- [14] K. Hattori, M. Sato, Miyauchi, et al., Single-incision laparoscopic surgery for small bowel resection with an intraumbilical arcuate incision in children, *Asian J. Endosc. Surg.* 5 (2012) 172–175.
- [15] Y.H. Tam, K.H. Lee, J.D. Sihoe, Initial experience in children using conventional laparoscopic instruments in single-incision laparoscopic surgery, *J. Pediatr. Surg.* 45 (2010) 2381–2385.
- [16] Y.M. Zhou, L.P. Wu, Y.F. Zhao, et al., Single-incision versus conventional laparoscopy for colorectal disease: a meta-analysis, *Dig. Dis. Sci.* 57 (2012) 2103–2112.

Open Access

This article is published Open Access at sciedirect.com. It is distributed under the [IJSCR Supplemental terms and conditions](#), which permits unrestricted non commercial use, distribution, and reproduction in any medium, provided the original authors and source are credited.