

Anterior cervical arthrodesis using an osteoconductive scaffold: The use of beta-tricalcium phosphate with local bone marrow aspirate in over 100 patients

Wilson Z. Ray, MD, Neill M. Wright, MD *

Washington University School of Medicine, St. Louis, Missouri

Materials and methods

One-hundred and twenty-three consecutive low-risk patients undergoing anterior cervical discectomy and fusion at 1, 2, or 3 levels, for either myelopathy or radiculopathy, were treated by a single surgeon using a polyetheretherketone (PEEK) spacer containing an osteoconductive putty consisting of a compression-resistant, 90% porous beta tricalcium phosphate (β -TCP), and collagen (Vitoss Pack; Orthovita, Malvern, Pennsylvania) reconstituted with bone marrow aspirate from the adjacent vertebral bodies and an anterior cervical plate (Reflex; Stryker Spine, Kalamazoo, Michigan). Patients were prospectively followed to evaluate fusion outcomes and complications in a study approved by the Institutional Review Board of Washington University School of Medicine.

The senior author's practice is to stratify patients according to risk for failed fusion. Patients with tobacco use, prior failed fusion, certain medications (such as chronic steroids), or with certain collagen disorders are stratified as high-risk. All patients enrolled in this study were considered low-risk for fusion failure. The surgical treatment method and results in high-risk patients is being prepared separately.

After a standard anterior cervical discectomy was performed for decompression, 2.5 mL of bone marrow was aspirated from the adjacent vertebral body from the Caspar post tract using a 10-mL syringe and a blunt tip needle. This bone marrow aspirate was injected in a 1:1 ratio onto 2.5 mL of a 90% porous β -TCP/10% collagen mix. This putty was packed into the PEEK spacer, which was then inserted into the discectomy defect and countersunk. Additional putty was packed on one side of the PEEK spacer, and ventral to the spacer, prior to insertion of the anterior cervical plate.

Patients were evaluated at 6 weeks and 3 months with anteroposterior and lateral radiographs, and at 6 months with anteroposterior, lateral, flexion, and extension radiographs. Fusion, defined as bridging bone and less than 2° of motion on dynamic films, was assessed by an independent, blinded radiologist.

Results

Overall, 181 levels were treated in 123 patients. There were no operative complications. Two patients were lost to follow-up after their 6-week visit. An additional 20 patients were lost to follow-up after their 3-month visits. All 22 had normal anteroposterior and lateral radiographs showing progression towards fusion, but no conclusions regarding fusion can be drawn on this group.

One-hundred and one patients were followed at least 6 months, with 153 levels treated in this group (53 single-level, 44 2-level, and 4 3-level cases). Sixty-two of those treated had degenerative disk disease, while 38 had ruptured soft disks. One patient had a traumatic disk. All patients were considered low-risk for fusion-related issues, although 7 patients did smoke lightly (less than ½ pack per day).

At 6 months, all 101 patients showed bridging bone on plain radiographs. However, 11 (10.9%) had more than 2° of motion on dynamic radiographs. These 11 patients were then followed to 12 months with repeat dynamic films and/or computed tomography scans. Eight of these 11 patients were subsequently confirmed as fused.

In total, 98 of 101 patients (97.0%) demonstrated fusion (Figs. 1 and 2). Of 153 levels, 150 (98.0%) treated demonstrated fusion. Two of the patients with failed fusion were 3-level cases, with solid fusion at the upper 2 levels in each case. The remaining patient was a single-level case. None of the 3 patients with fusion failure were symptomatic, and none required re-operation. The fusion rate in 1- and 2-level patients was 99% (96/97).

Discussion

Although autograft remains the gold standard for achieving fusion in anterior cervical arthrodesis, with reported single-level fusion rates of 95–97%,^{1,2} morbidity at the donor site can be significant with high rates of chronic pain³ and wound breakdown⁴ reported. Allograft bone supported with anterior cervical instrumentation provides equivalent fusion rates, 96% in single-level arthrodesis,⁵ without the associated morbidity of graft harvest. However, varying quality of allograft, supply variations, and concerns over allograft tissue safety has diminished its appeal in recent years. In 2005, recall of small amounts of allograft tissue due to fraudulent procurement by Biomedical Tissue Ser-

* Corresponding author: Neill M. Wright, MD, Herbert Lourie Professor of Neurological Surgery, Associate Professor in Neurological and Orthopaedic Surgery, Washington University School of Medicine, 660 S. Euclid Avenue, Box 8057 St. Louis, MO 63110.

E-mail address: wrightn@nsurg.wustl.edu

doi:10.1016/j.esas.2009.09.008

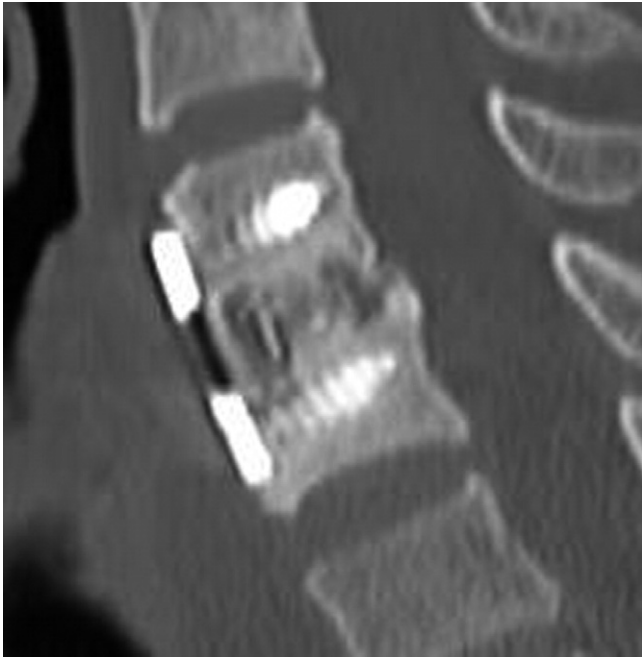

Fig. 1. Illustrative case of a 58-year-old woman with a herniated disc at C5-6 and radicular pain refractory to conservative treatment. An anterior cervical discectomy and fusion was performed using a PEEK spacer filled with osteoconductive β -TCP/collagen putty reconstituted with bone marrow aspirate from the adjacent vertebral body. At 6 months, a sagittal reconstruction CT scan demonstrates bridging bone in the PEEK spacer.

vices in New Jersey led to wide media coverage and subsequent public apprehension regarding allograft.

Osteoinductive graft materials have also been described, with rh-BMP-2 being the most studied. This has been used as an off-label application in the cervical spine, with 100% fusion rates in anterior cervical arthrodesis reported.^{6–8} However, complications of significant swelling resulting in tracheostomy, gastrostomy,^{6,8} and death have been reported, tempering the increased fusion rates. The Food and Drug Administration has issued an advisory against the use of rh-BMP-2 in the cervical spine outside of approved clinical studies.⁹

Osteoconductive synthetic bone substitutes have been studied increasingly as a replacement of autograft and allograft in spinal surgery. These synthetic cancellous bone void fillers provide a scaffold for attachment, proliferation, and differentiation of osteoprogenitor cells, and are classified as osteoconductive. A wide myriad of synthetics have been investigated and several variables have been shown to be critical to success, including mechanical properties, formulation, 3-dimensional architecture, and degradation characteristics.¹⁰ The addition of osteoinductive and osteogenic bone marrow aspirate increases further the potential success in spinal applications.

The use of synthetic osteoconduction materials in the interbody space, such as in the anterior cervical spine, also

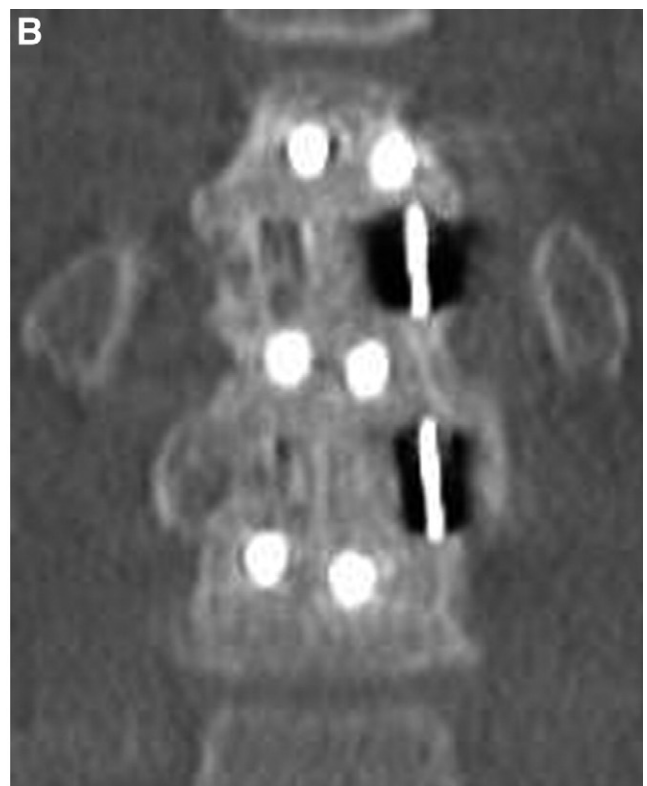
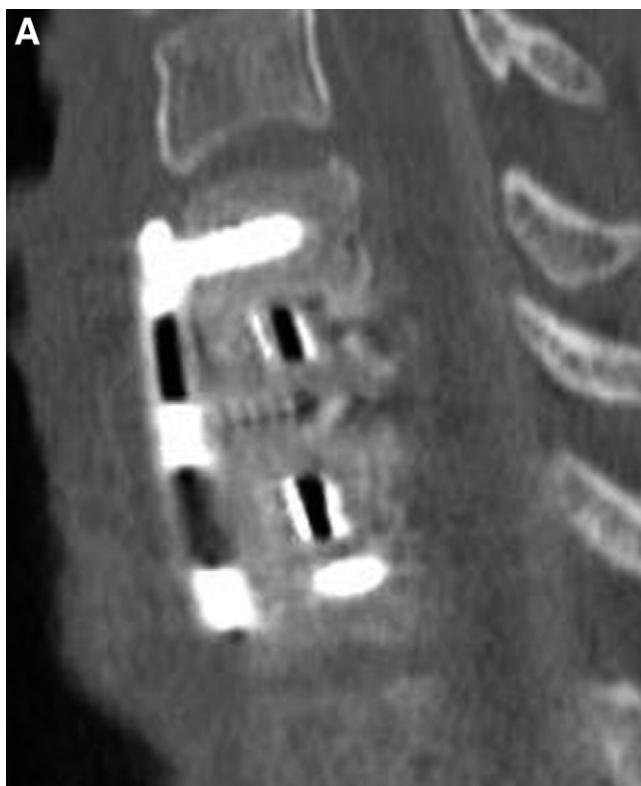

Fig. 2. Illustrative case of a 40-year-old male with degenerative disc disease at C5-6 and C6-7 and radicular pain refractory to conservative treatment. An anterior cervical discectomy and fusion was performed using PEEK spacers filled with osteoconductive β -TCP/collagen putty reconstituted with bone marrow aspirate from the adjacent vertebral body. At 6 months, sagittal (A) and coronal (B) reconstructions demonstrate solid bridging bone at both levels.

requires structural support. Early attempts at providing both mechanical support and osteoconduction with a single graft were alarmingly unsuccessful, with a coralline-derived hydroxyapatite graft fragmenting in nearly 90% of patients.¹¹ In the authors' current study, PEEK spacers were used to provide the mechanical support of the interbody space to circumvent this limitation of synthetic grafts.

Synthetic osteoconductive grafts from a variety of materials are available on the market—with formulations of hydroxyapatite, β -TCP, calcium sulfate, as well as admixtures of these materials. Limited published human data is available for hydroxyapatite-derived grafts in the spine, with poor results in both the cervical spine¹¹ and lumbar interbody¹² applications. More promising published human data is available on the use of β -TCP grafts in the lumbar spine.^{13–17}

The material content also affects the subsequent degradation and resorption of the synthetic graft. Ideally, after providing the scaffold for bone formation, the synthetic graft ultimately should dissipate. If a graft resorbs too quickly, however, bone formation may not occur in time and the fusion fails; if it resorbs too slowly, the material may make determinations of fusion difficult.

The amount of porosity in synthetic materials and the size of the pores appear critical.^{10,18} Porosity determines the bulk flow of nutrients, with smaller interconnected pores (<100 nm) facilitating the bulk flow of oxygen and nutrients into the graft material by wicking. Larger pores (150–500 μ m) are necessary for penetration of vascular tissues necessary for bone ingrowth.¹⁰ In animal interbody models, the degree of porosity correlated to fusion rates, with ideal fusion rates occurring with increasing porosity of a β -TCP synthetic.¹⁸

In this study, we used a β -TCP synthetic (Vitoss) containing 39% calcium and 20% phosphate [β -Ca₃(PO₄)₂]. Electron microscopy has demonstrated 90% interconnected porosity, with pore size ranging from 1 mm down to 1 μ m. This low-density, ultraporous synthetic cancellous bone void filler has been shown to facilitate bone and blood vessel in-growth through larger pores, with smaller pores providing nutrient and fluid transport.¹⁴

Prior published human clinical trials have proven the efficacy of β -TCP grafts in lumbar applications. In both noninstrumented¹⁵ and instrumented¹⁴ posterolateral fusions, β -TCP was used to supplement primarily local autograft with 2-year fusion rates of 85% and 93%, respectively. β -TCP has also been used to reconstruct the anterior iliac crest after graft harvest, with significant improvements in postoperative pain.¹⁷

In this study, low-risk patients undergoing an anterior cervical discectomy and fusion were treated with β -TCP reconstituted with local bone marrow aspirate, and we followed at least 6 months to assess fusion. Our fusion rate of 97% in 101 patients compares well to prior reported rates of 95–97% with either autograft or allograft, but without the morbidity of autograft harvest or the concerns of human-

derived tissue. Excluding the 3-level patients from the study, a group known to have a higher pseudarthrosis rate suggests a fusion rate of 99% (96 of 97) in 1- and 2-level low-risk cervical patients.

These results, along with the prior published human studies in the lumbar spine, demonstrate that an osteoconductive ultraporous β -TCP scaffold, along with osteoinductive and osteogenic bone marrow aspirate, provides a safe, FDA-approved alternative to autograft and allograft for certain spinal surgery applications. Our initial results were in a favorable surgical group, with high fusion rates expected in this low-risk population. The challenge will be to see if these same results are obtainable in more difficult fusion models such as lumbar interbody, or in higher-risk cervical patients.

Already underway is a study of high-risk anterior cervical patients. This group includes heavy smokers, those with prior cervical pseudarthrosis, or those taking certain medications such as chronic steroids. We have started treating those patients with a modified β -TCP (VitossBA) which incorporates bioactive glass. The history of bioactive glass suggests that the release of silicon, calcium, and sodium ions into the environment of bone healing acts in an osteostimulatory fashion to increase osteoblast activity (proliferation and protein production) and speeds up bone formation.¹⁹ Early results of treating high-risk anterior cervical arthrodesis patients with bioactive β -TCP are promising. These results will be presented shortly.

References

1. Bishop RC, Moore KA, Hadley MN. Anterior cervical interbody fusion using autogeneic and allogeneic bone graft substrate: a prospective comparative analysis. *J Neurosurg* 1996;85:206–10.
2. Zdeblick TA, Ducker TB. The use of freeze-dried allograft bone for anterior cervical fusions. *Spine* 1991;16:726–9.
3. Fernyhough JC, Schimandle JJ, Weigel MC, et al. Chronic donor site pain complicating bone graft harvesting from the posterior iliac crest for spinal fusion. *Spine* 1992;17:1474–80.
4. Laurie SW, Kaban LB, Mulliken JB, et al. Donor-site morbidity after harvesting rib and iliac bone. *Plast Reconstr Surg* 1984;73:933–8.
5. Kaiser MG, Haid RW Jr, Subach BR, et al. Anterior cervical plating enhances arthrodesis after discectomy and fusion with cortical allograft. *Neurosurgery* 2002;50:229–36; discussion 236–8.
6. Shields LB, Raque GH, Glassman SD, et al. Adverse effects associated with high-dose recombinant human bone morphogenetic protein-2 use in anterior cervical spine fusion. *Spine* 2006;31:542–7.
7. Smucker JD, Rhee JM, Singh K, et al. Increased swelling complications associated with off-label usage of rhBMP-2 in the anterior cervical spine. *Spine* 2006;31:2813–9.
8. Tumialan LM, Pan J, Rodts GE, et al. The safety and efficacy of anterior cervical discectomy and fusion with polyetheretherketone spacer and recombinant human bone morphogenetic protein-2: a review of 200 patients. *J Neurosurg Spine* 2008;8:529–35.
9. Schultz DG. FDA Public Health Notification: Life-threatening complications associated with recombinant human bone morphogenetic protein in cervical spine fusion; July 1, 2008.
10. Muschler GF, Nakamoto C, Griffith LG. Engineering principles of clinical cell-based tissue engineering. *J Bone Joint Surg Am* 2004;86-A:1541–58.
11. McConnell JR, Freeman BJ, Debnath UK, et al. A prospective randomized comparison of coralline hydroxyapatite with autograft in cervical interbody fusion. *Spine* 2003;28:317–23.

12. Neen D, Noyes D, Shaw M, et al. Healos and bone marrow aspirate used for lumbar spine fusion: a case controlled study comparing healos with autograft. *Spine* 2006;31:E636–40.
13. Epstein NE. Bone void filler in posterior iliac crest reconstruction and to supplement intertransverse process fusion. *Spine J* 2006;6:600–2.
14. Epstein NE. A preliminary study of the efficacy of Beta Tricalcium Phosphate as a bone expander for instrumented posterolateral lumbar fusions. *J Spinal Disord Tech* 2006;19:424–9.
15. Epstein NE. An analysis of noninstrumented posterolateral lumbar fusions performed in predominantly geriatric patients using lamina autograft and beta tricalcium phosphate. *Spine J* 2008;8: 882–7.
16. Lerner T, Bullmann V, Schulte TL, et al. A level-1 pilot study to evaluate of ultraporous beta-tricalcium phosphate as a graft extender in the posterior correction of adolescent idiopathic scoliosis. *Eur Spine J* 2009;18:170–9.
17. Resnick DK. Reconstruction of anterior iliac crest after bone graft harvest decreases pain: a randomized, controlled clinical trial. *Neurosurgery* 2005;57:526–9; discussion 526–9.
18. Toth JM, An HS, Lim TH, et al. Evaluation of porous biphasic calcium phosphate ceramics for anterior cervical interbody fusion in a caprine model. *Spine* 1995;20:2203–10.
19. Hench LL. The story of Bioglass. *J Mater Sci Mater Med* 2006;17: 967–78.