

ORIGINAL PAPER

doi: 10.5455/medarh.2023.77.258-262

MED ARCH. 2023; 77(4): 258-262

RECEIVED: JUN 13, 2023

ACCEPTED: AUG 05, 2023

¹Doctoral Program in Medical Science
Faculty of Medicine Universitas Brawijaya,
Malang, Indonesia

²Department of Biochemistry and
Biomolecular Faculty of Medicine
Universitas Brawijaya, Malang, Indonesia

³Department of Nursery Polytechnic
Program Ministry of Health, Malang,
Indonesia

⁴Department of Parasitology Faculty of
Medicine Universitas Brawijaya Malang,
Indonesia

⁵Department of Pharmacy, Faculty of
Medicine Universitas Brawijaya, Malang,
Indonesia

⁶Department of Obstetric and
Gynaecology, Faculty of Medicine
Universitas Brawijaya, Saiful Anwar
General Hospital, Malang, Indonesia

Corresponding author: Loeki Enggar Fitri,
Department of Parasitology Faculty of
Medicine Universitas Brawijaya Malang,
Indonesia, Jl. Veteran Malang 65145,
Indonesia, Tel. +62341569117 ; E-mail:
lukief@ub.ac.id. ORCID ID: [http://www.
orcid.org/0000-0002-4880-1048](http://www.orcid.org/0000-0002-4880-1048).

Fetal Growth Retardation is Associated with High Apoptotic Cells and Low VEGF Expression in Placenta of Malarial Pregnant Mice

Kana Mardhiyyah^{1,2}, Tanto Hariyanto³, Teguh Wahyu Sardjono⁴, Sri Winarsih⁵, Tatit Nurseta⁶, Loeki Enggar Fitri⁴

ABSTRACT

Background: During pregnancy, pregnant women are susceptible to malaria, contributing significantly to maternal and infant mortality. **Objective:** This research was conducted to study the effect of Plasmodium berghei infection in pregnant mice on fetal growth retardation through placental cell apoptosis and the change of local vascularization. **Methods:** Eighteen pregnant Balb/c strain mice resulting from simultaneously mating were divided into two groups those were nine pregnant mice used as non infected group and nine pregnant mice infected with Plasmodium berghei on day 9th post mating used as infected group respectively. On day 15th of post mating, all of the pregnant mice were killed. Fetal weights were measured using analytic balance. Apoptosis of placental cells and VEGF expression in the placental tissue were measured using immunohistochemistry. **Results:** Result showed that there was sequestration of parasite-infected red blood cells (PRBCs) in intervillous space. Statistical analysis showed that the fetal weights in infected pregnant mice group was significantly lower than non infected one ($p = 0.01$), and the placental cell apoptosis in placental tissue of infected pregnant mice was significantly higher than the non infected one ($p=0.00$). There was also a significant difference on VEGF expression between infected group and non infected group ($p= 0,00$). **Conclusion:** Plasmodium berghei infection in pregnant Balb/c mice can cause fetal growth retardation due to high of placental cell apoptosis and low VEGF expression.

Keywords: malaria in pregnancy, apoptosis, VEGF.

1. BACKGROUND

Pregnancy is a unique and interesting physiological phenomenon, where the fetus which is actually a semi-allograft and normally should be rejected by maternal immune response, can still accepted until the fetus being aterm, and finally rejected as a normal delivery (1-3) Pregnancy failure actually is a form of precipitation of rejection. It can be caused by many factors such as genetics, chromosomal and anatomical defects, and also infections (4)

Malarial infection in pregnant women, especially the non-immune individuals, can cause pregnancy failure in many forms of manifestations, such as abortion, immature, premature, still birth, congenital anomalies, intra uterine growth retardation/ restriction (IUGR) and low birth weight (LBW); depends on the parity and stage of pregnancy when the mother gets malaria infection and the severity of malarial disease. Complications are more often and severe in primi than multigravida (5, 6).

It has been proved that angiogenic dysregulation, imbalances in cytokine production, and disruption of complement activation pathway might be involved in the placental injury (7). Increased inflammatory responses in the infected placenta by sequestration of the parasite result into intrinsic pathway of apoptosis due to abundant oxidative stress and might disturb the maternal-fetal circulation that in turn causes placental cell death (8, 9).

This research was conducted to reveal that malaria infection in pregnant mice can cause IUGR via sequestration of PRBCs in intervillous space through placental cell apoptosis and the change of local vascularization by measuring VEGF expression.

© 2023 Kana Mardhiyyah, Tanto Hariyanto, Teguh Wahyu Sardjono, Sri Winarsih, Tatit Nurseta, Loeki Enggar Fitri

This is an Open Access article distributed under the terms of the Creative Commons Attribution Non-Commercial License (<http://creativecommons.org/licenses/by-nc/4.0/>) which permits unrestricted non-commercial use, distribution, and reproduction in any medium, provided the original work is properly cited.

2. OBJECTIVE

The objective of this study was to study the effect of *Plasmodium berghei* infection in pregnant mice on fetal growth retardation through placental cell apoptosis and the change of local vascularization

3. MATERIAL AND METHODS

Study design

This study was an experimental study. Eighteen pregnant Balb/c mice resulting from synchronized mating were divided into two groups. Nine pregnant mice were infected with 0.2 mL liquid containing 5×10^6 *Plasmodium berghei* (ANKA- strain) intraperitoneally. Pregnant Balb/c mice were infected in 9th day of post mating and used as infected group, and the other nine pregnant mice were not infected and used as non infected group. On day 15th of post mating, all of the pregnant mice were sacrificed, the litters were weighed individually using analytic balance (Mettler AE 50), while the apoptosis of placental cells were measured with immunohistochemistry using TUNEL (BioVision's Apo-BrdU-IHCTM Kit), by enumerating and averaging the number of apoptotic cells in twenty high power fields. Measuring of angiogenesis was done immunohistochemistry using monoclonal antibody to VEGF (Santa Cruz Biotechnology's VEGF (VG-1)). VEGF expression was calculated in the trophoblast and deciduas, intervillous space, as well as in the lumen of a blood vessel in one piece of immunohistochemical staining preparations.

Synchronization of estrus and mating

Female mice were separated from male mice for 2-3 weeks. The female mice were in a condition of unestrus state (Leeboot effect). They were then exposed to odors of males in order to restart the estrus cycle (Pheromone effect). The female mice were simultaneously in estrus condition for about 72 hr after being exposed to male odor (Whitten effect). Finally they were simultaneously mated in pair (1:1) within 1 night

Inoculation of mice

Inoculation was done by intraperitoneally injection of as much as 106 per mL of *Plasmodium berghei* ANKA strain on the day 9th post mating or in the second period of pregnancy.

Measurement of parasitemia

To observe the degree of parasitemia, 10 μ L of blood was isolated from the end of the tail of the mice and smeared as a thin smear and dried. Then, the smear was fixed with absolute methanol until it was well distributed and dried. The slides were stained with Giemsa solution (a mixture of Giemsa stain (Merck, HX612241) and Giemsa buffer (Bioanalitika, Indonesia) at a ratio of 1:9 for 30 min, rinsed with water and dried. The degree of parasitemia was determined by examining a blood smear under a microscope at a magnification of 1000 \times . The percentage of parasitemia was computed based on the number of erythrocytes infected with malaria parasites per 1000 erythrocytes.

Apoptosis examination

Apoptosis examination was carried out by immunohistochemistry techniques (TUNEL). First, slide from

placental tissue were made then washed using PBS pH 7.4 and incubated using 20ug / mL proteinase-K for 20 minutes. After that slide were incubated in 3% H₂O₂ for 5 minutes and then washed with PBS pH 7.4. Slide then incubated with Tunel fragmented DNA labeling for 1.5 hours at 37°C and washed using PBS pH 7.4 continuing with blocking with blocking buffer for 10 minutes. The following step slides were incubated with antibodies at room temperature for 1.5 hours. and washed with PBS continued with incubated with conjugate solution for 30 minutes and washed again with PBS. After that slides were added with a peroxidase and chromagen (DAB-Diamino Benzidine) for 20 minutes at room temperature. Then washed with PBS pH 7.4, and counterstain with Mayer hematoxylin for 10 minutes. Finally slide were rinsed with tap water and washed with dH₂O, dried and covered with a cover glass then observed under a light microscope with 1000x magnification. Apoptotic cells were shown as brown in the cell nucleus. The apoptotic index was calculated by means of cells undergoing apoptosis calculated per 100 trophoblast cells with 1000x magnification, at 10 fields of view from each placental tissue preparation (7).

Measurement of angiogenesis

Angiogenesis is measured by measuring VEGF expression. VEGF was measured using placental tissue preparations that had been initialized through immunohistochemical methods using mouse VEGF monoclonal antibodies (11). Placental tissue slides were deparaffinized and washed using PBS pH 7.4. H₂O₂ was added 3% (in methanol) and then incubated for 15 minutes. Slides were washed with PBS 3 times and added with unspecific blocking protein (Triton added blocking buffer) continue with incubated for 1 hour at room temperature. After washing with PBS 3 times, slides were added with primary antibody (VEGF) and then incubated overnight at 40°C. Slides then were washed with PBS 3 times and added with secondary antibody then incubated for 1 hour at room temperature. Slides were washed with PBS 3 times and added with SA-HRP and then incubated for 40 minutes at room temperature. Washed using PBS pH 7.4 and added using a substrate for Peroxidase (DAB-Diamino Benzidine) for 20 minutes at room temperature. Finally slides were washed with H₂O and Counterstain with Mayer hematoxylin for 10 minutes, rinsed with tap water then left to dry, mounting the entanglement and covered with a cover glass then observed under a light microscope with 1000x magnification. The brown color of the cell shows VEGF expression.

Ethical approval

The experiments were performed in accordance with the guidelines and approval (No.219/EC/KEPK-S2-JK/09/2011) of the Institutional Animal Care and Use Committee of Brawijaya University

Statistical analysis

The data of the research results were analyzed with SPSS software program calculations (17). The analysis techniques used were: a) different t test two independent samples (independent t test). This technique was used to compare two mean variable values of: (i) fetal

	Infected pregnant mice	Not infected pregnant mice	p value (two tailed t-test)
Average fetal body weights (milligrams)	203,00±22.95	272,00±15.46	P=0.001*
Number of apoptotic cells	190.50±58.37	33.00±20.50	P=0.001*
Sequestration of the PRBCs in placental intervillous space	Present	Absent	

*p < 0.05 = significant different

Table 1. The Comparison between average fetal body weights, number of placental opoptotic cells, and sequestration in malarial infected and not infected pregnant mice

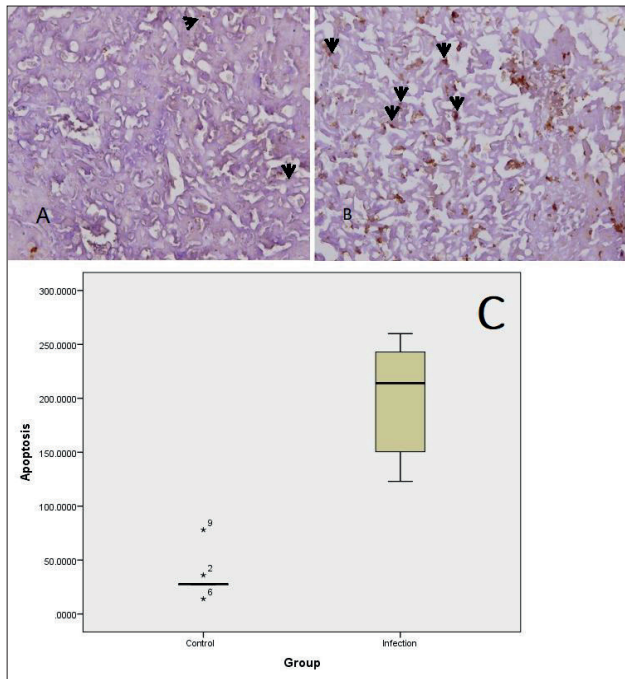


Figure 1. Apoptosis of trophoblast cells in infected and non-infected groups, indicated by arrows, in placental tissue by TUNEL assay. The number of apoptotic trophoblasts were higher in infected group (B) compared to non-infected group (A). Light microscope, magnification 400X (C) Expression of placenta apoptosis in infected and non- infected (control) groups

body weight of the control group and infected group. (ii) apoptosis of placental cells in the control group and infected group (iii) expression of VEGF (angiogenesis) control group and infected group. The test decision criteria is done by comparing the probability value (p) with a significance level = 0.05, b) Correlation test: This technique was used to determine the level of relationship of two mean variable values for: (i) Apoptosis of placental cells with fetal body weight of the infected group. (ii) Expression of VEGF (angiogenesis) with fetal body weight of the infected group.

4. RESULTS

This study showed that on the day 15th of post mating, the average of fetal body weights in infected group was less than not infected group (p = 0.001). Number of apoptotic cells in placental tissue of infected group is more than the control group (p = 0.001). The t-test independent showed a significant difference on VEGF expression between non infected group and infected group, p (p= 0,00). There was sequestration of the PRBCs

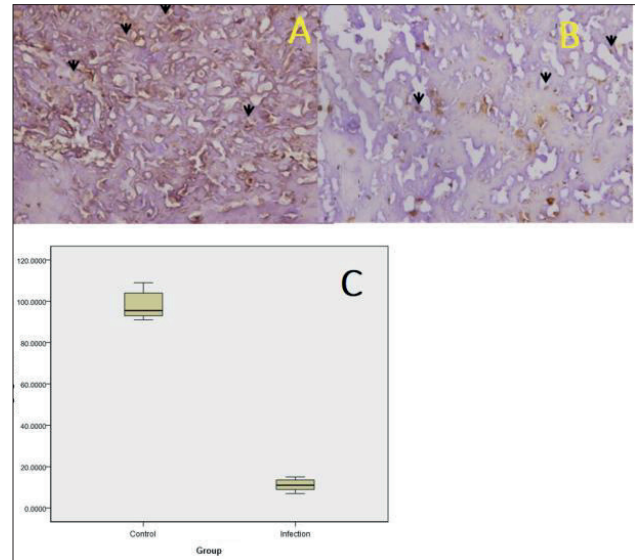


Figure 2. VEGF expression in placental of infected and non-infected groups A. Placental tissue of non-infected groups. B. Placental tissue of infected group, expression of VEGF of infected groups shown lower than in non infected group. Light microscope magnifications 1000X. C. Distribution of data between the non infected and infected groups was normal, there were significant differences between the two groups. In the control group, the data range is wide and median above / greater than the maximum value of the infected group.

in placental intervillous space in infected mice. (Table 1).

The number of apoptotic cells show on Figure 1. The VEGF expression show on Figure 2. Average fetal body weights of infected and the non infected groups show on Table 1. Placenta VEGF expression in non infected group showed higher numbers and wider spreading in the intervillous space, endothelial and placental tissue than those infected group. Placenta VEGV expression in infected group expressed very little. Using Hematoxylin and Eosin (HE) staining with magnification 1000x, there was a sequestration of Plasmodium infected erythrocytes in placental intervillous area (data not shown).

5. DISCUSSION

Malaria and pregnancy are mutually interfering conditions. The physiological of the pregnancy and the pathological of malaria have a synergistic effect on the course of each other causing specificity and severity of malaria disease. Pregnant women tend to a bias towards type-2 cytokines, resulting them to be more susceptible against diseases requiring type-1 response for protection including malaria. In malaria infected pregnant

women there is a shifting from TH2 to TH1 that makes an imbalance of the local placental immunologic, show by the decreasing of IL-10 and the elevating of IFN-, IL-2, and TNF- α (3, 12). Recent study has revealed the involvement of IL-17 that produced by TH17 and IL-10 that secreted by T-regulator, the high level of placental IL-17 caused low fetal weight, and interestingly the low fetal weight was caused by a decrease of placental IL-10 (10).

Placental apoptosis is a basic mechanism of normal delivery (13, 1) but placental apoptosis may be augmented or precipitated by a variety of condition, including hypoxia and redox imbalance. During the course of malaria infection, placenta is exposed to hypoxia. This causes apoptosis and fetal growth retardation (14, 15). Previous study stated there is a strong evident that redox imbalance and apoptosis are the two important factors for placental injury and related with the pathological consequents in malaria-infected women and infants (8). Fetal growth retardation due to increasing of placental cells apoptosis may be influenced by the sequestration of infected erythrocytes and accumulation of monocytes in placenta, which induce the release of free radicals. In this research, the number of apoptotic cells in placental tissue of pregnant mice infected by *P. berghei* is more than the non infected one ($p < 0,05$), and there is sequestration of the PRBCs in placental intervillous space. The average fetal body weight of infected mice was approximately 25% lower than in the group of non-infected mice ($p < 0.05$ two tailed t-test).

Angiogenesis includes branching of new micro vessels from larger vessels (16). Angiogenesis a key process in the development of villous blood vessels and terminal villous formation of the human placenta. The growth of placental blood vessel begins in the first stage of pregnancy and continues until delivery (17, 18). Previous study showed that malaria during pregnancy is related with pathology of placenta. This study also found the relation between the level of angiogenic factors in peripheral blood and placenta that play important roles in the structure and function of the placenta. The levels of Angiopoietin-1 in women suffered with malaria during pregnancy were associated with specific structure and function of placenta (7).

The vascular endothelial growth factor (VEGF) has been identified as one of positive regulators of angiogenesis process and the formation of new blood vessels. VEGF is dominantly expressed in the first trimester for embryonic and fetal development and participated in the proliferation, migration, and metabolic activity of trophoblasts (19-21). Therefore, parameters for measuring angiogenesis can be done by measuring VEGF expression.

Plasmodium berghei infection in pregnant mice causes placental malaria as indicated by the presence of parasitic sequestration in the placental intervillous region. *Plasmodium* sequestration induces vascular endothelial cells in the placenta. Induced endothelial cells can release pro-inflammatory mediators and decrease in anti-inflammation (22), causing VEGF expression to

decrease, thus disturb angiogenesis. It is assumed that *Plasmodium* sequestration causes a decrease in angiogenesis as evidenced by lower VEGF expression in infected placental tissue of pregnant mice

The effect of intrauterine growth restriction on fetus and placental weight were studied in mice on 21.5 days of pregnancy. Fetal body weight and placental blood flow are closely related with ligation on one side of uterine artery on 18.5 days of pregnancy. Result showed that a smaller weight fetus has a smaller placenta. There was a decrease in fetal weight and placental blood flow in the treatment group around 10% and 50% between the 19th and 21st pregnancy days compared to the control values on the 21st day. A sharp decrease in maternal placental blood flow is suspected to be the main causes of intrauterine growth restriction (23)

6. CONCLUSION

In conclusion, *Plasmodium berghei* infection in pregnant Balb/c mice causes fetal growth retardation associated with high placental cell apoptosis and low VEGF expression mediated by PRBCs sequestration in intervillous space.

- **Author's Contribution:** L.E., T.W. and K.N. gave substantial contributions to the conception or design of the work in acquisition, analysis, or interpretation of data for the work. K.N, T.H, and L.E. had a part in article preparing for drafting or revising it critically for important intellectual content. L.E., S.W., T.W. and T.N. gave final approval of the version to be published and agreed to be accountable for all aspects of the work in ensuring that questions related to the accuracy or integrity of any part of the work are appropriately investigated and resolved.
- **Conflicts of interest:** There are no conflicts of interest.
- **Financial support and sponsorship:** The authors would like to thank Faculty of Medicine, University of Brawijaya, Indonesia.

REFERENCES

1. Halperin R, Peller S, Rotschild M, Bukovsky I, and Schneider D. Placental Apoptosis in Normal and Abnormal Pregnancies. *Gynecol Obstet Invest.* 2000; 50: 84-87
2. Mor G, Cardenas I. The Immune System in Pregnancy: A unique Complexity. *American Journal of Reproductive Immunology.* 2010; 63: 425-433. doi:10.1111/j.1600-0897.2010.00836.x
3. Malik S, Sharma R, Salhan S. Chapter-10 Immunology of Normal Pregnancy. *Textbook of Obstetrics* 2016: 85-89. doi:10.5005/jp/books/12899_11.
4. Chua CLL, Khoo SKM, Ong JLE, Ramireddi GK, Yeo TW and Teo A (2021) Malaria in Pregnancy: From Placental Infection to Its Abnormal Development and Damage. *Front Microbiol.* 12: 777343. doi: 10.3389/fmicb.2021.777343
5. Adam I, Khamis AH and Elbashir MI. Prevalence and risk factors for *Plasmodium falciparum* malaria in pregnant women of Eastern Sudan. *Malaria Journal.* 2005; 4: 18. doi:10.1186/1475-2875-4-18
6. Saba N, Sultana A, and Mahsud I. Outcome And Complications Of Malaria In Pregnancy. *Gomal Journal of Medical Sciences.* 2008; 6(2): 98-101

7. Ataíde R, Murillo o, Dombrowski JG. Malaria in Pregnancy Interacts with and Alters the Angiogenic Profiles of the Placenta. *PLOS Neglected Tropical Diseases* 2015. DOI:10.1371/journal.pntd.0003824
8. Sharma L, Kaur J and Shukla G. Role of Oxidative Stress and Apoptosis in the Placental Pathology of *Plasmodium berghei* Infected Mice. *PLoS ONE* 2012;7(3). doi:10.1371/journal.pone.0032694
9. Sharma and Shukla Placental Malaria: A new insight into the Pathophysiology. *Frontiers in Medicine* 2017; Volume 4 | Article 117
10. Fitri LE, Sardjono TW, Rahmah Z, Siswanto B, Handono K, Dachlan YP. Low Fetal Weight is Directly Caused by Sequestration of Parasites and Indirectly by IL-17 and IL-Imbalance in the Placenta of Pregnant Mice with Malaria. *The Korean Journal of Parasitology* 2015; 53(2): 189-96. doi:10.3347/kjp.2015.53.2.189.
11. Meng, Q., Shao, L., Luo, X. et al. Expressions of VEGF-A and VEGFR-2 in placentae from GDM pregnancies. *Reprod Biol Endocrinol.* 2016; 14: 61. doi.org/10.1186/s12958-016-0191-8
12. Kane EG and Taylor-Robinson AW. Prospects and Pitfalls of Pregnancy-Associated Malaria Vaccination Based on the Natural Immune Response to *Plasmodium falciparum* VAR2CSA-Expressing Parasites. *Malaria Research and Treatment*, 2011; 1-21.
13. Smith SC, Baker PN, Symonds EM. Placental apoptosis in normal human pregnancy. *American Journal of Obstetrics and Gynecology.* 1997; 177(1): 57-65. doi:10.1016/s0002-9378(97)70438-1
14. Endo H, Okamoto A, Yamada K, Nikaido T, Tanaka T. Frequent apoptosis in placental villi from pregnancies complicated with intrauterine growth restriction and without maternal symptoms. *International Journal of Molecular Medicine.* 2005; 16(1): 79-84. doi:10.3892/ijmm.16.1.79.
15. Bouef P, Tan A, Romagosa C, Radford J, Mwapasa V, Molyneux ME, Meshnick SR, Hunt NH and Rogerson SYJ. Placental hypoxia during placental malaria. *J Infect Dis.* 2008; 197(5): 757–765.
16. Frater JL., Kay NE., Goolsby CL., Crawford SE., Dewald GW., Peterson LC. Dysregulated angiogenesis in B-chronic lymphocytic leukemia: Morphologic, immunohistochemical, and flow cytometric evidence. *Diagn Pathol.* 2008; 3: 16
17. Kaufmann P, Mayhew TM, Charnock-Jones DS. Aspects of human fetoplacental vasculogenesis and angiogenesis II Changes during normal pregnancy. *Placenta.* 2004; 25: 114-126.
18. Nakagawa Y, Fujimoto J, Tamaya T. Placental growth by the estrogen-dependent angiogenic factors, vascular endothelial growth factor and basic fibroblast growth factor, throughout gestation. *Gynecol Endocrinol.* 2004; 19: 259-266.
19. Arroyo JA, Winn VD. Vasculogenesis and angiogenesis in the IUGR placenta. *Semin Perinatol* 2008; 32: 172-177.
20. Ahmed A, Perkins J. Angiogenesis and intrauterine growth restriction. *Baillieres Best Pract Res Clin Obstet Gynaecol.* 2000; 14: 981-998.
21. Shiraishi S, Nakagawa K, Kinukawa N, Nakano H, Sueishi K. Immunohistochemical localization of vascular endothelial growth factor in the human placenta. *Placenta.* 1996; 17: 111-121.
22. Pacher P, Beckman JS, Liaudet L. Nitric oxide and peroxynitrite in health and disease, *Physiol Rev.* 2007; 87: 315–424.
23. Gilbert M., Leturque A. Fetal weight and its relationship to placental blood flow and placental weight in experimental intrauterine growth retardation in the rat, abstract. *J Dev Physiol.* 1982; 4(4): 237-246.