

# Unusual Presentation of Extensor Tendon Rupture Caused by a Dorsal Wrist Synovial Cyst

Salim Allahham, MD\*<sup>†‡</sup>  
 Ghanem Aljasseem, MD\*  
 Zaki Alyazji, MD\*  
 Ruba Sada, MD§  
 Mutaz Abuelgasim, MD\*  
 Sami Otman, MD\*  
 Habib Albasti, MD\*

**Summary:** Synovial cysts are juxta-articular-fluid-filled collections that are lined by synovial cells, distinguishing them from a very close cystic lesion, which is the ganglion cyst. They usually present with pain and unpleasant appearance; here we present a case of wrist synovial cyst that caused extensor tendon rupture. A 50-year-old woman presented to our clinic with a cystic lesion on the dorsum of her wrist, with an inability to extend her index finger. The lesion was found intraoperatively engulfing the extensors of the index and causing a rupture. The cyst was excised and the tendon was reconstructed; pathology report confirmed the lesion as synovial cyst. Synovial cysts and ganglion cysts are two different entities but they have been used interchangeably in the literature; pathology is the only way to differentiate between them because they usually present with identical scenarios. None of them were reported to cause extensor tendon rupture, as presented in our article. Synovial cysts can cause rupture to extensor tendons if they arise from the sheath, and it is better to anticipate synovial cyst and remove it surgically before causing any further damage, if the lesion appeared to rise from the tendon sheath on further imaging. (*Plast Reconstr Surg Glob Open* 2021;9:e3664; doi: 10.1097/GOX.0000000000003664; Published online 7 July 2021.)

A synovial cyst is a synovial fluid-filled collection that is lined by synovial cells, which distinguishes it from other cysts—most importantly, the ganglion cyst. They usually present as a focal extension of joint fluid that may, or may not, communicate with the joint<sup>1</sup>; they can also arise from bursae or tendon sheaths. Ganglia are the most common hand tumors, representing around 60% of them.<sup>2</sup> The two terms have been used interchangeably in the literature without clear definition.<sup>3</sup> Ganglia may occur at any age group but usually in 20s–40s and more in women than in men.<sup>4</sup> They are most commonly found on the dorsum of the wrist (70%), followed by volar wrist, flexor tendon sheath ganglia, and rarely interosseous or intratendinous ganglia. Here we describe a case of synovial cyst arising from the extensor tendon sheath of the

fourth compartment that caused rupture of both extensor tendons to the index finger as a rare scenario of such cysts.

## CASE PRESENTATION

A 50-year-old woman working as a home care nurse, right handed, nonsmoker, nonalcoholic, with a history of hypertension presented to our clinic, with the complaint of swelling on the dorsum of the left hand, which had been there for around 1 year. The swelling was associated with mild discomfort more than actual pain, and was stable in size. Two months before the clinic visit, the patient was cooking without putting any extra pressure on the fingers. Suddenly she felt a snap, and since then, she had noticed an inability to extend her left index finger. On physical examination, there was around 3 × 2 cm round, well-defined cyst at the mid-dorsum of the left wrist, not attached to the skin with no skin changes, not attached to deep structures, moving slightly while trying to passively move the left index finger, with positive transillumination. The patient was unable to extend her left index finger, with intact sensation and flexion of the same finger, otherwise had normal neurovascular examination of both hands, and right hand x-ray was normal.

From the clinical scenario and physical examination, suspicion of an intratendinous ganglion cyst was made as the most possible diagnosis, but the question was: is it

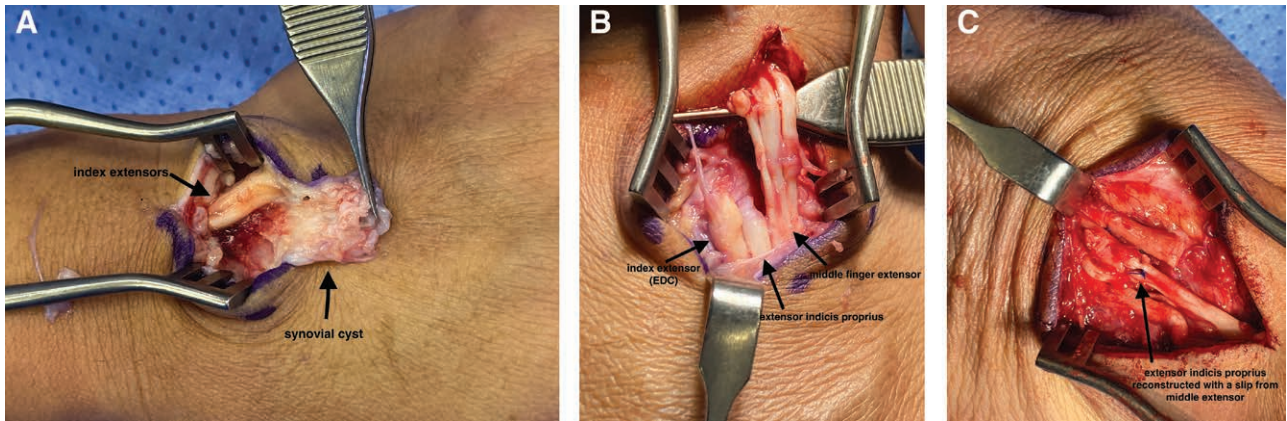
From the \*Plastic Surgery Department, Hamad General Hospital, Hamad Medical Corporation, Doha, Qatar; †Fellowship in Hand Reconstruction and Microsurgery, Ganga Hospital, India; ‡DAFPRS Fellowship, the Netherlands; and §CPESE, Hamad Medical Corporation.

Received for publication March 17, 2021; accepted May 5, 2021.

Copyright © 2021 The Authors. Published by Wolters Kluwer Health, Inc. on behalf of The American Society of Plastic Surgeons. This is an open-access article distributed under the terms of the [Creative Commons Attribution-Non Commercial-No Derivatives License 4.0 \(CCBY-NC-ND\)](https://creativecommons.org/licenses/by-nc-nd/4.0/), where it is permissible to download and share the work provided it is properly cited. The work cannot be changed in any way or used commercially without permission from the journal.

DOI: 10.1097/GOX.0000000000003664

**Disclosure:** All the authors have no financial interest to declare in relation to the content of this article.



**Fig. 1.** Patient photograph of the wrist synovial cyst. A, intraoperative photograph showing the cyst engulfing the index extensors with no appreciation of proximal ends. B, Index extensors and the 3 slips of the middle finger after removing the cyst. C, Slip of the middle finger extensor transferred to index proprius using the Pulver tuft technique.

really causing tendon rupture? To answer this question and to exclude any related malignancy, the patient was taken to theater for exploration and biopsy. Upon exploration, the cystic lesion did not look like a usual ganglion. It was attached to both extensor tendons of the index finger, not communicating with the joint space, and causing rupture to them both at zone 6. The lesion was excised totally and sent to the pathology laboratory; we could not appreciate the proximal parts of the ruptured extensors (Figs. 1, 2).

As the rupture was of a long duration, we decided not to explore the wound more. As the proximal parts would be of no use, reconstruction of the extensor indicis proprius was achieved by transferring a slip from the adjacent extensor digitorum communis of the middle finger using Pulver tuft suturing technique. The patient was discharged home, and was referred to our hand occupational therapist for rehab. At 3 months of follow-up, the patient had a full range of motion with no signs of recurrence. The patient will be followed by our clinic for an extended period to monitor any signs of recurrence.

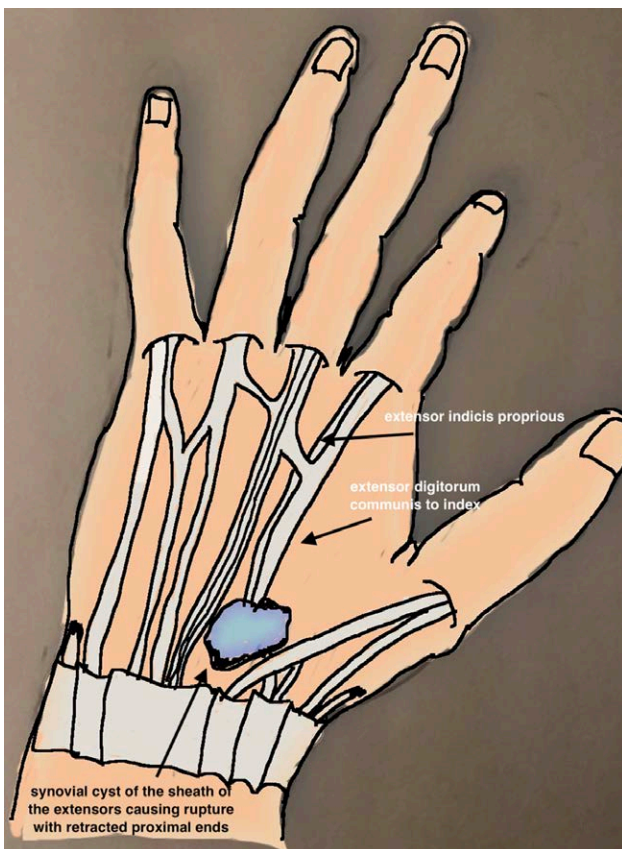
### DISCUSSION

Ganglion cysts (GCs) and synovial cysts (SCs) are soft tissue masses that develop around joints. Those cysts can be asymptomatic or cause symptoms such as pain, weakness, compression of nearby structures, or joint impairment.<sup>3</sup>

The literature on this topic is still confusing, with both terms used interchangeably. For example, different sources will use GC to qualify what, with appropriate review of the pathologic description, would truly correspond to an SC according to the previous definitions. Even more frequently, the term “synovial cyst” will be used to mention what typically corresponds to a GC, a soft tissue mass lacking a synovial lining with a mucinous, gelatinous content.<sup>5,6</sup>

These cysts come with identical clinical presentation, and the differentiation between them can almost always be made pathologically. There are many theories suggested for the pathogenesis of forming GCs, but most authors agree that they represent mucoid degeneration of periarticular structures,<sup>3,7,8</sup> which is supported by the findings under the microscope, where the wall of the cyst is composed of sheets of collagen arranged in layers without any synovial lining.<sup>9,10</sup>

In comparison, SCs are believed to be formed from the escape of extra joint effusion (caused by internal joint derangement) through a weakness point via one-way valve mechanism.<sup>11</sup> This cyst has a synovial lining, which differentiates it from ganglion. Some SCs are thought to rise from the bursa or tendon sheath itself without any communication with joints.<sup>12</sup>



**Fig. 2.** A schematic demonstrating the synovial cyst arising from the extensor tendon sheath, causing rupture with retracted proximal ends.

Diagnoses of these hand cysts are usually made clinically, with patients presenting with a palpable, transilluminating lesion that is fluctuating in size. Ultrasonography (US) is used to differentiate between cystic lesions and other solid neoplasms. One US feature that can be useful in differentiating between SCs and GCs is the compressibility, with ganglia being less compressible because of its fibrous capsule and viscous contents.<sup>13</sup> It can also help in determining whether the cyst is in communication with the joint,<sup>7</sup> and the relation with adjacent structures. Magnetic resonance imaging (MRI) or Arthro MRI can be used to exclude any ligamentous or joint injuries when those cysts present with wrist pain, plus being able to define the communication with joints if doubts persist after US.<sup>6,14,15</sup>

In this study, we describe a case of a synovial cyst located at the dorsum of the wrist that was based on the tendon sheath of the index finger extensors without any relation to the joint, which was observed intraoperatively. The patient presented clinically with extension lag of her index finger and a cyst on the dorsum of her hand, for which our first impression was a ganglion cyst, but given that no literature was provided on ganglia to cause tendon rupture, we went for surgical exploration and biopsy. Intraoperatively the cyst was engulfing the index extensors and causing rupture, which was around 2 months before presentation to the clinic. This rupture might be caused by chronic pressure from the cyst, which caused ischemic injury and thinning of the tendons, which led eventually to the rupture. Our choice after excision of the cyst was to reconstruct the extensor indicis proprius rather than to do primary repair.

In conclusion, we wanted to shed light on a rare presentation of a dorsal wrist synovial cyst that caused extensor tendon rupture. Our recommendation is to investigate any ganglion-like lesions that appear on the wrist dorsum with US or MRI to see the relations with the adjacent structures, and if the lesion appears to arise from the tendon sheath, our advice is to remove it surgically to avoid any future ruptures. This theory needs to be tested in the future, with higher level of evidence paper designs.

**Ghanem Aljasseem, MD**

Plastic Surgery Department  
Hamad General Hospital  
Hamad Medical Corporation  
Doha, Qatar  
E-mail: galjasseem@hamad.qa

## ACKNOWLEDGMENTS

We acknowledge the Qatar National Library for funding the open access publication of this article. We also acknowledge the peer reviewers for their valuable comments and feedback that significantly enhanced the content of this article. No ethical approval was needed for this study.

## REFERENCES

1. Beaman FD, Peterson JF. MR imaging of cysts, ganglia, and bursae about the knee. *Radiol Clin North Am.* 2007;45:969–982.
2. Thornburg LE. Ganglions of the hand and wrist. *J Am Acad Orthop Surg.* 1999;7:231–238.
3. Giard MC, Pineda C. Ganglion cyst versus synovial cyst? Ultrasound characteristics through a review of the literature. *Rheumatol Int.* 2015;35:597–605.
4. Meena S, Gupta A. Dorsal wrist ganglion: Current review of literature. *J Clin Orthop Trauma.* 2014;5:59–64.
5. Narváez JA, Narváez J, Aguilera C, et al. MR imaging of synovial tumors and tumor-like lesions. *Eur Radiol.* 2001;11:2549–2560.
6. Freire V, Guérini H, Campagna R, et al. Imaging of hand and wrist cysts: A clinical approach. *AJR Am J Roentgenol.* 2012;199:W618–W628.
7. Teefey SA, Dahiya N, Middleton WD, et al. Ganglia of the hand and wrist: A sonographic analysis. *AJR Am J Roentgenol.* 2008;191:716–720.
8. Schrank C, Meirer R, Stäbler A, et al. Morphology and topography of intraosseous ganglion cysts in the carpus: An anatomic, histopathologic, and magnetic resonance imaging correlation study. *J Hand Surg Am.* 2003;28:52–61.
9. Andren L, Eiken O. Arthrographic studies of wrist ganglions. *J Bone Joint Surg Am.* 1971;53:299–302.
10. McEvedy BV. The simple ganglion: A review of modes of treatment and an explanation of the frequent failures of surgery. *Lancet.* 1954;266:135–136.
11. Treadwell EL. Synovial cysts and ganglia: The value of magnetic resonance imaging. *Semin Arthritis Rheum.* 1994;24:61–70.
12. Steinbach LS, Stevens KJ. Imaging of cysts and bursae about the knee. *Radiol Clin North Am.* 2013;51:433–454.
13. Cardinal E, Buckwalter KA, Braunstein EM, et al. Occult dorsal carpal ganglion: Comparison of US and MR imaging. *Radiology.* 1994;193:259–262.
14. Stein D, Cantlon M, Mackay B, et al. Cysts about the knee: Evaluation and management. *J Am Acad Orthop Surg.* 2013;21:469–479.
15. Anderson SE, Steinbach LS, Stauffer E, et al. MRI for differentiating ganglion and synovitis in the chronic painful wrist. *AJR Am J Roentgenol.* 2006;186:812–818.