

# Molecular and Functional Defects in Kidneys of Mice Lacking Collagen $\alpha 3(\text{IV})$ : Implications for Alport Syndrome

Jeffrey H. Miner and Joshua R. Sanes

Department of Anatomy and Neurobiology, Washington University School of Medicine, St. Louis, Missouri, 63110

**Abstract.** Collagen IV is a major structural component of all basal laminae (BLs). Six collagen IV  $\alpha$  chains are present in mammals;  $\alpha 1$  and  $\alpha 2(\text{IV})$  are broadly expressed in embryos and adults, whereas  $\alpha 3-6(\text{IV})$  are restricted to a defined subset of BLs. In the glomerular BL of the kidney, the  $\alpha 1$  and  $\alpha 2(\text{IV})$  chains are replaced by the  $\alpha 3-5(\text{IV})$  chains as development proceeds. In humans, mutation of the collagen  $\alpha 3$ ,  $\alpha 4$ , or  $\alpha 5(\text{IV})$  chain genes results in a delayed onset renal disease called Alport syndrome. We show here that mice lacking collagen  $\alpha 3(\text{IV})$  display a renal phenotype

strikingly similar to Alport syndrome: decreased glomerular filtration (leading to uremia), compromised glomerular integrity (leading to proteinuria), structural changes in glomerular BL, and glomerulonephritis. Interestingly, numerous changes in the molecular composition of glomerular BL precede the onset of renal dysfunction; these include loss of collagens  $\alpha 4$  and  $\alpha 5(\text{IV})$ , retention of collagen  $\alpha 1/2(\text{IV})$ , appearance of fibronectin and collagen VI, and increased levels of perlecan. We suggest that these alterations contribute, along with loss of collagen IV isoforms per se, to renal pathology.

**C**OLLAGEN IV is a major component of basal laminae (BLs)<sup>1</sup> in vertebrates and invertebrates. Its component polypeptides, called  $\alpha$  chains, contain long "collagenous" stretches of Gly-x-y repeats that form triple helical trimers. The trimers, in turn, are covalently joined to each other at their "noncollagenous"  $\text{NH}_2$ - and  $\text{COOH}$ -terminal domains, forming a three-dimensional lattice that contributes importantly to the structural stability of the BL. In addition, collagen IV is linked to laminin, which forms the other major BL network, by the bridging glycoprotein entactin/nidogen. Together, the collagen IV and laminin networks are thought to determine the major features of the macromolecular architecture of BLs. Both laminin and collagen IV interact with cellular receptors, including the integrins, thereby playing roles in the adhesion of cells to matrix and in signaling from matrix to cells (for reviews see Hudson et al., 1993; Yurchenco and O'Rear, 1994; Kuhn, 1994; Zhou and Reeders, 1996).

Consistent with these crucial roles, mutations of either of the two collagen IV genes in *Caenorhabditis elegans* are embryonically lethal (Guo et al., 1991; Sibley et al., 1994). In vertebrates, in contrast, the situation is more complex. Mammalian BLs contain six known type IV collagen  $\alpha$  chains

(Hostikka et al., 1990; Hudson et al., 1993; Ninomiya et al., 1995; Zhou and Reeders, 1996). Most BLs are rich in  $\alpha 1$  and  $\alpha 2$  chains, suggesting that these chains may be required for embryonic development. The  $\alpha 3-6(\text{IV})$  chains, however, are selectively expressed in small subsets of BLs and are activated relatively late in development. Thus, their loss might be expected to cause tissue-specific defects. Indeed, mutations of the  $\alpha 3-5(\text{IV})$  genes in humans have been associated with Alport syndrome, a hereditary glomerulonephritis (inflammation of the kidney glomerulus) that leads to end-stage renal disease (Barker et al., 1990; Kashtan and Michael, 1993; Kashtan et al., 1994; Lemmink et al., 1994; Mochizuki et al., 1994; Antignac, 1995; Kawai et al., 1996; Tryggvason, 1996). Likewise, the  $\alpha 5(\text{IV})$  gene is mutated in a canine model of Alport syndrome (Zheng et al., 1994).

Analysis of these spontaneously occurring mutants has confirmed the importance of the collagens IV in vertebrates, but lack of a practical animal model has made it difficult to answer new questions that have arisen. How does the loss of collagen IV chains affect the structure and function of BLs? Why is renal function normal at birth in Alport syndrome, although collagens  $\alpha 3-5(\text{IV})$  are normally present in renal BLs perinatally? Are there phenotypic abnormalities associated with loss of collagen  $\alpha 3-5(\text{IV})$  from other BLs in which they are normally expressed, such as those of the testis (Enders et al., 1995), lung (Gunter et al., 1991), or skeletal neuromuscular junction (Sanes et al., 1990)? As a first step in addressing these issues, we recently cloned cDNAs encoding the  $\alpha 3-5(\text{IV})$  chains in mouse and generated subunit-specific antisera to recom-

Address all correspondence to Dr. Jeffrey H. Miner, Renal Division, Washington University School of Medicine, Campus Box 8126, 660 S. Euclid Ave., St. Louis, MO 63110-1093. Tel.: (314) 362-8235. Fax: (314) 362-8237. E-mail: minerj@thalamus.wustl.edu

1. *Abbreviations used in this paper:* BL, basal lamina; BUN, blood urea nitrogen; N-CAM, neural cell adhesion molecule; P, postnatal day.

binant  $\alpha 3\text{-5(IV)}$  fragments. Using these reagents, we showed that the distribution of the  $\alpha 1\text{-5(IV)}$  chains in mice is similar (but not identical) to that in humans (Miner and Sanes, 1994). Here, we describe the generation and characterization of mutant mice deficient in collagen  $\alpha 3\text{(IV)}$ . We document hereditary glomerulonephritis in these mice and show that fundamental alterations in the composition of renal BLs precede detectable renal pathology. Thus, alterations in matrix composition resulting from the absence of collagen  $\alpha 3\text{(IV)}$  may influence the pathogenesis of Alport syndrome.

## Materials and Methods

### Generation of Mutant Mice

A  $\lambda$  clone containing the 3' end of the *Col4a3* gene was obtained by probing a 129sv mouse genomic library (Stratagene, La Jolla, CA) with a previously described collagen  $\alpha 3\text{(IV)}$  cDNA (Miner and Sanes, 1994). The targeting vector (see Fig. 1 a) replaced two consecutive *AvrII* fragments of *Col4a3*, which contain the first three NC1 domain exons, with a *neo* cassette from the vector pPNT (Tybulewicz et al., 1991). The mutated gene was transferred to R1 ES cells (Nagy et al., 1993) by electroporation, and homologous recombinants were isolated by double selection with G418 (400  $\mu\text{g/ml}$ ) and 1-[2'-deoxy-2'-fluoro- $\beta$ -D-arabino furanosyl] 5' iodo uracil (FIAU) (0.27  $\mu\text{M}$ ). The targeting frequency was 1 in 17. Chimeras from three independently derived ES clones gave rise to heterozygous and then homozygous mutants. The phenotypes of the three lines were indistinguishable, and results from all three have been combined for presentation here.

### Molecular Analyses

For Southern analysis, genomic DNA from adult tail or liver was digested with *PstI* and probed with a  $^{32}\text{P}$ -labeled *BamHI* fragment of the *Col4a3* genomic clone. The probe lies outside the genomic sequences in the targeting vector (Fig. 1 a), and thereby provides a stringent test of homologous recombination.

RNAse protection analysis was performed using probes and methods described (Miner and Sanes, 1994). Based on the assumption that the abundance of EF1 $\alpha$  RNA varies little among tissues or with age, the level of this RNA was assayed in each sample and used to correct for possible variation in RNA amounts or purity. Relative RNA levels were determined by scanning laser densitometry of autoradiograms using an LKB Ultroskan (Pharmacia LKB Biotechnology, Inc., Piscataway, NJ).

Samples of blood and urine were collected from deeply anesthetized mice immediately before sacrifice. Total urinary protein was assayed with the Bio-Rad Protein Assay reagent (Hercules, CA) according to the manufacturer's instructions, using BSA as a standard. SDS-gel electrophoresis was performed under reducing conditions in 12% polyacrylamide gels; protein was visualized with Coomassie blue. Levels of creatinine and urea nitrogen in serum and urine were measured with a Cobas Mira Plus analyzer (Roche, Somerville, NJ).

## Histology

Methods for light and electron microscopy are described in Noakes et al. (1995b). Antibodies to collagens  $\alpha 3\text{-5(IV)}$ , laminin-1, laminin  $\beta 2$ , collagens I and VI, and neural cell adhesion molecule (N-CAM) were generated in our laboratory (Sanes et al., 1990; Miner and Sanes, 1994; Noakes et al., 1995a,b). Several antibodies were gifts of generous colleagues: antiperlecan (HK102 and HK84) from K. Kimata (Nagoya University, Nagoya, Japan) and M. Yamagata (National Institute for Basic Biology, Okazaki, Japan) (Kato et al., 1988), antilaminin  $\beta 1$  (5A2) from D. Abrahamson (University of Alabama at Birmingham) (Abrahamson et al., 1989), anti-tactin from A. Chung (University of Pittsburgh, Pittsburgh, PA) (Bender et al., 1981), anti-integrin  $\alpha 2$  (MA2) from S. Santoro (Washington University, St. Louis, MO) (Wu and Santoro, 1994), anti-integrin  $\alpha 3$  from R. Hynes (Massachusetts Institute of Technology, Cambridge, MA) (DePersio et al., 1995), anti-integrin  $\alpha 7$  from S. Kaufman (University of Illinois, Urbana, IL) (Martin et al., 1996), and antitenascin (578) from M. Schachner (Swiss Federal Inst. of Technology, Zurich, Switzerland) (Gatchalian et al., 1989). Commercial sources for other antibodies were Southern Biotechnology Associates, Birmingham, AL (collagen  $\alpha 1\text{2(IV)}$ ), Chemicon Intl., Temecula, CA (laminin  $\gamma 1$ ), Collaborative Research, Inc., Waltham, MA (fibronectin), Novocastra, Newcastle upon Tyne, UK (dysglycocalyx), and Serotec Ltd., Oxford, U.K. (integrin  $\alpha 6$ ).

## Results

To mutate the collagen  $\alpha 3\text{(IV)}$  gene (*Col4a3*), we deleted the first three coding exons of the COOH-terminal noncollagenous (NC1) domain (Fig. 1 a). This mutation was chosen because the NC1 domain is essential for assembly of a collagen IV network (Yurchenco and O'Rear, 1994; Ries et al., 1995; Zhou and Reeders, 1996) and because a similar mutation in the human *COL4A5* gene leads to a severe form of Alport syndrome (Tryggvason, 1996). The targeting vector was transferred to embryonic stem (ES) cells by electroporation, homologous recombinants were identified, and three independently derived ES cell clones generated germline chimeras after injection into mouse blastocysts. Heterozygotes displayed no detectable abnormalities and produced homozygotes at the expected Mendelian frequency. Southern analysis of genomic DNA from homozygotes confirmed disruption of the *Col4a3* gene (Fig. 1 b). As expected, no immunoreactivity was detected in any tissue with antisera to the NC1 domain of collagen  $\alpha 3\text{(IV)}$  (see below). Probes that recognize the NH $_2$ -terminal portion of the protein or the 5' end of the mRNA are unavailable for mouse, so we do not know whether truncated protein is produced. Studies of other collagens have shown, however, that any collagen chains

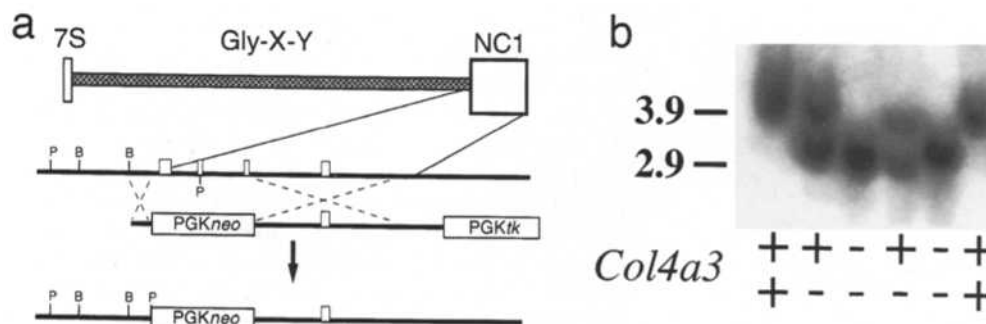


Figure 1. Mutation of the *Col4a3* gene. (a) Structure of the collagen  $\alpha 3\text{(IV)}$  protein and targeting vector, and the predicted product of homologous recombination. The protein contains a central triple helical collagenous region and a COOH-terminal noncollagenous (NC1) domain, which is essential for BL assembly. Three exons of the NC1 domain were deleted in the targeting vector. (b) Southern blot analysis of *PstI*-digested genomic DNA. The probe, which was from outside the short arm, is indicated in a. The 3.9-kb band present in wild-type mice was altered to 2.9 kb in the mutant.

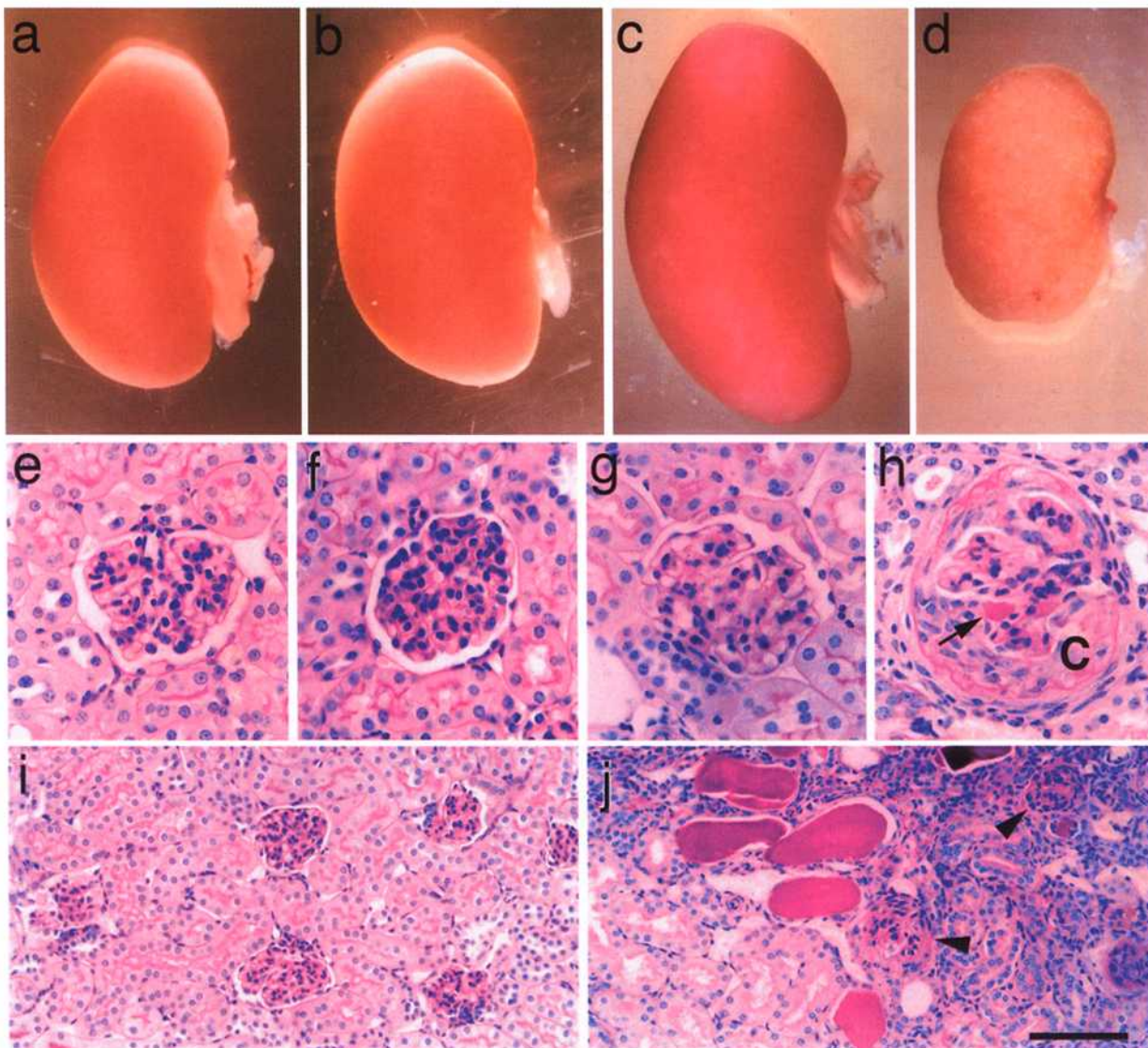
unable to assemble into matrix would be rapidly degraded (Prockop, 1992).

### Renal Failure in Collagen $\alpha 3(IV)$ Mutant Mice

Homozygous *Col4a3* mutants were externally normal at birth and for  $\sim 2$  mo thereafter. At 2–3 mo of age, however, most homozygotes began to lose weight and became lethargic. Many died in the third postnatal month, and only  $\sim 5\%$  lived longer than 4 mo. Based on the prominent glomerulonephritis in patient's with Alport syndrome, we suspected that renal failure was largely responsible for the mutants' phenotype. Indeed, mutant kidneys were shrunken, wrinkled, and discolored compared to those of heterozygous littermates at  $>P65$  (Fig. 2, *c* and *d*). Histological confirmation of glomerulonephritis is detailed be-

low. In contrast, kidneys were externally normal in  $\leq 5$ -wk-old mutants (Fig. 2, *a* and *b*) and displayed only minor histological abnormalities (Fig. 2, *e* and *f*). Thus, the *Col4a3* mutant resembles humans with Alport syndrome in displaying delayed onset renal disease.

To determine whether the renal abnormality was accompanied by impaired renal function, we measured urea and creatinine levels in blood and urine (Yager and Harrington, 1995). Urea and creatinine are produced in tissues, dissolved in blood, and passed nonselectively through the glomerular filter. Decreased glomerular function thereby leads to increased levels of both metabolites in the serum. In control mice, blood urea nitrogen (BUN) and creatinine levels changed little between postnatal days (P)20 and 120 (Fig. 3, *a* and *b*). Levels of both compounds were normal in mutants until  $\sim P60$  and then increased



**Figure 2.** Morphology and histology of collagen  $\alpha 3(IV)$ -deficient kidneys. (*a–d*) Kidneys from homozygous mutant mice (*b* and *d*) and littermate controls (*a* and *c*) at P36 (*a* and *b*) and P103 (*c* and *d*). Mutant kidneys are externally normal at P36 but shrunken and mottled at P103. (*e–j*) Periodic acid Schiff-stained sections from mutant (*f*, *h*, and *j*) and control (*e*, *g*, and *i*) kidneys at P36 (*e* and *f*) and P79 (*g–j*). Renal histology is nearly normal at P36, but glomerulosclerosis (*h*, arrowheads in *j*), glomerular crescents (*C*), an expanded interstitium, proteinaceous glomerular deposits (arrow in *h*), tubular deposits (*j*), and tubular atrophy are evident at P79. Bar in *j*: (*e–h*) 50  $\mu\text{m}$ ; (*i* and *j*) 100  $\mu\text{m}$ .

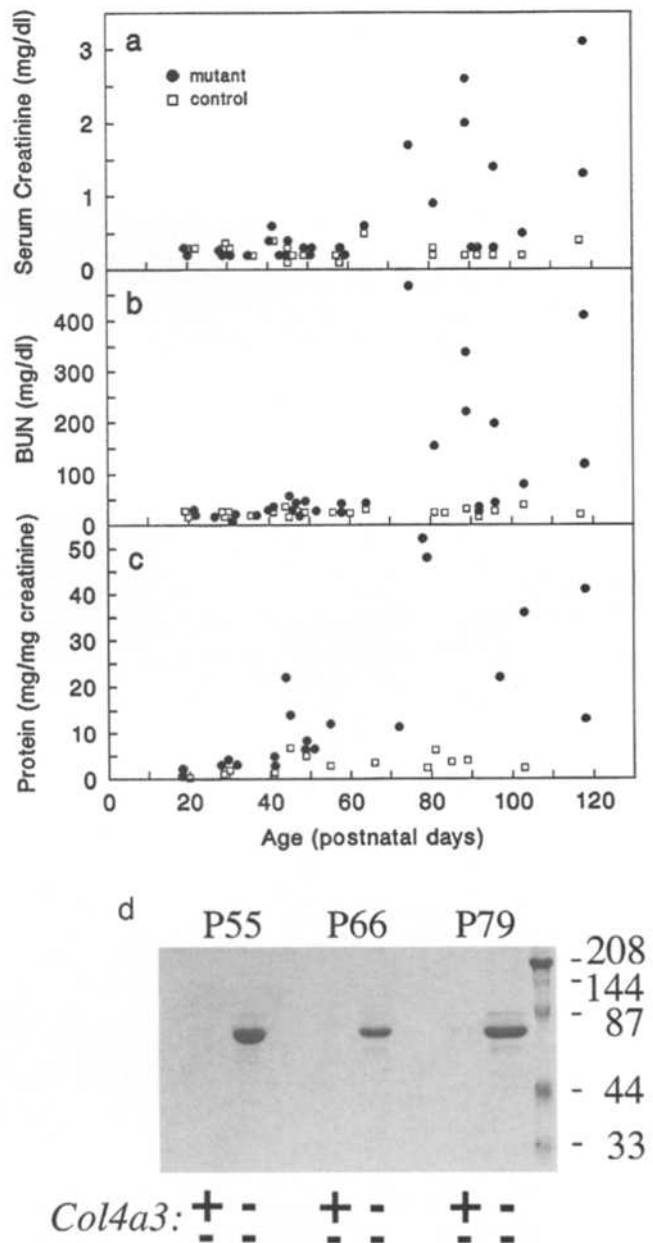
during the next month, indicating decreased filtration. Moreover, urinary volume was increased and urea nitrogen and creatinine concentrations in urine were decreased relative to controls (data not shown), which may indicate failure to concentrate the urine (a tubular function) as well as impaired filtration (a glomerular function; Yager and Harrington, 1995). Interestingly, a minority of mutants maintained normal levels of urea and creatinine in their blood as late as P100 (Fig. 3, *a* and *b*), and their kidneys showed correspondingly mild pathology (data not shown). In general, the mice with the most severe histological abnormalities displayed the most severe uremia and proteinuria. This correlation was evident both as a function of age and when comparing mice at a single age. Thus, although loss of collagen  $\alpha 3(\text{IV})$  always led to renal failure, the rate of appearance and the severity of the defect were variable.

Because the glomerular filter is freely permeable to urea and creatinine, their levels primarily reflect filtration capacity but not the integrity of the filter. To test the latter, we analyzed urine for the presence of protein, which is normally excluded from the urinary space by the glomerular BL and the cells that abut it. Levels of urinary protein were normalized to urinary creatinine to account for potential differences in the degree to which samples had been concentrated by the kidney. Until P40, mutant protein/creatinine ratios were only slightly higher than controls, but at later ages they were elevated from 2- to >20-fold (Fig. 3 *c*). Oddly, however, hematuria, a cardinal sign of Alport and other glomerulonephritides, was not evident in the *Col4a3* mutant. Therefore, to confirm that proteinuria reflected glomerular failure, we analyzed urinary protein by gel electrophoresis. When intact, the glomerular filter acts as a barrier to large proteins, such as albumin, whereas the predominant urinary proteins are of lower molecular weight in rare cases of tubular failure to resorb protein (Carlson and Harrington, 1993). As expected, the major protein in mutant urine was albumin (Fig. 3 *d*), confirming that the glomerular filter had been breached.

#### Molecular Consequences of Collagen $\alpha 3(\text{IV})$ Deficiency

Collagens  $\alpha 3\text{--}5(\text{IV})$  are present in renal BLs soon after birth (Miner and Sanes, 1994), yet we were unable to detect renal defects in the *Col4a3* mutant until after P40. Molecular alterations that precede overt pathology might provide insights into the role of collagen  $\alpha 3(\text{IV})$  in BL assembly, BL-cell interactions, and the pathogenesis of Alport syndrome. Accordingly, we stained kidneys from P15–30 mutants and littermate controls with a panel of antibodies to BL and plasma membrane components.

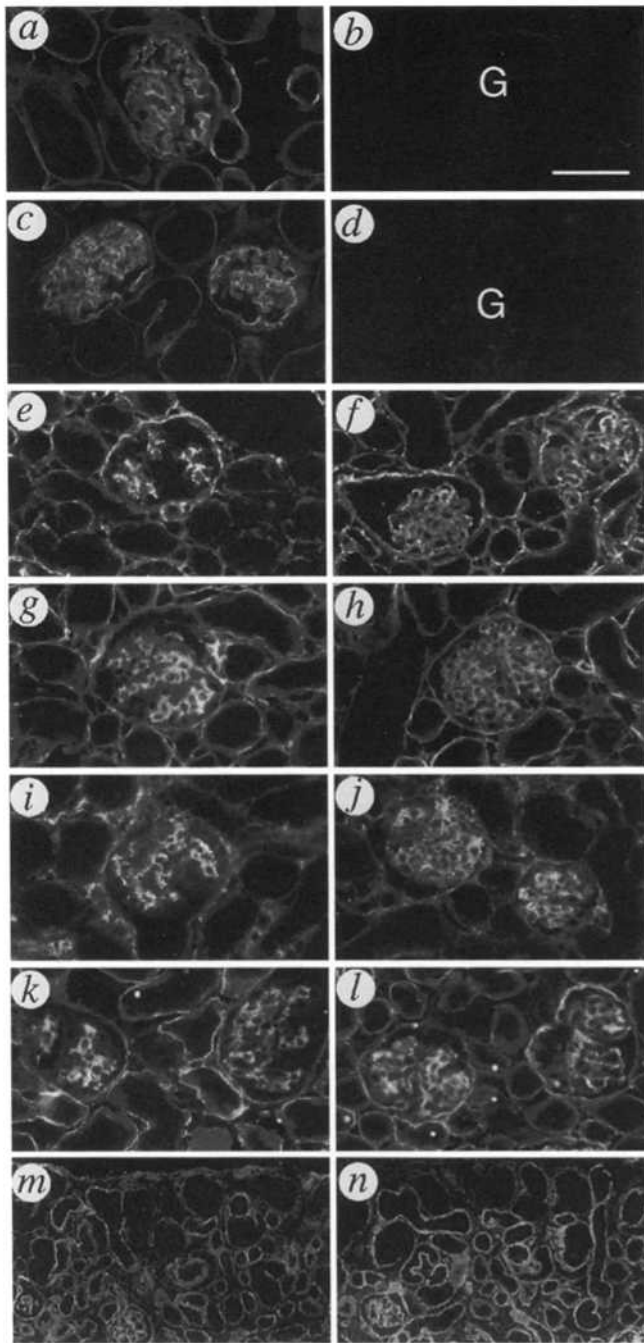
First, we assayed the collagen IV chains. As expected, collagen  $\alpha 3(\text{IV})$  was prominent in the BLs of glomeruli and of most tubules in controls but was undetectable in mutant BLs (Fig. 4, *a* and *b*). Collagens  $\alpha 4$  and  $\alpha 5(\text{IV})$  were codistributed with collagen  $\alpha 3(\text{IV})$  in controls but undetectable in mutants (Fig. 4, *c* and *d*, and Table I). In contrast, the collagen  $\alpha 1/\alpha 2(\text{IV})$  chains were nearly absent from control glomerular BL, but readily detectable in the mutant (Fig. 4, *e* and *f*). Thus, disruption of the *Col4a3* gene leads to alterations in the complement of collagen IV chains found in both glomerular and tubular BLs.



**Figure 3.** Analysis of serum and urine. (*a*) Creatinine concentration in serum. (*b*) BUN concentration. (*c*) Protein levels in urine, normalized for urinary creatinine to correct for differences in degree of urine concentration. Relative levels of urinary protein are similar in mutants and controls until  $\sim$ P40, then rise many-fold in mutants; levels of serum creatinine and BUN do not rise appreciably in mutants until after P60. Blood and urine were collected from anesthetized mice immediately before sacrifice. Each point represents a single mouse. (*d*) SDS-gel electrophoresis reveals that the major urinary protein in mutants is albumin, indicative of a defective glomerular barrier.

Changes in collagen IV immunoreactivity could reflect alterations at any of several levels, from transcription to chain assembly. To begin to distinguish these alternatives, we used an RNase protection assay to determine the levels of collagen  $\alpha 1$ ,  $\alpha 4$ , and  $\alpha 5(\text{IV})$  mRNAs in control and mutant kidneys (Fig. 5). Collagen  $\alpha 1(\text{IV})$  mRNA levels were similar in mutant and wild-type animals at P28–40, al-





**Figure 4.** Immunohistochemical analysis of kidneys in mutants (*right*) and littermate controls (*left*) at stages before renal pathology is evident. (*a-l*) P30 sections were stained with antibodies to collagen  $\alpha 3(\text{IV})$  (*a* and *b*), collagen  $\alpha 4(\text{IV})$  (*c* and *d*), collagen  $\alpha 1/2(\text{IV})$  (*e* and *f*), perlecan (*g* and *h*), fibronectin (*i* and *j*), or laminin  $\beta 1$  (*k* and *l*). Collagens  $\alpha 3-5(\text{IV})$  are absent from both glomeruli (G) and tubules in mutant kidneys. Collagen  $\alpha 1/2(\text{IV})$ , perlecan, and fibronectin are all concentrated in the mesangium of normal glomeruli but become prominent in glomerular BL in mutants. (*m* and *n*) P3 sections stained for laminin  $\gamma 1$ . Glomerulogenesis occurs normally in the mutant. G, glomerulus. Bar in *b*: (*a-l*) 50  $\mu\text{m}$ ; (*m* and *n*) 100  $\mu\text{m}$ .

though levels in mutants increased thereafter. In contrast,  $\alpha 4$  and  $\alpha 5(\text{IV})$  mRNAs were slightly elevated in mutants at all ages, indicating that the absence of these chains from mutant BLs reflects regulation at a posttranscriptional level.

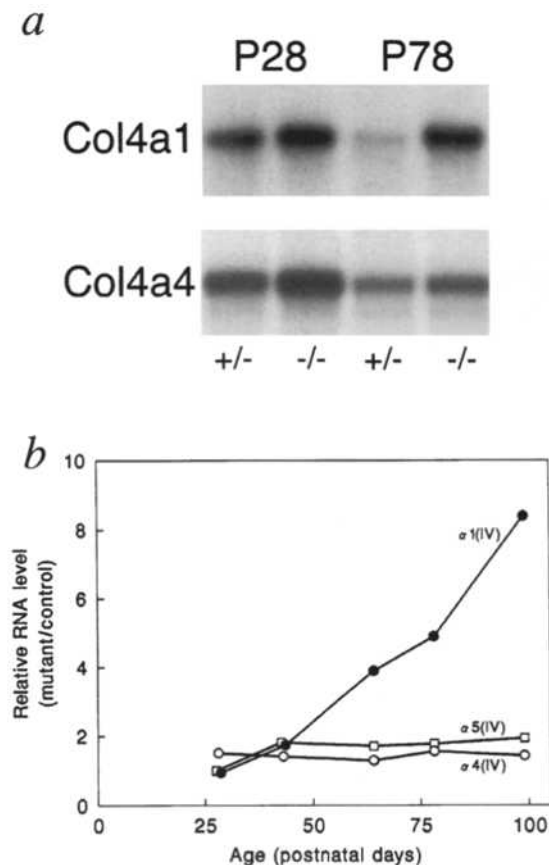
Further immunohistochemical analysis revealed three unexpected changes in the composition of glomerular BL in the mutant. First, levels of a heparan sulfate proteoglycan, perlecan (Couchman et al., 1993), were greatly increased in mutant glomerular BL; in controls, perlecan was present but concentrated in the mesangium (Fig. 4, *g* and *h*). Similar results were obtained with two independently isolated antibodies (see Materials and Methods), indicating that this alteration was more likely to reflect an increase in the level of perlecan than increased accessibility of an epitope. Second, fibronectin was abundant in the mesangium of control glomeruli, but absent from the BL of peripheral capillary loops (Laitinen et al., 1991). In mutants, in contrast, fibronectin was present at similar levels in BL and mesangium (Fig. 4, *i* and *j*). Similarly, collagen VI was restricted to mesangium in control glomeruli (Kashtan and Kim, 1992) but was also detectable in the glomerular BL of mutants (data not shown).

In contrast to these alterations, the distribution of the major noncollagenous proteins of BLs, laminin, and entactin did not differ detectably between control and mutant kidneys (Fig. 4, *k* and *l*, and Table I). Moreover, the subunit composition of laminin was similar in controls (Sanes et al., 1990; Miner and Sanes, 1994) and mutants: tubular

**Table I.** Distribution of Matrix and Membrane Antigens in the Kidneys of Control and *Col4a3* Mutant Mice

| Component                        | G   | M   | T   | I   | C |
|----------------------------------|-----|-----|-----|-----|---|
| <b>Basal lamina</b>              |     |     |     |     |   |
| Collagen $\alpha 1/2(\text{IV})$ | +++ | +++ | +++ | --- | + |
| $\alpha 3(\text{IV})$            | +-- | --- | *-- | --- | - |
| $\alpha 4(\text{IV})$            | +-- | --- | *-- | --- | - |
| $\alpha 5(\text{IV})$            | +-- | --- | *-- | --- | - |
| Laminin-1                        | +++ | +++ | +++ | --- | + |
| $\beta 1$                        | --± | +++ | +++ | --- | + |
| $\beta 2$                        | +++ | --- | --- | --- | + |
| $\gamma 1$                       | +++ | +++ | +++ | --- | + |
| Entactin                         | +++ | +++ | +++ | --- | + |
| Perlecan                         | ±++ | +++ | +++ | --- | + |
| <b>Matrix</b>                    |     |     |     |     |   |
| Collagen I                       | --- | --- | --- | ±±± | - |
| V                                | --- | ±±± | --- | ±±± | - |
| VI                               | -±± | +++ | --- | ±±± | - |
| Tenascin                         | --- | ±±± | --- | -±± | - |
| Fibronectin                      | +++ | +++ | --- | +++ | + |
| <b>Membrane</b>                  |     |     |     |     |   |
| Integrin $\alpha 2$              | --- | --- | --- | --- | - |
| $\alpha 3$                       | +++ | --- | *++ | --- | - |
| $\alpha 6$                       | ±±± | --- | ±±* | --- | - |
| $\alpha 7$                       | --- | --- | --- | --- | - |
| Dystroglycan                     | --- | --- | --- | --- | - |
| NCAM                             | --- | --- | --- | -++ | + |

G, glomerular BL or abutting cell membranes; M, mesangium; T, tubular BL or abutting membranes; I, interstitium; C, glomerular crescents. For each set of three entries, the first is from P15-66 control, the second from P30-35 mutant, and the third from P66-75 mutant. Crescents were present only in mutants at >P30. + or - denotes presence or absence of staining, respectively; ± denotes dim staining; \* denotes that only a subset was +. Note that integrin  $\alpha 2$  and dystroglycan are present in developing nephrons (Wu and Santoro, 1993; Durbeej et al., 1995).



**Figure 5.** Ribonuclease protection analysis of collagen IV chain gene expression in kidneys from mutants and littermate controls. (a) Representative experiment showing levels of collagen  $\alpha 1$  and  $\alpha 4(IV)$  RNA in heterozygous and homozygous mutant kidney at P28 and 78. (b) Ratio of RNA abundance in mutant kidney to that in littermate control as a function of postnatal age. Levels of  $\alpha 4$  and  $\alpha 5(IV)$  RNA are slightly elevated in mutants at all ages, whereas levels of  $\alpha 1(IV)$  RNA increase progressively as renal pathology worsens.

and glomerular BLs were rich in the  $\gamma 1$  chain, tubular BL contained  $\beta 1$  but no  $\beta 2$  chain, and glomerular BL contained  $\beta 2$  but little  $\beta 1$  chain (Table 1). Likewise, both mutant and control glomerular BL were rich in the recently described laminin  $\alpha 5$  chain (Miner et al., 1995), as revealed with an antiserum to a recombinant  $\alpha 5$  fragment (Miner, J.H., and J.R. Sanes, manuscript in preparation). In addition, the distribution and apparent levels of major cell surface receptors for BL components (Korhonen et al., 1990; Patey et al., 1994; Durbeej et al., 1995) were similar in mutants and controls; components examined included the collagen IV- and laminin-binding integrin subunits  $\alpha 2$ ,  $\alpha 3$ ,  $\alpha 6$ , and  $\alpha 7$  and the nonintegrin laminin receptor, dystroglycan (Table I). Thus, the alterations in the molecular architecture of mutant glomeruli are profound but selective.

Finally, we examined early postnatal kidneys in which nephrons were still forming. In the developing wild-type nephron, glomerular BL is initially rich in collagen  $\alpha 1$  and  $\alpha 2(IV)$  and laminin  $\beta 1$ , but these chains are joined by and eventually replaced by the collagen  $\alpha 3-5(IV)$  and laminin  $\beta 2$  chains, respectively, as glomerulogenesis proceeds. Tubular BL is  $\alpha 1,2(IV)$ -positive and mostly  $\alpha 3-5(IV)$ -nega-

tive at birth, but  $\alpha 3-5(IV)$  appears in a subset of tubules during the first postnatal weeks. However, in contrast to glomerular BL, tubular BL remains strongly  $\alpha 1,2(IV)$ -positive into adulthood (Miner and Sanes, 1994). Based on these patterns of expression, it seemed possible that development of tubules or glomeruli might be perturbed or delayed in the mutant. However, no defects were detected in mutant P3 kidneys, which contain glomeruli and tubules at various stages of development (Fig. 4, *m* and *n*). Moreover, the molecular transition from laminin  $\beta 1$  to  $\beta 2$  occurred on schedule in mutant glomerular BL (not shown). Thus, the appearance of the collagen  $\alpha 3-5(IV)$  chains accompanies but is not required for key events in the development of the nephron.

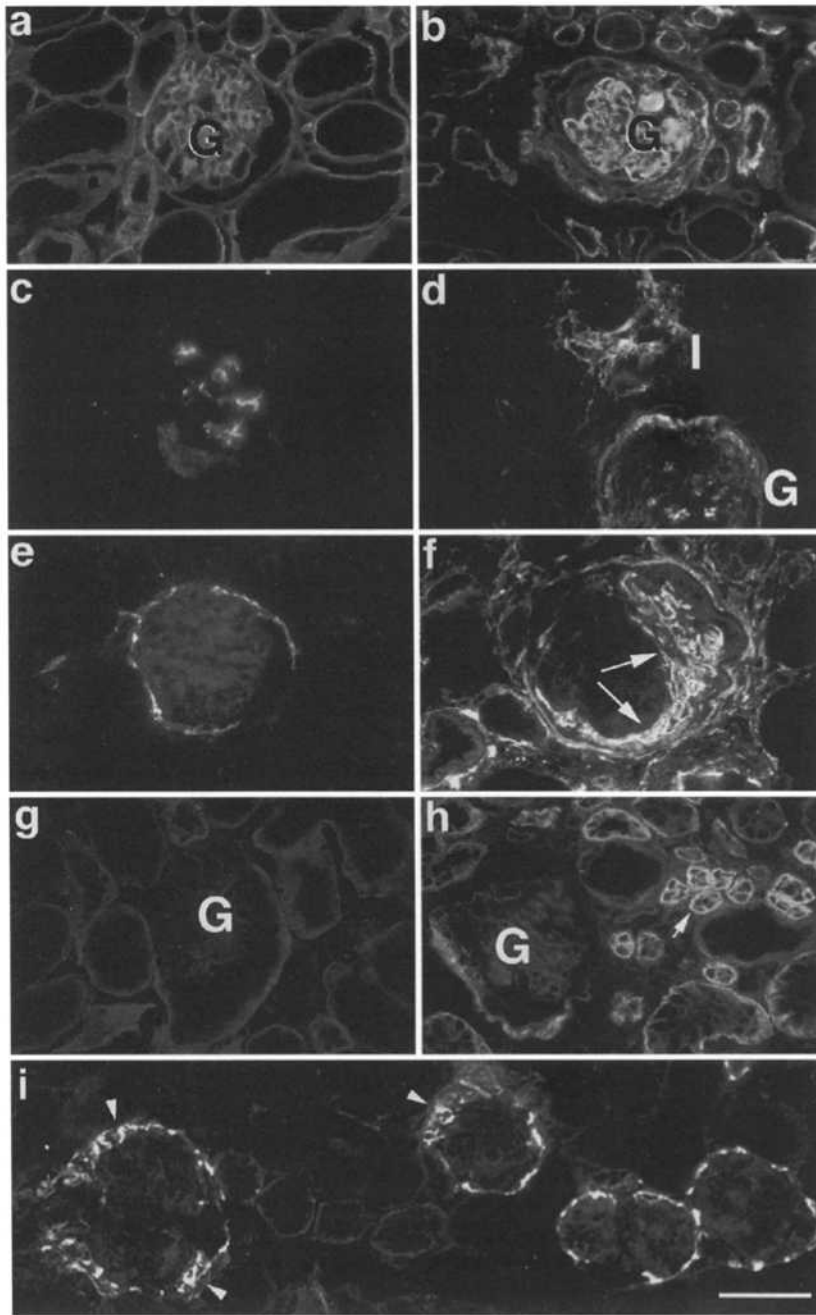
#### Pathological Consequences of Collagen $\alpha 3-5(IV)$ Loss

At P40, a few glomeruli in mutant kidneys were subtly abnormal by conventional histological criteria: they contained restricted segments of thickened Bowman's capsule (crescents) and/or patches of thickened, closed capillary loops (segmental glomerulosclerosis). Both the number of glomeruli affected and the severity of the defects increased during the subsequent 4-6 wk. During the same period, some tubules atrophied and others dilated, cells and extracellular matrix accumulated in interstitial spaces between tubules, and many tubules and glomerular capillaries became filled with hyalin deposits (Figs. 2, *g-j*, and 6, *a* and *b*). By P65, mutant kidneys displayed many signs of chronic glomerulonephritis (Kashtan and Michael, 1993; Kashtan et al., 1994).

Although several distinct human glomerulonephritides are similar by light microscopic criteria, glomeruli in Alport syndrome display a distinctive ultrastructural sign: the presence of a thickened, filamentous BL, which has been referred to as a "basket weave" (Kashtan and Michael, 1993; Kashtan et al., 1994). Numerous segments of glomerular BL in *Col4a3* mutant mice displayed a basket-weave appearance by P60 (Fig. 7). Although its etiology is not understood, this ultrastructural alteration provides strong evidence that the structural consequences of collagen  $\alpha 3-5(IV)$  deficiency are similar in mice and humans.

The sclerotic glomeruli and expanded tubulointerstitial spaces that appeared in the mutant contained increased levels of several matrix proteins. Glomeruli accumulated collagen  $\alpha 1/2(IV)$ , laminins  $\beta 1$ ,  $\beta 2$ , and  $\gamma 1$ , entactin, and perlecan. Expanded interstitial spaces accumulated collagen V and tenascin, which were sparse in normal kidney (Kashtan and Kim, 1992; Truong et al., 1994), as well as collagens I and VI and fibronectin, which were present in both control and mutant interstitia (Fig. 6, *a-d*, and Table I). Consistent with the expansion of the collagen  $\alpha 1(IV)$ -rich matrix, the abundance of collagen  $\alpha 1(IV)$  RNA increased severalfold in mutant kidney between  $\sim$ P40 and P99 (Fig. 5 *b*). On the other hand, no significant changes in the composition of mutant BL in nonsclerotic glomeruli were detected by immunohistochemistry between P15 and the time that renal disease became severe (Table I).

A surprising observation was the accumulation of two membrane-associated adhesive proteins, N-CAM and integrin  $\alpha 6$ , in the mutant renal cortex. N-CAM was confined to Bowman's capsule in normal kidney, as reported



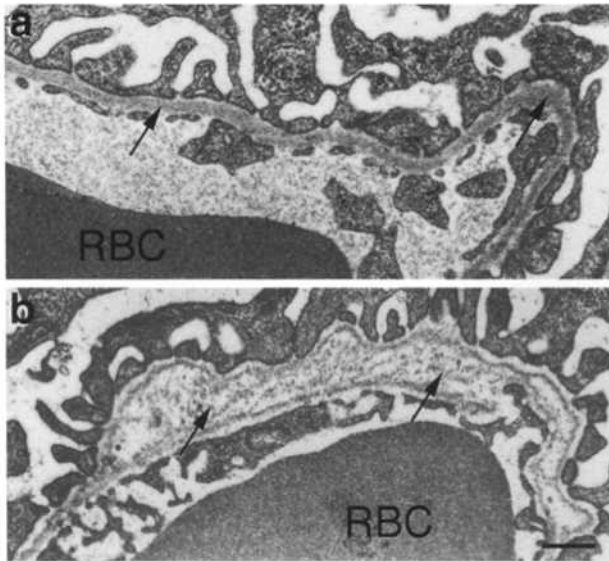
**Figure 6.** Histological analysis of kidneys in mutants (*right*) and littermate controls (*left*) at stages when renal pathology is evident. (*a-h*) P60–80 sections were stained with antibodies to entactin (*a* and *b*), tenascin (*c* and *d*), N-CAM (*e* and *f*), or integrin  $\alpha 6$  (*g* and *h*). Matrix in sclerotic glomeruli is entactin-positive. Cellular crescent in *f* (*arrows*) is N-CAM-positive. Interstitial deposits between tubules contain tenascin-, N-CAM-, and integrin  $\alpha 6$ -positive components. Integrin  $\alpha 6$  is also abundant on the basal surfaces of a subset of tubules. (*i*) P30 section from a mutant, stained for N-CAM. N-CAM is present in early glomerular crescents (*arrowheads*) even when most glomeruli appear normal. Thus, it serves as a sensitive indicator of early glomerular pathology. *G*, glomerulus; *I*, interstitium. Bar, 50  $\mu\text{m}$ .

previously (Klein et al., 1988), but was enriched in the cellular crescents that formed during the initial stage of glomerulonephritis (Fig. 6, *e* and *f*). The presence of N-CAM on these cells, along with their localization, suggests that they were derived from the parietal epithelial cells that comprise Bowman's capsule. Moreover, the paucity of N-CAM in normal kidney and its expression in crescents provided a useful marker for the relatively rare abnormal glomeruli at early stages (Fig. 6 *i*). Integrin  $\alpha 6$  was present at low levels on the basal side of all tubules in control kidney (Korhonen et al., 1990; Patey et al., 1994) but accumulated to high levels on the basolateral membranes of some tubules in the mutant (Fig. 6, *g* and *h*). Perhaps physiological changes that lead to or accompany tubular alterations in chronic nephritis cause up-regulation of this integrin

subunit. Finally, some of the cells in the interstitial spaces in the mutant kidneys were labeled by antibodies to integrin  $\alpha 6$  and N-CAM (Fig. 6, *e-h*). Double-labeling experiments revealed that the integrin  $\alpha 6$ - and N-CAM-positive interstitial cells were distinct (data not shown), suggesting the accumulation of at least two different populations of cells in the interstitium.

#### **Extrarenal Consequences of Collagen $\alpha 3$ -5(IV) Loss**

Collagen  $\alpha 3$ (IV) is present in several nonrenal BLs, including those of cochlea, testis, lung, and skeletal neuromuscular junction. Immunohistochemical analyses of some of these tissues revealed two distinct patterns of collagen IV chain accumulation in the *Col4a3* mutant. First, alveo-

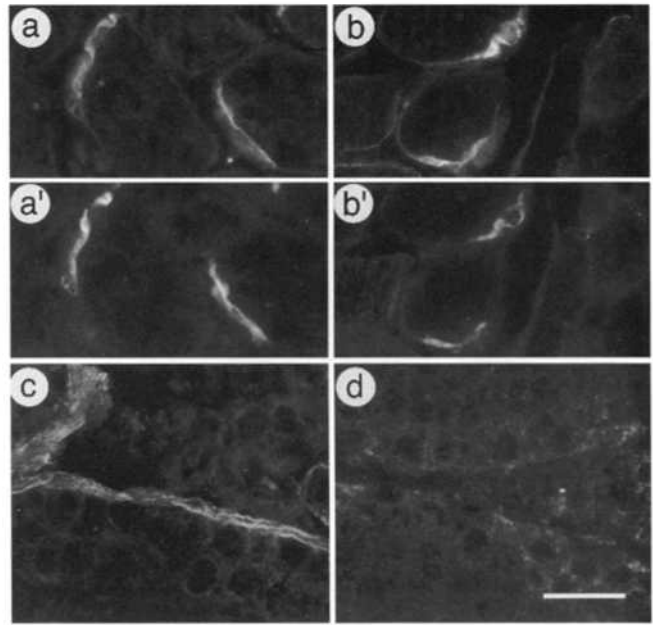


**Figure 7.** Electron micrographs of glomerular BL in P66 control (a) and mutant (b) kidneys. The basket-weaving that characterizes glomerular BL in humans with Alport syndrome is apparent in the mutant. Arrows indicate glomerular BL. RBC, red blood cell. Bar, 0.5  $\mu\text{m}$ .

lar BL in lung and seminiferous tubular BL in testis resemble tubular BL in kidney in that they normally contain  $\alpha 1,2(\text{IV})$  as well as  $\alpha 3-5(\text{IV})$  chains (Gunwar et al., 1991; Enders et al., 1995). The  $\alpha 3-5(\text{IV})$  chains were all absent from these tissues in the mutant, but the  $\alpha 1,2(\text{IV})$  chains persisted (Fig. 8, c and d, and data not shown). Thus, in these tissues, as in kidney, assembly or maintenance of the  $\alpha 4$  and  $\alpha 5(\text{IV})$  chains in BLs is dependent on the presence of intact  $\alpha 3(\text{IV})$  chain, consistent with the idea that they occur in the same collagen IV network. Second, the BL of the neuromuscular junction in wild-type skeletal muscle resembles renal glomerular BL in that it contains the  $\alpha 3-5(\text{IV})$  chains, but not  $\alpha 1,2(\text{IV})$  (Sanes et al., 1990; Miner and Sanes, 1994). No  $\alpha 3(\text{IV})$  was detectable at mutant synapses (data not shown), but  $\alpha 5(\text{IV})$  persisted at these sites (Fig. 8, a and b). Thus, loss of  $\alpha 3(\text{IV})$  does not inevitably lead to loss of  $\alpha 5(\text{IV})$ , perhaps because they are present in distinct collagen IV networks in some tissues. (Because antisera to  $\alpha 4(\text{IV})$  reacted poorly with mouse synapses, we could not assess the distribution of this chain.)

No alterations in gross structure were detected in extrarenal tissues by conventional histological methods, nor were their functions detectably impaired. Matings of *Col4a3* mutant homozygous males and females to wild-type mice or to each other gave rise to litters of normal size. We observed no impairment of pulmonary function in *Col4a3* mutants, despite the abundance of collagen  $\alpha 3-5(\text{IV})$  RNA and protein in normal lung (Gunwar et al., 1991; Miner and Sanes, 1994). Initial ultrastructural and immunohistochemical analyses of neuromuscular junctions (see Noakes et al., 1995a, for methods) revealed no abnormalities; electrophysiological studies to seek subtle defects are in progress.

Finally, since sensorineural deafness frequently accompanies Alport syndrome (Kashtan et al., 1994; Wester et al., 1995), we examined auditory function by recording auditory brainstem responses to clicks and tone pips (Colvin



**Figure 8.** Distribution of collagen IV chains in extrarenal tissues of the collagen  $\alpha 3(\text{IV})$  mutant mouse (b and d) and littermate controls (a and c). Sections from muscle (a and b) were stained with antiserum to collagen  $\alpha 5(\text{IV})$ , and sections from testes (c and d) were stained with anticollagen  $\alpha 4(\text{IV})$ . The sections from muscle were counterstained with a lectin (VVA) that marks synaptic sites (a' and b'). Collagen  $\alpha 5(\text{IV})$  is absent from mutant testes (not shown) but persists at mutant neuromuscular junctions. Bar, 25  $\mu\text{m}$ .

et al., 1996) from homozygotes and littermate controls. In 3 of 12 pairs of mice studied, auditory thresholds were significantly higher in the mutant than in the control. For the other nine mutants, however, thresholds and sensitivities were within the normal range. Importantly, auditory sensitivity was normal in mutants studied at P89 and P96, when renal pathology was already severe (Bohne, B.A., G.W. Harding, J.H. Miner, and J.R. Sanes, unpublished observations). These results suggest that cochlear manifestations of collagen  $\alpha 3(\text{IV})$  loss might depend on strain-dependent modifier genes, as has been observed for several heritable forms of deafness in mice and humans (Li and Borg, 1991). We are now testing this possibility by backcrossing the *Col4a3* mutant allele into various inbred backgrounds.

## Discussion

Mutation of the *Col4a3* gene in mice led to delayed-onset, progressive renal disease that includes decreased glomerular filtration (resulting in uremia) and increased glomerular permeability (resulting in proteinuria). By light microscopic criteria, the kidneys displayed glomerulosclerosis, tubular atrophy, and accumulation of interstitial cells and extracellular matrix. Electron microscopy revealed a characteristic basket-weave thickening and lamellation of the glomerular BL. In all of these respects, *Col4a3* mutant mice resemble humans with Alport syndrome (Barker et al., 1990; Kashtan and Michael, 1993; Kashtan et al., 1994; Lemmink et al., 1994; Mochizuki et al., 1994; Antignac, 1995; Kawai et al., 1996; Tryggvason, 1996).



The *Col4a3* mutant has permitted us to seek molecular changes that precede, and might therefore contribute to, renal pathology. We found that loss of collagen  $\alpha3(\text{IV})$  led to several changes in the composition of glomerular BL, some of which were apparent by P15, weeks before histological or physiological changes were observed. These include absence of collagens  $\alpha4(\text{IV})$  and  $\alpha5(\text{IV})$  and increased levels of collagens  $\alpha1,2(\text{IV})$ , fibronectin, perlecan, and collagen VI. Some of these alterations have been noted previously in human Alport syndrome (Kleppel et al., 1987; Kashtan and Kim, 1992; Gubler et al., 1995), but it has not been clear whether their appearance preceded clinical manifestations of disease. Our observation that the molecular composition of glomerular BL is altered in numerous ways before renal function is detectably impaired raises the possibility that these changes, as well as loss of collagen  $\alpha3-5(\text{IV})$  per se, contribute to renal failure in Alport syndrome.

The first histological abnormality observed was the appearance of glomerular crescents, visible in a small percentage of glomeruli by P30. Such crescents are not common in Alport syndrome but have been described repeatedly (see Gregory and Atkins, 1993 for references). N-CAM, which is normally confined to Bowman's capsule in adult kidney (Klein et al., 1988), was present on the cells that formed the crescents, consistent with their apparent derivation from the parietal epithelium of Bowman's capsule. Thus, N-CAM may serve as a useful early marker of compromised glomeruli.

Starting at around P60, levels of serum creatinine and blood urea nitrogen began to increase. These changes signaled a critical decrease in glomerular filtration, which became progressively more severe, culminating in renal failure and death. Histologically, glomerular BL acquired a basket-weave appearance, glomeruli became sclerotic, and the N-CAM-positive crescentic cells were replaced by deposits of matrix. The occlusion of Bowman's space and of glomerular capillaries and the fragmentation of glomerular BL are presumably the proximate causes of reduced filtration rate and selectivity, respectively. Tubular involvement was also apparent in late stages of the disease. Many tubules atrophied, while others became dilated with protein deposits. Integrin  $\alpha6$  levels increased markedly in a subset of tubules. Interstitial spaces between tubules expanded and became filled with cells and extracellular matrix. In human Alport syndrome, interstitial fibrosis predominates, but cellular accumulation has also been described (Kashtan et al., 1994).

This sequence of events leads to a speculative model of how the *Col4a3* mutation leads to renal disease. We propose that in glomerular BL, the absence of full-length collagen  $\alpha3(\text{IV})$  prevents the assembly of the collagen  $\alpha4$  and  $\alpha5(\text{IV})$  chains into a collagen IV network, leading to the degradation of these chains (Prockop, 1992). The collagen  $\alpha1,2(\text{IV})$  network that appears during glomerular development remains as part of the mature glomerular BL, thereby compensating structurally for loss of  $\alpha3-5(\text{IV})$ . However, fundamental differences between collagen  $\alpha1,2(\text{IV})$  and  $\alpha3-5(\text{IV})$  networks lead to accumulation of supranormal levels of perlecan and ectopic fibronectin and collagen VI in the glomerular BL. The changed BL composition results in glomerulopathy. The tubular involvement we observed

may be a nonspecific response to chronic glomerular disease or may result from the lack of the collagen  $\alpha3-5(\text{IV})$  chains in the subset of proximal and distal tubular BLs, where they are normally found. Another possibility, suggested by the accumulation of cells in the interstitium, is that an immune response might contribute to progression of the disease.

The glomerular structure and function in the *Col4a3* mutant contrast greatly with those in a mutant that lacks another major component of glomerular BL, laminin  $\beta2$  (Noakes et al., 1995a,b). Perinatally, glomerular BL undergoes a developmental transition from a preponderance of laminin  $\beta1$  and collagen  $\alpha1/2(\text{IV})$  to a preponderance of laminin  $\beta2$  and collagen  $\alpha3-5(\text{IV})$  (Miner and Sanes, 1994). In the *Col4a3* mutant, the  $\alpha1$  and  $\alpha2$  chains compensated for the loss of  $\alpha3-5(\text{IV})$ , but the laminin  $\beta1-\beta2$  transition clearly occurred. We showed previously that laminin  $\beta1$  levels remain high in the glomerular BL of laminin  $\beta2$  mutants but that the transition in collagen IV chains occurs on schedule (Noakes et al., 1995b). Together, these results demonstrate that the isoform composition of the two major macromolecular networks of the BL, the collagens IV and the laminins, are regulated independently. Moreover, the mutant phenotypes are extremely different. The laminin  $\beta2$  mutant exhibits massive proteinuria at 1–2 wk of age, but this occurs in the absence of severe histological change in the kidney. This pattern of impaired function with minimally altered structure is reminiscent of minimal change nephrotic syndrome in humans (Olson, 1992). In contrast, the *Col4a3* mutant exhibits delayed-onset renal disease characterized by glomerular structural abnormalities and interstitial fibrosis; this is strikingly similar to the pathology of human Alport syndrome.

The distinct phenotypes of laminin and collagen IV mutations indicate that these molecules play distinct roles in the glomerulus. We suggest that laminin  $\beta2$  is a signaling molecule that influences the maturation or maintenance of the podocyte. In its absence, podocyte differentiation is impaired, and the glomerular filtration barrier does not mature properly. In contrast, the collagen  $\alpha3-5(\text{IV})$  chains appear to be important for the structural integrity of the mature glomerular BL. Thus, loss of the collagen chains leads to a significant change in the molecular architecture and to the eventual breakdown of the glomerular BL.

There is, however, an alternative view of both mutant phenotypes: perhaps it is neither the absence of the normal adult isoform nor the persistence of the fetal isoform that leads to renal dysfunction, but rather the generation of an incompatible "mismatch" between laminins and collagens IV. Thus, in the laminin  $\beta2$  mutant, a fetal  $\beta1$ -containing laminin network is associated with the normal adult collagen  $\alpha3-5(\text{IV})$  network, whereas in the collagen  $\alpha3(\text{IV})$  mutant, a fetal collagen  $\alpha1/2(\text{IV})$  network coexists with the normal  $\beta2$ -containing laminin network. If such incompatibility leads to disease, we would expect that double mutants lacking both laminin  $\beta2$  and collagen  $\alpha3(\text{IV})$ , which would have a fully fetal (laminin  $\beta1-$  and collagen  $\alpha1/2(\text{IV})$ -containing) glomerular BL, might have a less severe phenotype than either single mutant. In contrast, if laminin  $\beta2$  and the collagen  $\alpha3-5(\text{IV})$  chains play distinct roles, then the double mutants would exhibit a more se-

vere phenotype than the single mutants. We are currently testing these ideas.

We thank M. Nichol and J. Mudd for generation of chimeras; M. Nichol for superb management of the animal facility; J. Cunningham, M. Elam, B. Klocke, S. King, and J. Merlie Jr. for assistance; A. Nagy for R1 ES cells; Drs. D. Abrahamson, A. Chung, R. Hynes, S. Kaufman, K. Kimata, M. Schachner, M. Yamagata, A. Pearlman, and S. Santoro, for antibodies; S. Gluck for comments on the manuscript; and the late J.P. Merlie for valuable advice during the early stages of this work.

This work was supported by grants from the National Institutes of Health and the Muscular Dystrophy Association to J.R. Sanes. J.H. Miner was supported by a Damon Runyon-Walter Winchell Cancer Research Fund Fellowship.

Received for publication 8 August 1996 and in revised form 17 September 1996.

## References

Abrahamson, D.R., M.H. Irwin, P.L. St. John, E.W. Perry, M.A. Accavitti, L.W. Heck, and J.R. Couchman. 1989. Selective immunoreactivities of kidney basement membranes to monoclonal antibodies against laminin: localization of the end of the long arm and the short arms to discrete microdomains. *J. Cell Biol.* 109:3477-3491.

Antignac, C. 1995. Molecular genetics of basement membranes: the paradigm of Alport syndrome. *Kidney Int.* 47(Suppl. 49):S29-S33.

Barker, D.F., S.L. Hostikka, J. Zhou, L.T. Chow, A.R. Oliphant, S.C. Gerken, M.C. Gregory, M.H. Skolnick, C.L. Atkin, and K. Tryggvason. 1990. Identification of mutations in the COL4A5 collagen gene in Alport syndrome. *Science (Wash. DC)*. 248:1224-1227.

Bender, B.L., R. Jaffe, B. Carlin, and A.E. Chung. 1981. Immunolocalization of entactin, a sulfated basement membrane component, in rodent tissues, and comparison with GP-2 (laminin). *Am. J. Pathol.* 103:419-426.

Carlson, J.A., and J.T. Harrington. 1993. Laboratory evaluation of renal function. In *Diseases of the Kidney*. R.W. Schrier and C.W. Gottschalk, editors. Little, Brown and Company, Boston. 383-389.

Colvin, J.S., B.A. Bohne, G.W. Harding, D.G. McEwen, and D.M. Ornitz. 1996. Skeletal overgrowth and deafness in mice lacking fibroblast growth factor receptor 3. *Nat. Genet.* 12:390-397.

Couchman, J.R., D.R. Abrahamson, and K.J. McCarthy. 1993. Basement membrane proteoglycans and development. *Kidney Int.* 43:79-84.

DePersio, C.M., S. Shah, and R.O. Hynes. 1995.  $\alpha 3\beta 1$  integrin localizes to focal contacts in response to diverse extracellular matrix proteins. *J. Cell Sci.* 108:2321-2336.

Durbeej, M., E. Larsson, O. Ibragimov-Beskrovnyaya, S.L. Roberds, K.P. Campbell, and P. Ekblom. 1995. Non-muscle  $\alpha$ -dystroglycan is involved in epithelial development. *J. Cell Biol.* 130:79-91.

Enders, G.C., T.Z. Kahsai, G. Lian, K. Funabiki, P.D. Killen, and B.G. Hudson. 1995. Developmental changes in seminiferous tubule extracellular matrix components of the mouse testis: alpha 3(IV) collagen chain expressed at the initiation of spermatogenesis. *Biol. Reprod.* 53:1489-1499.

Gatchalian, C.L., M. Schachner, and J.R. Sanes. 1989. Fibroblasts that proliferate near denervated synaptic sites in skeletal muscle synthesize the adhesive molecules tenascin(J1), N-CAM, fibronectin, and a heparan sulfate proteoglycan. *J. Cell Biol.* 108:1873-1890.

Gregory, M.C., and C.L. Atkin. 1993. Alport syndrome. In *Diseases of the Kidney*. R.W. Schrier and C.W. Gottschalk, editors. Little, Brown and Company, Boston. 571-591.

Gubler, M.-C., B. Knebelmann, A. Beziau, M. Broyer, Y. Pirson, F. Haddoum, M.M. Kleppel, and C. Antignac. 1995. Autosomal recessive Alport syndrome: immunohistochemical study of type IV collagen chain distribution. *Kidney Int.* 47:1142-1147.

Gunwar, S., P.A. Bejarano, R. Kalluri, J.P.M. Langeveld, B.J. Wisdom, Jr., M.E. Noelken, and B.G. Hudson. 1991. Alveolar basement membrane: molecular properties of the noncollagenous domain (hexamer) of collagen IV and its reactivity with Goodpasture autoantibodies. *Am. J. Respir. Cell Mol. Biol.* 5:107-112.

Guo, X., J.J. Johnson, and J.M. Kramer. 1991. Embryonic lethality caused by mutations in basement membrane collagen of *C. elegans*. *Nature (Lond.)*. 349:707-709.

Hostikka, S.L., R.L. Eddy, M.G. Byers, M. Hoyhtya, T.B. Shows, and K. Tryggvason. 1990. Identification of a distinct type IV collagen  $\alpha$  chain with restricted kidney distribution and assignment of its gene to the locus of X chromosome-linked Alport syndrome. *Proc. Natl. Acad. Sci. USA*. 87:1606-1610.

Hudson, B.G., S.T. Reeders, and K. Tryggvason. 1993. Type IV collagen: structure, gene organization, and role in human diseases. *J. Biol. Chem.* 268:26033-26036.

Kashtan, C.E., and Y. Kim. 1992. Abnormal distribution of the  $\alpha 1$  and  $\alpha 2$  chains of collagen IV and of collagens V and VI in glomeruli of patients with Alport syndrome. *Kidney Int.* 42:115-126.

Kashtan, C.E., and A.F. Michael. 1993. Alport syndrome: from bedside to genome to bedside. *Am. J. Kidney Dis.* 22:627-640.

Kashtan, C.E., R.K. Sibley, A.F. Michael, and R.L. Vernier. 1994. Hereditary nephritis: alport syndrome and thin glomerular basement membrane disease. In *Renal Pathology: With Clinical and Functional Correlations*. C.C. Tisher and B.M. Brenner, editors. J.B. Lippincott Company, Philadelphia. 1239-1266.

Kato, M., Y. Koike, S. Suzuki, and K. Kimata. 1988. Basement membrane proteoglycan in various tissues: characterization using monoclonal antibodies to the Engelbreth-Holm-Swarm mouse tumor low density heparan sulfate proteoglycan. *J. Cell Biol.* 106:2203-2210.

Kawai, S., S. Nomura, T. Harano, K. Harano, T. Fukushima, G. Osawa, and the Japanese Alport Network. 1996. The COL4A5 gene in Japanese Alport syndrome patients: spectrum of mutations of all exons. *Kidney Int.* 49:814-822.

Klein, G., M. Langegger, C. Goridis, and P. Ekblom. 1988. Neural cell adhesion molecules during embryonic induction and development of the kidney. *Development (Camb.)*. 102:749-761.

Kleppel, M.M., C.E. Kashtan, R.J. Butkowski, A.J. Fish, and A.F. Michael. 1987. Alport familial nephritis: absence of 28 kilodalton non-collagenous monomers of type IV collagen in glomerular basement membrane. *J. Clin. Invest.* 80:263-266.

Korhonen, M., J. Ylanne, L. Laitinen, and I. Virtanen. 1990. The  $\alpha 1$ - $\alpha 6$  subunits of integrins are characteristically expressed in distinct segments of developing and adult human nephron. *J. Cell Biol.* 111:1245-1254.

Kuhn, K. 1994. Basement membrane (type IV) collagen. *Matrix Biol.* 14:439-445.

Laitinen, L., T. Vartio, and I. Virtanen. 1991. Cellular fibronectins are differentially expressed in human fetal and adult kidney. *Lab. Invest.* 64:492-498.

Lemmink, H.H., T. Mochizuki, P.W.J. van den Heuvel, C.H. Schroder, A. Barrientos, L.A.H. Monnens, B.A. van Oost, H.G. Brunner, S.T. Reeders, and H.J.M. Smeets. 1994. Mutations in the type IV collagen  $\alpha 3$  (COL4A3) gene in autosomal recessive Alport syndrome. *Hum. Mol. Genet.* 3:1269-1273.

Li, H.-S., and E. Borg. 1991. Age-related loss of auditory sensitivity in two mouse genotypes. *Acta Otolaryngol.* 111:827-834.

Martin, P.T., S.J. Kaufman, R.H. Kramer, and J.R. Sanes. 1996. Synaptic integrins in developing, adult, and mutant muscle: selective association of  $\alpha 1$ ,  $\alpha 7A$ , and  $\alpha 7B$  integrins with the neuromuscular junction. *Dev. Biol.* 174:125-139.

Miner, J.H., and J.R. Sanes. 1994. Collagen IV  $\alpha 3$ ,  $\alpha 4$ , and  $\alpha 5$  chains in rodent basal laminae: sequence, distribution, association with laminins, and developmental switches. *J. Cell Biol.* 127:879-891.

Miner, J.H., R.M. Lewis, and J.R. Sanes. 1995. Molecular cloning of a novel laminin chain,  $\alpha 5$ , and widespread expression in adult mouse tissues. *J. Biol. Chem.* 270:28523-28526.

Mochizuki, T., H.H. Lemmink, M. Mariyama, C. Antignac, M.-C. Gubler, Y. Pirson, C. Verellen-Dumoulin, B. Chan, C.H. Schroder, H.J. Smeets, and S.T. Reeders. 1994. Identification of mutations in the  $\alpha 3(IV)$  and  $\alpha 4(IV)$  collagen genes in autosomal recessive Alport syndrome. *Nat. Genet.* 8:77-82.

Nagy, A., J. Rossant, R. Nagy, W. Abramow-Newerly, and J.C. Roder. 1993. Derivation of completely cell culture-derived mice from early-passage embryonic stem cells. *Proc. Natl. Acad. Sci. USA*. 90:8424-8428.

Ninomiya, Y., M. Kagawa, K. Iyama, I. Naito, Y. Kishiro, J.M. Seyer, M. Sugimoto, T. Oohashi, and Y. Sado. 1995. Differential expression of two basement membrane collagen genes, COL4A6 and COL4A5, demonstrated by immunofluorescence staining using peptide-specific monoclonal antibodies. *J. Cell Biol.* 130:1219-1229.

Noakes, P.G., M. Gautam, J. Mudd, J.R. Sanes, and J.P. Merlie. 1995a. Aberrant differentiation of neuromuscular junctions in mice lacking s-laminin/laminin  $\beta 2$ . *Nature (Lond.)*. 374:258-262.

Noakes, P.G., J.H. Miner, M. Gautam, J.M. Cunningham, J.R. Sanes, and J.P. Merlie. 1995b. The renal glomerulus of mice lacking s-laminin/laminin  $\beta 2$ : nephrosis despite molecular compensation by laminin  $\beta 1$ . *Nat. Genet.* 10:400-406.

Olson, J.L. 1992. The nephrotic syndrome. In *Pathology of the Kidney*. R.H. Heptinstall, editor. Little, Brown and Company, Boston. 779-869.

Patey, N., L. Halbwachs-Mecarelli, D. Droz, P. Lesavre, and L.H. Noel. 1994. Distribution of integrin subunits in normal human kidney. *Cell Adhesion Commun.* 2:159-167.

Prockop, D.J. 1992. Mutations in collagen genes as a cause of connective-tissue diseases. *N. Engl. J. Med.* 326:540-546.

Ries, A., J. Engel, A. Lustig, and K. Kuhn. 1995. The function of the NC1 domains in type IV collagen. *J. Biol. Chem.* 270:23790-23794.

Sanes, J.R., E. Engvall, R. Butkowski, and D.D. Hunter. 1990. Molecular heterogeneity of basal laminae: isoforms of laminin and collagen IV at the neuromuscular junction and elsewhere. *J. Cell Biol.* 111:1685-1699.

Sibley, M.H., P.L. Graham, N. von Mende, and J.M. Kramer. 1994. Mutations in the  $\alpha 2(IV)$  basement membrane collagen gene of *Caenorhabditis elegans* produce phenotypes of differing severities. *EMBO (Eur. Mol. Biol. Organ.) J.* 13:3278-3285.

Truong, L.D., J. Pindur, R. Barrios, V. D'Agati, J. Lechago, W. Suki, and M. Majesky. 1994. Tenascin is an important component of the glomerular extracellular matrix in normal and pathologic conditions. *Kidney Int.* 45:201-210.

Tryggvason, K. 1996. Mutations in type IV collagen genes and Alport phenotypes. *Contrib. Nephrol.* 117:154-171.

Tybulewicz, V.L., C.E. Crawford, P.K. Jackson, R.T. Bronson, and R.C. Mulligan. 1991. Neonatal lethality and lymphopenia in mice with a homozygous

- disruption of the c-abl proto-oncogene. *Cell*. 65:1153-1163.
- Wester, D.C., C.L. Atkin, and M.C. Gregory. 1995. Alport syndrome: clinical update. *J. Am. Acad. Audiol.* 6:73-79.
- Wu, J.E., and S.A. Santoro. 1994. Complex patterns of expression suggest extensive roles for the alpha 2 beta 1 integrin in murine development. *Dev. Dynam.* 199:292-314.
- Yager, H.M., and J.T. Harrington. 1995. Evaluation of serum electrolytes, creatinine, and blood urea nitrogen. In *The Principles and Practice of Nephrology*. H.R. Jacobson, G.E. Striker, and S. Klahr, editors. Mosby-Year Book, Inc., St. Louis. 85-89.
- Yurchenco, P.D., and J.J. O'Rear. 1994. Basal lamina assembly. *Curr. Opin. Cell Biol.* 6:674-681.
- Zheng, K., P.S. Thorne, P. Marrano, R. Bauman, and R.R. McInnes. 1994. Canine X chromosome-linked hereditary nephritis: a genetic model for human X-linked hereditary nephritis resulting from a single base mutation in the gene encoding the  $\alpha 5$  chain of collagen type IV. *Proc. Natl. Acad. Sci. USA*. 91:3989-3993.
- Zhou, J., and S.T. Reeder. 1996. The  $\alpha$  chains of type IV collagen. *Contrib. Nephrol.* 117:80-104.