



CASE REPORT

# Wilderness Cardiology: A Case of Envenomation-Associated Cardiotoxicity Following a Rattlesnake Bite

Justin Slade · Alexandru Baja · Ajlan Al Zaki · Paul Auerbach · Fatima Rodriguez

Received: January 7, 2021 / Accepted: February 10, 2021 / Published online: February 23, 2021  
© The Author(s) 2021

## ABSTRACT

Cardiac injury is infrequently described as a complication of snake bite envenomation. We present the case of a 62-year-old male with shortness of breath, right lower extremity edema, and elevated cardiac troponin 6 days after a Northern Pacific rattlesnake bite.

**Keywords:** Envenomation; Rattlesnake bite; Thrombocytopenia; Troponin elevation; Venom-induced cardiotoxicity

---

J. Slade (✉) · A. Al Zaki · F. Rodriguez  
Department of Medicine, Stanford University,  
Stanford, CA, USA  
e-mail: justin.j.slade@gmail.com

J. Slade  
Medical Service, VA Palo Alto Health Care System,  
Palo Alto, CA, USA

A. Baja  
Humanitas University, Milan, Italy

P. Auerbach  
Department of Emergency Medicine, Stanford  
University, Stanford, CA, USA

F. Rodriguez  
Division of Cardiovascular Medicine, Department of  
Medicine, Stanford University, Stanford, CA, USA

## Key Summary Points

Cardiovascular sequelae of Crotaline snake (including rattlesnake) envenomation include vascular disruption with microhemorrhage and potential compartment syndrome as well as direct cardiotoxicity that may provoke arrhythmia or myocardial inflammation.

Ovine Crotalidae – polyvalent immune fab (*CroFab*) and supportive care are the cornerstones of treatment following moderate-to-severe Crotalinae envenomation.

Recurrent Crotalidae venom toxicity can occur despite control of initial manifestations with *CroFab*, particularly in cases of severe envenomation.

## DIGITAL FEATURES

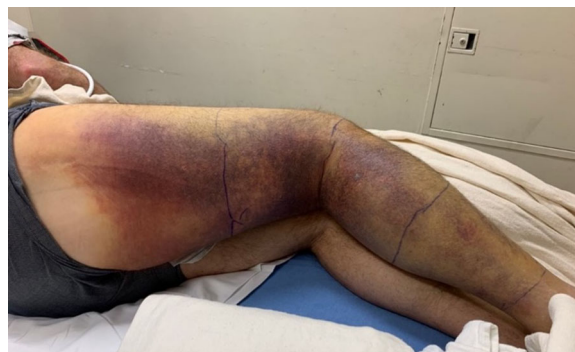This article is published with digital features, including a summary slide, to facilitate understanding of the article. To view digital features for this article go to <https://doi.org/10.6084/m9.figshare.13736740>.



**Fig. 1** Rattlesnake bite. Post-bite puncture wounds on the anterolateral right lower extremity

## HISTORY OF PRESENTATION

A 62-year-old male presented to a local hospital 1 h after sustaining a Northern Pacific rattlesnake bite to his right anterolateral shin while he was hiking in Marin County, California (Fig. 1). On arrival, he noted an onset of limb dysesthesia and perioral numbness, the latter of which resolved with administration of six vials of ovine *Crotalidae*-polyvalent immune fab (CroFab). Over the ensuing 24 h, he continued to experience dysesthesia as well as edema and ecchymosis surrounding the site of envenomation. Lower extremity ultrasonography revealed no evidence of deep vein thrombosis. He was observed a second night and discharged home after a total of 36 h with stable right lower extremity dysesthesia, edema, and ecchymosis. Four days later, he presented to the emergency department at our hospital with progressive dyspnea on exertion, lightheadedness, and worsening right lower extremity pain and edema. He was afebrile with a heart rate of 78 beats per minute and blood pressure of 145/68 mmHg. On physical examination, he was in no apparent respiratory distress on room air yet exhibited marked right lower extremity edema with ecchymosis and associated tenderness to palpation extending from the proximal thigh to the foot (Fig. 2). Range of motion of his knee and ankle was limited by edema, sensation



**Fig. 2** Right lower extremity on presentation. The extensive edema and ecchymosis present highlight the tremendous vascular injury inducible from *Crotaline* envenomation

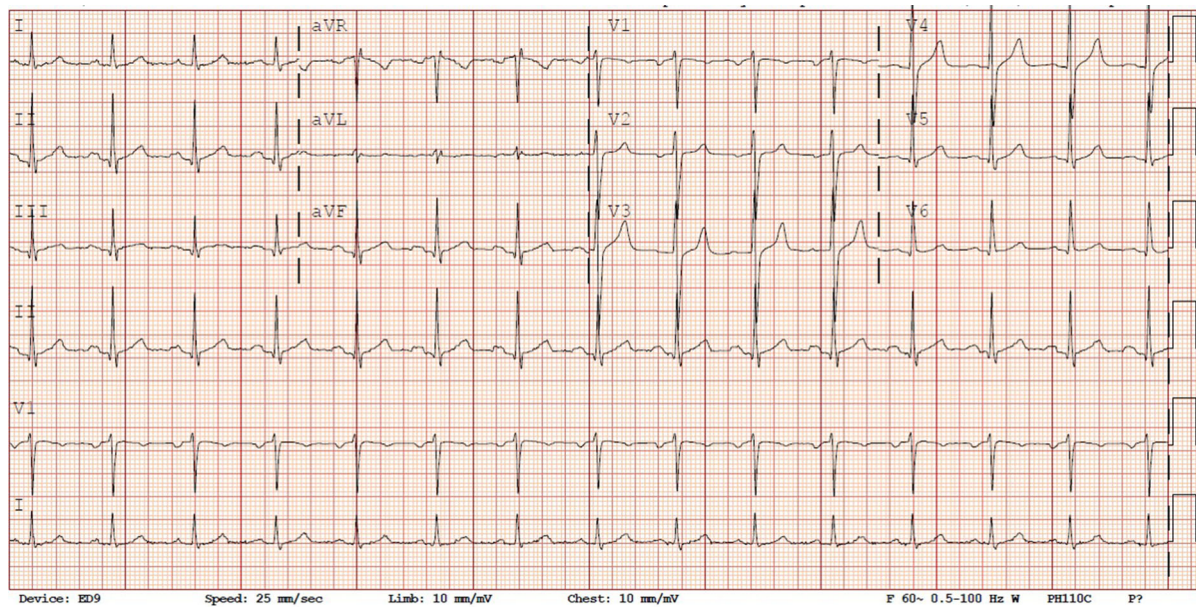
was intact, and his dorsalis pedis pulses were palpable. He denied chest pain but noted intermittent palpitations. Electrocardiogram revealed normal sinus rhythm with no ST segment changes (Fig. 3), though a high burden of premature ventricular contractions (PVCs) in a bigeminy pattern was noted on cardiac monitor. His initial troponin I level was 0.21 ng/ml (reference < 0.055 ng/ml). He was subsequently admitted for cardiovascular monitoring due to concern for venom-induced cardiotoxicity.

## PAST MEDICAL HISTORY

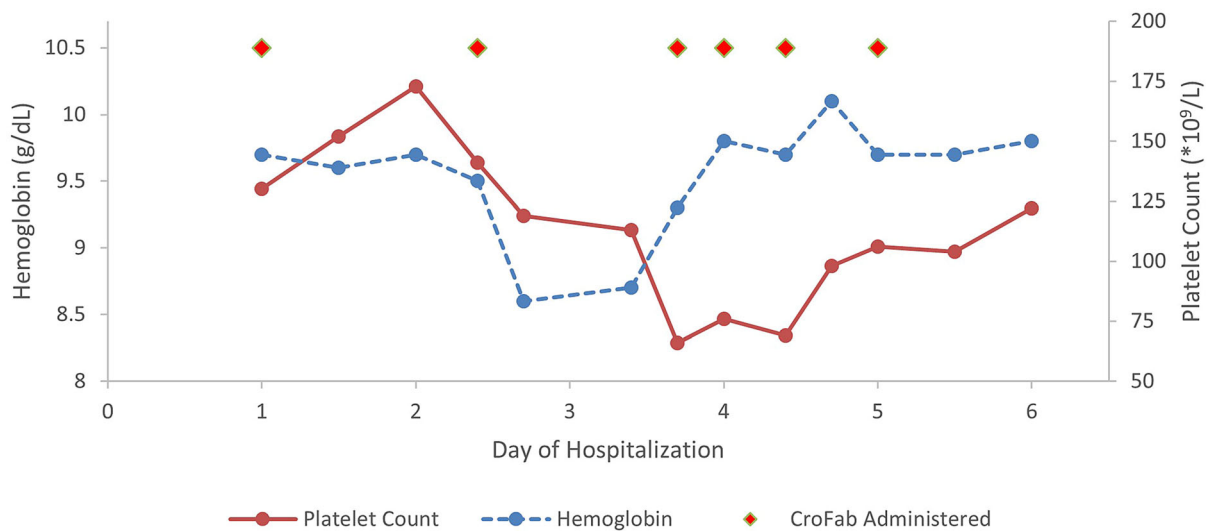
Hyperlipidemia, benign prostatic hyperplasia, and atrial flutter for which he underwent successful radiofrequency catheter ablation in 2015.

## DIFFERENTIAL DIAGNOSIS

Pulmonary embolism, acute coronary syndrome, cardiac toxicity secondary to *Crotalinae* (a family including rattlesnake, cottonmouth, and copperhead snakes) envenomation, and demand ischemia secondary to anemia from hemolysis or bleeding diathesis. Compartment syndrome was an additional consideration due to his right lower extremity symptoms.



**Fig. 3** Admission electrocardiogram. Showing sinus rhythm and no ischemic changes



**Fig. 4** Hemoglobin and platelet count trend over hospital course. These trends are reflective of the potential for prolonged microvascular hemorrhage and platelet consumption secondary to venom toxicity and the need for

continuous assessment and CroFab administration as needed

## INVESTIGATIONS

Serial complete blood counts (CBCs) were remarkable for anemia and thrombocytopenia (Fig. 4). A comprehensive metabolic panel, peripheral smear, lactate dehydrogenase,

haptoglobin, peripheral smear, direct Coombs test, international normalized ratio (INR), partial thromboplastin time (PTT), and fibrinogen were within normal limits. His troponin I peaked at 0.23 ng/ml and remained persistently elevated in this range throughout the

**Table 1** Troponin I and coagulation lab trends over hospitalization

	Reference range	Day 1	Day 3	Day 5
Troponin I (ng/ml)	< 0.055	0.223	0.184	0.199
D-Dimer (µg/ml FEU)	< 0.50	2.72		
Fibrinogen (mg/dl)	234–395	452	369	384
Prothrombin time (s)	11.5–14.7	14.1	13.3	13.7
INR	0.9–1.2	1.1	1.1	1.1

FEU fibrin-equivalent units, INR international normalized ratio

hospitalization (Table 1). Creatine kinase was 498 U/l (reference range < 190 U/l) and creatine kinase-muscle/brain was 2.7 ng/ml (reference range < 10.4 ng/ml). Computed tomography pulmonary angiography was negative for pulmonary embolism. Transthoracic echocardiography noted normal biventricular function with no focal wall motion abnormality, mild mitral regurgitation, and moderate concentric left ventricular hypertrophy. Review of outpatient records noted a recent ambulatory cardiac monitor study for follow-up on his history of atrial flutter which revealed no PVCs or recurrent atrial arrhythmias.

## MANAGEMENT

In light of strong clinical suspicion that the patient's progressive symptoms as well as new hematologic and cardiovascular findings were sequelae of ongoing venom toxicity, six vials of CroFab were administered at the time of admission with close monitoring of CBC, INR, and fibrinogen every 6 h. Cardiac monitor surveillance was continued on admission and serial troponin measurements were taken. Surgical consultation was obtained for lower extremity evaluation, which included circumferential leg measurements, due to initial concern for compartment syndrome. On hospital day #2, he was transfused one unit of packed red blood cells as it was felt that his progressive dyspnea was secondary to acute anemia from microvascular hemorrhage into his right lower extremity. On hospital day #3, his

thrombocytopenia worsened. Subcutaneous heparin initially given for DVT prophylaxis was discontinued and a heparin-induced thrombocytopenia panel was checked and found to be negative. He received four additional vials of CroFab every 6 h (16 total vials) until platelet counts exceeded  $100 \times 10^9/l$  per American Association of Poison Control Centers guidelines [1].

## DISCUSSION

There are nearly 10,000 snakebite injuries treated annually in the United States, many of which are from venomous snakes [2]. The Northern Pacific rattlesnake (a pit viper subtype) is indigenous to the region extending from California to British Columbia and is responsible for 98% of venomous bites in the United States. Snakebite patients should be rapidly assessed for airway, breathing, and circulation compromise and transported to the nearest emergency department. Serial examination of involved tissue should occur every 15–30 min until effects have stabilized. Patients with systemic symptoms, abnormal laboratory findings, or progressive tissue insult should receive antivenom therapy under the guidance of a medical toxicologist or poison control center [3]. Toxicity from Crotalinae bites may cause coagulopathy with thrombosis or bleeding, thrombocytopenia, rhabdomyolysis, compartment syndrome, and cardiac manifestations [4]. The latter comprise arrhythmias, ischemia, and inflammation, most likely as part of an



inflammatory post-envenomation syndrome [5]. Troponin elevation in the context of snakebites is scarcely reported in the literature [6]. It is unknown if the cardiotoxic effects are caused by the venom itself, the resulting systemic inflammatory response, or a combination of both. Studies in horses have documented troponin and tumor necrosis factor  $\alpha$  elevations after rattlesnake bites [7], however life-threatening rhythm disturbances (ventricular tachycardia, atrial fibrillation) represent the more commonly observed complications in those with no history of cardiac disease [8]. Our patient exhibited a persistent mild elevation of troponin I throughout this hospitalization as well as a high burden of PVCs in the absence of electrolyte abnormalities and that had not been noted on a previous ambulatory cardiac monitor study, which is suggestive of cardiotoxicity from Crotalinae envenomation. Occurrence several days following the initial envenomation can be explained by residual venom release at the bite site following inoculation, venom–antivenom complex detachment upon initial neutralization with antivenom, or a host-dependent immune reaction against venom components [8]. A heterophile antibody was negative, ruling-out a false-positive result [10]. Our clinical laboratory also confirmed, by spiking sample serum specimens with various antivenom concentrations, that CroFab-antibodies were not interfering with our troponin I assay.

## FOLLOW-UP

Over the final 3 days of his hospitalization, the patient noted improvement in dyspnea, palpitations, and right lower extremity pain. On hospital day 6, his hemoglobin and platelet counts began to improve without requiring further administration of CroFab. He was discharged home with outpatient physical therapy and an ambulatory cardiac monitor, which revealed marked reduction in his PVC burden over the ensuing 2 weeks. He subsequently underwent an exercise stress echocardiogram, which revealed no evidence of inducible ischemia.

## CONCLUSIONS

Crotalinae envenomation is a serious, life-threatening event that can provoke hematologic derangements, extensive vascular damage, and impact a multitude of organs including the heart. This case highlights the importance of close cardiovascular monitoring due to the potential for adverse and incompletely understood cardiac and vascular sequelae of rattlesnake bites. There are no established guidelines for cardiovascular evaluation in the setting of rattlesnake envenomation. Based on our experience and review of the literature, we recommend initial evaluation with ECG, troponin I, and cardiac monitoring for patients presenting with symptoms concerning for cardiovascular manifestations such as chest pain, palpitations, or shortness of breath following rattlesnake envenomation. The participant provided consent for the publication of this article and the use of their images to be published as open access.

## ACKNOWLEDGEMENTS

We thank the patient described in this case report and those involved in his care throughout this clinical course.

**Funding.** No funding or sponsorship was received for this study or publication of this article.

**Authorship.** All named authors meet the International Committee of Medical Journal Editors (ICMJE) criteria for authorship for this article, take responsibility for the integrity of the work as a whole, and have given their approval for this version to be published.

**Disclosures.** Dr. Fatimah Rodriguez serves as an advisor to HealthPals and Carta and has received consulting fees from Novo Nordisk. Justin Slade, Alexandru Baja, Ajlan Al Zaki, and Paul Auerbach have nothing to disclose.

**Compliance with Ethics Guidelines.** The participant provided consent for the publication of this article and the use of their images to be published as open access.

**Data Availability.** Data sharing is not applicable to this article as no datasets were generated or analyzed during the current study.

**Open Access.** This article is licensed under a Creative Commons Attribution-NonCommercial 4.0 International License, which permits any non-commercial use, sharing, adaptation, distribution and reproduction in any medium or format, as long as you give appropriate credit to the original author(s) and the source, provide a link to the Creative Commons licence, and indicate if changes were made. The images or other third party material in this article are included in the article's Creative Commons licence, unless indicated otherwise in a credit line to the material. If material is not included in the article's Creative Commons licence and your intended use is not permitted by statutory regulation or exceeds the permitted use, you will need to obtain permission directly from the copyright holder. To view a copy of this licence, visit <http://creativecommons.org/licenses/by-nc/4.0/>.

## REFERENCES

1. Lavonas EJ, Ruha A-M, Banner W, et al. Unified treatment algorithm for the management of crotaline snakebite in the United States: results of an evidence-informed consensus workshop. *BMC Emerg Med.* 2011;11:2.
2. O'Neil ME, Mack KA, Gilchrist J, Wozniak EJ. Snakebite injuries treated in United States Emergency Departments, 2001–2004. *Wilderness Environ Med.* 2007;18:281–7.
3. Kanaan NC, Ray J, Stewart M, et al. Wilderness Medical Society practice guidelines for the treatment of pitviper envenomations in the United States and Canada. *Wilderness Environ Med.* 2015;26:472–87.
4. Walter F, Chase P, Fernandez M, McNally J. Venomous Snakes. In: Shannon M, Borron S, Burns M, editors. *Haddad and Winchester's clinical management of poisoning and drug overdose.* 4th ed. Philadelphia: Saunders/Elsevier; 2007. p. 399–420.
5. Gold BS, Dart RC, Barish RA. Bites of venomous snakes. *N Engl J Med.* 2002;347:347–56.
6. Silva A, Pilapitiya S, Siribaddana S. Acute myocardial infarction following a possible direct intravenous bite of Russell's viper (*Daboia russelli*). *BMC Res Notes.* 2012;5:500.
7. Gilliam LL, Holbrook TC, Ownby CL, et al. Cardiotoxicity, inflammation, and immune response after rattlesnake envenomation in the horse. *J Vet Intern Med.* 2012;26:1457–63.
8. Virmani S, Bhat R, Rao R, Kapur R, Dsouza S. Paroxysmal atrial fibrillation due to venomous snake bite. *JCDR.* 2017;11:OD01–2.
9. Seifert SA, Boyer LV. Recurrence phenomena after immunoglobulin therapy for snake envenomations: part 1. Pharmacokinetics and pharmacodynamics of immunoglobulin antivenoms and related antibodies. *Ann Emerg Med.* 2001;37:189–95.
10. Lum G, Solarz DE, Farney L. False positive cardiac troponin results in patients without acute myocardial infarction. *Lab Med.* 2006;37:546–50.