

## Nodular Fasciitis of the Breast

Mansour Moghimi,<sup>1</sup> Pouria Yazdian Anari,<sup>2,\*</sup> Marzie Vaghefi,<sup>2</sup> Abbas Meidany,<sup>2</sup> and Heidar Salehi<sup>2</sup>

<sup>1</sup>Department of Pathology, Shahid Sadoughi University of Medical Sciences, Yazd, Iran

<sup>2</sup>Medical Student Research Committee, Shahid Sadoughi University of Medical Sciences, Yazd, Iran

\*Corresponding author: Pouria Yazdian Anari, Medical Student Research Committee, Shahid Sadoughi University of Medical Sciences, Yazd, Iran. Tel: +98-3536230354; +98-9385101025, Fax: +98-3538113407, E-mail: Pouria\_yazdian\_a@yahoo.com

Received 2015 April 26; Revised 2015 July 25; Accepted 2015 September 20.

### Abstract

Nodular fasciitis of the breast is a rare benign pathology of soft tissue that is a consequence of fibroblastic hyperplasia within breast. It can mimic breast cancer clinically, radiologically, and histopathologically. A 43 year-old female with a painless mass within upper-lateral quadrant of her left breast complained of rapid and progressive growth during previous few days. No evidence of nipple discharge or sensation of pain was expressed. The mass was tender to palpation, but the size was too tiny to detect. The definitive diagnosis was established with sonography, which detected a hypoechoic lesion, 10 mm in diameter. The excisional biopsy delivered a tissue composed of fusiform fibroblastic cells with bright ellipsoid-like nuclei and elevated nucleolus. Mitotic formations were also obvious. Low cellular and high cellular zones with hyaline fibrosis and erythrocyte accumulation existed, as well as a light lymphocytic infiltration. All of these features, in addition to adipocytic accumulation within the margins of this lesion, suggested a definitive diagnosis of Nodular fasciitis. The diagnosis of nodular fasciitis is difficult and often is indiscriminable from breast cancer, so paying close attention to this matter is critical.

**Keywords:** Nodular Fasciitis, Ultrasonography, Pathology

### 1. Introduction

Nodular fasciitis is a benign lesion that develops due to proliferation of fibroblastic and myofibroblastic cells within subcutaneous tissue (1-3), commonly found in soft tissues (4). The lesion is seen more frequently in the upper limbs and trunk of young to middle-aged individuals, so development in the breast area is rare (4). The definitive etiology of this lesion is unclear (4-6), but it develops within the breasts of females aged 36 to 48 (1-3). This tumor-like lesion consists of myofibroblastic cells, which are seeded through a mucopolysaccharide stroma in a circular pattern with a feathery appearance.

Nodular fasciitis is well known to dermatologists and pathologists, due to its preferential occurrence in subcutaneous tissues and importance in the differential diagnosis of soft-tissue tumors. Nodular fasciitis is rarely encountered in other fields of clinical practice. In this case report, we describe a patient with nodular fasciitis in the breast tissue that mimicked a breast cancer manifestation.

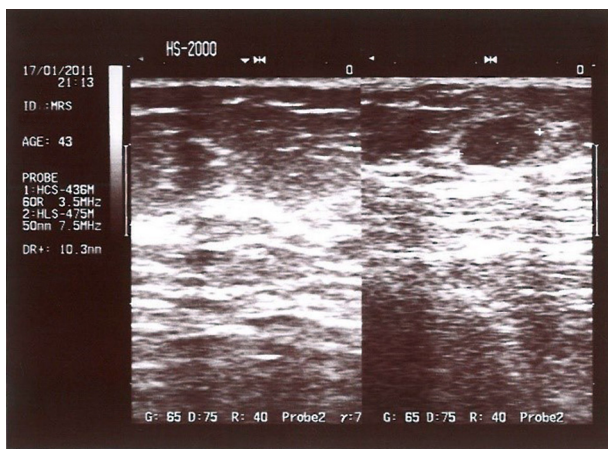
### 2. Case Presentation

The patient was a 43 year-old female who had detected a

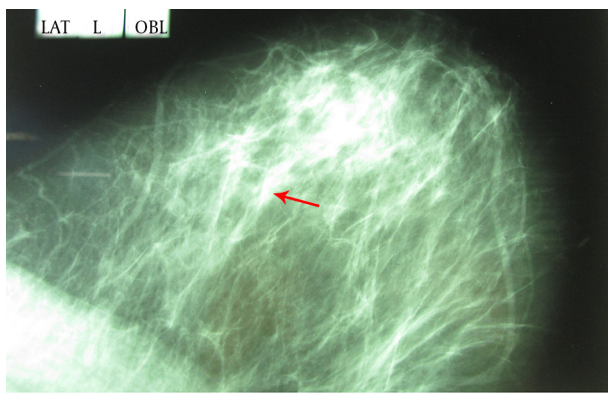
mass within the upper-lateral quadrant of her left breast 20 days earlier. A past medical history of thyroidectomy, hyperlipidemia and diabetes mellitus existed. Due to a harsh mastalgia, some diagnostic sonographies had been conducted on her breasts during the previous year. No evidence of malignancy was reported, and only fibrocystic changes were detected. Therefore, a follow-up schedule including annual sonography and physical examination was recommended to the patient. Two months after the last survey, the patient detected a mass within the aforementioned site of her left breast.

In examination, the mass was tiny, without any sharp margins, and tender to palpation. No evidence of active painful sensation or discharge from the nipple was detected. Complementary studies including sonography, mammography and excisional biopsy were established and the following findings were reported:

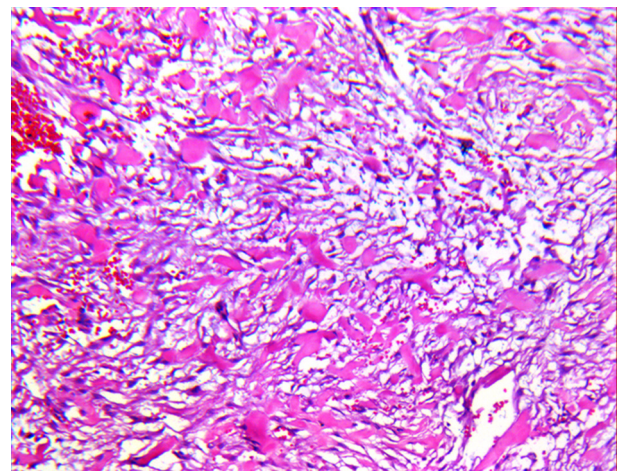
In the sonogram, a 10 mm diameter hypoechoic mass was detected in the 12 o'clock position within the left breast. The first sonography of the lesion [with a BIRADS category of 2] showed a suspicious mass and the second



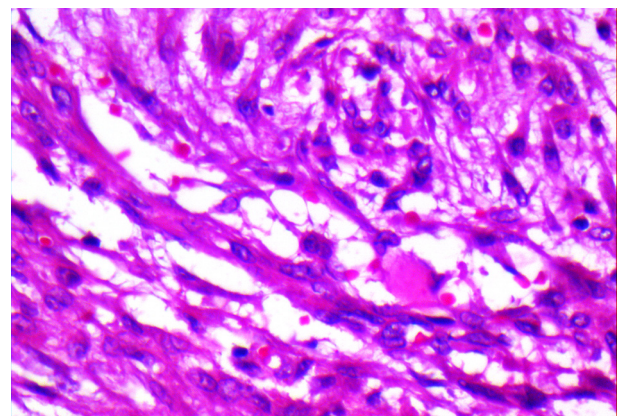
**Figure 1.** A 43 year-old woman with a mass in upper-lateral quadrant of left breast. Breast sonography shows a hypoechoic mass.



**Figure 2.** BIRADS category 4 in mammography of the left breast (mass is marked in the mammography)



**Figure 3.** Microscopic appearance of the mass (H&E staining,  $\times 10$ )



**Figure 4.** Microscopic appearance of the mass (H&E staining,  $\times 40$ )

sonography [in which the BIRADS category increased to 4] revealed the mass is growing (Figure 1). Considering the position of the lesion, mammography showed no evidence of mass, but some evidence of fibroglandular condensation were obvious (Figure 2).

Finally, according to the pathologic study, macroscopic and microscopic findings are listed below:

**Macroscopic appearances:** a gray-cream tissue with the size of  $2 \times 1.5 \times 1$  cm contained a creamy nodular lesion with 1.5 cm in diameter and loose formidability.

**Microscopic features:** the tissue was composed of fusiform fibroblastic cells with the bright ellipsoid-like nuclei, elevated nucleolus and also mitotic formations were obvious.

Low cellular and high cellular zones with hyaline fibrosis and erythrocyte accumulation beside a light lymphocytic infiltration existed.

Considering all of these features in addition to adipocytic accumulation within margins of this lesion, suggested the definitive diagnosis of nodular fasciitis (Figures 3 and 4).

### 3. Discussion

Nodular fasciitis rarely develops within the breast (5) and commonly presents with subcutaneous manifestations (6). The incidence ratio of nodular fasciitis between males and females is 1:1 (4, 6).

Nodular fasciitis is clinically and pathologically similar to breast cancer (7). However, in this lesion, nipple discharge is absent and the mass grows rapidly (1-3). For the patient in our example, the mass growth had progressed within only 20 days. In 36% of cases, nodular fasciitis develops in the forearm and 20% in the head and neck region, but the occurrence of this lesion within the breast is quite rare. As shown in Table 1, in our wide internet search, there were only 19 cases of this kind from 1988 until now (4, 6)

In Table 1, we describe cases reported from 2010 till 2014. All of the cases that introduced nodular fasciitis from 1980 until the present totaled 150, but the presence of nodular fasciitis in the breast tissue was rare.

**Table 1.** Summary of Different Cases

Case	Reference	Year	Age/Gender	Size	Treatment
1	Kontogeorgos et al. (8)	1988	-	-	Excised
2	B. Maly and A. Maly (9)	2001	15-year-old woman	2	Excised
3	Dahlstrom et al. (2)	2001	38-year-old woman	1.2	Excised
4	Polat et al. (6)	2002	66-year-old woman	-	Excised
5	Tulbah et al. (10)	2003	18-year-old woman	-	Excised
6	Brown and Carty (11)	2003	65-year-old woman	5.5	observed
7	Porter et al. (12)	2006	75-year-old woman	-	-
8	Porter et al. (12)	2006	52-year-old woman	-	-
9	Hayashi et al. (5)	2007	41-year-old woman	1.5	Excised
10	Squillaci et al. (13)	2007	40-year-old woman	3.5	Excised
11	Yamamoto et al. (14)	2009	18-year-old woman	0.8	Excised
12	Hayashi et al. (5)	2012	25-year-old woman	0.5	Excised
13	Paker et al. (15)	2013	17-year-old woman	1.5	Excised
14	Son et al. (16)	2013	41-year-old woman	1.1	Excised
15	Kakimoto et al. (17)	2014	78-year-old woman	1.5	Excised
16	Samardzic et al. (18)	2014	68-year-old woman	4	Excised
17	Yamamoto S. et al. (14)	2014	35-year-old woman	3.5	Excised
18	Choi et al. (19)	2014	35-year-old woman	1.5	Excised
19	Rhee et al. (20)	2014	-	-	-

Differential diagnosis between nodular fasciitis and breast cancer is difficult when using radiography or mammography, so the definitive diagnosis is established using accurate histopathology (1-3). In sonography, this lesion manifests as an ellipsoid mass. However, we cannot discriminate nodular fasciitis from breast cancer with this technique (7, 8). Nodular fasciitis develops within the breasts of middle-aged females from 36 to 48 year-old (1-3). Considering this age range for incidence of nodular fasciitis, it could be thought that our patient is in the middle of this range. Fifty percent of all lesions are located within superficial fascias whereas others are within deep ones, correlated with muscles, tendons, vessels, neuronal sheaths and periosteums (4, 6). The size of the mass is commonly around 1 to 3 cm and rarely is more than 5 cm (4, 6).

Finally, considering the extreme similarity between nodular fasciitis and breast cancer, the use of cytologic techniques could reduce unnecessary biopsies and enable physicians to decide whether interventional surgical procedure is more suitable. This also reduces the risk of iatrogenic harm to the patient (1-3).

## Acknowledgments

This study was conducted in Yazd Shahid Sadoughi Hospital.

## Footnotes

**Authors' Contribution:** Study concept Mansour Moghimi; acquisition of data: Pouria Yazdian-Anari;

analysis and interpretation of data: Marzie Vaghefi; drafting of the manuscript: Abbas Meidany; critical revision of the manuscript for important intellectual content: Mansour Moghimi; administrative, technical, and material support: Heidar Salehi; study supervision: Mansour Moghimi.

## References

1. Shimizu S, Hashimoto H, Enjoji M. Nodular fasciitis: an analysis of 250 patients. *Pathology*. 1984;**16**(2):161-6. [PubMed: 6462780]
2. Dahlstrom J, Buckingham J, Bell S, Jain S. Nodular fasciitis of the breast simulating breast cancer on imaging. *Australas Radiol*. 2001;**45**(1):67-70. [PubMed: 11259978]
3. Montgomery EA, Meis JM. Nodular fasciitis. Its morphologic spectrum and immunohistochemical profile. *Am J Surg Pathol*. 1991;**15**(10):942-8. [PubMed: 1928550]
4. Allen PW. Nodular fasciitis. *Pathology*. 1972;**4**(1):9-26. [PubMed: 4501523]
5. Hayashi H, Nishikawa M, Watanabe R, Sawaki M, Kobayashi H, Shibata A, et al. Nodular fasciitis of the breast. *Breast Cancer*. 2007;**14**(3):337-9. doi: 10.1007/s12282-009-0149-1. [PubMed: 17690516]
6. Polat P, Kantarci M, Alper F, Gursan N, Suma S, Okur A. Nodular fasciitis of the breast and knee in the same patient. *AJR Am J Roentgenol*. 2002;**178**(6):1426-8. doi: 10.2214/ajr.178.6.1781426. [PubMed: 12034611]
7. Ozben V, Aydogan F, Karaca FC, Ilvan S, Uras C. Nodular Fasciitis of the Breast Previously Misdiagnosed as Breast Carcinoma. *Breast Care (Basel)*. 2009;**4**(6):401-2. doi: 10.1159/000261502. [PubMed: 20877676]
8. Kontogeorgos G, Papamichalis G, Bouropoulou V. Fibroblastic lesion of the breast exhibiting features of nodular fasciitis. *Arch Anat Cytol Pathol*. 1988;**36**(3):113-5. [PubMed: 3202657]
9. Maly B, Maly A. Nodular fasciitis of the breast: report of a case initially diagnosed by fine needle aspiration cytology. *Acta Cytol*.

- 2001;**45**(5):794-6. [PubMed: 11575664]
10. Tulbah A, Baslaim M, Sorbris R, Al-Malik O, Al-Dayel F. Nodular fasciitis of the breast: a case report. *Breast J.* 2003;**9**(3):223-5. [PubMed: 12752631]
  11. Brown V, Carty NJ. A case of nodular fasciitis of the breast and review of the literature. *Breast.* 2005;**14**(5):384-7. doi: 10.1016/j.breast.2004.09.014. [PubMed: 16216741]
  12. Porter GJ, Evans AJ, Lee AH, Hamilton LJ, James JJ. Unusual benign breast lesions. *Clin Radiol.* 2006;**61**(7):562-9. doi: 10.1016/j.crad.2006.02.008. [PubMed: 16784941]
  13. Squillaci S, Tallarigo F, Patarino R, Bisceglia M. Nodular fasciitis of the male breast: a case report. *Int J Surg Pathol.* 2007;**15**(1):69-72. doi: 10.1177/1066896906295999. [PubMed: 17172503]
  14. Yamamoto S, Chishima T, Adachi S. Nodular fasciitis of the breast mimicking breast cancer. *Case Rep Surg.* 2014;**2014**:747951. doi: 10.1155/2014/747951. [PubMed: 24963435]
  15. Paker I, Kokenek TD, Kacar A, Ceyhan K, Alper M. Fine needle aspiration cytology of nodular fasciitis presenting as a mass in the male breast: report of an unusual case. *Cytopathology.* 2013;**24**(3):201-3. doi: 10.1111/j.1365-2303.2011.00947.x. [PubMed: 22230031]
  16. Son YM, Nahm JH, Moon HJ, Kim MJ, Kim EK. Imaging findings for malignancy-mimicking nodular fasciitis of the breast and a review of previous imaging studies. *Acta Radiol Short Rep.* 2013;**2**(8):2047981613512830. doi: 10.1177/2047981613512830. [PubMed: 24349717]
  17. Kakimoto M, Nakata T, Imaizumi K, Hirano T, Yamamoto Y, Chikatanani K, et al. [A case of locally recurrent breast cancer difficult to differentiate from nodular fasciitis]. *Gan To Kagaku Ryoho.* 2014;**41**(12):1881-3. [PubMed: 25731362]
  18. Samardzic D, Chetlen A, Malysz J. Nodular fasciitis in the axillary tail of the breast. *J Radiol Case Rep.* 2014;**8**(5):16-26. doi: 10.3941/jrcr.v8i5.1903. [PubMed: 25426226]
  19. Choi HY, Kim SM, Jang M, Yun BL, Ahn HS, Park SY, et al. Nodular Fasciitis of the Breast: A Case and Literature Review. *Ultraschall Med.* 2015;**36**(3):290-1. doi: 10.1055/s-0034-1366340. [PubMed: 24854130]
  20. Rhee SJ, Ryu JK, Kim JH, Lim SJ. Nodular fasciitis of the breast: two cases with a review of imaging findings. *Clin Imaging.* 2014;**38**(5):730-3. doi: 10.1016/j.clinimag.2014.04.006. [PubMed: 24849197]