

## Pneumocephalus Presenting as Sudden Thunderclap Headache

### Abstract

Pneumocephalus is a rare condition characterized by the presence of gas within the cranial cavity. This gas arises either from a trauma, tumor, surgical procedure, or occasionally from infection. Pneumocephalus secondary to chronic otitis media is an extremely rare phenomenon. We describe here a 70-year-old male, a known case of chronic suppurative otitis media who presented with sudden onset severe thunderclap headache and was eventually diagnosed as pneumocephalus.

**Keywords:** *Pneumocephalus, subarachnoid hemorrhage, thunderclap headache*

**Vivek S. Guleria,  
Ajay Sharma,  
Chetan Sharda,  
Virendra Kumar**

*Department of Medicine,  
Military Hospital, Palampur,  
Himachal Pradesh, India*

### Introduction

Pneumocephalus denotes the presence of air within the skull.<sup>[1]</sup> In 1884, Chiari was the first to diagnose pneumocephalus on an autopsy done on a patient with ethmoiditis.<sup>[2]</sup> Orogenic infections rarely cause pneumocephalus. Although the rate of intracranial complications related to middle ear disease is only 0.5%–4%, mortality still ranges between 5% and 15%. Pneumocephalus secondary to chronic suppurative otitis media (CSOM) is an extremely rare phenomenon. Despite its rarity, the sequelae of intracranial air associated with otitis media may be grave if misdiagnosed. We report here a case of pneumocephalus occurring in a known case of CSOM who presented in our medical department with sudden onset of severe headache.

### Case Report

A 70-year-old elderly male, a known case of CSOM, bilateral ears with history of ear discharge for 10 years associated with impairment of hearing, presented with sudden onset of severe headache of 2 h duration accompanied by recurrent vomiting. On examination, the patient was uncomfortable, restless holding occipital portion of his head, and claiming it to be the worst headache he ever had. His blood pressure was 156/78 mmHg and pulse rate 120/min. He was febrile with a temperature of 100°F. He had terminal neck rigidity though Kernig's sign was negative.

Otoscopic examination showed purulent otorrhea in the left external meatus and the left tympanic membrane was slightly hyperemic; no swelling or tenderness was noted in the external auditory meatus or in the retroauricular area [Figure 1]. His fundus and other systemic examination was normal.

A probable diagnosis of subarachnoid hemorrhage was made and urgent noncontrast computed tomography was done which showed diffuse pneumocephalus and soft tissue in both middle ears suggestive of CSOM [Figures 2-4].

The patient had neutrophilic leukocytosis with total leukocyte count of 12,000/cumm. Rest of his hematological and biochemical profile was normal [Table 1]. Lumbar puncture was done. Cerebrospinal fluid was turbid with total leukocyte count of 3100/cumm, neutrophils being the predominant cells, proteins 80 mg/dl, and sugars of 54 mg/dl. Both CSF and ear discharge yielded no growth.

A diagnosis of CSOM leading to meningitis, pneumocephalus, and sepsis was made and the patient was started on vancomycin (20 mg/kg/dose 12 hourly intravenous [IV]), meropenem (40 mg/kg/dose q8 h, IV), and dexamethasone (10 mg 6 hourly along with supportive management). After 48 h of medical treatment, the patient's clinical status improved dramatically.

### Discussion

Pneumocephalus can be defined as the presence of air or gas within the intracranial

#### Address for correspondence:

*Dr. Vivek S. Guleria,  
Department of Medicine,  
Military Hospital,  
Palampur - 176 061,  
Himachal Pradesh, India.  
E-mail: vivekguleria@gmail.  
com*

This is an open access article distributed under the terms of the Creative Commons Attribution-NonCommercial-ShareAlike 3.0 License, which allows others to remix, tweak, and build upon the work non-commercially, as long as the author is credited and the new creations are licensed under the identical terms.

For reprints contact: reprints@medknow.com

**How to cite this article:** Guleria VS, Sharma A, Sharda C, Kumar V. Pneumocephalus presenting as sudden thunderclap headache. *Asian J Neurosurg* 2017;12:695-7.

#### Access this article online

Website: [www.asianjns.org](http://www.asianjns.org)

DOI: 10.4103/ajns.AJNS\_25\_15

Quick Response Code:



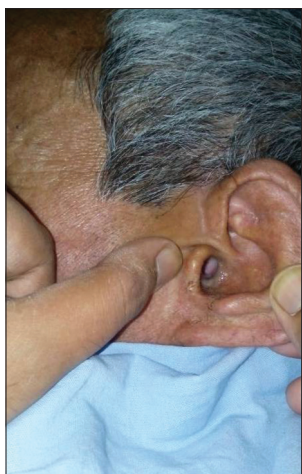


Figure 1: Purulent otorrhea in the left external meatus

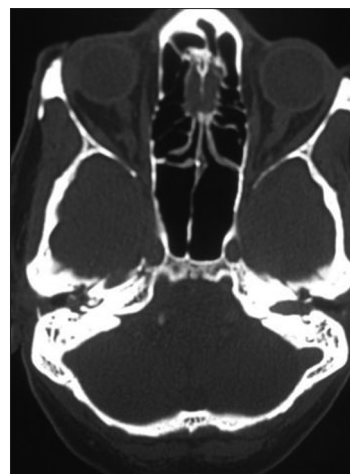


Figure 2: Computed tomography showing bilateral sclerotic mastoids and soft tissue in both middle ears suggestive of chronic suppurative otitis media

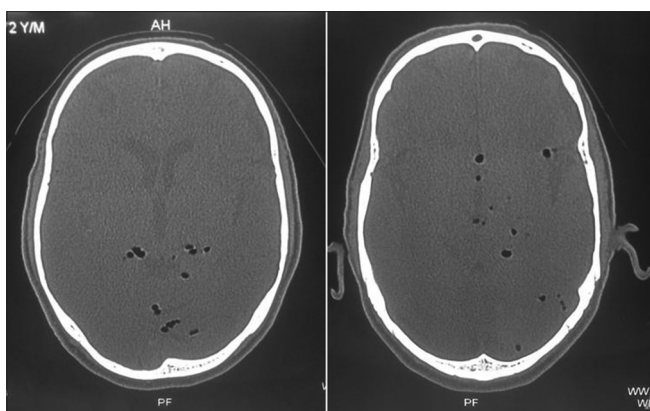


Figure 3: Subarachnoid pneumocephalus involving quadrigeminal plate, Sylvian fissure, interpeduncular and suprasellar cisterns

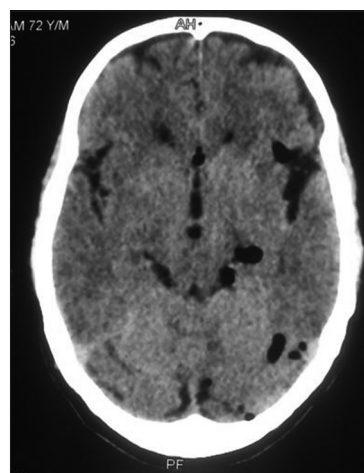


Figure 4: Subarachnoid pneumocephalus involving quadrigeminal plate, Sylvian fissure, interpeduncular and suprasellar cisterns

**Table 1: Investigations on admission**

Investigation	Value
Hemoglobin (g/dl)	14.3
Total leukocyte count (/cumm)	12,600
Polymorphs (%)	78
Lymphocytes (%)	18
Urea (mg/dl)	23
Creatinine (mg/dl)	0.8
Serum bilirubin (mg/dl)	0.8
Alanine aminotransferase (IU/L)	28
Aspartate aminotransferase (IU/L)	32
Urine routine/microscopic examination	Normal
Blood sugar random (mg/dl)	90

cavity. Pneumocephalus can be epidural, subdural, subarachnoid, parenchymal, or intraventricular depending on the location of air. It may be as a result of traumatic injuries, erosion of the skull due to neoplasm or infection, neurosurgical procedures, or fistulous tract formation.<sup>[3]</sup>

Although pneumocephalus is quite common following trauma, it is a rare manifestation of middle ear infections. Genesis of pneumocephalus in the absence of a breach

between the middle ear and middle or posterior cranial fossa can be explained by spread of the infection, caused by gas-forming microorganisms that may exist in the otogenic foci, as in cases of CSOM. Hematogenous dissemination can occur by the way of small blood vessels that connect the vascular networks of the temporal bone, dura and venous sinuses, and also through vascular connections existing between the mucoperiosteum of the middle ear and dura<sup>[4]</sup>

In the clinical picture of otogenic pneumocephalus and meningitis as in this case, headache is one of the earliest symptoms, together with fever. Vomiting may be present, along with agitation and irritability. Rigor nuchalis is another early sign, as well as lethargy and poor oral intake. Headache becomes intolerable with progressive involvement of dura mater, photophobia may appear, and fever continues to rise. Neurological deficits, alteration in consciousness and coma may follow if treatment is not promptly established. Treatment of pneumocephalus

depends on the degree and progression of air collection and of course the etiology. Most cases resolve with conservative management, while surgical intervention is indicated in continued CSF leak or progression to a tension condition.<sup>[5]</sup>

### Conclusion

In spite of early diagnosis and aggressive use of antibiotics, intracranial complications of otitis media still occur. Pneumocephalus secondary to otogenic infections though rare should always be considered as a differential, as it requires prompt intervention.

### Financial support and sponsorship

Nil.

### Conflicts of interest

There are no conflicts of interest.

### References

1. Frankel M, Fahey D, Alker G. Otogenic pneumocephalus secondary to chronic otitis media. *Arch Otolaryngol* 1980;106:437-9.
2. Andrews JC, Canalis RF. Otogenic pneumocephalus. *Laryngoscope* 1986;96:521-8.
3. Dowd GC, Molony TB, Voorhies RM. Spontaneous otogenic pneumocephalus. Case report and review of the literature. *J Neurosurg* 1998;89:1036-9.
4. Nager GT. *Pathology of the Temporal Bone*. Baltimore: Williams and Wilkins; 1993. p. 262-3.
5. Ajalloveyan M, Doust B, Atlas MD, Fagan PA. Pneumocephalus after acoustic neuroma surgery. *Am J Otol* 1998;19:824-7.