

# Ultrasound-guided perineural injection with dextrose for treatment of radial nerve palsy

## A case report

Si-Ru Chen, MD<sup>a</sup>, Yu-Ping Shen, MD<sup>b</sup>, Tsung-Yen Ho, MD<sup>b</sup>, Liang-Cheng Chen, MD, MS<sup>b</sup>, Yung-Tsan Wu, MD<sup>b,\*</sup>

### Abstract

**Rationale:** Perineural injection with dextrose could be a novel intervention for peripheral entrapment neuropathy. However, this intervention has not been reported for treating radial nerve palsy (RNP). Here, we present a case with RNP having outstanding improvement after 2 sessions of ultrasound-guided perineural injection with 5% dextrose (D5W).

**Patient concerns:** A 62-year-old woman presented with difficulty and weakness in extension of her left wrist and fingers after she slept with the arm compressed against her body.

**Diagnoses:** On the basis of the findings of electrophysiological study and ultrasonography, the RNP with axonal injury was diagnosed.

**Interventions:** Initially, the patient received 2-months conservative treatments without any improvement. Two sessions of ultrasound-guided perineural injection with total 15cc D5W with an interval of 1 month were performed 2 months after symptom onset.

**Outcomes:** A noteworthy improvement in sensory and motor functions was observed after ultrasound-guided perineural injection with D5W.

**Lessons:** This case shows that ultrasound-guided perineural injection with D5W may be an effective and novel intervention for RNP.

**Abbreviations:** BR = brachioradialis, CMAP = compound muscle action potential, CTS = carpal tunnel syndrome, D5W = 5% dextrose, EDC = extensor digitorum common, EIP = extensor indicis proprius, MN = median nerve, MUAP = motor unit action potential, NASIDs = nonsteroidal anti-inflammatory drugs, RN = radial nerve, RNP = radial nerve palsy, TRPV1 = transient receptor potential vanilloid receptor-1, VAS = visual analog scale.

**Keywords:** dextrose, radial nerve palsy, ultrasound-guided

## 1. Introduction

Radial nerve palsy (RNP) has various etiologies, including prolonged pressure and trauma to the radial nerve (RN) in the arm. The symptoms typically encompass pain, dyesthesia, and drop wrist. Conservative management includes rest, physical therapy, and nonsteroidal anti-inflammatory drugs (NASIDs),

and surgery is recommended if symptoms persist without improvement after conservative therapy for 12 weeks.<sup>[1]</sup>

Perineural injection with dextrose is a new treatment for peripheral neuropathy and was first developed by Lyftogt<sup>[2]</sup> in 2005. Moreover, 5% dextrose (D5W) has been commonly used in the clinical practice because it has no known significant sequelae for nerves.<sup>[3,4]</sup> Even though perineural injection with dextrose has been progressively clinically utilized, its definite effect has been insufficiently proven due to few published studies so far. Furthermore, perineural injection via nerve hydro-dissection could detach soft tissues, improving the passage of nerve impulses and limiting ischemic nerve damage.<sup>[5]</sup> In 2017, Wu et al<sup>[4]</sup> showed that perineural injection with D5W is a safe and effective intervention for carpal tunnel syndrome (CTS). However, perineural injection with D5W for treating RNP has not been previously reported.

Here, we present a case with RNP having outstanding improvement after 2 sessions of ultrasound-guided perineural injection with D5W.

## 2. Case report

The study had approval from the institutional review board of Tri-Service General Hospital (No. 1-107-05-038) and the patient provided the written informed consent for the report.

Editor: N/A.

There is no funding or support in this study.

The authors have no conflicts of interest to disclose.

<sup>a</sup> Department of Medicine, <sup>b</sup> Department of Physical Medicine and Rehabilitation, Tri-Service General Hospital, School of Medicine, National Defense Medical Center, Taipei, Taiwan, Republic of China.

\* Correspondence: Yung-Tsan Wu, Department of Physical Medicine and Rehabilitation, Tri-Service General Hospital, School of Medicine, National Defense Medical Center, No. 325, Sec. 2, Cheng-Kung Road, Neihu District, Taipei, Taiwan, Republic of China (e-mail: crwu98@gmail.com).

Copyright © 2018 the Author(s). Published by Wolters Kluwer Health, Inc. This is an open access article distributed under the terms of the Creative Commons Attribution-Non Commercial License 4.0 (CCBY-NC), where it is permissible to download, share, remix, transform, and buildup the work provided it is properly cited. The work cannot be used commercially without permission from the journal.

Medicine (2018) 97:23(e10978)

Received: 22 February 2018 / Accepted: 7 May 2018

<http://dx.doi.org/10.1097/MD.0000000000010978>

A 62-year-old woman who was previously healthy presented with difficulty and weakness in extension of her left wrist and fingers after she slept with the arm compressed against her body. Thus, the patient visited a district hospital where neurologic examinations showed decreased sensation in the distribution of the RN from the distal third of the arm to the forearm and hand. The patient rated the dyesthesia at 7 on a visual analog scale (VAS). She also presented with drop wrist with a power grade being 2 at the extensor carpi radialis longus/brevis, extensor carpi ulnaris, supinator, and all digital extensor muscles. The strength of wrist/finger flexion and the triceps were normal. The deep tendon reflex of the brachioradialis (BR) was decreased but otherwise was within the normal range.

An electrophysiological study was performed 18 days after the onset of symptoms. The results showed a markedly reduced amplitude of compound muscle action potential (CMAP) of the left RN compared with the contralateral side below the spiral groove with normal conduction velocity (Table 1). In addition, denervation potentials with fibrillation at the extensor digitorum communis (EDC) and extensor indicis proprius (EIP) and a positive sharp wave at EDC, EIP, and BR were observed. The electromyography studies showed decreased amplitude and discrete recruitment of motor unit action potential (MUAP) in the EDC, EIP, and BR (Table 1). In addition, the examined muscles including the triceps, biceps, first dorsal interosseous, and abductor pollicis brevis did not show abnormal findings. Based on clinical symptoms and results of the electrophysiological study, axonal injury of radial nerve neuropathy due to compression of the RN at the spiral groove was diagnosed. Initially, the patient received 2 weeks of conservative treatments including physical modalities along with medications of NSAIDs and Cobalamin; however, no improvement was noted. After that, the patient only received the previously noted medications but the symptoms persisted.

The patient was referred to our department 2 months after symptom initiation where her symptoms and neurological examinations were found to be unchanged. The ultrasonography found swelling of the RN at the spiral groove compared with right side (Fig. 1A–D). Hence, ultrasound-guided perineural injection with D5W (total 15 cc) was injected at the point of the swelling of the RN. 5 cc of D5W was injected into both the upper

and inferior part of the RN and additional 5 mL was delivered with a long-axial approach to peel the RN off the brachialis via hydrodissection (Fig. 1E and F).

Physical and occupational therapies were also performed 4 days postinjection. One week postinjection, the patient reported significant improvement in dyesthesia and disability. Her muscle power had increased from grade 2 to 3<sup>+</sup> and dyesthesia VAS score decreased from 7 to 3.

Another perineural injection with D5W was performed 1 month later. The VAS score decreased to two 2 weeks postinjection and her muscle power improved to around 4. The follow-up electrophysiological study 3 weeks after the 2nd injection revealed normal amplitude of CMAP and MUAP and no more denervation potentials with nearly normal recruitment activity (except a mild decrease at EDC) and mild increased polyphasic waves at BR and EDC. The patient regularly participated in rehabilitation program and she reported complete resolution of her symptoms 2 months after 2nd injection (Fig. 2).

### 3. Discussion

Although the etiology of RNP is known to be multifactorial, excessive pressure on the RN is regarded as one of the major causes. Published studies demonstrated favorable recovery within average 47 days after nontraumatic compressive radial neuropathy.<sup>[6]</sup> In our case, the patient initially did not respond to conservative treatments for 2 months while outstanding improvement was observed a week after the 1st perineural injection. Moreover, noteworthy improvements were also observed 2 weeks after the 2nd injection. We suggest the perineural injection with D5W contributed to the improvement of sensory and motor functions in our patient.

Traditional prolotherapy is based on the theory of tendon-ligament regeneration by injecting >10% dextrose to stimulate local inflammation.<sup>[7]</sup> In contrast, the possible mechanism of D5W is thought to decrease neurogenic inflammation by inhibiting transient receptor potential vanilloid receptor-1 (TRPV1) that can be found on peripheral nerves. The inactivity of TRPV1 could then block the release of neuropeptides that supply the inflammation cascade.<sup>[8]</sup> Although the true mechanism of D5W for peripheral neuropathy is still unclear, recent

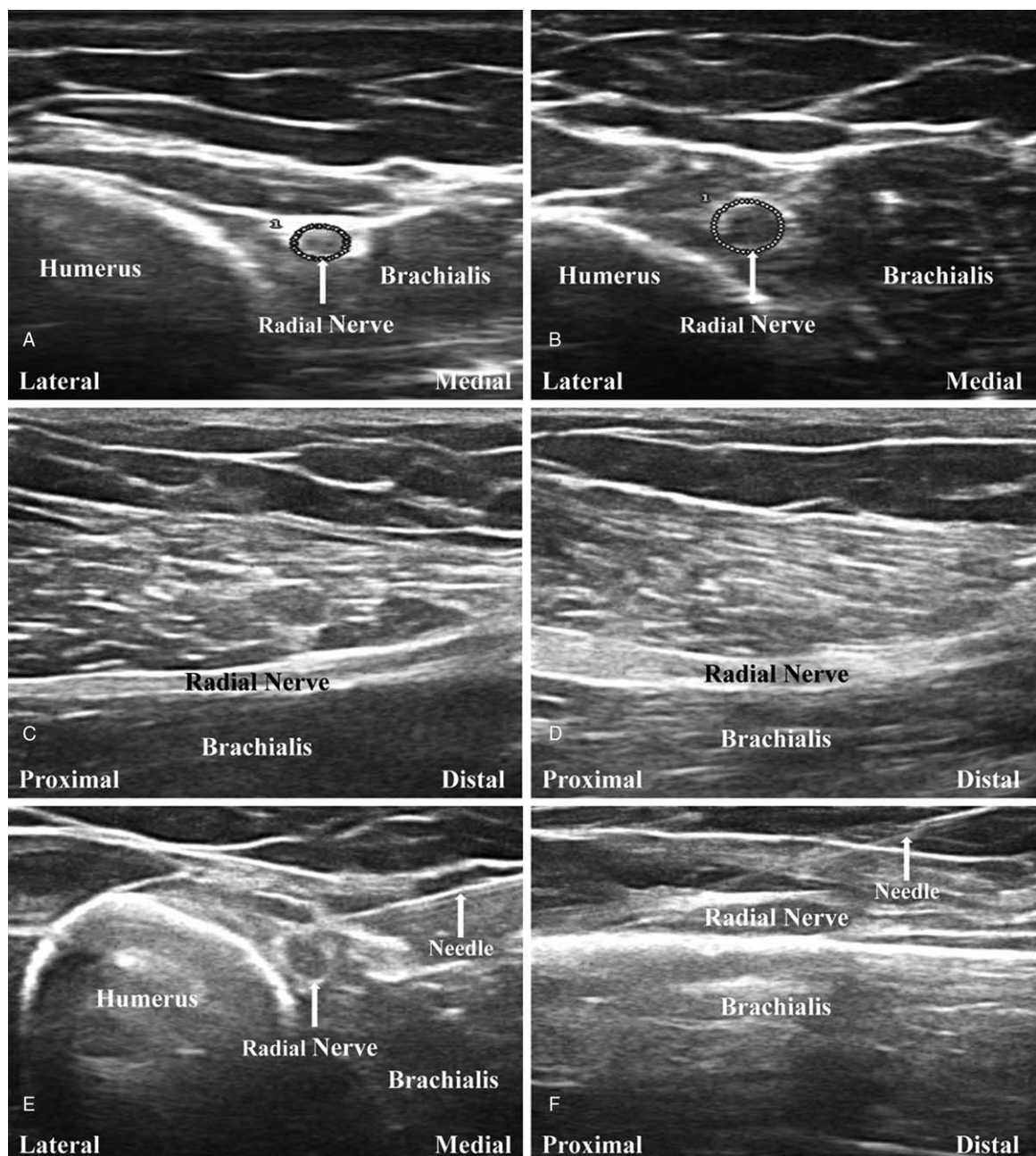
**Table 1**  
Nerve conduction and needle electromyography studies.

Nerve	Stimulus site	Recording site	Amplitude (mV/uV)	Velocity (m/s)	Latency (ms)	Distance from recording site (cm)
Sensory						
Left radial	Forearm	Base 1st digit	84.3	42.4	1.77	7.5
Left radial	Elbow	Base 1st digit	16.3	48.7	3.70	18.0
Right radial	Forearm	Base 1st digit	116.0	39.7	1.51	6.0
Right radial	Elbow	Base 1st digit	20.8	55.2	3.44	19.0
Motor						
Left radial	Forearm	EIP	2.2		1.98	4.5
Left radial	Elbow	EIP	2.3	55.6	3.96	15.5
Right radial	Forearm	EIP	3.2		1.88	4.5
Right radial	Elbow	EIP	3.5	59.7	3.80	16.0

Needle EMG muscle	Spontaneous				MUAP			
	Insertional activity	Fibrillation	Positive sharp wave	Fasciculation	Amplitude (uV)	Polyphasic potential	Duration	Recruitment pattern
EIP	NL	1+	2+	None	1–	NL	NL	Discrete
EDC	NL	1+	1+	None	1–	NL	NL	Discrete
BR	NL	None	1+	None	1–	NL	NL	Discrete

BR=brachioradialis, EDC=extensor digitorum communis, EIP=extensor indicis proprius, MUAP=motor unit action potential, NL=normal.



**Figure 1.** Ultrasonographic imaging. A, Short-axial view of the radial nerve (RN) (arrow) on the noncompression side. B, Significantly increased cross-sectional area of the RN on the compression side (arrow). C, Long-axial view of the RN on the noncompression side. D, Obvious swelling of the RN on the compression side (arrow). E, Ultrasound-guided injection at the RN (short-axial view). F, Ultrasound-guided injection at the RN (long-axial view).

published study showed a significant reduction in the cross-sectional area of the median nerve (MN) compared with that in the control group (perineural injection with normal saline) and this observation hints at the antineurogenic inflammation mechanism of D5W.<sup>[4]</sup> Further histological research to investigate the definite mechanism of D5W is necessary.

Except for possible antineurogenic inflammation of D5W, perineural injection inducing nerve hydrodissection could partially have contributed to the therapeutic effect by detaching soft tissue adhesions to allow for additional nerve impulses to pass through and reverse the ischemic damage. Despite the effect, its duration is currently unknown.<sup>[5]</sup> However we believe that any hydrodissection effect would not persist for long in our case

based on the reasons illustrated as below. First, the D5W can be nearly completely absorbed 1 hour postinjection by the findings of Wu et al.<sup>[4]</sup> Second, the compressive pressure causing RNP is temporary, unlike the pathophysiology of persistent compression by the carpal tunnel on the MN. Hence, the effect of hydrodissection in RNP is expected to be less essential or persist as long as CTS.<sup>[4]</sup> A future well-designed trial is necessary to investigate the true effect of hydrodissection.

The use of ultrasound-guided perineural injection with D5W was first published in 1 case report where this technique was performed to treat the entrapment of superficial RN from a fibrotic adhesion at the wrist.<sup>[9]</sup> However, there were no objective measurements used to evaluate the patient's prognosis. More-

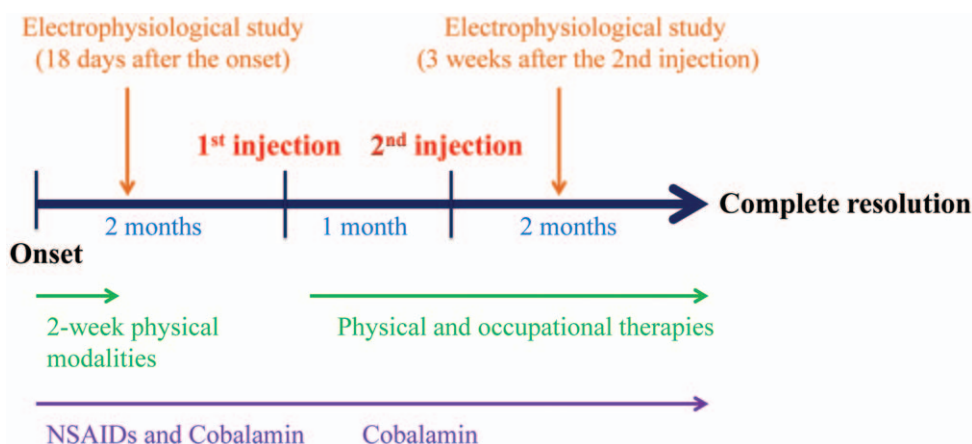


Figure 2. Timeline of treatment and follow-up period.

over, Wu et al<sup>[4]</sup> found perineural injection with D5W has benefits for CTS. The severity of RNP in our patient was reported as axonal injury, not a conduction block, although the conduction block was the most frequent injury type in RNP.<sup>[10]</sup> The pathophysiology behind the noteworthy recovery in the electrophysiological study after perineural injection in our case is hard to explain because current studies about D5W for axonal injury are lacking. The follow-up electrophysiological study was performed about 4 months after the injury and it showed normal amplitude of CMAP. Moreover, no more denervation potential with nearly normal recruitment activity and a mild increased polyphasic wave at BR and EDC were observed. It seems there was incomplete reinnervation of RNP at this time-point. In addition, the initial electrophysiological study showed a slightly reduced amplitude of CMAP (−31 to 34%) with mild increased denervation potentials. It indicated mild axonal injury in our case and this may explain the relatively rapid disappearance of denervation potentials and improved recruitment. Here, we suggest that perineural injection with D5W may be a novel approach to enhance the recovery of the RNP even after a severe axonal injury. However, spontaneous recovery of the RNP can also occur and 1 case report cannot demonstrate the overall effect of this treatment.

#### 4. Conclusions

We demonstrated for the first time that ultrasound-guided perineural injection with D5W may be a novel intervention for RNP and studies with larger sample sizes were necessary to further explore the present study results.

#### Acknowledgment

The authors are grateful to Miss Jenifert Hsu who contributed to the technical assistant.

#### Author contributions

**Conceptualization:** Si-Ru Chen, Yung-Tsan Wu.

**Data curation:** Yu-Ping Shen, Tsung-Yen Ho.

**Investigation:** Si-Ru Chen.

**Writing – original draft:** Si-Ru Chen, Yu-Ping Shen, Tsung-Yen Ho, Yung-Tsan Wu.

**Writing – review and editing:** Liang-Cheng Chen, Yung-Tsan Wu.

#### References

- [1] Knutsen EJ, Calfee RP. Uncommon upper extremity compression neuropathies. *Hand Clin* 2013;29:443–53.
- [2] Lyftogt J. Prolotherapy and Achilles tendinopathy: a prospective pilot study of an old treatment. *Australas Musculoskelet Med* 2005;10:16–9.
- [3] Dufour E, Donat N, Jaziri S, et al. Ultrasound-guided perineural circumferential median nerve block with and without prior dextrose 5% hydrodissection: a prospective randomized double-blinded noninferiority trial. *Anesth Analg* 2012;115:728–33.
- [4] Wu YT, Ho TY, Chou YC, et al. Six-month efficacy of perineural dextrose for carpal tunnel syndrome: a prospective randomized double-blind controlled trial. *Mayo Clin Proc* 2017;92:1179–89.
- [5] Cass SP. Ultrasound-guided nerve hydrodissection: what is it? A review of the literature. *Curr Sports Med Rep* 2016;15:20–2.
- [6] Kim KH, Park KD, Chung PW, et al. The usefulness of proximal radial motor conduction in acute compressive radial neuropathy. *J Clin Neurol* 2015;11:178–82.
- [7] Jensen KT, Rabago DP, Best TM, et al. Early inflammatory response of knee ligaments to prolotherapy in a rat model. *J Orthop Res* 2008;26:816–23.
- [8] Bertrand H, Kyriazis M, Reeves KD, et al. Topical mannitol reduces capsaicin-induced pain: results of a pilot-level, double-blind, randomized controlled trial. *PM R* 2015;7:1111–7.
- [9] Chang KV, Hung CY, Ozcakar L. Snapping thumb and superficial radial nerve entrapment in De Quervain disease: ultrasound imaging/guidance revisited. *Pain Med* 2015;16:2214–5.
- [10] Arnold WD, Krishna VR, Freimer M, et al. Prognosis of acute compressive radial neuropathy. *Muscle Nerve* 2012;45:893–5.