

Case Report

Interdigitating Dendritic Cell Sarcoma of the Small Intestine Presenting as Spontaneous Hemoperitoneum – A Rare Case Report

Raveena Karthikeyan, H. Sakthivel, N. Rajkumar, K. Srinivasan

Department of General Surgery, Jawaharlal Institute of Postgraduate Medical Education and Research, Puducherry, India

Submitted: 01-Nov-2019
Revised : 24-Jan-2020
Accepted : 26-Mar-2020
Published : 09-Mar-2021

ABSTRACT

Interdigitating dendritic cell sarcoma (IDCS) is an extremely rare neoplasm arising from the antigen-presenting cells of the immune system. It usually involves the lymph nodes, and extranodal sites are rarely affected. Here, we report a first known case of spontaneous hemoperitoneum caused by the rupture of IDCS of the small bowel. A 61-year-old male presented with complaints of abdominal pain and fever for 3 days and breathlessness for 1 day. Ultrasound abdomen revealed a 15 cm × 7 cm heterogeneous collection with thick septations in the periumbilical region. Diagnostic peritoneal lavage revealed hemoperitoneum and gangrenous bowel. Emergency laprotomy was done and it revealed a friable mass arising from the ileum. Resection of 2 ft of the ileum and double-barrel ileostomy was done. Immunohistochemical analysis revealed a positivity of S100 and leukocyte common antigen). A diagnosis of IDCS was made. The patient had an uneventful postoperative recovery and planned for postoperative chemotherapy.

KEYWORDS: Immunohistochemistry, interdigitating dendritic cell sarcoma, spontaneous hemoperitoneum

INTRODUCTION

Dendritic cells are immune accessory cells derived from the hematopoietic stem cells. There are four types of dendritic cells present in lymph nodes: follicular, interdigitating, Langerhans, and fibroblastic/histolytic cells. Interdigitating cells are commonly located in the T-cell-rich areas of peripheral lymphoid tissue.^[1] Interdigitating dendritic cell sarcoma (IDCS) is a rare neoplasm with only 100 cases reported in the English literature.^[2,3] Although this tumor mostly arises in the lymph nodes, the extranodal sites such as spleen, small intestine, tonsil, nasopharynx, testis, and urinary tract are also noted.^[1,2] To our knowledge, only few cases of the IDCS arising from the small intestine have been reported till date. Based on the findings from previous studies, patients with intestinal involvement tend to be presented with intestinal obstruction.^[2,4] However, we report a first known case of IDCS of ileum presenting as spontaneous hemoperitoneum.

CASE REPORT

A 61-year-old male presented to the emergency department with complaints of lower abdominal pain,

fever, and vomiting for 3 days and breathlessness for 1 day. There was no history of trauma. Medical history was significant for essential hypertension and diabetes mellitus which had been controlled with oral drugs. Family history was negative for malignancy. His physical examination revealed tenderness in the lower abdomen without any palpable abdominal mass. Bowel sounds were absent. Digital examination showed a normal fecal staining. His laboratory tests were normal except for anemia (4.5g/dl). Ultrasound abdomen revealed 15 cm × 7 cm heterogeneous collection with thick septations in the periumbilical region. Diagnostic peritoneal lavage revealed hemoperitoneum and gangrenous bowel. Emergency laprotomy was done. A friable mass is seen arising from the distal ileum about 2 ft from the ileocecal junction [Figure 1]. Resection of 2 ft of the ileum and double barrel ileostomy

Address for correspondence: Dr. H. Sakthivel, Department of General Surgery, Jawaharlal Institute of Postgraduate Medical Education and Research, Puducherry - 605 008, India.
E-mail: shakthivel.hsurgeon@gmail.com

This is an open access journal, and articles are distributed under the terms of the Creative Commons Attribution-NonCommercial-ShareAlike 4.0 License, which allows others to remix, tweak, and build upon the work non-commercially, as long as appropriate credit is given and the new creations are licensed under the identical terms.

For reprints contact: WKHLRPMedknow_reprints@wolterskluwer.com

How to cite this article: Karthikeyan R, Sakthivel H, Rajkumar N, Srinivasan K. Interdigitating dendritic cell sarcoma of the small intestine presenting as spontaneous hemoperitoneum – A rare case report. Niger J Surg 2021;27:71-4.

Access this article online	
Quick Response Code: 	Website: www.nigerianjsurg.com
	DOI: 10.4103/njs.NJS_55_19

was done [Figure 2]. After adequate irrigation of the peritoneal cavity, the abdomen is closed by anatomical layers. Microscopically, the tumor cells were seen scattered in the subserosal aspect. Immunohistochemical analysis showed that the tumor cells were positive for leukocyte common antigen, CD 68, and S100 [Figure 3]. A diagnosis of the IDCS was made based on histological and immunohistochemical findings.

DISCUSSION

Spontaneous hemoperitoneum is a rare but life-threatening complication that is defined as blood within the peritoneal cavity of nontraumatic etiology. It most commonly arises from hepatic, splenic, vascular, or gynecologic pathology, and usually in anticoagulated or coagulopathic patients.^[5] Spontaneous hemoperitoneum caused by the rupture of tumors of the intestine is a rare entity.

Dendritic cell neoplasms are extremely rare tumors arising from the reticular cells, which participate in immune response as antigen-presenting cells that stimulate T-lymphocyte. The WHO classified dendritic cell neoplasms into five groups: Langerhans cell histiocytosis, Langerhans cell sarcoma, interdigitating dendritic cell sarcoma, follicular dendritic cell sarcoma, and not specified otherwise.^[6] IDCS is the most aggressive form among all the types.^[4] The median age at diagnosis is 56.5 years with slight male predilection (male-to-female ratio of 1.38:1). It mostly occurs in the lymph nodes; however, extranodal sites such as nasopharynx, small intestine, skin, testis, ovary, urinary bladder, tonsils, and pleura have also been reported.^[2,7] Local disease and no necrosis are found to be related with a better prognosis, while young age, tumors measuring ≥ 5 cm in diameter,^[4] intraabdominal lesion, and combined nodal/extranodal involvement indicate an adverse outcome of patients.

Dendritic cell sarcomas should be differentiated from other histiocytic and dendritic neoplasms as well as from melanoma and fibroblastic reticular tumors. The diagnosis cannot be made with clinical and light microscopy alone. Immunohistochemistry helps in achieving the diagnosis. In our case, the tumor cells stained positive for S100, myeloid cell marker CD68, and the leukocyte common antigen which is consistent with the previous reports describing IDCS,^[4,8] as well as negative for CD1a (LCS marker), CD3 (T-cell marker), CD20 (B-cell marker), HMB45 (melanoma marker), or cytokeratin (epithelial cell marker).

After a thorough review of the literature, we have found only eight cases of IDCS^[4] involving the intestinal tract [Table 1]. The small intestine was the common site, and most of the cases were presented with intestinal obstruction. However, we report a first known case of spontaneous hemoperitoneum caused by the rupture of IDCS of ileum.

There are no standard treatment guidelines for the treatment of IDCS owing to its rarity. IDCS is treated with surgical excision, radiotherapy, chemotherapy, or a combination of these therapies. In localized IDCS, surgical resection is the main stay of the treatment. Adjuvant radiotherapy has shown to prolong disease survival rates in some studies.^[6,7] Most of the advanced cases, which survived for several years, were treated with chemotherapy and/or radiation therapy.^[4] Several chemotherapeutic agents have been tried, including cyclophosphamide, doxorubicin, vincristine, and prednisolone; doxorubicin, bleomycin, vinblastine, and dacarbazine; dexamethasone, cisplatin, and high-dose cytarabine; and ifosfamide, carboplatin, and etoposide.^[6,7] In our case, the patient was advised chemotherapy but he refused citing age as a factor. After 6-month follow-up, there was no recurrence and the patient was planned for the restoration of intestinal continuity.

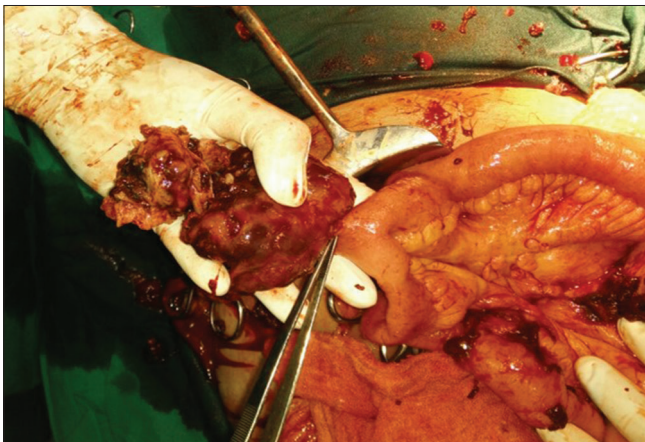

Figure 1: The intraoperative view showing tumor arising from the terminal ileum

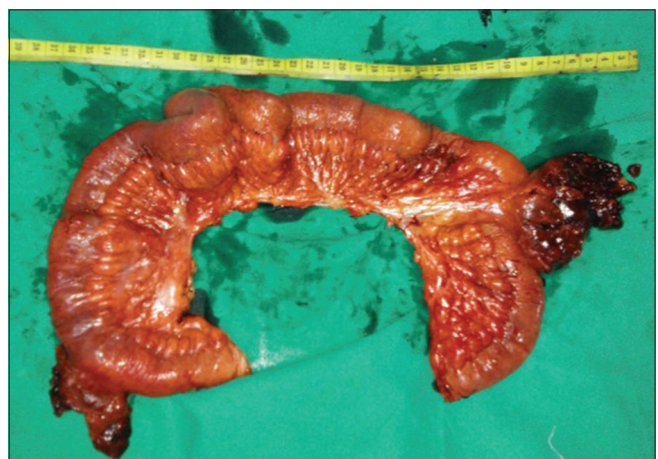

Figure 2: Resected part of the ileum showing friable mass

Table 1: Summary of the interdigitating dendritic cell sarcoma involving the intestinal tract

Author	Year	Patient age/sex	Symptoms	Site	Treatment	Outcome
Daum <i>et al.</i> ^[9]	1985	43/male	Abdominal pain anorexia	Jejunum	Resection chemotherapy	Died of disease
Miettinen <i>et al.</i> ^[10]	1993	52/female	Intestinal obstruction	Small intestine retroperitoneum mediastinum	Resection chemotherapy	Died of disease
Banner <i>et al.</i> ^[11]	1997	68/female	Abdominal distension vomiting	Cecum	Resection chemotherapy	Alive with disease 3-month follow-up
Kanaan <i>et al.</i> ^[12]	2006	36/female	Epigastric pain dysphagia vomiting	Duodenum lymphnodes liver	Resection	Died of disease
Ishihara <i>et al.</i> ^[4]	2010	47/male	Abdominal pain	Terminal ileum lymphnodes liver	Resection and chemotherapy after relapse	Free of disease 3-year follow-up and alive with disease 8-month follow-up
Shibutani <i>et al.</i> ^[13]	2010	76/male	Hematochezia mass protruding from anus	Rectum, regional and para-aortic lymph nodes	Resection adjuvant chemotherapy	Alive with disease 8-month follow-up
Nonaka <i>et al.</i> ^[14]	2011	50/male	Not mentioned	Terminal ileum multifocal lymphadenopathy	Resection	Recurrence of disease in duodenum after 3 years
Hirji <i>et al.</i> ^[15]	2017	20/male	Frequent bowel movements, weight loss, rectal bleeding	Rectum	Resection	Free of disease 18-month follow-up
Present case	2019	61/male	Abdominal pain, fever, vomiting	Terminal ileum	Resection	Free of disease 6-month follow-up

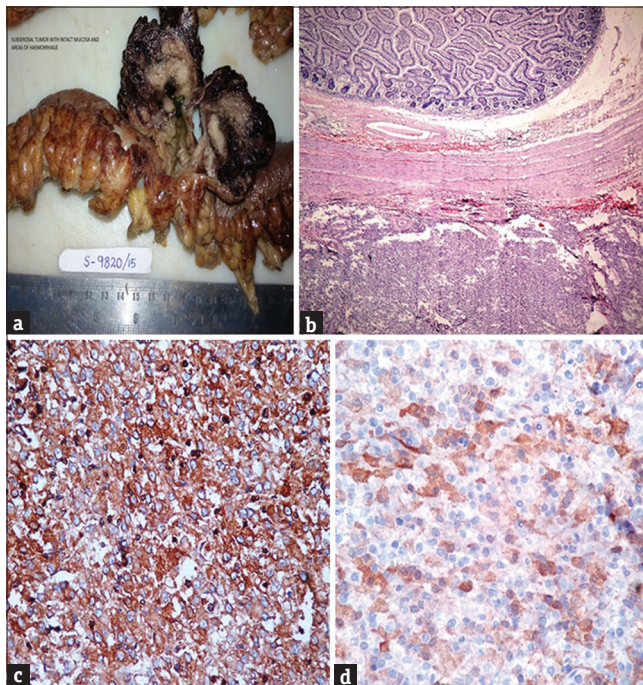


Figure 3: (a) The cut surface of the specimen revealing central white mass with surrounding hemorrhage. (b) Microscopic examination ($\times 100$) showing tumor cells scattered in subserosal aspect. (c) Immunohistochemical staining showing tumor cells are positive for leukocyte common antigen. (d) Immunohistochemical staining showing tumor cells are positive for S100

Our case report describes the first known case of IDCS of the small intestine presenting as spontaneous

hemoperitoneum. IDCS is a rare neoplasm, and extranodal IDCS is more uncommon than the nodal presentation. Besides, clinical picture and light microscopy, immunohistochemistry plays an important role in arriving at the diagnosis. Surgical resection is the mainstay of treatment for localized disease. The role of adjuvant, neoadjuvant chemotherapy, and radiotherapy in metastatic disease is still not clearly defined.

Acknowledgment

We would like to thank Dr. Vigneshwaran VB for significant contributions in copyediting the article.

Declaration of patient consent

The authors certify that they have obtained all appropriate patient consent forms. In the form the patient(s) has/have given his/her/their consent for his/her/their images and other clinical information to be reported in the journal. The patients understand that their names and initials will not be published and due efforts will be made to conceal their identity, but anonymity cannot be guaranteed.

Financial support and sponsorship

Nil.

Conflicts of interest

There are no conflicts of interest.

REFERENCES

- Han HS, Lee OJ, Lim SN, An JY, Lee KM, Choe KH, *et al.* Extranodal interdigitating dendritic cell sarcoma presenting in the pleura: A case report. *J Korean Med Sci* 2011;26:304-7.
- Saygin C, Uzunaslan D, Ozguroglu M, Senocak M, Tuzuner N. Dendritic cell sarcoma: A pooled analysis including 462 cases with presentation of our case series. *Crit Rev Oncol Hematol* 2013;88:253-71.
- Xue T, Jiang XN, Wang WG, Zhou XY, Li XQ. Interdigitating dendritic cell sarcoma: Clinicopathologic study of 8 cases with review of the literature. *Ann Diagn Pathol* 2018;34:155-60.
- Ishihara S, Honda Y, Asato T, Nonaka M, Nakagawa S, Hirashima K, *et al.* Interdigitating dendritic cell sarcoma of the ileum recurred in multiple lymph nodes and duodenum three years after operation without chemotherapy. *Pathol Res Pract* 2010;206:514-8.
- Kasotakis G. Spontaneous hemoperitoneum. *Surg Clin North Am* 2014;94:65-9.
- Madabhavi I, Patel A, Modi G, Anand A, Panchal H, Parikh S. Interdigitating dendritic cell tumor: A rare case report with review of literature. *J Cancer Res Ther* 2018;14:690-3.
- Mahamid A, Alfici R, Troitsa A, Anderman S, Groisman G, Zeina AR. Small intestine perforation due to metastatic uterine cervix interdigitating dendritic cell sarcoma: A rare manifestation of a rare disease. *Rare Tumors* 2011;3:e46.
- Olnes MJ, Nicol T, Duncan M, Bohlman M, Erlich R. Interdigitating dendritic cell sarcoma: A rare malignancy responsive to ABVD chemotherapy. *Leuk Lymphoma* 2002;43:817-21.
- Daum GS, Liepman M, Woda BA. Dendritic cell phenotype in localized malignant histiocytosis of the small intestine. *Arch Pathol Lab Med* 1985;109:647-50.
- Miettinen M, Fletcher CD, Lasota J. True histiocytic lymphoma of small intestine. Analysis of two S-100 protein-positive cases with features of interdigitating reticulum cell sarcoma. *Am J Clin Pathol* 1993;100:285-92.
- Banner B, Beauchamp ML, Liepman M, Woda BA. Interdigitating reticulum-cell sarcoma of the intestine: A case report and review of the literature. *Diagn Cytopathol* 1997;17:216-22.
- Kanaan H, Al-Maghrabi J, Linjawi A, Al-Abbassi A, Dandan A, Haider AR. Interdigitating dendritic cell sarcoma of the duodenum with rapidly fatal course: A case report and review of the literature. *Arch Pathol Lab Med* 2006;130:205-8.
- Shibutani M, Teraoka H, Nakao S, Tamamori Y, Nitta A, Chikugo T. A case of interdigitating dendritic cell sarcoma of the rectum. *Jap J Gastroenterol Surg* 2010;43:857-62.
- Nonaka K, Honda Y, Gushima R, Maki Y, Sakurai K, Iyama K, *et al.* Narrow-band imaging of interdigitating dendritic cell sarcoma originating in the duodenum. *Endoscopy* 2011;43 Suppl 2 UCTN: E113-4.
- Hirji SA, Senturk JC, Hornick J, Sonoda T, Bleday R. A rare case of interdigitating dendritic cell sarcoma of the rectum: Review of histopathology and management strategy. *BMJ Case Rep* 2017;2017:bcr 2017221754.