



OPEN ACCESS

Trousseau's sign and QT prolongation in hypocalcaemia

Jack Schnur, Hadeer Sinawe, Athina Lidia Yoham, Damian Casadesus

Internal Medicine, Jackson Memorial Hospital, Miami, Florida, USA

Correspondence to
Dr Damian Casadesus;
dcasadesus@hotmail.com

Accepted 26 February 2021

DESCRIPTION

A 65-year-old woman presented to the hospital with severe weakness, muscle cramps and lower extremity contractures. She had a medical history of hypertension, atrial fibrillation and heart failure with preserved ejection fraction. She also had amiodarone-induced thyrotoxicosis with multinodular substernal goitre with subsequent thyroidectomy without parathyroid tissue implant in the forearm, performed 8 months earlier. The patient mentioned recent emotional instability, difficulty performing activities of daily living and depression. She was taking metoprolol, diltiazem, apixaban, levothyroxine and furosemide. Physical examination revealed Trousseau's sign while taking her blood pressure (video 1). Her total calcium level was 5.8 mg/dL (normal range (NR) 8.4–10.2), ionised calcium 2.96 mg/dL (NR 4.52–5.28), 25-hydroxyvitamin D 24.0 ng/mL (59.9 nmol/L, considered insufficient <30 ng/mL), parathyroid hormone less than 1.0 pg/mL (NR 15.0–65.0), thyroid-stimulating hormone (TSH) 2.66 mIU/mL (NR 0.27–4.2), magnesium 1.2 mg/dL (NR 1.7–2.2), potassium 3.4 mmol/L (NR 3.6–5.0) and creatinine 1.3 mg/dL (NR 0.52–1.04). ECG showed sinus rhythm with QT interval prolongation, and chest radiograph showed pulmonary oedema.

The patient was diagnosed with symptomatic hypocalcaemia secondary to postsurgical hypoparathyroidism. She started treatment with calcium gluconate 3 g intravenous at admission followed by 1 g intravenous every 12 hours, calcium carbonate 2000 mg orally every 6 hours and calcitriol 3 µg orally every 6 hours. The weakness, muscle cramps and extremity contractures resolved within the first 24 hours. She received treatment for hypokalaemia and hypomagnesaemia. Furosemide, which is associated with hypokalaemia, hypomagnesaemia and hypocalcaemia, was changed to hydrochlorothiazide during the admission. The absence of parathyroid hormone leads to hypocalcaemia and hypercalciuria. Hydrochlorothiazide is greatly beneficial in the treatment of this patient because it decreases the urinary calcium and increases the serum calcium.

The patient's length of hospitalisation was 72 hours, and at the time of discharge, the creatinine was normal. The hypokalaemia, hypomagnesaemia and pulmonary oedema resolved. The ECG showed a normal QT interval, her ionised calcium was 4.76 mg/dL and calcium level was 8.5 mg/dL. The patient was discharged home and continues treatment with furosemide 40 mg orally daily, potassium supplements, calcitriol 2 µg orally every 8 hours

and calcium carbonate 1000 mg orally two times per day.

Trousseau's sign is common in the setting of hypocalcaemia. It is observable as a carpopedal spasm induced by ischaemia secondary to the inflation of a sphygmomanometer to 20 mmHg over the systolic blood pressure for 3 min. In our patient, it was observed in hypocalcaemia secondary to postsurgical hypoparathyroidism and worsened with furosemide. Chvostek's sign, also observed in hypocalcaemia, was not observed in our patient. However, it is absent in about one-third of patients with hypocalcaemia.^{1–3}

In contrast with two previous reported cases, our patient also had QT prolongation, emotional instability and depression.^{1–3} QT prolongation is associated with hypocalcaemia, as well as with hypomagnesaemia and hypokalaemia. Hypocalcaemia can cause psychological symptoms, particularly emotional instability, anxiety, depression and less common hallucinations and psychosis. After 8 months of follow-up with the same treatment, she is asymptomatic, she has normal calcium levels and she can perform all her activities of daily living.

Acknowledgements We would like to acknowledge the important role and assistance of nurse Monica Cozar during the diagnosis and treatment of the patient.

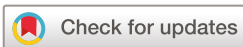Contributors JS and DC designed the case presentation and were involved in the clinical management. JS and HS obtained and edited the video. JS, DC, AY and HS have been involved in drafting the manuscript and editing final version.

Patient's perspective

"I was really surprised that the doctor could make the correct diagnosis of my medical condition just observing my hand while taking my blood pressure and my leg contracture. My symptoms improved rapidly after they started treatment."

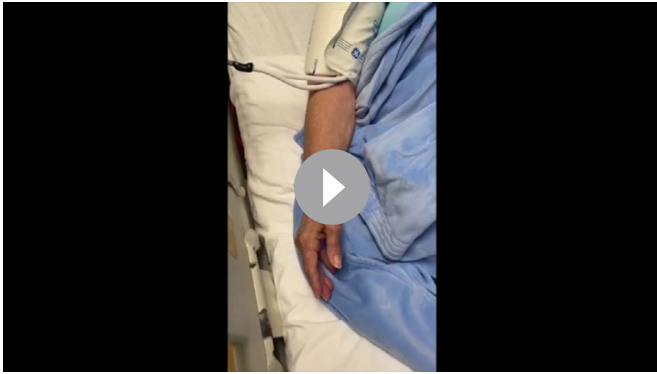
Learning points

- ▶ Trousseau's sign is caused by hypocalcaemia.
- ▶ Resolution of Trousseau's sign occurs after effective treatment of hypocalcaemia secondary to postsurgical hypoparathyroidism with active vitamin D and calcium.
- ▶ Other signs and symptoms such as QT prolongation and emotional instability can be present in hypocalcaemia resolving with the correct treatment.



© BMJ Publishing Group Limited 2021. Re-use permitted under CC BY-NC. No commercial re-use. See rights and permissions. Published by BMJ.

To cite: Schnur J, Sinawe H, Yoham AL, et al. *BMJ Case Rep* 2021;**14**:e240260. doi:10.1136/bcr-2020-240260



Video 1 Trousseau's sign observed during the inflation of a sphygmomanometer.

Funding The authors have not declared a specific grant for this research from any funding agency in the public, commercial or not-for-profit sectors.

Competing interests None declared.

Patient consent for publication Obtained.

Provenance and peer review Not commissioned; externally peer reviewed.

Open access This is an open access article distributed in accordance with the Creative Commons Attribution Non Commercial (CC BY-NC 4.0) license, which permits others to distribute, remix, adapt, build upon this work non-commercially, and license their derivative works on different terms, provided the original work is properly cited and the use is non-commercial. See: <http://creativecommons.org/licenses/by-nc/4.0/>.

REFERENCES

- 1 van Busse BCT, Koopmans RP. Trousseau's sign at the emergency department. *BMJ Case Rep* 2016;2016:bcr2016216270.
- 2 Jesus JE, Landry A. Images in clinical medicine. Chvostek's and Trousseau's signs. *N Engl J Med* 2012;367:e15.
- 3 Kamalanathan S, Balachandran K, Parthan G, *et al*. Chvostek's sign: a video demonstration. *Case Rep Child Ment Hosp Chic* 2012;2012:bcr2012007098.

Copyright 2021 BMJ Publishing Group. All rights reserved. For permission to reuse any of this content visit <https://www.bmj.com/company/products-services/rights-and-licensing/permissions/>
BMJ Case Report Fellows may re-use this article for personal use and teaching without any further permission.

Become a Fellow of BMJ Case Reports today and you can:

- ▶ Submit as many cases as you like
- ▶ Enjoy fast sympathetic peer review and rapid publication of accepted articles
- ▶ Access all the published articles
- ▶ Re-use any of the published material for personal use and teaching without further permission

Customer Service

If you have any further queries about your subscription, please contact our customer services team on +44 (0) 207111 1105 or via email at support@bmj.com.

Visit casereports.bmj.com for more articles like this and to become a Fellow