



Case report

Acute fatal group A Streptococcal primary peritonitis following vaginal delivery



Mohamed Aziz Daghmouri^{a,*}, Fatma Zahra Affes^b, Alia Jebri^a, Raja Boussassi^a,
Sonia Ben Hamouda^b, Badreddine Bouguerra^b, Mohamed Houissa^a

^a Department of Anesthesia, Charles Nicolle Hospital, Tunis, Tunisia

^b Department of Gynecology, Charles Nicolle Hospital, Tunis, Tunisia

ARTICLE INFO

Article history:

Received 6 February 2020

Received in revised form 19 February 2020

Accepted 19 February 2020

Keywords:

Group A streptococcus

Primary peritonitis

Streptococcal toxic syndrome

Vaginal delivery

ABSTRACT

Acute primary peritonitis due to group A streptococci (GAS) is a rare but life-threatening disease most often seen in case of liver cirrhosis or nephrotic syndrome. The specific mechanism of this infection remains unknown and according to the literature hematogenous, lymphatic, retrograde inoculation from the genitourinary tract and translocation of intestinal tract flora have all been proposed. We report a case of a 37-year-old previously healthy patient who presented to the emergency, four days after vaginal delivery, with abdominal pain and septic shock. Acute peritonitis was diagnosed and peritoneal and blood culture revealed group A streptococci. Unfortunately, the patient died within 12 h despite adequate resuscitation and antimicrobials. The present case report highlights the importance of an early diagnosis with an adequate therapy in case of GAS peritonitis after vaginal delivery.

© 2020 Published by Elsevier Ltd. This is an open access article under the CC BY-NC-ND license (<http://creativecommons.org/licenses/by-nc-nd/4.0/>).

Introduction

Group A Group A streptococcus (GAS), also known as *streptococcus pyogenes*, generally causes mild infections, the most frequently observed ones are pharyngitis and impetigo. However, the incidence of GAS infection is increasing according to several studies and their presentation are becoming more severe [1,2]. Streptococcal toxic syndrome which is considered as a rare and dramatic manifestation of GAS infection, could present as primary peritonitis in previous healthy patient complicated by a septic shock with multiple organ failure [3]. We present a rare case of an unusual acute primary peritonitis due to GAS following vaginal delivery in 37-year-old previously healthy patient, in order to highlight the importance of an early good diagnostic in addition to the initiation of an adequate therapy on time with the aim to improve the prognosis which is poor most of the times.

Case presentation

A 37-year-old patient (Parity 3, Gestation 2), without a significant medical history, was admitted four days after spontaneous vaginal delivery of twins with lateral episiotomy. Serologic testing of HIV and hepatitis in addition to vaginal swabs and urine

culture were done during pregnancy and were negative. Immediate post-partum period was uneventful and she was discharged after 24 h without any history of illness in her children.

On admission, she presented with nonspecific abdominal pain and septic shock. Axillary temperature was 36 °C. Blood pressure was 80/30 mmHg and she had tachycardia 130/min in addition to marbling and cold limbs. Abdominal ultrasound revealed free intra-abdominal fluid. Fluid resuscitation was started rapidly in addition to the use of catecholamine (The dose of noradrenaline used was from 0.5 µg/kg/min to a maximum of 2 µg/kg/min). She was tachypneic with a respiratory rate of 30 cycle/min. An unspecific bowel infection was suspected and broad-spectrum antimicrobial treatment with imipenem 1 g, amikacin 20 mg/kg and teicoplanin 400 mg was initiated. Blood test revealed a hemoglobin level of 9.2 g/dL, leukocytes 1540 × 10³/µL [3], platelet count 104000/µL, C-reactive protein 340 mg/dL, creatinine 1.92 mg/dL, albumin 1.2 g/dL, in addition to cytolysis (ALT 120 UI/L and AST 146 UI/L) and cholestasis. Blood gas revealed a metabolic acidosis (pH = 7.12) with high arterial lactate levels of 8.9 mmol/L. The SOFA score was 9.

Emergency exploratory laparotomy was performed. On exploration, there was a large amount of purulent fluid with global venous congestion. However, inspection of the bladder, the uterus, the adnexa and the bowel were without abnormality or any iatrogenic injury. The appendix was macroscopically normal. Lavage of the peritoneal cavity was done and pelvic drain was left in place. Mesenteric ischemia was suspected so heparin 50 mg was

* Corresponding author.

E-mail address: Aziz.daghmouri@gmail.com (M. Aziz Daghmouri).

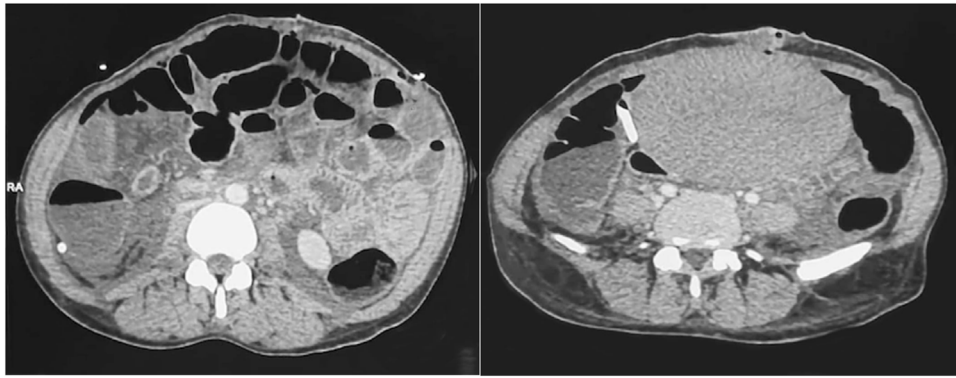


Fig. 1. CT-scan of the abdomen showing intraperitoneal free fluid with paralytic ileus but without any sign of arterial or venous thrombosis.

administered and post operatively a CT scan of the abdomen was performed. It revealed intraperitoneal free fluid with paralytic ileus but without any sign of arterial or venous thrombosis. Fluid culture in addition to blood culture were positive for group A streptococci

Post operatively and after the achievement of CT scan (Fig. 1), the patient was transferred to the intensive care unit. Despite all efforts, she remained in septic shock with multiorgan failure and disseminated intravascular coagulation and died within 12 h after admission.

Discussion

We present an unusual case of acute primary peritonitis due to group A streptococci following vaginal delivery. This type of peritonitis is caused by a mechanism which is not completely understood, however there are some hypotheses that have suggested hematogenous infection routes, retrograde inoculation from genitourinary tract or increased translocation of intestinal bacteria [4]. In addition to those, some factors would predispose to the development of primary peritonitis like liver cirrhosis, immunosuppression or nephrotic syndrome, but it could also be seen in young and healthy individuals [5].

In the last decades, an increase of gram-positive bacteria has been noted at the expense of gram-negative one as a cause of primary peritonitis. Although Lancefield group A streptococci, which were typically the cause of pharyngitis, endocarditis or erysipelas, are rarely associated with life threatening primary peritonitis [2,6]. According to the previous case reports published, there is a clear predominance of healthy and young females (aged between 30 and 40 years), so ascending infection from genitourinary tract must be considered as the first entry site to suspect [7–9]. However, there are other potential entry sites like for example the upper respiratory tract or skin lesions, but in many cases, the source of GAS infection remained unknown [10].

Concerning the clinical presentation, the vast majority of patient described in the literature presented on admission severe abdominal pain with high fever and secondary peritonitis was suspected [11]. However, the portal of entry was difficult to be deduced based on the symptoms or physical examination, but in our case, it was probably the genital tract because of the previous vaginal delivery. Although, it remains unclear whether surgical exploration of the abdominal cavity is beneficial or not, especially, for patient with negative CT scan where secondary peritonitis could not be excluded [12,13]. Rimawi et al. [14] showed that surgical treatment is beneficial in order to treat the streptococcal toxic shock syndrome and it could explain the high rate of exploratory surgery in young patients with acute onset of peritonitis. Thus, in some cases and in order to prevent from

surgery, GAS peritonitis could be treated with antibiotics but a rapid antigen detection test should be considered [15]. However, Gisser et al. [16] reported that despite an early intravenous antibiotics there was no improvement in their patients without surgery. Antimicrobial therapy should be initiated rapidly [15] but according to the literature there are few information in addition to little consensus concerning the adequate antibiotic regimens which should be used in case of GAS peritonitis [4]. For uncomplicated GAS infection, penicillin is recommended because it is well known that GAS are sensitive to beta-lactam antimicrobial [17], however in case of septic patient, broad-spectrum anti-microbials will be used and for example in our case, an association of imipenem, amikacin and teicoplanin was used.

Conclusion

We present a rare case of an acute primary peritonitis due to group A streptococci following vaginal delivery in a young and healthy patient complicated with septic shock and streptococcal toxic shock syndrome. Despite of surgical treatment in addition to the broad-spectrum antibiotics, it had a lethal outcome within 12 h. The genitourinary tract should be considered as the main entry site in GAS infection especially on post-partum period and timely adequate therapy should be initiated.

Authors contribution

Dr Mohamed Aziz Daghmouri: Initial diagnostics and treatment of the patient and case report manuscript

Dr Fatma Zahra Affes: Initial diagnostics and treatment of the patient and case report manuscript

Dr Alia Jebri: Initial diagnostics and treatment of the patient

Dr Raja Boussassi: Initial diagnostics and treatment of the patient

Dr Sonia Ben Hamouda: Initial diagnostics and treatment of the patient

Dr Baddredine Bouguerra: Initial diagnostics and treatment of the patient

Dr Mohamed Houissa: Initial diagnostics and treatment of the patient

Availability of data and material

Not applicable

Ethics approval

Not applicable

Consent

We have a signed consent.

Consent for publication

a consent was signed by a member of her family

Funding

we don't have any external funding.

Declaration of Competing Interest

No conflicts of interest

Acknowledgements

we would like to express our appreciation to our department team for their valuable assistance

References

- [1] Stevens DL. Streptococcal toxic-shock syndrome: spectrum of disease, pathogenesis, and new concepts in treatment. *Emerging Infect Dis*. sept 1995;1(3):69–78.
- [2] Lamagni TL, Darenberg J, Luca-Harari B, Siljander T, Efstratiou A, Henriques-Normark B, et al. Epidemiology of severe *Streptococcus pyogenes* disease in Europe. *J Clin Microbiol* 2008;46(july (7)): 2359–67.
- [3] Stevens DL. Group a streptococcal Sepsis. *Curr Infect Dis Rep* 2003;5(october (5)):379–86.
- [4] Solomkin JS. Evaluating evidence and grading recommendations: the SIS/IDSA guidelines for the treatment of complicated intra-abdominal infections. *Surg Infect (Larchmt)*. 2010;11(june (3)):269–74.
- [5] Martin J, Murchan S, O'Flanagan D, Fitzpatrick F. Invasive Group A streptococcal disease in Ireland, 2004 to 2010. *Euro Surveill* 2011;13(october (41)): 16.
- [6] Luca-Harari B, Darenberg J, Neal S, Siljander T, Strakova L, Tanna A, et al. Clinical and microbiological characteristics of severe *Streptococcus pyogenes* disease in Europe. *J Clin Microbiol* 2009;47(april (4)):1155–65.
- [7] Tilanus AMR, de Geus HRH, Rijnders BJA, Dwarkasing RS, van der Hoven B, Bakker J. Severe group A streptococcal toxic shock syndrome presenting as primary peritonitis: a case report and brief review of the literature. *Int J Infect Dis* 2010;3(september 14 Suppl):e208–212.
- [8] Moskovitz M, Ehrenberg E, Grieco R, Chamovitz B, Burke M, Snyder D, et al. Primary peritonitis due to group A streptococcus. *J Clin Gastroenterol* 2000;30(april (3)):332–5.
- [9] Vuilleumier H, Halkic N. Streptococcal toxic shock syndrome revealed by a peritonitis. Case report and review of the literature. *Swiss Surg* 2001;7(1):25–7.
- [10] Westwood DA, Roberts RH. Management of primary group A streptococcal peritonitis: a systematic review. *Surg Infect (Larchmt)*. avr 2013;14(2):171–6.
- [11] Malota M, Felbinger TW, Ruppert R, Nüssler NC. Group A Streptococci: a rare and often misdiagnosed cause of spontaneous bacterial peritonitis in adults. *Int J Surg Case Rep* 2015;6(January):251–5.
- [12] Bray S, Morgan J. Two cases of group A streptococcal vulvovaginitis in premenopausal adults in a sexual health setting. *Sex Health*. sept 2006;3(3):187–8.
- [13] Kanetake K, Hayashi M, Hino A, Futamura N, Mori Y, Takagi H, et al. Primary peritonitis associated with streptococcal toxic shock-like syndrome: report of a case. *Surg Today* 2004;34(12):1053–6.
- [14] Rimawi BH, Soper DE, Eschenbach DA. Group A streptococcal infections in obstetrics and gynecology. *Clin Obstet Gynecol* 2012;55(4):864–74 december.
- [15] Little P, Hobbs FDR, Moore M, Mant D, Williamson I, McNulty C, et al. Clinical score and rapid antigen detection test to guide antibiotic use for sore throats: randomised controlled trial of PRISM (primary care streptococcal management). *BMJ* 2013;347(October):f5806.
- [16] Gisser JM, Fields MC, Pick N, Moses AE, Sruogo I. Invasive group a streptococcus associated with an intrauterine device and oral sex. *Sex Transm Dis* 2002;29(8) 483–5 August.
- [17] Walker MJ, Barnett TC, McArthur JD, Cole JN, Gillen CM, Henningham A, et al. Disease manifestations and pathogenic mechanisms of Group A Streptococcus. *Clin Microbiol Rev* 2014;27(2):264–301 April.