



CLINICAL PRACTICE ARTICLE

REVISED Minimally invasive (flapless) crown lengthening by erbium:YAG laser in aesthetic zone [version 3; peer review: 2 approved]

Saverio Capodiferro , Angela Tempesta, Luisa Limongelli, Giuseppe Barile, Daniela Di Venere, Massimo Corsalini 

Interdisciplinary Department of Medicine, University of Bari, Bari, Italy

V3 First published: 30 Sep 2020, 9:1185
<https://doi.org/10.12688/f1000research.26008.1>
 Second version: 22 Jan 2021, 9:1185
<https://doi.org/10.12688/f1000research.26008.2>
 Latest published: 01 Mar 2021, 9:1185
<https://doi.org/10.12688/f1000research.26008.3>

Abstract

Crown lengthening is a surgical procedure aimed at exposure of a larger tooth surface by gingivectomy alone or with cortical bone remodelling for aesthetic purposes in the anterior zone of the maxilla or for reconstruction of teeth affected by subgingival caries. We report two cases of crown lengthening in the anterior maxilla for aesthetic purposes by gingival and bone re-contouring performed by erbium-doped yttrium aluminium garnet (erbium:YAG) laser. As highlighted in this report, the erbium:YAG laser-assisted crown lengthening is less invasive and also leads to faster clinical outcomes in contrast to the conventional surgical technique by scalpel incision, flap elevation and osteoplastic.

Keywords

flap-less crown lengthening, Erbium:YAG laser; smile line

Open Peer Review

Reviewer Status  

	Invited Reviewers	
	1	2
version 3 (revision) 01 Mar 2021		 report
		
version 2 (revision) 22 Jan 2021		 report
		
version 1 30 Sep 2020	 report	 report

1. **Rada T. Kazakova** , Medical University of Plovdiv, Plovdiv, Bulgaria

2. **Nasim Chiniforush** , Tehran University of Medical Sciences, Tehran, Iran

Any reports and responses or comments on the article can be found at the end of the article.

Corresponding author: Saverio Capodiferro (capodiferro.saverio@gmail.com)

Author roles: **Capodiferro S:** Conceptualization, Investigation, Methodology; **Tempesta A:** Writing – Original Draft Preparation, Writing – Review & Editing; **Limongelli L:** Data Curation, Writing – Review & Editing; **Barile G:** Data Curation, Investigation, Methodology; **Di Venere D:** Supervision, Validation, Writing – Review & Editing; **Corsalini M:** Supervision, Writing – Review & Editing

Competing interests: No competing interests were disclosed.

Grant information: The author(s) declared that no grants were involved in supporting this work.

Copyright: © 2021 Capodiferro S *et al.* This is an open access article distributed under the terms of the [Creative Commons Attribution License](#), which permits unrestricted use, distribution, and reproduction in any medium, provided the original work is properly cited.

How to cite this article: Capodiferro S, Tempesta A, Limongelli L *et al.* **Minimally invasive (flapless) crown lengthening by erbium:YAG laser in aesthetic zone [version 3; peer review: 2 approved]** F1000Research 2021, 9:1185 <https://doi.org/10.12688/f1000research.26008.3>

First published: 30 Sep 2020, 9:1185 <https://doi.org/10.12688/f1000research.26008.1>

REVISED Amendments from Version 2

Minimal changes have been introduced accordingly to the last reviewer report.

Any further responses from the reviewers can be found at the end of the article

Introduction

Several clinical situations may require dental crown lengthening (CL) such as irregular smile line, gummy smile, decayed or fractured teeth, worn out teeth by parafunction habits (e.g. bruxism)^{1,2}. Regardless of aesthetic or functional purpose, the conventional technique of CL involves scalpel incision, flap elevation and bone remodeling by burns, with or without adjunctive gingivectomy, the latter essentially related to the gingival biotype^{3,4}. Despite the excellent clinical outcome, the conventional surgical technique may be more invasive depending on the severity of the clinical situation as well patient’s general health condition (e.g. medically compromised patients or in therapy with anticoagulant drugs). Many alternatives techniques for CL have been reported in literature but it is generally accepted that the least invasive are the laser-assisted techniques^{5,6}. Of these, the erbium:YAG laser has the advantage to work on both hard (bone) and soft tissues (gingiva)⁷. We report on 2 cases treated by a mini-invasive erbium:YAG laser-assisted procedure (including gingiva and bone re-contouring) for CL in the anterior maxilla.

Cases presentation

Case 1

The patient was a 53 y.o. Caucasian woman with an no relevant medical history who was unemployed at the time of presentation (March, 2015). She presented an abundant gingiva covering tooth 1.2 which she wished to remove for aesthetical purposes (Figure 1a,b). Gingival remodeling and bone re-contouring by erbium:YAG laser was suggested. A small amount of anesthesia was injected locally (0.9 ml of mepivacaine cloridrate 2%, 1:100,000 epinephrine) after which the gingiva was remodeled by laser (Key Laser 3-Kavo s.r.l.-Italy) in de-focalized modality

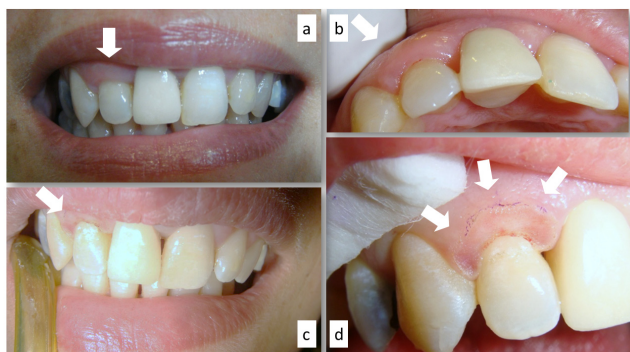


Figure 1. Alteration of the smile line related to the abundant gingiva of tooth 1.2 (a,b); gingival remodelling by erbium-doped yttrium aluminium garnet (erbium:YAG) laser and its immediate clinical appearance (c,d).

(not in contact free beam tip, 180 mJ/10 Hz, poor water emission) until the dental crown was sufficiently exposed according to the patient smile line (Figure 1c,d). After one week (Figure 2a), a second procedure was performed to re-contour the marginal bone by the same laser, using a surgical tip (optical prism scalpel-like tip of 01x10mm, 120 mJ/10 Hz, abundant water emission) in contact modality and through the gingival sulcus (flap-less); a light bleeding occurred during the procedure (Figure 2b). The gingival margin was completely healed, and the smile line appeared significantly improved 12 days after surgery (Figure 2c).

Case 2

This 47 y.o. Caucasian housewife who presented in April 2016 with severe abrasion of the anterior teeth related to bruxism over a long duration (Figure 3a). Her medical history was un-remarkable. No pain and/or teeth hyper-sensibility were indicated by the patient, however, she was unhappy with her smile. A laser-assisted CL of the lateral and central incisors was planned to re-define a new marginal gingiva profile. After local injection of anesthesia, (1,8 ml of mepivacaine cloridrate 2%, 1:100,000 epinephrine), the marginal gingiva was careful recontoured by erbium:YAG laser (Key Laser 3-Kavo s.r.l.-Italy) (not in contact

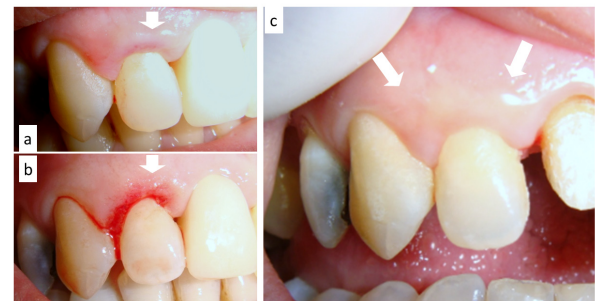


Figure 2. Second step after seven days (a); flapless (through the gingival sulcus) bone re-contouring by erbium-doped yttrium aluminium garnet (erbium:YAG) laser (b) and its clinical appearance after 12 days (c).

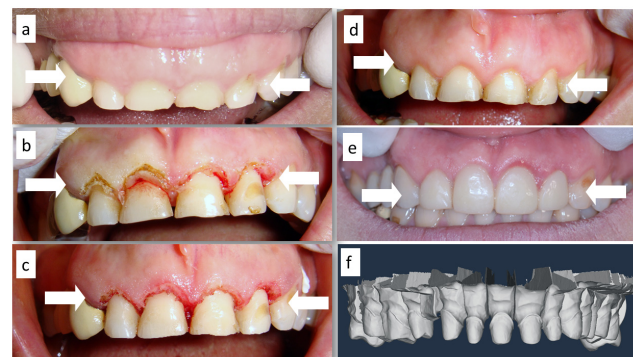


Figure 3. Severe abrasion of incisors due to bruxism (a); erbium-doped yttrium aluminium garnet (erbium:YAG) laser-assisted gingivectomy (b) and contextual flapless bone remodelling (c); the clinical appearance after 14 days (d), the teeth preparation as appearing on computer-aided design and the following prosthetic rehabilitation (e,f).

free beam tip, 180 mJ/10 Hz, poor water emission) till an adequate teeth exposure (Figure 3b,c); subsequently, the cortical bone was-remodeled by a surgical tip (optical prism scalpel-like tip of 01x10mm, 160 mJ/10 Hz, abundant water emission) on both aspects of the maxilla through the gingival sulcus without flap elevation (Figure 3d). After 14 days, gingival tissues appeared healed and teeth prepared for the following prosthetic restoration by cemented metal-ceramic crowns. (Figure 3e,f).

Discussion

Several medical devices have been proposed to make CL less invasive, including piezosurgery^{4,8}. Several lasers such as diode, neodymium-doped yttrium aluminum garnet (Nd:YAG), potassium titanyl phosphate (KTP), CO₂, Erbium, chromium-doped yttrium, scandium, gallium and garnet (Er,Cr:YSGG) and erbium:YAG are widely used for CL^{1,2,6,9}. However, the main difference between these is their capability to work exclusively on soft or hard or both tissues^{3,9,10}. Diode, Nd:YAG, KTP and CO₂ lasers may be useful when only gingival remodeling alone is necessary and this is essentially related to their surgical capabilities, especially contextual cuts and coagulation^{2,9,11,12}. In fact, they are generally suggested for many surgical and non-surgical procedures in the oral cavity (frenectomy/frenulotomy, vestibuloplasty, mucosal biopsy, treatment of tooth hyper-sensitivity, benign, potentially malignant and malignant lesions removal, surgical and not-surgical periodontal treatments including drug-related gingival overgrowth, photocoagulation of venous malformations, etc), but not for bone treatments¹²⁻¹⁹. When both gingival and bone remodelling is required, instead, the choice necessarily must fall on Er,Cr:YSGG or erbium:YAG lasers thanks to their selectivity for water, resulting in the capability to work by ablation on hard tissues as tooth and bone^{10,11,20,21}.

Therefore, such lasers can be used for dental cavity preparation, periodontal treatments, dentinal hypersensitivity, benign lesion removal, treatment of viral lesion of the oral mucosa and lip, gingival and/or bone remodelling or cutting^{7,9,10,20}. In the reported cases, authors used an erbium:YAG laser both for soft and hard tissue treatment but with different tips and output energy parameters. The excellent clinical outcomes we described in terms of minimal invasiveness, lack of intra- and post-operative complications and pain, fast and predictable healing, are essentially related to the intrinsic properties of the erbium:YAG laser light and to the generally recognized gentle laser-oral tissues interaction^{10,11,20-23}.

Conclusion

The overall clinical benefits of the erbium:YAG laser allows flapless CL to be simplified, even in difficult cases. The total absence of laser-related thermal injuries to the oral hard and soft tissues leads to highly predictable clinical results, and this is important in the treatment of the anterior teeth for aesthetic purposes. However, a good knowledge of laser-tissue interaction principles, sufficient experience on laser use and, obviously, familiarity with the general and basic guidelines of oral/periodontal surgery are mandatory to achieve desirable clinical results.

Consent

Written informed consent for publication of their clinical details and clinical images was obtained from the patient.

Data availability

Underlying data

All data underlying the results are available as part of the article and no additional source data are required.

References

- Hempton TJ, Dominici JT: **Contemporary crown-lengthening therapy: a review.** *J Am Dent Assoc.* 2010; **141**(6): 647-655.
[PubMed Abstract](#) | [Publisher Full Text](#)
- Narayanan M, Laju S, Erali SM, et al.: **Gummy Smile Correction with Diode Laser: Two Case Reports.** *J Int Oral Health.* 2015; **7**(Suppl 2): 89-91.
[PubMed Abstract](#) | [Free Full Text](#)
- Farista S, Kalakonda B, Koppolu P, et al.: **Comparing Laser and Scalpel for Soft Tissue Crown Lengthening: A Clinical Study.** *Glob J Health Sci.* 2016; **8**(10): 55795.
[PubMed Abstract](#) | [Publisher Full Text](#)
- McGuire MK, Scheyer ET: **Laser-assisted flapless crown lengthening: a case series.** *Int J Periodontics Restorative Dent.* 2011; **31**(4): 357-364.
[PubMed Abstract](#)
- Kazakova RT, Tomov GT, Kissev CK, et al.: **Histological Gingival Assessment after Conventional and Laser Gingivectomy.** *Folia Med (Plovdiv).* 2018; **60**(4): 610-616.
[PubMed Abstract](#) | [Publisher Full Text](#)
- Fekrazad R, Moharrami M, Chiniforush N: **The Esthetic Crown Lengthening by Er,Cr:YSGG laser: A Case Series.** *J Lasers Med Sci.* 2018; **9**(4): 283-287.
[PubMed Abstract](#) | [Publisher Full Text](#) | [Free Full Text](#)
- Diaci J, Gaspiric B: **Review Comparison of Er: YAG and Er Cr: YSGG lasers used in dentistry.** *J Laser Health Acad.* 2012; **2012**(1): 1-13.
[Reference Source](#)
- Lavu V, Arumugam C, Venkatesan N, et al.: **A Present Day Approach to Crown Lengthening - Piezosurgery.** *Cureus.* 2019; **11**(11): e6241.
[PubMed Abstract](#) | [Publisher Full Text](#) | [Free Full Text](#)
- Tachmatzidis T, Dabarakis N: **Technology of Lasers and Their Applications in Oral Surgery: Literature Review.** *Balkan Journal of Dental Medicine.* 2016; **20**(3): 131-137.
[Publisher Full Text](#)
- Stübinger S: **Advances in bone surgery: the Er:YAG laser in oral surgery and implant dentistry.** *Clin Cosmet Investig Dent.* 2010; **2**: 47-62.
[PubMed Abstract](#) | [Publisher Full Text](#) | [Free Full Text](#)
- Parker S: **Verifiable CPD paper: laser-tissue interaction.** *Br Dent J.* 2007; **202**(2): 73-81.
[PubMed Abstract](#) | [Publisher Full Text](#)
- Derikvand N, Chinipardaz Z, Ghasemi S, et al.: **The Versatility of 980 nm Diode Laser in Dentistry: A Case Series.** *J Lasers Med Sci.* 2016; **7**(3): 205-208.
[PubMed Abstract](#) | [Publisher Full Text](#) | [Free Full Text](#)
- Limongelli L, Tempesta A, De Caro A, et al.: **Diode Laser Photocoagulation of Intraoral and Perioral Venous Malformations After Tridimensional Staging by High Definition Ultrasonography.** *Photobiomodul Photomed Laser Surg.* 2019; **37**(11): 722-728.
[PubMed Abstract](#) | [Publisher Full Text](#)
- Capodiferro S, Limongelli L, Tempesta A, et al.: **Diode laser photocoagulation of sublingual varices in 706 patients on antithrombotic therapy without drug discontinuation.** *Ann Ital Chir.* 2020; **91**: 100-104.
[PubMed Abstract](#)

15. Capodiferro S, Limongelli L, Tempesta A, et al.: **Diode laser treatment of venous lake of the lip.** *Clin Case Rep.* 2018; **6**(9): 1923–1924.
[PubMed Abstract](#) | [Publisher Full Text](#) | [Free Full Text](#)
16. Capodiferro S, Tempesta A, Limongelli L, et al.: **Nonsurgical Periodontal Treatment by Erbium:YAG Laser Promotes Regression of Gingival Overgrowth in Patient Taking Cyclosporine A: A Case Report.** *Photomed Laser Surg.* 2019; **37**(1): 53–56.
[PubMed Abstract](#) | [Publisher Full Text](#)
17. Limongelli L, Capodiferro S, Tempesta A, et al.: **Early tongue carcinomas (clinical stage I and II): echo-guided three-dimensional diode laser mini-invasive surgery with evaluation of histological prognostic parameters. A study of 85 cases with prolonged follow-up.** *Lasers Med Sci.* 2020; **35**(3): 751–758.
[PubMed Abstract](#) | [Publisher Full Text](#)
18. Favia G, Capodiferro S, Limongelli L, et al.: **Malignant transformation of oral proliferative verrucous leukoplakia: a series of 48 patients with suggestions for management.** *Int J Oral Maxillofac Surg.* 2020; S0901-5027(20)30206-X.
[PubMed Abstract](#) | [Publisher Full Text](#)
19. Luke AM, Mathew S, Altawash MM, et al.: **Lasers: a review with their applications in oral medicine.** *J Lasers Med Sci.* 2019; **10**(4): 324–329.
[PubMed Abstract](#) | [Publisher Full Text](#) | [Free Full Text](#)
20. Harashima T, Kinoshita J, Kimura Y, et al.: **Morphological comparative study on ablation of dental hard tissues at cavity preparation by Er:YAG and Er,Cr:YSGG lasers.** *Photomed Laser Surg.* 2005; **23**(1): 52–55.
[PubMed Abstract](#) | [Publisher Full Text](#)
21. Chen CK, Wu YT, Chang NJ, et al.: **Er:YAG Laser for Surgical Crown Lengthening: A 6-Month Clinical Study.** *Int J Periodontics Restorative Dent.* 2017; **37**(2): e149–e153.
[PubMed Abstract](#) | [Publisher Full Text](#)
22. Kao RT, Dault S, Frangadakis K, et al.: **Esthetic crown lengthening: appropriate diagnosis for achieving gingival balance.** *J Calif Dent Assoc.* 2008; **36**(3): 187–91.
[PubMed Abstract](#)
23. Flax HD, Radz GM: **Closed-flap laser-assisted esthetic dentistry using Er: YSGG technology.** *Compend Contin Educ Dent.* 2004; **25**(8): 622, 626, 628–30 passim.
[PubMed Abstract](#)

Open Peer Review

Current Peer Review Status:  

Version 3

Reviewer Report 02 March 2021

<https://doi.org/10.5256/f1000research.54289.r80423>

© 2021 Chiniforush N. This is an open access peer review report distributed under the terms of the [Creative Commons Attribution License](#), which permits unrestricted use, distribution, and reproduction in any medium, provided the original work is properly cited.



Nasim Chiniforush 

Dental Implant Research Center, Dentistry Research Institute, Tehran University of Medical Sciences, Tehran, Iran

The article in this format is acceptable for indexing.

Competing Interests: No competing interests were disclosed.

Reviewer Expertise: photodynamic therapy, laser surgery, photobiomodulation, hard tissue surgery, soft tissue surgery

I confirm that I have read this submission and believe that I have an appropriate level of expertise to confirm that it is of an acceptable scientific standard.

Version 2

Reviewer Report 26 January 2021

<https://doi.org/10.5256/f1000research.54007.r77858>

© 2021 Chiniforush N. This is an open access peer review report distributed under the terms of the [Creative Commons Attribution License](#), which permits unrestricted use, distribution, and reproduction in any medium, provided the original work is properly cited. The author(s) is/are employees of the US Government and therefore domestic copyright protection in USA does not apply to this work. The work may be protected under the copyright laws of other jurisdictions when used in those jurisdictions.



Nasim Chiniforush 

Dental Implant Research Center, Dentistry Research Institute, Tehran University of Medical

Sciences, Tehran, Iran

- The unit for energy should be mJ not MJ.
- What does poor emission mean? Give exact amount of water irrigation.
- The country of laser device should be added.
- It's better to add this citations:
 - Fekrazad R, Moharrami M, Chiniforush N. The Esthetic Crown Lengthening by Er;Cr:YSGG laser: A Case Series. *J Lasers Med Sci*. 2018 Fall;9(4):283-287. doi: 10.15171/jlms.2018.50. Epub 2018 Sep 17. PMID: 31119024; PMCID: PMC6499554.¹
 - Flax HD, Radz GM. Closed-flap laser-assisted esthetic dentistry using Er:YSGG technology. *Compend Contin Educ Dent*. 2004 Aug;25(8):622, 626, 628-30 passim. PMID: 15456127.²

References

1. Fekrazad R, Moharrami M, Chiniforush N: The Esthetic Crown Lengthening by Er;Cr:YSGG laser: A Case Series. *Journal of Lasers in Medical Sciences*. 2018; **9** (4): 283-287 [Publisher Full Text](#)
2. Flax HD, Radz GM: Closed-flap laser-assisted esthetic dentistry using Er:YSGG technology. *Compend Contin Educ Dent*. 2004; **25** (8): 622, 626, 628-30 passim [PubMed Abstract](#)

Competing Interests: No competing interests were disclosed.

Reviewer Expertise: photodynamic therapy, laser surgery, photobiomodulation, hard tissue surgery, soft tissue surgery

I confirm that I have read this submission and believe that I have an appropriate level of expertise to confirm that it is of an acceptable scientific standard, however I have significant reservations, as outlined above.

Author Response 27 Jan 2021

saverio capodiferro, University of Bari, Bari, Italy

Dear Reviewer, thank you for your suggestions. Changes (MJ with mJ, adding of references and Country of laser device as suggested) will be performed accordingly in the next version. With regard to the water emission, I'm very sorry but it is impossible to identify correctly the quantity as limitation of the laser device. Thank you again.

Competing Interests: None

Version 1

Reviewer Report 03 December 2020

<https://doi.org/10.5256/f1000research.28703.r72300>

© 2020 Chiniforush N. This is an open access peer review report distributed under the terms of the [Creative Commons Attribution License](#), which permits unrestricted use, distribution, and reproduction in any medium, provided the original work is properly cited.



Nasim Chiniforush

Dental Implant Research Center, Dentistry Research Institute, Tehran University of Medical Sciences, Tehran, Iran

- In two cases please add pulse duration of laser device you used for each purpose and laser tip diameter and length.
- You can add some more information about the advantages of erbium lasers.
- It's better to add case report in title of your manuscript.
- This article after minor revision can be acceptable for indexing.

Is the background of the cases' history and progression described in sufficient detail?

Yes

Are enough details provided of any physical examination and diagnostic tests, treatment given and outcomes?

Yes

Is sufficient discussion included of the importance of the findings and their relevance to future understanding of disease processes, diagnosis or treatment?

Yes

Is the conclusion balanced and justified on the basis of the findings?

Yes

Competing Interests: No competing interests were disclosed.

Reviewer Expertise: photodynamic therapy, laser surgery, photobiomodulation, hard tissue surgery, soft tissue surgery

I confirm that I have read this submission and believe that I have an appropriate level of expertise to confirm that it is of an acceptable scientific standard, however I have significant reservations, as outlined above.

Author Response 15 Jan 2021

saverio capodiferro, University of Bari, Bari, Italy

Thank you very much. Changes have been made accordingly.

Competing Interests: No competing interests were disclosed.

Reviewer Report 17 November 2020

<https://doi.org/10.5256/f1000research.28703.r72302>

© 2020 Kazakova R. This is an open access peer review report distributed under the terms of the [Creative Commons Attribution License](#), which permits unrestricted use, distribution, and reproduction in any medium, provided the original work is properly cited.



Rada T. Kazakova 

Department of Prosthetic Dentistry, Faculty of Dental Medicine, Medical University of Plovdiv, Plovdiv, Bulgaria

Dr. Saverio Capodiferro *et al.*'s article reports two cases of a crown lengthening procedure with an Er:YAG laser. This procedure aims at exposure of a larger tooth surface usually on the anterior maxillary region by gingivectomy alone (soft tissue crown lengthening), or gingivectomy and cortical bone remodeling (hard tissue crown lengthening). The advantages of the Er:YAG method, compared to the classical scalpel one, is that it leads to a predictable outcome and a faster healing. The background of the cases' history and progression described is in sufficient detail. The authors have introduced us to the patients, their age, history of the disease and the reason why they sought for the crown lengthening procedure in particular. There is enough data provided of the examinations and diagnostic tests, treatment given and outcomes. The authors described in detail what the gingival level was, and illustrated the gingival overgrowth, the steps and the clinical outcome with excellent photos, including a CAD/CAM scan. They also added photos after the procedures and the results after the final restorations. The discussion is sufficient and it accentuates on the importance of the outcome and the better and faster healing of the Er:YAG laser crown lengthening, compared to the classical method with the scalpel. It gives much details on the wide areas of use of the different lasers, as well as a comparison between them – their advantages and disadvantages, as well as their indications and contraindications. The conclusion is balanced and summarizes the findings. One of the most important advantage of the Er:YAG laser method described is the better healing and the predictable results, which is mentioned in the conclusion. My only small recommendations for them, which are not obligatory, are the following: to change 'a small anesthesia' to 'a little bit of anesthesia' and to describe what type of anesthesia they used (e.g. terminal, intra-ligamental, etc.); 'light bleeding' – should be written without 'a'; it would be useful if they could provide the readers with some more information and the precise specification of the laser, laser mode and scalpel tip used; 'her medical history was un-remarkable' is a statement that I could not quite understand, maybe the readers need some more clarity, as well.

I congratulate the team with the good work, the efforts and the wonderful outcomes and wish them to more and more success in the future. The article is interesting and well-described. I will

definitely vote 'approved' for this article.

Is the background of the cases' history and progression described in sufficient detail?

Yes

Are enough details provided of any physical examination and diagnostic tests, treatment given and outcomes?

Yes

Is sufficient discussion included of the importance of the findings and their relevance to future understanding of disease processes, diagnosis or treatment?

Yes

Is the conclusion balanced and justified on the basis of the findings?

Yes

Competing Interests: No competing interests were disclosed.

Reviewer Expertise: Laser dentistry

I confirm that I have read this submission and believe that I have an appropriate level of expertise to confirm that it is of an acceptable scientific standard.

The benefits of publishing with F1000Research:

- Your article is published within days, with no editorial bias
- You can publish traditional articles, null/negative results, case reports, data notes and more
- The peer review process is transparent and collaborative
- Your article is indexed in PubMed after passing peer review
- Dedicated customer support at every stage

For pre-submission enquiries, contact research@f1000.com

F1000Research