

Available online at www.sciencedirect.com

journal homepage: www.elsevier.com/locate/radcr

Case Report

Case report: Use of unenhanced cardiac MR to evaluate low flow states for thrombus [☆]

Avinoam Levin, MD^a, Raphael Miller, BS^{a,*}, Nidhish Tiwari, MBBS^b, Mark Guelfguat, DO^a

^aDepartment of Radiology, Jacobi Medical Center, 1400 Pelham Pkwy S, The Bronx, NY 10461, USA

^bDepartment of Cardiology, Jacobi Medical Center, 1400 Pelham Pkwy S, The Bronx, NY 10461, USA

ARTICLE INFO

Article history:

Received 27 July 2022

Accepted 18 August 2022

Keywords:

Spontaneous echo contrast
Black blood double inversion recovery
Cardiac magnetic resonance imaging

ABSTRACT

Left atrial spontaneous echo contrast is an echocardiographic finding associated with hypercoagulable states and stasis and can be clinically correlated with a thromboembolism in patients with atrial fibrillation, mitral stenosis, or mitral valve repair. Black blood double inversion recovery cardiac magnetic resonance is used to map out cardiac anatomy and demonstrates higher signal in blood flowing at a slower rate, such as at the sites of aortic aneurysms, aortic dissections and vessel occlusions. Here, we present the case of a 66-year-old woman with persistent atrial fibrillation and left atrial findings of spontaneous echo contrast and high signal on black blood double inversion recovery cardiac magnetic resonance imaging, raising concern for a thrombus. However, this was ruled out with subsequent bright blood cardiac magnetic resonance imaging demonstrating high signal with transitory central swirling low signal in the left atrium. Thus, cardiac magnetic resonance imaging can be used to demonstrate non-thrombotic low flow states in cases where contrast is contraindicated.

© 2022 The Authors. Published by Elsevier Inc. on behalf of University of Washington.

This is an open access article under the CC BY-NC-ND license

(<http://creativecommons.org/licenses/by-nc-nd/4.0/>)

Introduction

Left atrial (LA) spontaneous echo contrast (SEC) is an echocardiographic finding that is associated with slow or occluded blood flow [1–3]. Similarly, black blood double inversion recovery (DIR) is a cardiac magnetic resonance (cMR) imaging sequence that demonstrates high signal at sites of slow or occluded blood flow. By contrast, bright blood is a cMR sequence

that demonstrates high signal at sites of normal blood flow [4]. We present a case where LA SEC and high signal black blood DIR cMR in the left atrium raised concern for occluded flow. However, high signal with central low signal swirling on bright blood sequence clarified that the former findings were due to slow rather than occluded flow. Contrast-enhanced cMR confirmed the absence of a thrombus. Therefore, black blood DIR cMR with follow-up bright blood cMR can be used to evaluate for slow or occluded blood flow where contrast is contraindicated.

[☆] Competing Interests: None.

* Corresponding author.

E-mail address: raphael.miller@einsteinmed.edu (R. Miller).

<https://doi.org/10.1016/j.radcr.2022.08.066>

1930-0433/© 2022 The Authors. Published by Elsevier Inc. on behalf of University of Washington. This is an open access article under the CC BY-NC-ND license (<http://creativecommons.org/licenses/by-nc-nd/4.0/>)

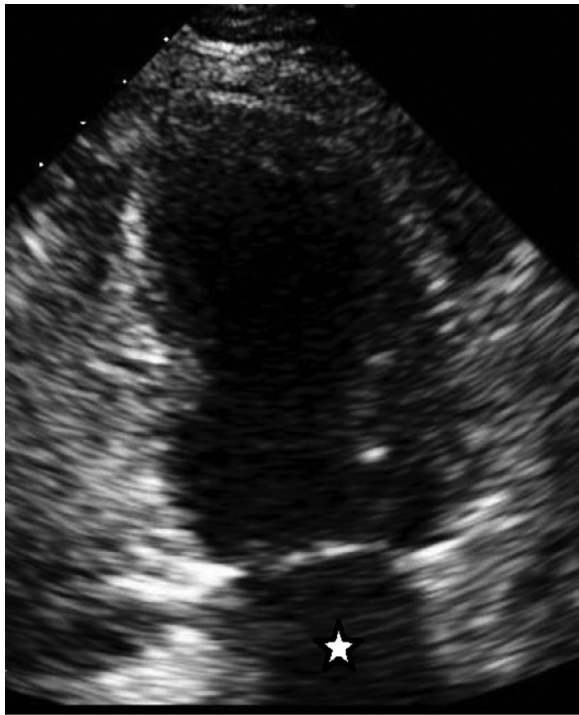

Fig. 1 – Subcostal, 2-chamber echocardiographic view. Diffuse low-level intraluminal echoes are demonstrated, consistent with “smoke” artefact in the markedly dilated LA (white star).

Case report

A 66-year-old woman presented to her cardiologist for follow-up visit. She had a history of persistent atrial fibrillation (confirmed by Holter monitor 1 year prior), chronic kidney disease (stage 3), severe asthma, hypertension, hyperlipidemia, and bilateral total knee replacements. On examination, the patient reported fatigue, chronic orthopnea, intermittent wheezing, dyspnea on minimal exertion, and chest tightness on exertion that would improve with rest. Her medication regimen included Rivaroxaban, Losartan/Hydrochlorothiazide, Digoxin, Rosuvastatin, Lasix, and Diltiazem.

Due to her symptoms, the patient underwent a TTE which showed marked LA dilation with presence of spontaneous echo contrast (SEC) (Fig. 1). Additionally, follow-up electrocardiogram confirmed that the patient was still in atrial fibrillation. She was also tested for coronary artery disease with a pharmacological stress test with myocardial perfusion imaging utilizing Regadenoson. The stress test showed no evidence of ischemia or infarct and calculated the left ventricular ejection fraction as 54% with stress and 47% at rest.

Images from cMR with sequences that included black blood DIR, bright blood, and intravenous contrast-enhanced were obtained. Black blood DIR sequence demonstrated high signal in the LA (Fig. 2), consistent with slow or occluded flow. However, bright blood sequence displayed high signal with central swirling low signal in the LA (Fig. 3), indicating slow flow rather than occluded flow. Bright blood cMR also confirmed

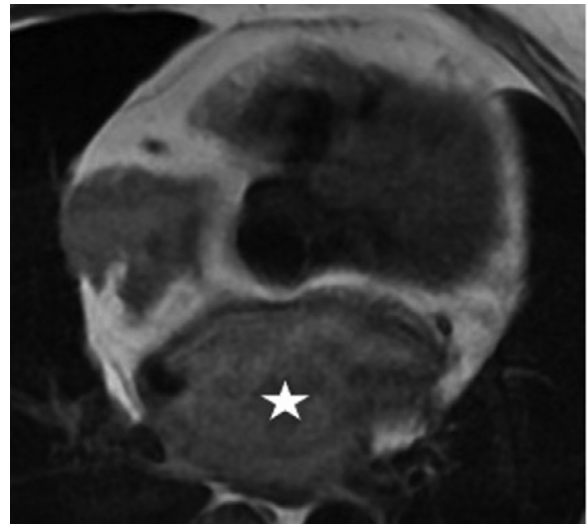


Fig. 2 – cMR black blood DIR axial image. High signal flow is demonstrated filling the entire LA (white star).

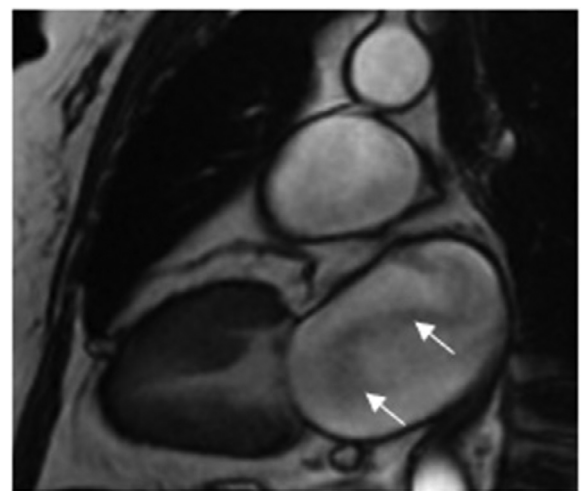


Fig. 3 – cMR bright blood vertical long axis view. Severe LA enlargement is demonstrated. Additionally, the entire lumen is filled with bright signal intraluminal blood. Also noted is swirling low signal intensity inflow of pulmonary venous blood in the LA lumen (white arrows).

the marked dilation of her LA. Finally, the intravenous contrast enhanced sequence confirmed the lack of an intraluminal thrombus (Fig. 4).

She was subsequently referred to an arrhythmia clinic. There, she was put on a Holter monitor, which showed atrial fibrillation with a maximum heart rate of 188 beats per minute, extended periods of rapid ventricular response, and an average heart rate of 89 beats per minute. Ablation was discussed, but due to her severely dilated atria, she was at high risk of reverting back to atrial fibrillation. Instead, her medication regimen was optimized by ceasing the Losartan-HCTZ and Diltiazem and starting Losartan and Diltiazem CD. She was subsequently lost to follow-up.

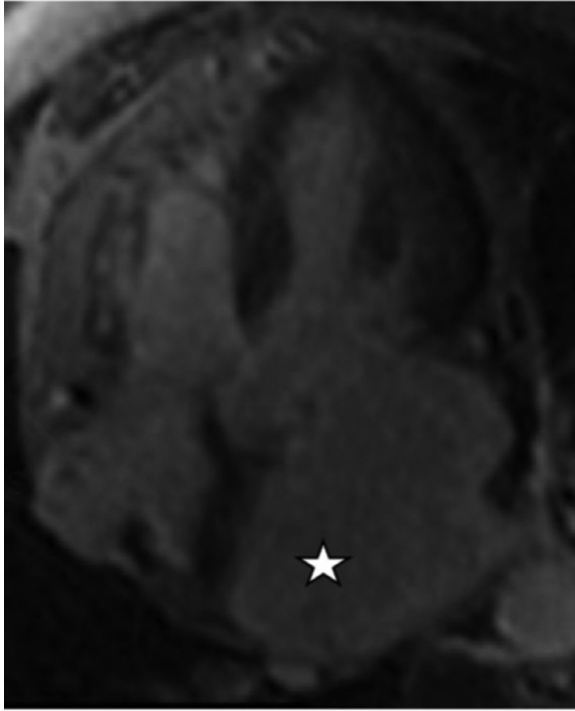


Fig. 4 – cMR horizontal long axis view with delayed gadolinium enhancement. Filling of the LA cavity with contrast-enhanced blood (white star) is demonstrated, confirming lack of intraluminal thrombus. Left ventricular myocardial enhancement is normal.

Discussion

LA SEC is an echocardiographic finding characterized by smoke-like swirling in the LA cavity. It is associated with hypercoagulable states and stasis and considered a predictor for past and future thromboembolism in patients with atrial fibrillation, mitral stenosis, or mitral valve repair [1–3]. Indeed, one study of 78 patients with SEC found that SEC was the only significant correlate of LA thrombus from among almost a dozen variables [5].

Black blood DIR is a cMR sequence in which blood flowing at a normal rate is nulled for enhanced visibility of the internal borders of the cardiac walls [6] and atrial wall morphology [4,7]. As a result, sites of decreased or disorganized flow, including aortic aneurysms, aortic dissections, vessel occlusions, and atrial fibrillation, paradoxically demonstrate increased signal on black blood DIR [6]. By contrast, bright blood is a cMR sequence that does not null normal velocity blood flow and therefore demonstrates high signal at sites of normal blood flow [4].

In this patient, the findings from the black blood DIR cMR of diffusely high intraluminal signal raised concern for a large thrombus filling the entire LA cavity. However, the possibility of a thrombus was effectively ruled out by the presence of high signal completely occupying the LA on bright blood cMR imaging. Still, consistent with the black blood findings of low blood flow in the LA, the bright blood sequence also demonstrated

central swirling, low signal blood inflow from the pulmonary veins. Therefore, the findings on cMR, using black blood DIR and bright blood sequences, indicated slow flowing, but not thrombosed, blood in the LA.

The absence of a LA thrombus was later confirmed in our patient by utilizing a contrast-enhanced cMR sequence. Indeed, contrast-enhanced cMR is significantly better at identifying cardiac thrombi than bright blood cMR [8,9]. However, where contrast cannot be administered, such as in patients with chronic kidney failure, bright blood sequencing can be helpful for evaluating possible LA thrombi [10].

Also, the radiographically determined finding of slow flow in the LA was supported and explained by persistent atrial fibrillation on both electrocardiography and Holter monitor.

This case demonstrates that high signal black blood DIR pooling on cMR is analogous to SEC on TTE, in that they both indicate slow or occluded blood flow. Therefore, in cases where cMR contrast is contraindicated, black blood DIR cMR can be utilized to evaluate a suspicion for a slow flow state or thrombus. Additionally, resulting high signal black blood findings can be concerning for a thrombus but can be further evaluated by use of bright blood sequencing. As a result, while cMR is not traditionally considered a first line modality for evaluating low flow states, it can be used when necessary as a surrogate for SEC and to differentiate between low flow states and thrombi by using a combination of black blood DIR and bright blood sequences.

Conclusion

Cardiac magnetic resonance imaging can be used to demonstrate non-thrombotic low flow states and rule out thrombosis. Black blood DIR sequence can be used to demonstrate a low flow state and bright blood sequence can confirm the absence of a thrombus. This finding is especially important in cases where first line intravenous contrast studies cannot be performed due to contraindication or otherwise.

Patient consent

Written informed consent for publication was provided by the discussed patient.

REFERENCES

- [1] Black IW, Hopkins AP, Lee LC, Walsh WF. Left atrial spontaneous echo contrast: a clinical and echocardiographic analysis. *J Am Coll Cardiol* 1991;18(2):398–404.
- [2] Black IW, Stewart WJ. The role of echocardiography in the evaluation of cardiac source of embolism: left atrial spontaneous echo contrast. *Echocardiography* 1993;10(4):429–39.
- [3] Patel A, Au E, Donegan K, Kim RJ, Lin FY, Stein KM, et al. Multidetector row computed tomography for identification of left atrial appendage filling defects in

- patients undergoing pulmonary vein isolation for treatment of atrial fibrillation: comparison with transesophageal echocardiography. *Heart Rhythm* 2008;5(2):253–60.
- [4] Berr SS, Roy RJ, French BA, Yang Z, Gilson W, Kramer CM, et al. Black blood gradient echo cine magnetic resonance imaging of the mouse heart. *Magn Reson Med* 2005;53(5):1074–9.
- [5] Fatkin D, Kelly RP, Feneley MP. Relations between left atrial appendage blood flow velocity, spontaneous echocardiographic contrast and thromboembolic risk in vivo. *J Am Coll Cardiol* 1994;23(4):961–9.
- [6] Edelman RR, Chien D, Kim D. Fast selective black blood MR imaging. *Radiology* 1991;181(3):655–60.
- [7] Ginami G, López K, Mukherjee RK, Neji R, Munoz C, Roujol S, et al. Non-contrast enhanced simultaneous 3D whole-heart bright-blood pulmonary veins visualization and black-blood quantification of atrial wall thickness. *Magn Reson Med* 2019;81(2):1066–79.
- [8] Weinsaft JW, Kim HW, Shah DJ, Klem I, Crowley AL, Brosnan R, et al. Detection of left ventricular thrombus by delayed-enhancement cardiovascular magnetic resonance prevalence and markers in patients with systolic dysfunction. *J Am Coll Cardiol* 2008;52(2):148–57.
- [9] Mollet NR, Dymarkowski S, Volders W, Wathiong J, Herbots L, Rademakers FE, et al. Visualization of ventricular thrombi with contrast-enhanced magnetic resonance imaging in patients with ischemic heart disease. *Circulation* 2002;106(23):2873–6.
- [10] Rustemli A, Bhatti TK, Wolff SD. Evaluating cardiac sources of embolic stroke with MRI. *Echocardiography* 2007;24(3):301–8 discussion 8.