



Case Report

Synchronous acute sub-serosal appendicitis and cholecystitis, in a patient with a long standing small bowel neuroendocrine tumor

Zuhdi Al-Nabulsi, MRCS*, Ahmed Hazem H., FRCS and Majid Bassuni, FRCS

Department of General Surgery, National Health Service Highland, Belford Hospital, Fort William, UK

Received 17 December 2020; revised 24 February 2021; accepted 8 March 2021; Available online 6 April 2021



المخلص

هذا التقرير عن مريض في ٦٢ من عمره يعاني من ورم الغدد الصم العصبية للأمعاء الدقيقة منذ فترة طويلة مع انتشار ثابت إلى الكبد. حضر يشكو من آلام حادة في الجهة اليمنى من بطنه يصاحبها غثيان وقيء. بالاستناد إلى الفحوصات الشعاعية، تم تشخيص المريض بالتهاب المرارة المتزامن والتهاب الزائدة الدودية.

تم إجراء جراحة لاستئصال كل من الزائدة الدودية والحوصلة المرارية بالمنظار سويًا حيث أكد فحص الأنسجة للعضوين المستأصلين لاحقًا التهابهما أوليًا دون وجود أي أثر سرطاني. تعافى المريض بعدها بسلاسة وتركزت الخطة العلاجية ما بعد العملية على متابعة علاج ورم الغدد الصم العصبية في الأمعاء الدقيقة وتقييم العلاج التلطيفي المتبع منذ سنوات.

من النادر جدا تزامن كلا الالتهابين، حيث لا يوجد سبب مؤكد خلفه. بناء على المراجعة التي أجريتها للمنشورات العلمية، تم تسجيل ١١ حالة التهاب متزامن في كلا العضوين (الزائدة الدودية والحوصلة المرارية) حتى العام ٢٠١٩، ويعتقد أن تكون هذه الحالة بين أيديكم الأولى حيث يصاحب هذا التزامن ورم الغدد الصم العصبية. نهدف في هذا التقرير إلى سرد الصورة المرضية، وتحدياتها التشخيصية والخطة العلاجية المتبعة مع بعض التفاصيل من داخل العملية الجراحية المجراة.

الكلمات المفتاحية: التهاب الزائدة الدودية؛ التهاب المرارة؛ ورم الغدد الصماء العصبية؛ استئصال الزائدة الدودية بالمنظار؛ استئصال المرارة بالمنظار؛ الجراحة العامة

Abstract

We report the case of a 62-year-old retired man with a long-standing small bowel neuroendocrine tumour. He presented with right-sided abdominal pain associated with nausea and vomiting. Radiographic imaging confirmed acute appendicitis and cholecystitis. We performed a synchronous laparoscopic appendectomy and cholecystectomy in the same setting. Histopathological examination of specimens confirmed the preoperative diagnoses in both organs. Our patient recovered uneventfully. The postoperative management plan focused on continuation of the follow-up for the small bowel neuroendocrine tumour. The synchronicity of both acute cholecystitis and appendicitis is extremely uncommon. We believe that our case report is the first of its kind with synchronous inflammation of the gallbladder and appendix in a patient with neuroendocrine tumour. In this report, we aim to provide insights on managing such a condition in the background of other intra-abdominal tumours.

Keywords: Appendicitis; Cholecystitis; General surgery; Laparoscopic appendectomy; Laparoscopic cholecystectomy; Neuroendocrine tumour

© 2021 The Authors.

Production and hosting by Elsevier Ltd on behalf of Taibah University. This is an open access article under the CC BY-NC-ND license (<http://creativecommons.org/licenses/by-nc-nd/4.0/>).

* Corresponding address: Belford Hospital, Belford Road, PH336BS, UK.

E-mail: Zuhdi.al-nabulsi@nhs.net (Z. Al-Nabulsi)

Peer review under responsibility of Taibah University.



Production and hosting by Elsevier

Introduction

Acute appendicitis and cholecystitis are considered the two most common causes for surgical operations among

surgical emergencies.¹ Although they are very common, it is extremely rare for them to occur synchronously, with only 11 cases being reported by 2019.² Bacterial dislodgment was suggested behind this synchronicity, but the true aetiology remains unknown. Appendicular neuroendocrine tumours are reported to be uncommon and are usually diagnosed incidentally following histological investigations.³ On the other hand, gallbladder stones and cholecystitis are reported to be common in patients with mid-gut neuroendocrine tumours (MGNET).⁴

Case presentation

A 62-year-old retired man presented to our rural hospital while on vacation, complaining of acute right-sided abdominal pain and vomiting for a couple of days. He had long-standing small bowels neuroendocrine tumour with liver lesions which had been biopsied and diagnosed in 2003. He had been managed symptomatically with octreotide and analgesics, and had never required surgical procedures. On examination, he was afebrile with stable vital signs, but had tenderness and local guarding of the right side of his abdomen in both the upper and lower quadrants. His initial blood results were as follows: white blood cells of $13.9 \times 10^9/L$, neutrophils of $8.6 \times 10^9/L$, and C-reactive protein of 15 mg/L. He was admitted for hydration, symptomatic relief, monitoring, and imaging after being tested for coronavirus disease 2019 (COVID-19). His previous medical history included the small bowel neuroendocrine tumour, treated symptomatically using various analgesics and octreotide. His treatment and follow-up had ceased for the previous 6 months as his symptoms improved. He missed his follow-up treatment, and had run out of octreotide due to COVID-19 lockdown-related disruptions.

Investigations

On the next day, he remained symptomatic and had a significant increase in his inflammatory markers in addition to new abnormalities on his liver function tests; therefore, he received intravenous antibiotics according to local guidelines for intra-abdominal sepsis (amoxicillin and metronidazole). In view of the tenderness being more in the lower quadrant and the pre-existing MGNET, an abdominal computed tomography (CT) scan was performed which revealed inflamed retrocecal appendicitis. CT also revealed peri-cholecystic oedema and diffuse gallbladder wall thickening, suggesting inflammatory reaction near the gallbladder (Figure 1, Figure 2). The CT showed central mesenteric lymphadenopathy, with one lymph node showing a calcified rim.

Abdominal ultrasound scan (USS) was performed to confirm and differentiate cholecystitis from reactive inflammatory changes secondary to the retrocecal appendicitis, as USS is considered the appropriate initial radiological investigation for assessment of the right upper quadrant where gallbladder pathologies are suspected.⁵ USS revealed thick-walled oedematous gallbladder with multiple stones but normal duct: mainly normal common bile duct diameters (Figure 3), hypoechoic liver lesions, suggesting the known old metastasis from his neuroendocrine tumour.

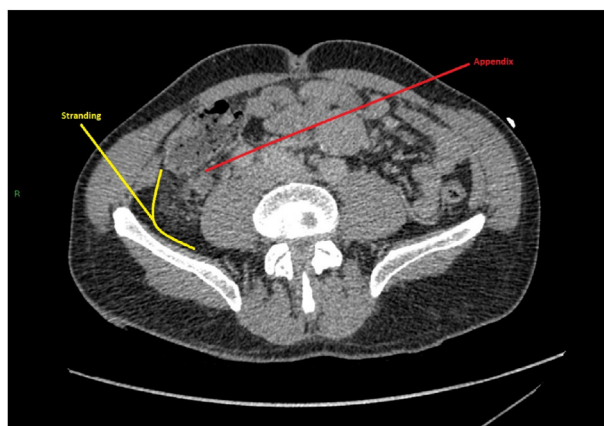


Figure 1: Abdominal CT scan axial view showing the inflamed retrocecal appendix.

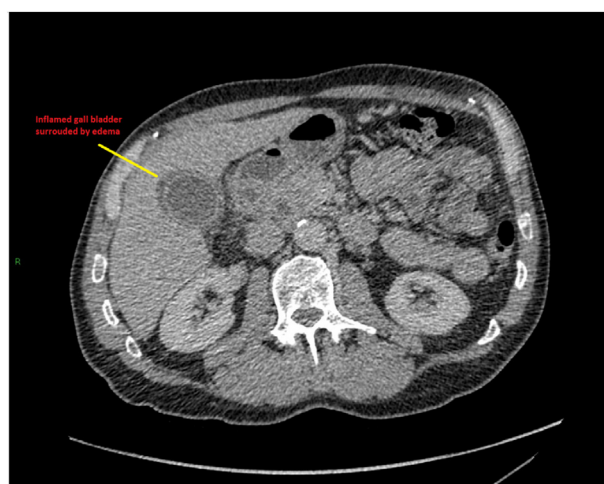


Figure 2: Abdominal CT scan axial view showing the gallbladder.

Preoperatively, he received a single 360 mg dose of gentamycin according to local guidelines, followed with

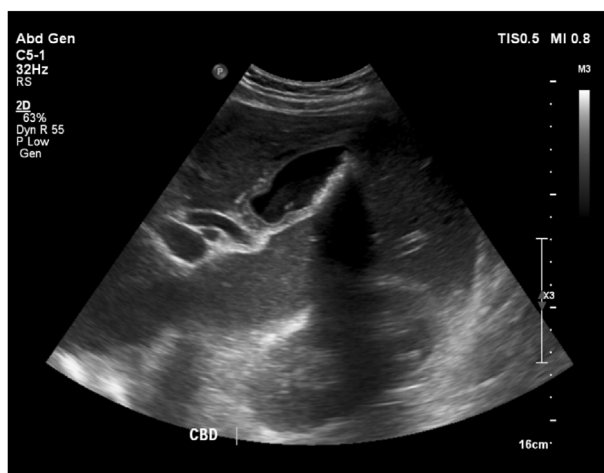

Figure 3: USS view of the gallbladder showing thickened wall and sludge.

Gentamycin levels check with a possibility to resume it depending on his prognosis.

Informed consent was obtained for exploratory laparoscopy, appendectomy and possibly cholecystectomy, especially since the patient's pain and inflammatory markers were not reverting to normal levels. He didn't consent for blood transfusion because of his religious belief.

Treatment (The procedure)

COVID-19 local protocols were followed, and diagnostic laparoscopy was performed through a central 10 mm umbilical port, followed by standard 5 mm suprapubic port and 10 mm left lower quadrant port. The exploration of the four quadrants revealed an inflamed gallbladder, some free fluid in the right lower quadrant, and multiple global hepatic focal lesions approximately 0.5–1.0 cm in size. No peritoneal or abdominal wall metastasis were seen.

The appendix was not visible, so we proceeded towards it by first positioning the patient heads down and left side tilted down. As it was retrocecal according to the CT, we proceeded to mobilise the ascending colon and laterally reflected it. Still, the appendix was not visualised despite following the taenia several times. A careful serosal dissection and mapping the convergence of the taenia coli was performed where the appendix appeared to be a retrocecal, sub-serosal buried and inflamed. The serosa was dissected of the appendix and appendectomy was resumed (Figure 4).

Attention was then diverted to the gallbladder, which was engorged, inflamed, and appeared to have formed an empyema. Three further ports were inserted: 10 mm epigastric, 5 mm right hypochondrial and 5 mm left para-median epigastric port to the left of the falciform ligament to manipulate and retract a redundant large left liver lobe (Figure 5). We turned the patient to his right side and with his head up (reverse Trendelenberg position) and rearranged the surgical team so that the assistant had the camera through the umbilical port and a fan retractor for the left lobe of the liver through the 5 mm left para-median

epigastric port. The leading surgeon had the epigastric and the right hypochondrial ports.

Standard dissection till the critical view of safety, which is considered a very safe approach for cholecystectomy, was achieved.⁶ Clipping of the cystic duct and artery, which originated from a curved right hepatic artery and was underneath an enlarged prominent lymph node, was then done.

The gallbladder was dissected from the liver bed and retrieved with its cystic artery lymph node in a bag. Unfortunately, several liver focal lesions were clearly visualised on both lobes and were assumed to be the same hypoechoic lesions detected on his liver using USS, resembling mostly metastasis from his neuroendocrine tumour. Haemostasis was achieved with negligible blood loss. Furthermore, 10 ml of 0.5% Bupivacaine was flushed into the cystic bed, and a right-sided drain was inserted into the sub-hepatic Morrison pouch through the right-sided 5 mm hypochondrium port.

We did not take any biopsy specimens from the hepatic lesions to avoid possible difficult-to-control bleeding. Those lesions were also believed to be secondary to his neuroendocrine primary tumour diagnosed in 2003, hence a formal multi-disciplinary team approach (MDT) was suggested for him to be followed-up locally at his treatment centre (> 400 miles away) and arranged by his general practitioner (GP). No further investigation specific to the neuroendocrine tumour were organised at our centre.

Outcome and follow-up

Both the appendix and the gallbladder with its cystic artery lymph node were sent for histological examination, because of the patient's pre-existing neuroendocrine tumour. Both samples showed inflammation in each organ. Macroscopically, the appendix was inflamed with fibrinous exudates covering most of its surface, while the gallbladder had biliary gravels inside with thickening of the wall up to 4 mm. Microscopically, both samples showed signs of inflammation with focal ulceration but no signs of dysplasia or invasive malignancy.

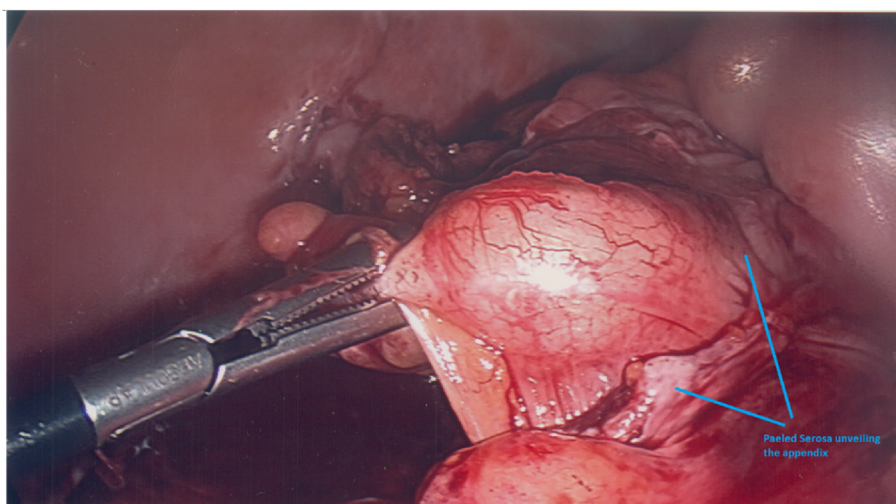
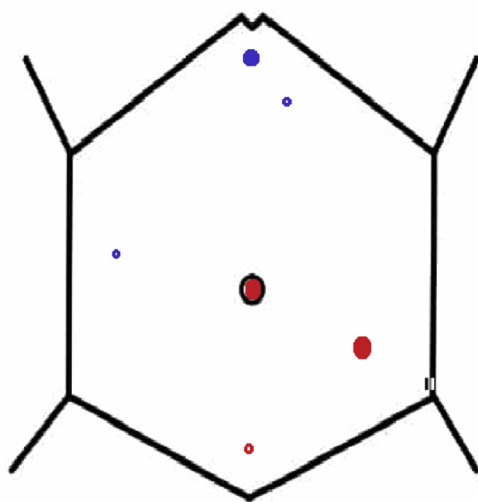


Figure 4: Intraoperative view of the appendix; some of the serosa peeled off.

Laparoscopic Ports Mapping: Al-Nabulsi et al, Synchronus Acute Appendicitis and Cholecystitis in a patient with long standing small bowels carcinoid tumour.



Red Ports: Were inserted 1st for the appendectomy, 2X10 mm umbilical and left Iliac fossa, 5mm suprapubic Port.
Blue Ports: 10mm epigastric, 5mm right hypochondrium, 5mm epigastric left sided was added to retract a redundant left liver lobe.

Figure 5: Laparoscopic ports mapping (Illustrated by Z Al-Nabulsi using Microsoft Paint).

Overall, our patient, who had a good physiological reserve and a World Health Organization Performa status of 2, recovered quickly and did very well several hours after the operation. He was able to resume oral intake and oral antibiotics for further 3 days. He was encouraged to eat and drink, and was discharged on day 2 post-operation, as he was well enough to resume his vacation.

Discussion

Synchronicity backgrounds

In 2019, a literature review of the synchronicity of acute appendicitis with acute cholecystitis found only 11 reported cases; this reflects how uncommon this phenomenon is.¹ The report indicated that the average age of patients who had this condition was 52.3 years, which is significantly higher than the mean age of patients undergoing primary appendectomy; nearly 70% of them were <30 years old, with teenagers being the most common age group to undergo primary appendectomy.⁷ Meanwhile, the mean age of having cholecystectomy was reported to range from early fifties to seventies, depending on many demographic variables^{8,9}. The causes behind this synchronicity remain unknown but it was suggested that a bacterial infection of the gallbladder originating from an inflamed gangrenous appendicitis leading to gallbladder dyskinesia might be one of the causes. We believe that this is difficult to prove as this phenomenon is extremely rare or might be underreported, which does not allow further analysis to identify possible etiologies.¹⁰

Symptoms of this uncommon synchronous phenomena are reported to be either upper abdominal pain or right-sided abdominal pain, and to a lesser extent, diffuse or central abdominal pain.² Both abdominal CT scans and USS are used as diagnostic modalities; both investigations were used in our case during the acute course of the clinical presentation. In all reported cases, the patients underwent acute standard surgical treatment or conservative treatment with a view of interval laparoscopic scheduled intervention.^{2,11}

Our patient who presented with acutely inflamed, retrocecal, and sub-serosal appendix was 62 years, which is not a common age for this presentation but a common one for cholecystitis. He had a hot cholecystectomy which was considered following the diagnostic laparoscopy, as this is considered safe and cost-effective if symptoms lasted less than 5 days as was in this case.⁵ This was successfully achieved in our surgical encounter. A common umbilical camera port was used for both procedures. Other cholecystectomy ports were fashioned accordingly to the intraoperative findings.

More on imaging

The Royal College of Surgeons emergency general surgery commissioning guide advises the use of a CT scan in any persistent acute abdominal pain in patients aged 50 and above. CT scans are also considered invaluable in cases of intra-abdominal sepsis and obstruction.⁵ Hence, in our case, a CT scan was prioritised as our patient, who we knew had a neuroendocrine tumour, suffered from acute right-sided abdominal pain with significant elevation of his inflammatory markers. On the other hand, in standard circumstances the National Institute for Health and Care Excellence (NICE) guidelines recommend USS if confirmation of cholecystitis is needed.¹²

An USS was needed to confirm calculi cholecystitis due to the complexity of the case, as the typical symptoms and signs of cholecystitis were not present. The gall bladder wall thickening with the peri-cholecystic fluid on the CT was not sufficient on its own, given a confirmed diagnosis of retrocecal appendicitis. Several studies suggest that CT scans are more sensitive than USS in detecting cholecystitis.¹³ Despite the suggested superiority of the CT scans, a study concluded that USS remains more sensitive in detecting gallstones. The same study also reported that patients who undergo both diagnostic investigations are mostly male with complex medical history and in whom the classic signs of cholecystitis are absent.¹⁴

A watchful waiting approach was adopted initially in accordance with the guidelines of the Association of Upper Gastrointestinal Surgery of Great Britain and Ireland (AUGIS), which suggested treating cholecystitis conservatively during crisis periods such as COVID-19 except when the patients were deemed septic or had empyemas confirmed by USS.¹⁵ Post operatively, triple antibiotics were deescalated and switched to oral administration for another 3 days due to intraoperative surgical findings of peri-cholecystic fluids and early empyema formation. The drain was removed after 24 h.

Neuroendocrine related cholecystitis and appendicitis

Neuroendocrine tumours which are mostly found in the gastrointestinal tract are commonly found in the small intestines twice as often as they are found in the appendix which is considered the second most common site.¹⁶ Octreotide, which is commonly used to manage carcinoid syndromes, increases patients' risk of developing gallbladder stones and cholecystitis. Hence a prophylactic cholecystectomy is advised if patients are to undergo surgical management for their gastrointestinal neuroendocrine tumours, where management plans includes octreotide.⁴

Appendicular neuroendocrine tumours are the most common type of appendicular primary tumours where acute appendicitis is the most common presentation of primary appendicular tumours. Secondary metastatic appendicular tumours are not as common as primary, but they are reported to arise commonly from a colorectal source. Synchronous colorectal appendicular metastasis and neuroendocrine tumours are reported in 10% of secondary appendicular tumours of colorectal origins.¹⁷ In our case, intraoperative exploration did not reveal any possible primary or secondary sites except during the cholecystectomy where an enlarged cystic lymph node was found and retrieved in addition to the obvious liver surface focal seeded lesions. Both specimens were retrieved carefully and there were neither primary nor secondary appendicular tumours as revealed by histopathological examinations. The patient was discharged back to his GP with plans for referral to an endocrinology MDT for further management.

COVID-19 implications

The four royal Colleges of surgeons assessed the impact of COVID-19 on all acute surgical admissions and stressed the use of personal PPE equipment, in line with Public Health England guidelines. Laparoscopic procedures were identified as a procedure carrying some risk for aerosol type infections but the level of the risk has not been clearly defined. On the other hand, general anaesthesia is a well identified aerosol-generating procedure where PPE is strongly advised. Hence, there was no reluctance in our case to use full PPE during procedures.¹⁸

Conclusion

We presented a case of synchronous acute sub-serosal appendicitis and cholecystitis in a patient diagnosed with long-standing small bowels neuroendocrine tumour. Both the appendix and gallbladder pathology showed only acute inflammatory processes. Emergency laparoscopic appendectomy and cholecystectomy for concurrent acute appendicitis and acute cholecystitis appeared to be safe and efficient procedures. Furthermore, the interpretation of both intraoperative and radiological findings are of importance in concurrent conditions where it is easy to miss hidden pathologies intraoperatively in view of this synchronicity. One example

is our buried sub-serosal appendix in view of the easily found inflamed gallbladder.

Source of funding

This research did not receive any specific grant from funding agencies in the public, commercial, or not-for-profit sectors.

Conflict of interest

The authors have no conflict of interest to declare.

Ethical approval

This is to state that this work has obtained all ethical approvals needed, which is primarily the patient's consent. This was obtained in writing twice; peri-operatively and after writing the manuscript which was reviewed and approved by the patient himself dated on 29/October/2020.

Authors' contribution

ZAN, AHH and MB conceptualised and designed the report, while ZAN wrote the manuscript, produced the illustrations and got the patient's consent. AHH and MB edited and revised the manuscript. MB was the main surgeon, ZAN was the 2nd Surgeon, and AHH provided advice and logistic support. All authors have critically reviewed and approved the final draft and are responsible for the content and similarity index of the manuscript.

Acknowledgment

Many thanks to Enjy Bassuni for linguistic editing and review.

References

1. Ramsay G, Wohlgeut JM, Jansen JO. Emergency general surgery in the United Kingdom: a lot of general, not many emergencies, and not much surgery. *J Trauma Acute Care Surg* 2018; 85(3): 500–506. <https://doi.org/10.1097/TA.0000000000002010>.
2. Buhamed F, Edward M, Shuaib A. Synchronous acute appendicitis and acute cholecystitis, is it a myth or reality? A literature review. *Open Access Emerg Med* 2019. <https://doi.org/10.2147/oaem.s214161>.
3. Barut B. Carcinoid tumors of appendix presenting as acute appendicitis. *Turkish J Trauma Emerg Surg* 2018. <https://doi.org/10.5505/tjtes.2018.99569>.
4. Norlén O, Hessman O, Stålberg P, Åkerström G, Hellman P. Prophylactic cholecystectomy in midgut carcinoid patients. *World J Surg* 2010; 34(6): 1361–1367. <https://doi.org/10.1007/s00268-010-0428-1>.
5. Anderson I, Barrow E, Lees N, Epstein J, Tierney G, Cameron I, et al. Commissioning guide: emergency general surgery (acute abdominal pain). *R Coll Surg* 2017; (July 2017): 1–31. file:///C:/Users/user/Downloads/Commissioning_guide_EGS_Published_v3.pdf.
6. Strasberg SM, Brunt LM. Rationale and use of the critical view of safety in laparoscopic cholecystectomy. *J Am Coll Surg* 2010. <https://doi.org/10.1016/j.jamcollsurg.2010.02.053>.

7. Addiss DG, Shaffer N, Fowler BS, Tauxe RV. The epidemiology of appendicitis and appendectomy in the United States incidental appendectomies are commonly performed at the time of other abdominal or pelvic surgery to prevent future appendicitis (16). Because the epidemiology of incidental ap **Am J Epidemiol** 1990; 132(5): 910–925.
8. Alves KR, Goulart AC, Ladeira RM, de Oliveira IRS, Benseñor IM. Frequência de colecistectomia e fatores de risco sociodemográficos e clínicos associados no estudo ELSA-Brasil. **Sao Paulo Med J** 2016; 134(3): 240–250. <https://doi.org/10.1590/1516-3180.2015.0250130216>.
9. Matsui Y, Hirooka S, Yamaki S, Kotsuka M, Kosaka H, Yamamoto T, et al. Assessment of clinical outcome of cholecystectomy according to age in preparation for the “Silver Tsunami”. **Am J Surg** 2019; 218(3): 567–570. <https://doi.org/10.1016/j.amjsurg.2019.01.021>.
10. Gandhi J, Tan J. Concurrent presentation of appendicitis and acute cholecystitis: diagnosis of rare occurrence. **BMJ Case Rep** 2015. <https://doi.org/10.1136/bcr-2014-208916>.
11. Lee TY, Chang HM, Shih ML, Chen TW, Hsieh CB, Chan DC, et al. Successful nonsurgical treatment for synchronous acute cholecystitis and acute appendicitis: a case report and review of the literatures. **J Med Sci** 2014; 34(3): 121–122. <https://doi.org/10.4103/1011-4564.134385>.
12. Cholecystitis - acute | Topics A to Z | CKS | NICE. https://cks.nice.org.uk/topics/cholecystitis-acute/?_escaped_fragment_=evidence. Accessed October 3, 2020.
13. Wertz JR, Lopez JM, Olson D, Thompson WM. Comparing the diagnostic accuracy of ultrasound and CT in evaluating acute cholecystitis. **Am J Roentgenol** 2018. <https://doi.org/10.2214/AJR.17.18884>.
14. Fagenholz PJ, Fuentes E, Kaafarani H, Cropano C, King D, De Moya M, et al. Computed tomography is more sensitive than ultrasound for the diagnosis of acute cholecystitis. **Surg Infect** 2015; 16(5): 509–512. <https://doi.org/10.1089/sur.2015.102>.
15. AUGIS Guidelines for Biliary Disease during Crisis period. 2020;(March):1093090.
16. Modlin IM, Kidd M, Latich I, Zikusoka MN, Shapiro MD. Current status of gastrointestinal carcinoids. **Gastroenterology** 2005; 128(6): 1717–1751. <https://doi.org/10.1053/j.gastro.2005.03.038>.
17. Connor SJ, Hanna GB, Frizelle FA. Retrospective clinicopathologic analysis of appendiceal tumors from 7,970 appendectomies. **Dis Colon Rectum** 1998. <https://doi.org/10.1007/BF02236899>.
18. Updated General Surgery Guidance on COVID-19, 2nd Revision, 7th April 2020 | RCSEd. <https://www.rcsed.ac.uk/news-public-affairs/news/2020/april/updated-general-surgery-guidance-on-covid-19-2nd-revision-7th-april-2020>. Accessed October 4, 2020.

How to cite this article: Al-Nabulsi Z, H. AH, Bassuni M. Synchronous acute sub-serosal appendicitis and cholecystitis, in a patient with a long standing small bowel neuroendocrine tumor. *J Taibah Univ Med Sc* 2021;16(5):776–781.