

REVIEW ARTICLE OPEN



Gray and white matter abnormality in patients with T2DM-related cognitive dysfunction: a systemic review and meta-analysis

Teng Ma^{1,3}, Ze-Yang Li^{1,3}, Ying Yu¹, Bo Hu¹, Yu Han¹, Min-Hua Ni¹, Yu-Xiang Huang², Hao-Han Chen², Wen Wang¹ [✉], Lin-Feng Yan ¹ and Guang-Bin Cui ¹

© The Author(s) 2022

AIMS/HYPOTHESIS: Brain structure abnormality in patients with type 2 diabetes mellitus (T2DM)-related cognitive dysfunction (T2DM-CD) has been reported for decades in magnetic resonance imaging (MRI) studies. However, the reliable results were still unclear. This study aimed to make a systemic review and meta-analysis to find the significant and consistent gray matter (GM) and white matter (WM) alterations in patients with T2DM-CD by comparing with the healthy controls (HCs).

METHODS: Published studies were systemically searched from PubMed, MEDLINE, Cochrane Library and Web of Science databases updated to November 14, 2021. Studies reporting abnormal GM or WM between patients with T2DM-CD and HCs were selected, and their significant peak coordinates (x, y, z) and effect sizes (z -score or t -value) were extracted to perform a voxel-based meta-analysis by anisotropic effect size-signed differential mapping (AES-SDM) 5.15 software.

RESULTS: Total 15 studies and 16 datasets (1550 participants) from 7531 results were involved in this study. Compared to HCs, patients with T2DM-CD showed significant and consistent decreased GM in right superior frontal gyrus, medial orbital (PFCventmed. R, BA 11), left superior temporal gyrus (STG. L, BA 48), and right calcarine fissure / surrounding cortex (CAL. R, BA 17), as well as decreased fractional anisotropy (FA) in right inferior network, inferior fronto-occipital fasciculus (IFOF. R), right inferior network, longitudinal fasciculus (ILF. R), and undefined area (32, -60, -42) of cerebellum. Meta-regression showed the positive relationship between decreased GM in PFCventmed.R and MoCA score, the positive relationship between decreased GM in STG.L and BMI, as well as the positive relationship between the decreased FA in IFOF.R and age or BMI.

CONCLUSIONS/INTERPRETATION: T2DM impairs the cognitive function by affecting the specific brain structures. GM atrophy in PFCventmed. R (BA 11), STG. L (BA 48), and CAL. R (BA 17), as well as WM injury in IFOF. R, ILF. R, and undefined area (32, -60, -42) of cerebellum. And those brain regions may be valuable targets for future researches. Age, BMI, and MoCA score have a potential influence on the altered GM or WM in T2DM-CD.

Nutrition and Diabetes (2022)12:39; <https://doi.org/10.1038/s41387-022-00214-2>

INTRODUCTION

Type 2 diabetes mellitus (T2DM) has been widely regarded as a common challenge in human health. It was estimated that ~36% of the population in Asia suffered from T2DM, and the patients with T2DM in America could be double in 2050 [1, 2]. Unfortunately, T2DM is also the leading cause of a range of complications (e.g., stroke, cognitive dysfunction, and depression), which will further place a heavy burden on human health [3, 4]. Cognitive impairment is one of the most common complications of T2DM [5]. Previous study reported that a 150% increased risk of cognitive impairment in human with T2DM [6]. However, there was still a lack of reliable biomarkers in clinical practice, making early prediction and treatment of T2DM-CD difficult [7]. Further exploration of the underlying mechanism of T2DM-CD was of great significance for clinical intervention strategies and therapeutic effects [6, 8].

Recently, more and more studies have begun to focus on the potential neural mechanisms in T2DM-CD. Neuroimaging is one of the most important techniques for exploring T2DM-CD. Gray matter (GM) and white matter (WM) are two sensitive markers in neuroimaging studies, which indicate the changes in brain structure caused by T2DM [9–12].

Voxel-based morphometry (VBM) and surface-based morphometry (SBM) are two very important methods in studies exploring changes in brain GM [13]. Previous SBM study reported that patients with T2DM-CD showed the cortical/subcortical GM atrophy in thalamus, putamen, and hippocampus compared to healthy controls (HCs) [14]. Besides, it was reported that patients with T2DM-CD showed the lesser gray matter volume (GMV) in the right temporal and left occipital cortex than HCs in VBM studies [15]. In addition, study found that patients with T2DM-CD had the

¹Department of Radiology, Functional and Molecular Imaging Key Lab of Shaanxi Province, Tangdu Hospital, Fourth Military Medical University (Air Force Medical University), 569 Xinsi Road, Xi'an 710038 Shaanxi, China. ²Student Brigade, Fourth Military Medical University (Air Force Medical University), 169 Changle Road, Xi'an 710032 Shaanxi, China. ³These authors contributed equally: Teng Ma, Ze-Yang Li. ✉email: wangwen@fmmu.edu.cn; ylf8342@163.com; cuiqbtd@163.com

Received: 22 January 2022 Revised: 5 July 2022 Accepted: 15 July 2022

Published online: 15 August 2022

lower cortical thickness in temporal, parietal, frontal, and occipital regions than HCs [16]. Diffusion tensor imaging (DTI) is one of the most important techniques to explore the brain WM alterations in T2DM. The voxel-based analysis (VBA) and tract-based spatial statistics (TBSS) are two major methods based on DTI to explore the integrity of WM, the injury degree of which can be indicated by the fractional anisotropy (FA) and the mean diffusivity (MD) [17]. According to the TBSS study, patients with T2DM-CD showed the injured WM in corpus callosum (CC), left anterior limb of the internal and external capsule compared to HCs [18]. However, patients with T2DM-related amnesic mild cognitive impairment (T2DM-aMCI) had the significant decreased FA in anterior thalamic radiation (ATR), corticospinal tract (CST), cingulum, inferior fronto-occipital fasciculus (IFOF), superior longitudinal fasciculus (SLF), uncinate fasciculus (UF), and left superior longitudinal fasciculus temporal part (SLF-temp) compared to HCs [19]. Taken together, studies above have demonstrated that the GM and WM abnormalities played a crucial role in the process of T2DM-CD.

However, those findings of brain structure abnormalities in T2DM-CD in previous neuroimaging studies were heterogenous. Although previous systemic review and meta-analysis studies have explored the altered GM and WM in T2DM, significant and consistent results in T2DM-CD were still lack. Therefore, a systemic review and meta-analysis of brain structural changes in T2DM-CD is warranted. In this study, we aimed to collect the studies on GM or WM alterations between T2DM-CD and HCs, as well as explore the characteristic brain regions that could provide a target for further researches. Before making this meta-analysis, we made two hypotheses: (1) GM and the adjacent WM in specific brain regions might be damaged simultaneously, (2) brain regions involved in cognitive regulation might be impaired.

METHODS

This systemic review and meta-analysis followed the PRISMA statement checklists [20], which was showed in Supplementary Table 1. The protocols were registered in PROSPERO (CRD42021248423; CRD42021249713) (<https://www.crd.york.ac.uk/prospero/>), which were showed in Supplementary Table 2. All works were performed by two reviewers (TM and ZYL) independently, any controversial questions were consulted and solved with the third reviewer (LFY).

Systemic search and study selection

The systemic search of PubMed, MEDLINE, Cochrane Library and Web of Science Databases updated to November 14, 2021. Items used in this systemic search were showed as follows: (“diabetes mellitus, type 2” OR “type 2 diabetes” OR “NIDDM”, “T2DM” OR “diabetes mellitus, type II”) AND (“cognitive dysfunction”, “cognitive decline”, “cognitive impairment”, and “cognitive dissonance”) AND (“cerebral cortex”, “gray matter”, “VBM”, “voxel-based morphometry”, “cortical thickness”, “thickness”, “cortical thinning”, and “thinning”); (“diabetes mellitus, type 2” OR “type 2 diabetes” OR “NIDDM”, “T2DM” OR “diabetes mellitus, type II”) AND (“cognitive dysfunction”, “cognitive decline”, “cognitive impairment”, “cognitive dissonance”) AND (“white matter” OR “fractional anisotropy” OR “FA” OR “mean diffusivity” OR “MD” OR “VBA” OR “TBSS” OR “voxel-based analysis” OR “Tract-Based Spatial Statistics”) [21–23]. Detailed search strategies were showed in Supplementary Table 3. In addition, references to included studies and relevant reviews were searched as a supplement.

Inclusion criteria: (1) study reported the GM/WM abnormality in T2DM; (2) Between-group comparison of T2DM-CD and HCs; (3) study included male and female subjects (age > 18 years old); (4) reported available coordinates (x, y, z) in standard space (e.g., Montreal Neurological Institute (MNI) or Talairach (TAL)); (5) Cognitive assessments were performed in all subjects, and T2DM had lower cognitive scores than HCs. Exclusion criteria: (1) lacked HCs; (2) not adult; (3) single gender; (4) regions-of-interest

(ROI) studies; (5) lack of cognitive assessment; (6) animal studies; (7) not original studies; (8) not gray/white matter studies; (9) lack coordinate information; (10) not TBSS or VBA method.

Quality assessment, data extraction, and conversion

The quality of total 15 studies (11 GM datasets and 5 WM datasets) included was assessed by 12-point checklists, and the total score of which more than 6 was regarded as available [24, 25].

The quality assessment information of the studies included was detailed in Supplementary Table 4. General information (researchers, cognitive scales, age, disease duration, BMI, HbA1c, *P* value, and standard space) of all studies included were showed in Table 1. The detailed cognitive scores were showed in Supplementary Table 5. Significant peak coordinates (x, y, z) and effect sizes (*t* value or *z* score) of GM/WM abnormality between T2DM-CD and HCs were collected for meta-analysis. The data conversion between *t*-values and *z*-scores was performed on the SDM website (<https://www.sdmproject.com/>).

Voxel-based meta-analysis by AES-SDM

The meta-analyses of GM and WM were respectively performed in the “Gray Matter” and “Fractional Anisotropy” templates of the anisotropic effect size-signed differential mapping (AES-SDM) 5.15 software [26, 27]. This meta-analysis followed the standard processes of AES-SDM that have been explained in previous studies [28, 29], which were briefly described as follows: (1) By extracting the peak coordinates and effect sizes of GM/WM anomalies between T2DM-CD and HC, new statistical maps were recreated separately for each dataset in standard MNI map; (2) The mean map was created from the random-effects mean of the dataset maps, which was weighted by the sample size, intra-study variance, and between group heterogeneity; (3) a quantitative meta-analytic comparison of altered GM/WM was performed by calculating statistical differences in each voxel between patients with T2DM-CD and HCs; (4) the AES-SDM default parameters (Anisotropy = 1, Isotropic full width at half maximum (FWHM) = 20 mm, Probability = 0.005, Peak height threshold = 1, Extent threshold = 10 voxels) and 50-randomization test were adopted in this study [30]. The approach to pool the VBM and SBM studies into meta-analysis was shown in Supplementary Fig. 1 (https://www.nitrc.org/forum/forum.php?forum_id=3982). All significant results were visualized by MRICroGL software [31, 32].

Heterogeneity, sensitivity, and publication bias assessment

The heterogeneity between-study in main results was checked by the Q-test in SDM default, and the forest plots were visualized by R software 4.1.2 (<https://www.r-project.org/>). Whole-brain voxel-based jackknife sensitivity was performed to assess the reliability of results by repeating the same steps of main analysis and iteratively removing the included studies iteratively. It was regarded as significant and robust when the main results were reproducible for all or most of the analysis times [26]. The publication bias was checked by the Egger’s test in SDM default, which was visualized by funnel plots [33, 34].

Meta-regression analysis

Meta-regression was performed to explore the possible effect of risk factors (age, percentage of female patients, disease duration, MMSE/MoCA score, BMI, and HbA1c) on GM/WM abnormalities in T2DM-CD. The linear model meta-regression and *P* = 0.0005 were selected in this study.

RESULTS

Systemic search information and characteristics of included studies

Total 7531 results were searched from 4 databases and relevant references. The 1871 results were further removed because of duplication. The remaining 5660 results were screened with the

Table 1. General information of 15 studies included (gray and white matter).

| Study | Participants (female) | | Neuropsychology examinations | | Age means (sd.) | | P value | Disease duration (year) | Field strength (T) | T2DM HbA1c (%) | T2DM BMI (kg/m ²) | Coordinate space | Subject |
|-------------------------------|-----------------------|-----------|------------------------------|---------------------|-----------------|--------------|---------------------|-------------------------|--------------------|----------------|-------------------------------|------------------|--------------|
| | Total | T2DM | HC | HC | T2DM | HC | | | | | | | |
| Moran et al. [39] | 713 (308) | 350 (140) | 363 (168) | Other | 67.8 (6.90) | 72.1 (7.20) | 0.001 (corrected) | NA | 1.5 | 7.20 | 31.30 | NO | Gray matter |
| Li et al. [14] | 56 (35) | 28 (15) | 28 (20) | MoCA + MMSE | 56.5 (1.10) | 53.9 (1.20) | 0.05 (corrected) | 8.20 | 3.0 | 9.80 | 24.80 | MNI | Gray matter |
| Chen et al. [35] | 22 (16) | 11 (8) | 11 (8) | MMSE | 61.2 (NA) | 56.2 (NA) | 0.05 (corrected) | NA | 3.0 | 8.30 | 25.40 | MNI | Gray matter |
| Natalia et al. [42] | 50 (19) | 25 (8) | 25 (11) | MMSE + Other | 60.0 (4.60) | 57.8 (5.40) | 0.001 (uncorrected) | NA | 3.0 | 6.67 | 28.60 | TAL | Gray matter |
| Wang et al. [11] | 46 (16) | 23 (7) | 23 (9) | MoCA + MMSE + Other | 53.1 (9.60) | 53.9 (9.20) | 0.001 (uncorrected) | 7.00 | 3.0 | 8.30 | 25.90 | MNI | Gray matter |
| Yoon et al. [16] ^a | 150 (75) | 100 (50) | 50 (25) | Other | 49.2 (7.70) | 49.0 (7.80) | 0.05 (corrected) | 1.83 | 1.5 | 7.12 | 25.50 | TAL | Gray matter |
| Zhang et al. [37] | 57 (37) | 29 (17) | 28 (20) | MoCA + MMSE | 56.21 (7.69) | 52.24 (9.09) | 0.05 (corrected) | 8.18 | 3.0 | 7.78 | 24.35 | MNI | Gray matter |
| Zhou et al. [38] | 40 (20) | 21 (11) | 19 (9) | MMSE + Other | 68 (5.00) | 69 (5.00) | 0.001 (uncorrected) | 4.70 | 1.5 | 8.60 | 25.70 | TAL | Gray matter |
| Wei et al. [25] | 63 (30) | 31 (15) | 32 (15) | MMSE | 58.42 (8.42) | 55.03 (7.81) | 0.001 (uncorrected) | 5.73 | 1.5 | 6.77 | 26.30 | MNI | Gray matter |
| Duan et al. [36] | 104 (44) | 52 (18) | 52 (26) | MoCA + MMSE + Other | 54.35 (5.33) | 53.31 (4.30) | 0.05 (corrected) | 9.19 | 3.0 | 8.42 | 24.32 | MNI | Gray matter |
| Feng et al. [40] | 40 (NA) | 20 (NA) | 20 (NA) | MoCA + Other | 36.45 (3.72) | 34.05 (4.78) | 0.05 (corrected) | 3.79 | 3.0 | 9.80 | 25.41 | MNI | Gray matter |
| Cui et al. [46] | 80 (45) | 38 (18) | 42 (27) | MMSE + Other | 60.2 (7.4) | 58.2 (6.4) | 0.05 (corrected) | 9.0 | 3.0 | 8.00 | 24.90 | MNI | White matter |
| Kim et al. [43] | 40 (22) | 20 (11) | 20 (11) | Other | 54.6 (2.3) | 54.3 (2.4) | 0.05 (corrected) | 12.1 | 3.0 | 10.70 | 24.70 | MNI | White matter |
| Xiong et al. [44] | 48 (30) | 20 (12) | 28 (18) | MMSE + MoCA + Other | 63.55 (5.81) | 59.65 (5.98) | 0.01 (corrected) | 9.09 | 3.0 | 8.15 | 24.37 | MNI | White matter |
| Yau et al. [45] | 41 (20) | 24 (11) | 17 (9) | Other | 57.21 (8.05) | 56.44 (6.94) | 0.01 (corrected) | 7.94 | 1.5 | 7.83 | 32.13 | TAL | White matter |
| Yoon et al. [16] ^a | 150 (75) | 100 (50) | 50 (25) | Other | 49.2 (7.70) | 49.0 (7.80) | 0.05 (corrected) | 1.83 | 1.5 | 7.12 | 25.50 | MNI | White matter |

MMSE Mini-Mental State Examination, MoCA Montreal Cognitive Assessment, Other examinations other than the MMSE or MoCA, TAL Talairach, MNI Montreal Neurological Institute, NO Stereotaxic space, NA not available.

^aThe same study.

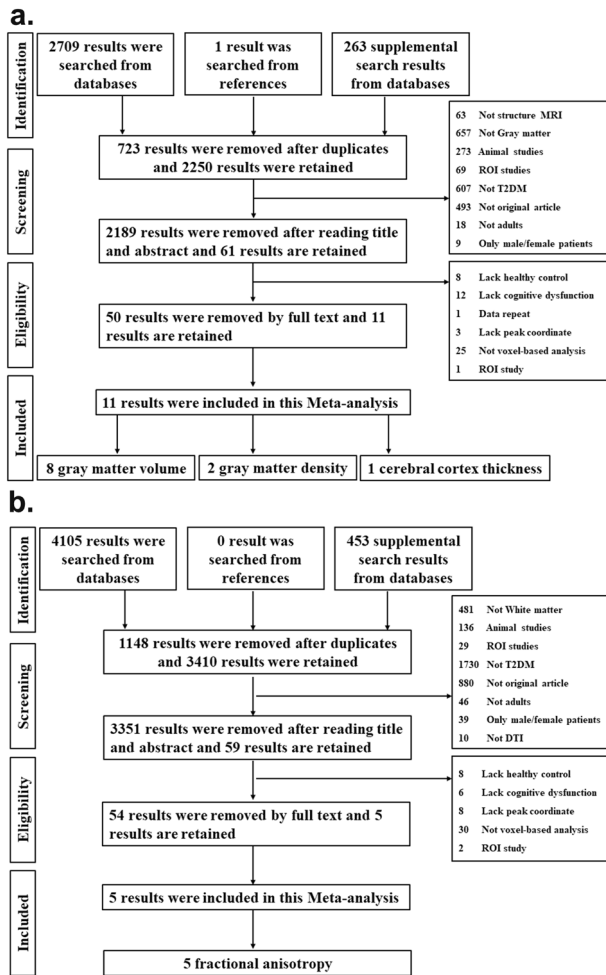


Fig. 1 Search flow diagram followed the PRISMA statement. The systemic searches were separately performed on GM (a) and WM studies (b).

title and abstract, and 5540 results of which were removed. The full-text of remained 120 results were read, and 104 results of which were removed. In the end, total 15 studies (16 datasets) meeting the inclusion criteria were included in this study, which consisted of 11 GM datasets including 7 GMV [15, 35–40], 2 gray matter density (GMD) [40–42], and 2 cerebral cortical thickness [14, 16], as well, as 5 WM datasets including 5 FA abnormality [16, 43–46]. The detailed search flow diagram was showed in Fig. 1.

GM abnormality between T2DM-CD and HCs

According to the main analysis, patients with T2DM-CD showed the significant and consistent GM reduction in right superior frontal gyrus, medial orbital (PFCventmed.R) (BA 11, $MNI: 4, 38, -12$; $SDM-Z = -2.193$, $P < 0.001$), left superior temporal gyrus (STG.L) (BA 48, $MNI: -52, -16, 12$, $SDM-Z = -2.174$, $P < 0.001$), and right calcarine fissure/surrounding cortex (CAL.R) (BA 17, $MNI: 16, -58, 8$, $SDM-Z = -1.879$, $P < 0.005$) compared to HCs (Table 2, Fig. 2). No increased GM was found in T2DM-CD compared to HCs. Q statistic showed the heterogeneity in main results ($Q = 46.682$, $P < 0.000$) (Supplementary Table 6, Supplementary Fig. 2). Jackknife analysis showed 10 of 11 times in PFCventmed. R, 8 of 11 times in STG. L, and 8 of 11 times in CAL. R (Supplementary Table 7). Egger's test showed the publication bias in PFCventmed.R ($P < 0.05$), while no publication bias in in STG.L and CAL.R ($P > 0.05$) (Supplementary Fig. 3).

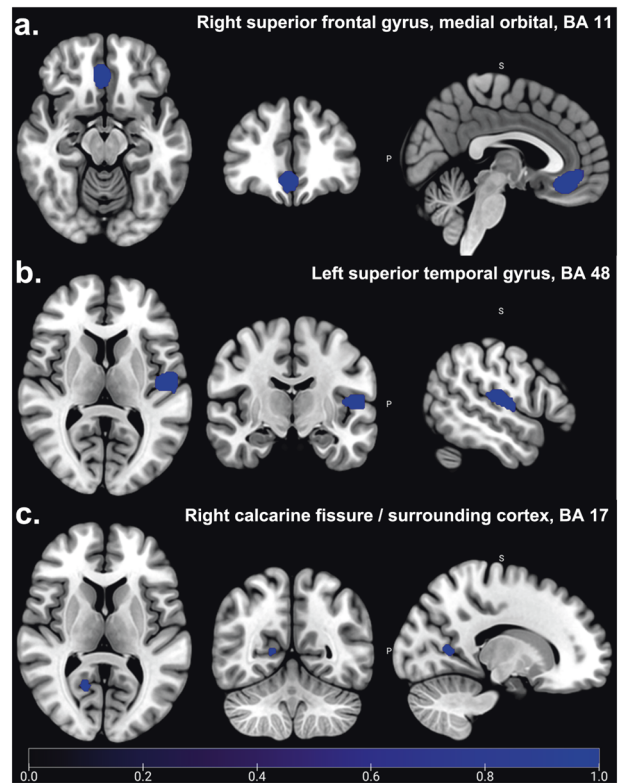


Fig. 2 Significant GM abnormalities between T2DM-CD and HCs. Patients with T2DM-CD showed significant and consistent decreased GM (Blue) in right superior frontal gyrus, medial orbital (PFCventmed.R, BA 11) (a), left superior temporal gyrus (STG.L, BA 48) (b), and right calcarine fissure/surrounding cortex (CAL.R, BA 17) (c) compared to HCs ($P < 0.005$). No increased GM was found in T2DM-CD compared to HCs ($P = 0.005$).

WM abnormality between T2DM-CD and HCs

According to the main analysis, patients with T2DM-CD showed the significant and consistent decreased FA in right inferior network, inferior fronto-occipital fasciculus (IFOF.R) ($MNI: 36, -12, -12$, $SDM-Z = -1.402$, $P < 0.001$), right inferior network, longitudinal fasciculus (ILF.R) ($MNI: 54, -18, -14$, $SDM-Z = -1.038$, $P < 0.005$), and undefined area in cerebellum ($MNI: 32, -60, -42$, $SDM-Z = -1.017$, $P < 0.005$) compared to HCs (Table 2, Fig. 3). Q statistic showed no heterogeneity in main results ($Q = 7.056$, $P > 0.05$) (Supplementary Table 6, Supplementary Fig. 4). Jackknife analysis showed 4 of 5 times in right inferior network, inferior fronto-occipital fasciculus, 4 of 5 times in right inferior network, inferior longitudinal fasciculus, and 4 of 5 times in undefined area in cerebellum (Supplementary Table 7). Egger's test was not performed to check the publication bias because of limited studies (< 10 studies).

Meta-regression analysis

The potential effects of risk factors (e.g., age, BMI, HbA1c, disease duration, and MMSE/MoCA score) on the GM or WM abnormalities in T2DM-CD were respectively performed in meta-regression. The results showed that the GM reduction in PFCventmed.R was positively related with the MoCA score, and the GM reduction in STG.L was positively related with the BMI (Table 3 and Fig. 4). In addition, the decreased FA in IFOF.R was positively related with both age and BMI (Table 3 and Fig. 5).

DISCUSSION

In our systemic review and meta-analysis, GM and WM abnormalities in patients with T2DM-CD were the first to be explored.

Table 2. Significant decreased GM and WM in patients with T2DM-CD compared with HCs.

| MNI coordinate | SDM-Z | P | Voxels | Description | Jackknife |
|----------------|--------|--------|--------|--|-----------|
| Gray matter | | | | | |
| 4,38, -12 | -2.193 | <0.001 | 435 | Right superior frontal gyrus, medial orbital, BA 11 | 10/11 |
| -52, -16,12 | -2.174 | <0.001 | 419 | Left superior temporal gyrus, BA 48 | 8/11 |
| 16, -58,8 | -1.879 | <0.005 | 51 | Right calcarine fissure / surrounding cortex, BA 17 | 8/11 |
| White matter | | | | | |
| 36, -12, -12 | -1.402 | <0.001 | 57 | Right inferior network, inferior fronto-occipital fasciculus | 4/5 |
| 54, -18, -14 | -1.038 | <0.005 | 20 | Right inferior network, inferior longitudinal fasciculus | 4/5 |
| 32, -60, -42 | -1.017 | <0.005 | 15 | Undefined | 4/5 |

BA Brodmann area.

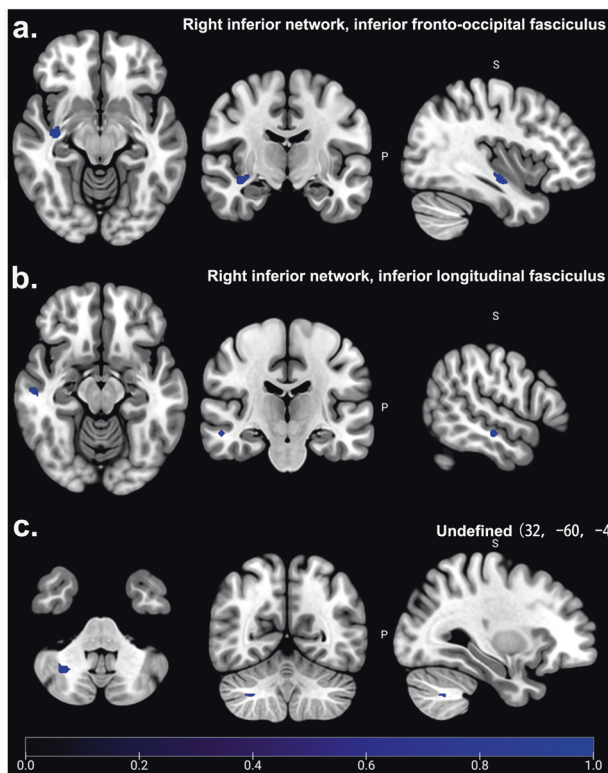


Fig. 3 Significant WM abnormalities between T2DM-CD and HCs. Patients with T2DM-CD showed the significant and consistent decreased FA (Blue) in right inferior network, inferior fronto-occipital fasciculus (IFOF.R) (a), right inferior network, inferior longitudinal fasciculus (ILF.R) (b), and undefined area of cerebellum (32, -60, -42) (c) ($P < 0.005$). No increased FA was found in T2DM-CD compared to HCs ($P = 0.005$).

The GMV, GMD, and cortical thickness changes between T2DM-CD and HCs were combined to explore the specific brain regions with GM alterations in T2DM-CD. The FA changes between T2DM-CD and HCs were pooled to explore the specific brain regions with WM abnormalities. Main analysis showed that patients with T2DM-CD had the significant decreased GM in PFCventmed.R (BA 11), STG.L (BA 48), and CAL.R (BA 17), as well, as they had decreased FA in IFOF.R, ILF.R, and undefined area of cerebellum area (32, -60, -42). Meta-regression showed that the BMI might be positively related with both decreased GM in STG.L and decreased FA in IFOF.R, the MoCA score might be positively related with the decreased GM in PFCventmed.R, and the age of patients might be positively related with the decreased FA in IFOF.R.

According to our main results, GM abnormalities in specific brain regions in patients with T2DM-CD were also consistent with the findings of previous systemic review and meta-analysis studies on brain structural alterations caused by T2DM. For example, previous meta-analysis of VBM studies reported that patients with T2DM had the significant GM reductions in bilateral STG, middle temporal gyrus (MTG), medial superior frontal gyrus (SFGmedial), insula (INS), median cingulate cortex, precuneus cortex, and the left lentiform nucleus [47]. Meanwhile, another meta-analysis study reported that the patients with T2DM showed a lower GMV in STG.L, MTG.R, right rolandic operculum (ROL.R), and left fusiform gyrus (FFG.L) than HCs [48]. In addition, the recent systemic review and meta-analysis also showed that the patients with T2DM had the significant decreased GMV in bilateral STG/ROL, MTG.L, ITG.L, and left supramarginal gyrus (SMG.L) [49]. Similarly, our study found that the patients with T2DM-CD had the significant decreased GM in STG.L compared to HCs. Taken together, the GM reduction in STG.L was robust in both T2DM and T2DM-CD. It was reported that the STG played a crucial role in extracting meaningful information from speech input [50]. Previous evidences also demonstrated that the functional deficit of STG was the common mechanism of CD caused by various diseases including T2DM, schizophrenia, and multiple sclerosis [37, 51, 52]. Therefore, the GM reduction in STG.L may be a specific biomarker for T2DM to T2DM-CD by impairing the function of speech information encoding.

Furthermore, our study also found that patients with T2DM-CD had the significant decreased FA in IFOF.R compared to HCs, which was consistent with the findings of previous systemic review and meta-analysis studies. For example, previous meta-analysis study reported that the patients with T2DM showed the significant decreased FA in IFOF.R, corpus callosum (CC), and left olfactory cortex compared to HCs [17]. Another same study found that patients with T2DM had the significant decreased FA in CC (genu and body), bilateral anterior and superior corona radiata (CR), bilateral cingulum, and bilateral superior fronto-occipital fasciculus (SFOF) [53]. Taken together, the decreased FA in FOF was robust in both T2DM and T2DM-CD. It was reported that the damaged WM integrity of IFOF.R was related with the episodic memory and attention function impairment in patients with T2DM [19]. And the previous studies have demonstrated that the FOF fiber tract was significantly involved in the linguistic, spatial, and visual functions [54–56]. Therefore, the decreased FA in FOF might be another specific biomarker for T2DM to T2DM-CD by impairing the memory and attention functions.

In addition to the robust results in both T2DM and T2DM-CD, our study also found that the patients with T2DM-CD had the significant GM reduction in PFCventmed.R (BA 11) and CAL.R (BA 17), as well as decreased FA in ILF.R and undefined area of cerebellum (32, -60, -42). Although previous studies have

Table 3. The relationship between Age, BMI, MoCA and decreased GM/WM in patients with T2DM-CD.

| Risk factors | MNI coordinate | SDM-Z | P | Voxels | Description |
|--------------|----------------|--------|---------|--------|--|
| Gray matter | | | | | |
| BMI | -56, -18, 10 | -2.715 | <0.0005 | 245 | Left superior temporal gyrus, BA 48 |
| MoCA | 2, 36, -14 | -1.388 | <0.0005 | 24 | Right superior frontal gyrus, medial orbital, and BA 11 |
| White matter | | | | | |
| BMI | 36, -14, -10 | -1.392 | <0.0005 | 11 | Right inferior network, inferior fronto-occipital fasciculus |
| Age | 36, -12, -12 | -1.827 | <0.0005 | 18 | Right inferior network, inferior fronto-occipital fasciculus |

BA Brodmann area.

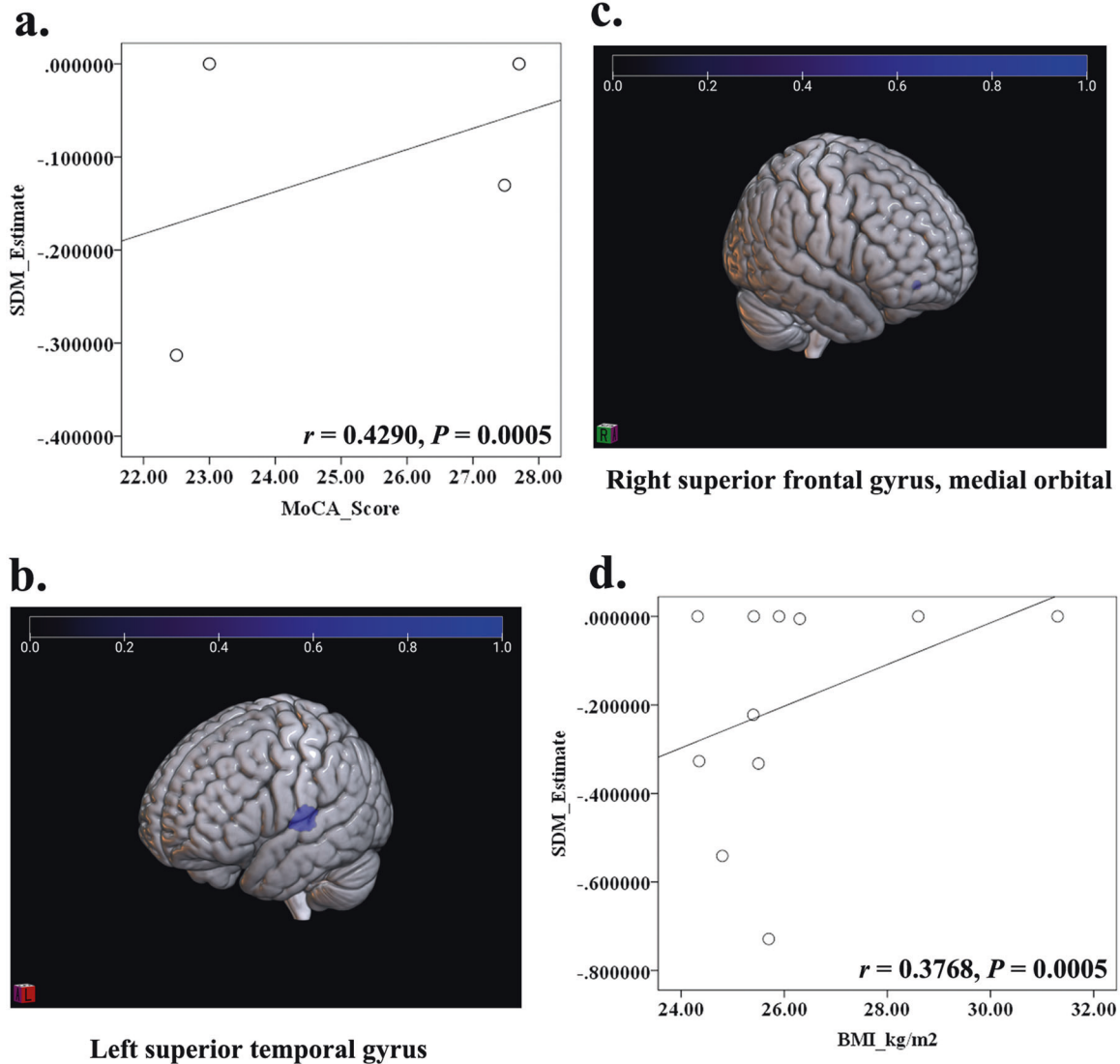


Fig. 4 The relationship between MoCA score, BMI, and decreased GM in patients with T2DM-CD. According to the meta-regression, the MoCA score was positively related with the decreased GM in PFCventmed.R (a, c) ($r = 0.4290$, $P < 0.0005$), while the BMI was positively related with the decreased GM in STG.L (b, d) ($r = 0.3768$, $P < 0.0005$).

shown that the first three structural abnormalities were involved in the T2DM or CD [57–59], the further exploration in T2DM-CD was suggested. Furthermore, the decreased FA in undefined area of cerebellum (32, -60, -42) that was adjacent to the cerebellar dentate nucleus (CDN) was newly found in T2DM-CD. Previous studies reported that the abnormal functional connectivity between CDN and cerebral cortex was significantly correlated

with the CD in Alzheimer's disease (AD) or first-episode schizophrenia [60, 61]. Therefore, impaired information transmission resulting from decreased FA in the CDN-adjacent WM region might also be associated with T2DM-CD. Meta-regression showed that the risk factors of BMI, age of patients, and MoCA score might play an effect on the GM or WM alterations in T2DM-CD, but the results need to be verified due to the limited

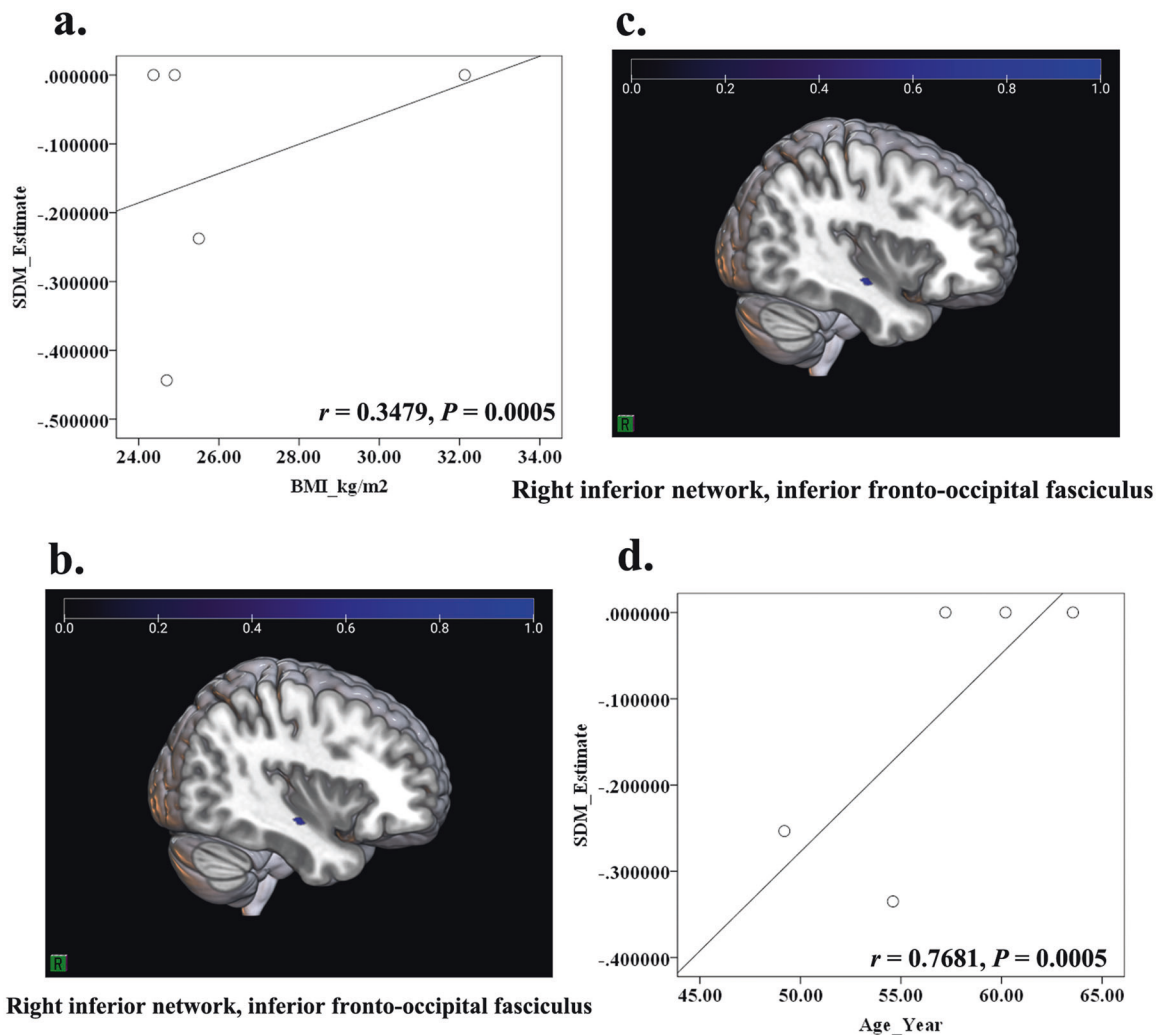


Fig. 5 The relationship between BMI, age and decreased FA in patients with T2DM-CD. According to the meta-regression, both the BMI (a, c) ($r = 0.3479, P < 0.0005$) and age of patients (b, d) ($r = 0.7681, P < 0.0005$) were positively related with the decreased FA in IFOF.R.

datasets. The other factors including MMSE score, percentage of female patients, HbA1c, and disease duration were suggested to be further explored in the future.

Some limitations in this study were declared as follows: Firstly, only published studies from 4 databases were searched; secondly, only peak coordinates and effect sizes of studies included were extracted and analyzed; thirdly, subgroup analysis was not performed because of limited datasets; fourthly, GMV, GMD, and cortical thickness were pooled into this meta-analysis, which might increase the heterogeneity; fifthly, the results of meta-regression should be accepted with caution because of the limited datasets.

In conclusion, GM and WM abnormalities caused by T2DM in specific brain regions (STG.L and FOF) were significantly correlated with the visual and linguistic dysfunctions, which might play a crucial role in the process of T2DM-CD. Our findings also showed that T2DM damages the GM and its functionally related WM (e.g., IFOF. R and PFCventmed.R), but not the adjacent WM. Those results might be a reference for researchers in the future studies.

DATA AVAILABILITY

All data included in this study is showed in this article or supplementary information, any further request is available by contacting with the corresponding authors.

REFERENCES

- Vijan S. In the clinic. Type 2 diabetes. *Ann Intern Med.* 2015;162:C1–16. <https://doi.org/10.7326/AITC201503030>.
- Ma RCW, Chan JCN. Type 2 diabetes in East Asians: similarities and differences with populations in Europe and the United States. *Ann N. Y Acad Sci.* 2013;1281:64–91. <https://doi.org/10.1111/nyas.12098>.
- van Sloten TT, Sedaghat S, Carnethon MR, Launer LJ, Stehouwer CDA. Cerebral microvascular complications of type 2 diabetes: stroke, cognitive dysfunction, and depression. *Lancet Diabetes Endocrinol.* 2020;8:325–36. [https://doi.org/10.1016/S2213-8587\(19\)30405-X](https://doi.org/10.1016/S2213-8587(19)30405-X).
- Hills AP, Arena R, Khunti K, Yajnik CS, Jayawardena R, Henry CJ, et al. Epidemiology and determinants of type 2 diabetes in south Asia. *Lancet Diabetes Endocrinol.* 2018;6:966–78. [https://doi.org/10.1016/S2213-8587\(18\)30204-3](https://doi.org/10.1016/S2213-8587(18)30204-3).
- Srikanth V, Sinclair AJ, Hill-Briggs F, Moran C, Biessels GJ. Type 2 diabetes and cognitive dysfunction-towards effective management of both comorbidities. *Lancet Diabetes Endocrinol.* 2020;8:535–45. [https://doi.org/10.1016/S2213-8587\(20\)30118-2](https://doi.org/10.1016/S2213-8587(20)30118-2).
- Geijselaers S, Sep S, Stehouwer C, Biessels GJ. Glucose regulation, cognition, and brain MRI in type 2 diabetes: a systematic review. *Lancet Diabetes Endocrinol.* 2015;3:75–89. [https://doi.org/10.1016/S2213-8587\(14\)70148-2](https://doi.org/10.1016/S2213-8587(14)70148-2).
- Zilliox LA, Chadrasekaran K, Kwan JY, Russell JW. Diabetes and cognitive impairment. *Curr Diab Rep.* 2016;16:87. <https://doi.org/10.1007/s11892-016-0775-x>.
- Biessels GJ, Despa F. Cognitive decline and dementia in diabetes mellitus: mechanisms and clinical implications. *Nat Rev Endocrinol.* 2018;14:591–604. <https://doi.org/10.1038/s41574-018-0048-7>.
- Roy B, Ehlert L, Mullur R, Freeby MJ, Woo MA, Kumar R, et al. Regional brain gray matter changes in patients with type 2 diabetes mellitus. *Sci Rep.* 2020;10:9925. <https://doi.org/10.1038/s41598-020-67022-5>.

10. Cao C, Liu W, Zhang Q, Wu J, Sun Y, Li D, et al. Irregular structural networks of gray matter in patients with type 2 diabetes mellitus. *Brain Imaging Behav.* 2020;14:1477–86. <https://doi.org/10.1007/s11682-019-00070-2>.
11. Wang D, Wang L, Wei M, Xia X, Tian X, Cui X, et al. Relationship between type 2 diabetes and white matter hyperintensity: a systematic review. *Front Endocrinol (Lausanne).* 2020;11:595962. <https://doi.org/10.3389/fendo.2020.595962>.
12. Sun J, Xu B, Zhang X, He Z, Liu Z, Liu R, et al. The mechanisms of type 2 diabetes-related white matter intensities: a review. *Front Public Health.* 2020;8:498056. <https://doi.org/10.3389/fpubh.2020.498056>.
13. Li Q, Zhao Y, Chen Z, Long J, Dai J, Huang X, et al. Meta-analysis of cortical thickness abnormalities in medication-free patients with major depressive disorder. *Neuropsychopharmacology.* 2020;45:703–12. <https://doi.org/10.1038/s41386-019-0563-9>.
14. Li C, Zuo Z, Liu D, Jiang R, Li Y, Li H, et al. Type 2 diabetes mellitus may exacerbate gray matter atrophy in patients with early-onset mild cognitive impairment. *Front Neurosci.* 2020;14:856. <https://doi.org/10.3389/fnins.2020.00856>.
15. Wang C, Fu K, Liu H, Xing F, Zhang S. Brain structural changes and their correlation with vascular disease in type 2 diabetes mellitus patients: a voxel-based morphometric study. *Neural Regen Res.* 2014;9:1548–56. <https://doi.org/10.4103/1673-5374.139482>.
16. Yoon S, Cho H, Kim J, Lee D, Kim G, Hong Y, et al. Brain changes in overweight/obese and normal-weight adults with type 2 diabetes mellitus. *Diabetologia.* 2017;60:1207–17. <https://doi.org/10.1007/s00125-017-4266-7>.
17. Zhou C, Li J, Dong M, Ping L, Lin H, Wang Y, et al. Altered white matter microstructures in type 2 diabetes mellitus: a coordinate-based meta-analysis of diffusion tensor imaging studies. *Front Endocrinol (Lausanne).* 2021;12:658198. <https://doi.org/10.3389/fendo.2021.658198>.
18. Zhang J, Wang Y, Wang J, Zhou X, Shu N, Wang Y, et al. White matter integrity disruptions associated with cognitive impairments in type 2 diabetic patients. *Diabetes.* 2014;63:3596–605. <https://doi.org/10.2337/db14-0342>.
19. Gao S, Chen Y, Sang F, Yang Y, Xia J, Li X, et al. White matter microstructural change contributes to worse cognitive function in patients with type 2 diabetes. *Diabetes.* 2019;68:2085–94. <https://doi.org/10.2337/db19-0233>.
20. Liberati A, Altman D, Tetzlaff J, Mulrow C, Gøtzsche P, Ioannidis J, et al. The PRISMA statement for reporting systematic reviews and meta-analyses of studies that evaluate healthcare interventions: explanation and elaboration. *BMJ.* 2009;339:b2700. <https://doi.org/10.1136/bmj.b2700>.
21. Coleman SJ, Stevelink SAM, Hatch SL, Denny JA, Greenberg N. Stigma-related barriers and facilitators to help seeking for mental health issues in the armed forces: a systematic review and thematic synthesis of qualitative literature. *Psychol Med.* 2017;47:1880–92. <https://doi.org/10.1017/S0033291717000356>.
22. Li C, Wang J, Gui L, Zheng J, Liu C, Du H. Alterations of whole-brain cortical area and thickness in mild cognitive impairment and Alzheimer's disease. *J Alzheimers Dis.* 2011;27:281–90. <https://doi.org/10.3233/JAD-2011-110497>.
23. Nortje G, Stein DJ, Radua J, Mataix-Cols D, Horn N. Systematic review and voxel-based meta-analysis of diffusion tensor imaging studies in bipolar disorder. *J Affect Disord.* 2013;150:192–200. <https://doi.org/10.1016/j.jad.2013.05.034>.
24. Tang Y, Wang M, Zheng T, Yuan F, Yang H, Han F, et al. Grey matter volume alterations in trigeminal neuralgia: A systematic review and meta-analysis of voxel-based morphometry studies. *Prog Neuropsychopharmacol Biol Psychiatry.* 2020;98:109821. <https://doi.org/10.1016/j.pnpbp.2019.109821>.
25. Wei X, Luo C, Li Q, Hu N, Xiao Y, Liu N, et al. White matter abnormalities in patients with parkinson's disease: a meta-analysis of diffusion tensor imaging using tract-based spatial statistics. *Front Aging Neurosci.* 2020;12:610962. <https://doi.org/10.3389/fnagi.2020.610962>.
26. Yang C, Yao L, Liu N, Zhang W, Tao B, Cao H, et al. Microstructural abnormalities of white matter across tourette syndrome: a voxel-based meta-analysis of fractional anisotropy. *Front Neurol.* 2021;12:659250. <https://doi.org/10.3389/fneur.2021.659250>.
27. Niu R, Du M, Ren J, Qing H, Wang X, Xu G, et al. Chemotherapy-induced grey matter abnormalities in cancer survivors: a voxel-wise neuroimaging meta-analysis. *Brain Imaging Behav.* 2020;15:2215–27. <https://doi.org/10.1007/s11682-020-00402-7>.
28. Radua J, Rubia K, Canales-Rodríguez EJ, Pomarol-Clotet E, Fusar-Poli P, Mataix-Cols D. Anisotropic kernels for coordinate-based meta-analyses of neuroimaging studies. *Front Psychiatry.* 2014;5:13. <https://doi.org/10.3389/fpsy.2014.00013>.
29. Radua J, Mataix-Cols D, Phillips ML, El-Hage W, Kronhaus D, Cardoner N, et al. A new meta-analytic method for neuroimaging studies that combines reported peak coordinates and statistical parametric maps. *Eur Psychiatry.* 2012;27:605–11. <https://doi.org/10.1016/j.eurpsy.2011.04.001>.
30. Liu X, Lai H, Li J, Becker B, Zhao Y, Cheng B, et al. Gray matter structures associated with neuroticism: a meta-analysis of whole-brain voxel-based morphometry studies. *Hum Brain Mapp.* 2021;42:2706–21. <https://doi.org/10.1002/hbm.25395>.
31. Park JS, Jung YW. Peeled images and sectioned images from real-color volume models of foot. *Surg Radio Anat.* 2021;43:37–43. <https://doi.org/10.1007/s00276-020-02534-3>.
32. Kumral E, Bayam FE, Özdemir HN. Cognitive and behavioral disorders in patients with precuneal infarcts. *Eur Neurol.* 2021;84:157–67. <https://doi.org/10.1159/000513098>.
33. Li X, Wang J. Abnormal neural activities in adults and youths with major depressive disorder during emotional processing: a meta-analysis. *Brain Imaging Behav.* 2021;15:1134–54. <https://doi.org/10.1007/s11682-020-00299-2>.
34. Yeung AWK. Structural and functional changes in the brain of patients with Crohn's disease: an activation likelihood estimation meta-analysis. *Brain Imaging Behav.* 2021;15:807–18. <https://doi.org/10.1007/s11682-020-00291-w>.
35. Chen Z, Li J, Sun J, Ma L. Brain expansion in patients with type II diabetes following insulin therapy: a preliminary study with longitudinal voxel-based morphometry. *J Neuroimaging.* 2014;24:484–91. <https://doi.org/10.1111/jon.12059>.
36. Duan S, Liu D, Li T, Kuang J, Wei P, Wang J. Effect of type 2 diabetes mellitus on cognitive function in middle-aged adults and its characteristics. *J Third Mil Med Univ.* 2016;38:314–9. <https://doi.org/10.16016/j.1000-5404.201509122>.
37. Zhang Y, Zhang X, Zhang J, Liu C, Yuan Q, Yin X, et al. Gray matter volume abnormalities in type 2 diabetes mellitus with and without mild cognitive impairment. *Neurosci Lett.* 2014;562:1–6. <https://doi.org/10.1016/j.neulet.2014.01.006>.
38. Zhou H, Lu W, Zhang Z, Bai F, Chang J, Teng G. Study of cognitive function and brain volume in type 2 diabetic patients. *Zhong Hua Yi Xue Za Zhi.* 2010;90:327–31. <https://doi.org/10.3760/cma.j.issn.0376-2491.2010.05.011>.
39. Moran C, Phan T, Chen J, Blizzard L, Beare R, Venn A, et al. Brain atrophy in type 2 diabetes: regional distribution and influence on cognition. *Diabetes Care.* 2013;36:4036–42. <https://doi.org/10.2337/dc13-0143>.
40. Feng Y, Li Y, Tan X, Liang Y, Ma X, Chen Y, et al. Altered gray matter volume, functional connectivity, and degree centrality in early-onset type 2 diabetes mellitus. *Front Neurol.* 2021;12:697349. <https://doi.org/10.3389/fneur.2021.697349>.
41. Wei T, Liu X, Cui D, Xue Z, Guo Y, Lu A, et al. Gray matter density alteration and its correlation with cognitive impairment in patients with type 2 diabetes mellitus. *Chin J Med Phys.* 2018;35:364–8. <https://doi.org/10.3969/j.issn.1005-202X.2018.03.021>.
42. García-Casares N, Jorge RE, García-Arnés JA, Acion L, Berthier ML, Gonzalez-Alegre P, et al. Cognitive dysfunctions in middle-aged Type 2 diabetic patients and neuroimaging correlations: a cross-sectional study. *J Alzheimer's Dis.* 2014;42:1337–46. <https://doi.org/10.3233/JAD-140702>.
43. Kim D, Yu JH, Shin M, Shin Y, Kim M. Hyperglycemia reduces efficiency of brain networks in subjects with Type 2 diabetes. *PLoS One.* 2016;11:e157268. <https://doi.org/10.1371/journal.pone.0157268>.
44. Xiong Y, Zhang S, Shi J, Fan Y, Zhang Q, Zhu W. Application of neurite orientation dispersion and density imaging to characterize brain microstructural abnormalities in type-2 diabetics with mild cognitive impairment. *J Magn Reson Imaging.* 2019;50:889–98. <https://doi.org/10.1002/jmri.26687>.
45. Yau PL, Javier D, Tsui W, Sweat V, Bruehl H, Borod JC, et al. Emotional and neutral declarative memory impairments and associated white matter microstructural abnormalities in adults with type 2 diabetes. *Psychiatry Res.* 2009;174:223–30. <https://doi.org/10.1016/j.psychres.2009.04.016>.
46. Cui Y, Tang T, Lu C, Lu T, Wang Y, Teng G, et al. Disturbed interhemispheric functional and structural connectivity in Type 2 diabetes. *J Magn Reson Imaging.* 2021;55:424–34. <https://doi.org/10.1002/jmri.27813>.
47. Liu J, Liu T, Wang W, Ma L, Ma X, Shi S, et al. Reduced gray matter volume in patients with type 2 diabetes mellitus. *Front Aging Neurosci.* 2017;9:161. <https://doi.org/10.3389/fnagi.2017.00161>.
48. Wu G, Lin L, Zhang Q, Wu J. Brain gray matter changes in type 2 diabetes mellitus: a meta-analysis of whole-brain voxel-based morphometry study. *J Diabetes Complications.* 2017;31:1698–703. <https://doi.org/10.1016/j.jdiacomp.2017.09.001>.
49. Yao L, Yang C, Zhang W, Li S, Li Q, Chen L, et al. A multimodal meta-analysis of regional structural and functional brain alterations in type 2 diabetes. *Front Neuroendocrinol.* 2021;62:100915. <https://doi.org/10.1016/j.ymfe.2021.100915>.
50. Yi HG, Leonard MK, Chang EF. The encoding of speech sounds in the superior temporal gyrus. *Neuron.* 2019;102:1096–110. <https://doi.org/10.1016/j.neuron.2019.04.023>.
51. Achiron A, Chapman J, Tal S, Bercovich E, Gil H, Achiron A. Superior temporal gyrus thickness correlates with cognitive performance in multiple sclerosis. *Brain Struct Funct.* 2013;218:943–50. <https://doi.org/10.1007/s00429-012-0440-3>.
52. Rajarethinam RP, DeQuardo JR, Nalepa R, Tandon R. Superior temporal gyrus in schizophrenia: a volumetric magnetic resonance imaging study. *Schizophr Res.* 2000;41:303–12. [https://doi.org/10.1016/s0920-9964\(99\)00083-3](https://doi.org/10.1016/s0920-9964(99)00083-3).
53. Huang L, Zhang Q, Tang T, Yang M, Chen C, Tao J, et al. Abnormalities of brain white matter in Type 2 diabetes mellitus: a meta-analysis of diffusion tensor imaging. *Front Aging Neurosci.* 2021;13:693890. <https://doi.org/10.3389/fnagi.2021.693890>.
54. Dick AS, Bernal B, Tremblay P. The language connectome. *Neuroscientist.* 2014;20:453–67. <https://doi.org/10.1177/1073858413513502>.
55. Herbet G, Yordanova YN, Duffau H. Left spatial neglect evoked by electrostimulation of the right inferior fronto-occipital fasciculus. *Brain Topogr.* 2017;30:747–56. <https://doi.org/10.1007/s10548-017-0574-y>.

56. Yuki N, Yoshioka A, Mizuhara R, Kimura T. Visual hallucinations and inferior longitudinal fasciculus in Parkinson's disease. *Brain Behav.* 2020;10:e01883. <https://doi.org/10.1002/brb3.1883>.
57. Kotkowski E, Price L, Franklin C, Salazar M, Woolsey M, DeFronzo R, et al. A neural signature of metabolic syndrome. *Hum Brain Mapp.* 2019;40:3575–88. <https://doi.org/10.1002/hbm.24617>.
58. Zhang T, Liao Q, Zhang D, Zhang C, Yan J, Ngetich R, et al. Predicting MCI to AD conversation using integrated sMRI and rs-fMRI: machine learning and graph theory approach. *Front Aging Neurosci.* 2021;13:688926. <https://doi.org/10.3389/fnagi.2021.688926>.
59. Tan X, Fang P, An J, Lin H, Liang Y, Shen W, et al. Micro-structural white matter abnormalities in type 2 diabetic patients: a DTI study using TBSS analysis. *Neuroradiology.* 2016;58:1209–16. <https://doi.org/10.1007/s00234-016-1752-4>.
60. Olivito G, Serra L, Marra C, Domenico C, Caltagirone C, Toniolo S, et al. Cerebellar dentate nucleus functional connectivity with cerebral cortex in Alzheimer's disease and memory: a seed-based approach. *Neurobiol Aging.* 2020;89:32–40. <https://doi.org/10.1016/j.neurobiolaging.2019.10.026>.
61. Xie Y, Xi Y, Cui L, Guan M, Li C, Wang Z, et al. Functional connectivity of cerebellar dentate nucleus and cognitive impairments in patients with drug-naive and first-episode schizophrenia. *Psychiatry Res.* 2021;300:113937. <https://doi.org/10.1016/j.psychres.2021.113937>.

AUTHOR CONTRIBUTIONS

GBC, LFY, and WW made the article framework design; GBC and LFY provided the funding support; TM, ZYL, and LFY performed the systemic search, study selection and data analysis; YY, BH, YH, MHN, YXH, and HHC checked the methods and results, searched the reference materials, and contributed to the interpretation of findings; TM, ZYL, and LFY wrote the original draft; GBC and WW revised the article.

FUNDING

This study was supported by the National Natural Science Foundation of China (No. 81771815, GBC) and the Military Medical Enhancement Program of Air Force Medical University (No. 2018HKPY03, GBC; No. 2018JSTS13, LFY).

COMPETING INTERESTS

The authors declare that the research was conducted in the absence of any commercial or financial relationships that could be construed as a potential conflict of interest.

ADDITIONAL INFORMATION

Supplementary information The online version contains supplementary material available at <https://doi.org/10.1038/s41387-022-00214-2>.

Correspondence and requests for materials should be addressed to Wen Wang, Lin-Feng Yan or Guang-Bin Cui.

Reprints and permission information is available at <http://www.nature.com/reprints>

Publisher's note Springer Nature remains neutral with regard to jurisdictional claims in published maps and institutional affiliations.



Open Access This article is licensed under a Creative Commons Attribution 4.0 International License, which permits use, sharing, adaptation, distribution and reproduction in any medium or format, as long as you give appropriate credit to the original author(s) and the source, provide a link to the Creative Commons license, and indicate if changes were made. The images or other third party material in this article are included in the article's Creative Commons license, unless indicated otherwise in a credit line to the material. If material is not included in the article's Creative Commons license and your intended use is not permitted by statutory regulation or exceeds the permitted use, you will need to obtain permission directly from the copyright holder. To view a copy of this license, visit <http://creativecommons.org/licenses/by/4.0/>.

© The Author(s) 2022