



Medial Patellofemoral Ligament Reconstruction Using All-Soft Suture Anchors for Patellar Fixation

Justin L. Makovicka, M.D., David E. Hartigan, M.D., Karan A. Patel, M.D.,
Sailesh V. Tummala, B.S., and Anikar Chhabra, M.D., M.S.

Abstract: The medial patellofemoral ligament (MPFL), which is critical for both patellar stability and normal kinematics of the patellofemoral joint, is disrupted in most patellar dislocations. Consequently, MPFL reconstruction is advocated in recurrent dislocations to restore native patellar constraints. Fixation of the MPFL graft to the medial border of the patella can be achieved through various methods, each with its own benefits and drawbacks. We present a technique for MPFL fixation to the patella using all-soft suture anchors, theoretically decreasing the risk of patellar fracture and articular surface violation.

Lateral patellar dislocations comprise 2% to 3% of acute knee injuries.¹ Various anatomic and patient factors predispose individuals to these injuries. These factors include generalized ligamentous laxity, as found in Ehlers-Danlos syndrome, as well as “miserable malalignment syndrome,” which is a combination of femoral anteversion, genu valgum, and external tibial torsion or pronated feet that leads to an increased Q-angle. An increased Q-angle results in increased lateral translational forces on the patella increasing the risk of instability. The overall recurrence rate after a primary patellar dislocation approaches 40%, and a previous instability episode has been associated with the highest risk of subsequent instability episodes.^{2,3} Patellar dislocations commonly occur during athletic activity, and over 90% are indirect injuries occurring through a valgus and torsional force on a flexed knee.¹ All acute

patellar dislocations result in increased laxity of the medial patellofemoral ligament (MPFL), with 50% to 96% of post-dislocation patients having complete deficiency of the ligament during surgical exploration.^{4,5}

The MPFL is a strong band of retinacular tissue between 45 and 64 mm in length and 3 and 30 mm in width that lies in the second layer of the medial soft-tissue complex consisting of both a short oblique bundle and an inferior straight bundle.⁶ It connects the Schöttle point, between the adductor tubercle and the medial epicondyle of the medial femur, to the patella through a fanlike attachment at the superior aspect of the medial border of the patella. From 0° to 30° of knee flexion, the patella lies outside of bony constraints provided by the trochlea and the MPFL is the primary passive restraint, providing 60% of the total medial restraining force against lateral patellar displacement.⁷ It also acts as an indirect dynamic stabilizer of the patella, with the contraction of the vastus medialis obliquus pulling the patella medially through the MPFL.⁸

Conservative treatment with 3 to 6 months of physical therapy with an emphasis on quadriceps strengthening remains the mainstay for treatment of first-time patellar dislocators without loose bodies or intra-articular damage. Because of the role played by the MPFL in stability of the patellofemoral joint, MPFL reconstruction may be considered in patients who are recurrent dislocators and those in whom conservative treatment fails.⁸ For anatomic double-bundle MPFL reconstruction, multiple different techniques for fixation of the soft-tissue graft to the patella have been described. These include bone tunnels, interference screws, and suture anchors (SAs).⁹ The patellar bone

From the Department of Orthopedics, Mayo Clinic (J.L.M., D.E.H., K.A.P., A.C.), Phoenix, Arizona; and John A. Burns School of Medicine, University of Hawaii (S.V.T.), Honolulu, Hawaii, U.S.A.

The authors report the following potential conflict of interest or source of funding: D.E.H. receives support from Arthrex. Consultant. A.C. receives support from Arthrex. Consultant. Full ICMJE author disclosure forms are available for this article online, as [supplementary material](#).

Received August 21, 2017; accepted August 28, 2017.

Address correspondence to Anikar Chhabra, M.D., M.S., Department of Orthopedics, Mayo Clinic, 5779 E Mayo Blvd, Phoenix, AZ 85054, U.S.A. E-mail: Chhabra.Anikar@mayo.edu

© 2017 by the Arthroscopy Association of North America. Published by Elsevier. This is an open access article under the CC BY-NC-ND license (<http://creativecommons.org/licenses/by-nc-nd/4.0/>).

2212-6287/171019

<https://doi.org/10.1016/j.eats.2017.08.075>

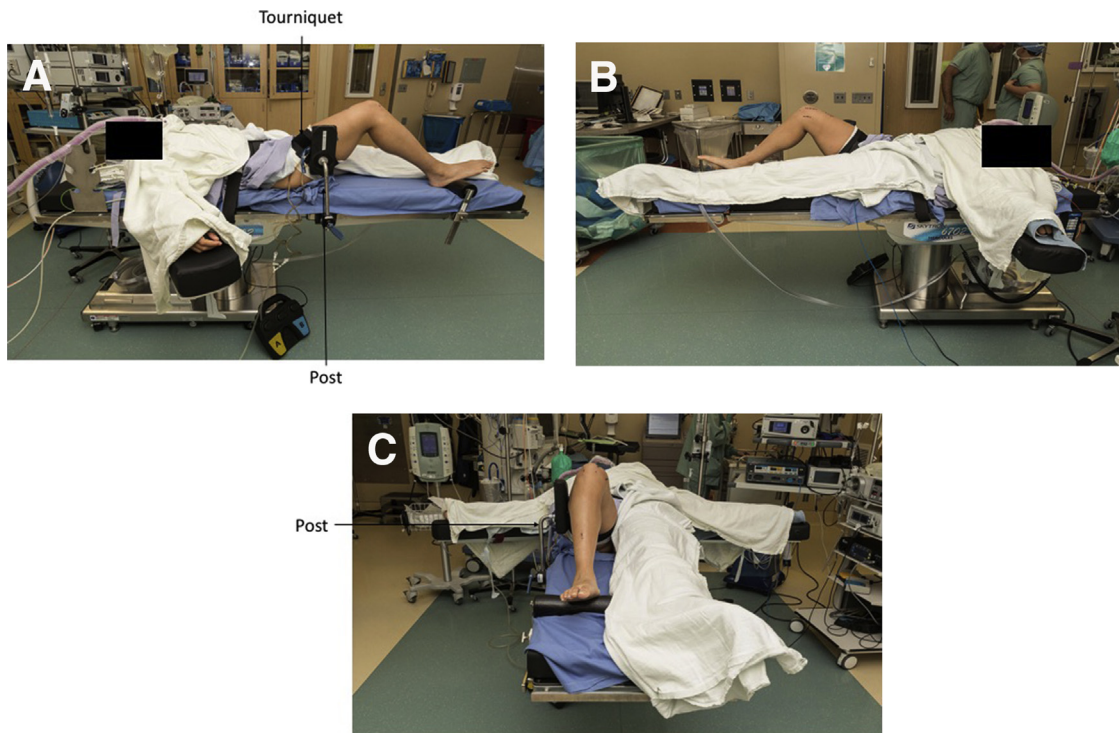


Fig 1. Lateral (A), medial (B), and end-table (C) views of operating room setup in preparation for medial patellofemoral ligament reconstruction. The patient is supine with the knee at 90°. The post and sterile draping can be set up as per the surgeon's preference.

tunnel (PBT) technique remains widely used in MPFL reconstruction but poses some disadvantages. First, the bone tunnels create stress risers in the patella that may lead to fractures of the patella, as have been reported by several authors.¹⁰⁻¹³ Moreover, to prevent patellar fractures, the bone tunnels must be drilled through the patella avoiding both the anterior cortex and the articular surface, posing a challenge for the surgeon.⁹ In addition, the PBT technique requires a lateral parapatellar incision, resulting in decreased cosmesis and increased infection risk of the procedure.¹⁴ In an attempt to reduce these complications, classic solid SAs

have been used in anatomic double-bundle MPFL reconstruction. Authors have determined several potential advantages of SAs over the PBT technique. SAs decrease the patellar fracture risk from stress risers by creating a sulcus for the anchors instead of tunnels, improve cosmesis without the need for a lateral incision, and allow reconstruction with a shorter graft because there is no need to loop the tendon through bone tunnels.^{9,15,16}

All-soft suture anchors (ASAs) have more recently been introduced as an alternative to classic solid SAs in the arthroscopic repair of labral and rotator cuff tears in

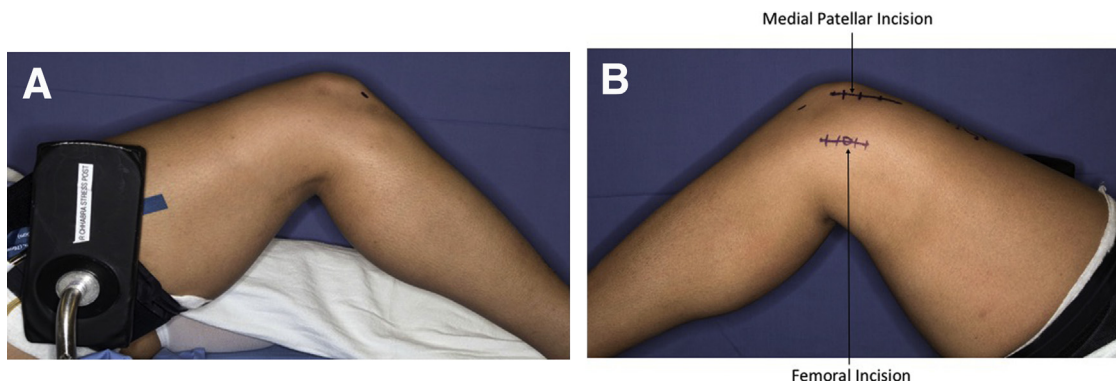


Fig 2. Lateral (A) and medial (B) views of outlined patellar and femoral incisions, along with standard anterolateral and anteromedial arthroscopy portals. A longitudinal line is drawn along the medial border of the patella with the knee in extension. The knee is then flexed to 90°, and a longitudinal line at the location of the medial epicondyle is drawn parallel to the first line for the femoral incision, both approximately 3 cm in length.

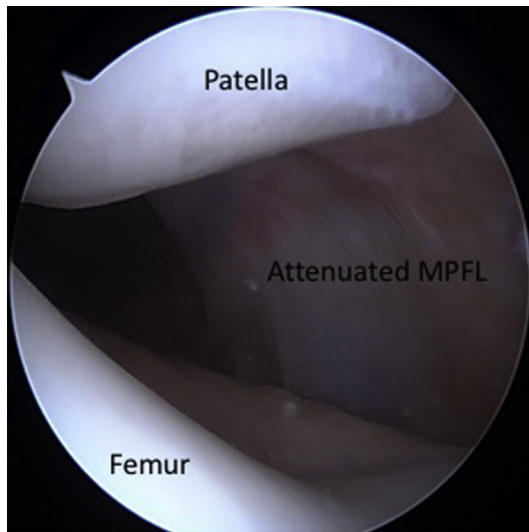


Fig 3. A diagnostic arthroscopy is performed addressing all concomitant pathology with particular attention paid to the patellofemoral joint pathology, alignment, and need for treatment. An arthroscopic view of the patellofemoral joint with visualization of the attenuated medial patellofemoral ligament (MPFL) can be seen.

alignment. These measurements aid the surgeon in determining whether a bony realignment procedure, such as a tibial tubercle osteotomy, is needed in addition to MPFL reconstruction to prevent recurrent instability.

Positioning and Preparation

The patient is positioned in the supine position with a tourniquet placed at thigh level on the affected side. A post of the surgeon’s preference should be placed on the operative side to assist in producing a valgus force for diagnostic arthroscopy (Fig 1). A large C-arm is brought in from the contralateral side of the patient to allow for anteroposterior and true lateral radiographs. A comprehensive ligamentous examination with the patient under anesthesia is performed along with evaluation of tilt, excursion, and tracking of the patellofemoral joint. A surgical marker is used to outline standard anterolateral and anteromedial portals, along with the proposed surgical incisions for the MPFL repair. A longitudinal line is drawn along the medial border of the patella with the knee in extension. The knee is then flexed to 90°, and a longitudinal line at the location of the medial epicondyle is drawn parallel to the first line for the femoral incision, both approximately 3 cm in length (Fig 2).

addition to lateral ligament reconstruction for ankle instability.¹⁷⁻²⁰ The ASA is composed entirely of suture, allowing placement in tunnels with smaller diameters than classic SAs, preserving more bone, and theoretically decreasing the risk of patellar fracture and articular surface violation.^{19,20} This article describes our technique for anatomic double-bundle MPFL reconstruction using ASAs for patellar fixation.

Diagnostic Arthroscopy

With a 30° arthroscope through the anterolateral portal, a diagnostic arthroscopy is performed addressing all concomitant pathology, with particular attention paid to patellofemoral joint pathology, alignment, and need for treatment (Fig 3). Arthroscopic equipment is then removed and attention turned to the open portion of the procedure. The arthroscopic portals are left open until the end of the case to allow for dynamic visualization with the arthroscope after MPFL reconstruction.

Technique

Imaging

In addition to a standard knee radiographic series, the evaluation of patients with patellar instability should include standing long leg alignment films for mechanical alignment and either computed tomography or magnetic resonance imaging to determine the tibial tuberosity–tibial groove distance for rotational

Reconstruction

The medial patellar incision is first exposed with blunt dissection down to the retinaculum. The retinaculum is then incised in line with the skin incision approximately 2

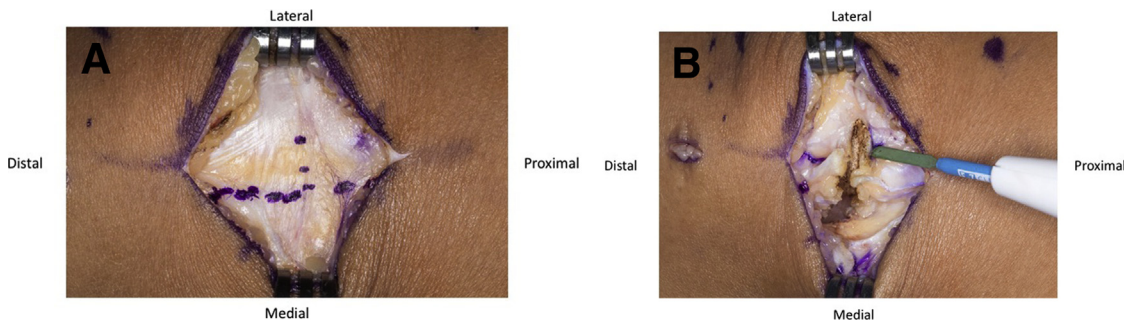


Fig 4. Once the medial patellar incision is exposed bluntly down to the retinaculum, it is incised in line with the skin incision approximately 2 to 3 mm off the border of the patella (A) and a T-incision is then made at the one-third–two-thirds junction of the proximal patella (B). Care must be taken not to incise the joint capsule.

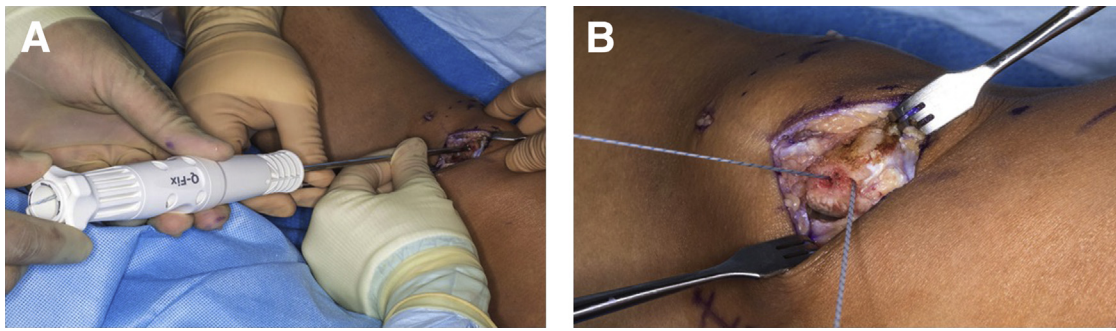


Fig 5. (A) The proximal anchor site is drilled in the trough at the one-third–two-thirds junction of the proximal patella, and a 1.8-mm Q-Fix anchor is placed at the proximal anchor site. (B) A second 1.8-mm Q-Fix anchor is placed 0.75 cm distally to the first.

to 3 mm off the border of the patella, preserving a cuff of tissue for closure. A T-incision is made in the retinaculum at the one-third–two-thirds junction of the proximal patella with care taken to not incise the joint capsule (Fig 4). Once the proper location is confirmed with the C-arm, a rongeur is used to remove all soft tissue and create a trough of smooth, bleeding bone along the medial border of the patella approximately 2 cm proximal to distal, 5 mm anterior to posterior, and 5 mm deep into bone. Next, a drill guide for the 1.8-mm Q-Fix anchor (Smith & Nephew, Andover, MA) is placed in the trough at the proximal anchor site (one-third–two-thirds

junction of proximal patella) and the drill is aimed slightly distally to account for the contour of the patella. The drill is advanced until the shoulder of the drill bottoms in the drill guide. It is important to ensure that the drill remains in the cancellous bone and does not penetrate the articular surface or anterior cortex; if the cortex is felt, the angle should be redirected. The 1.8-mm Q-Fix anchor inserter is then inserted into the bone hole and the anchor deployed (Fig 5). A second 1.8-mm Q-Fix anchor is then placed in a similar fashion, approximately 0.75 cm distal to the first anchor along the medial border of the patella, with a transverse trajectory across the patella. Once the graft

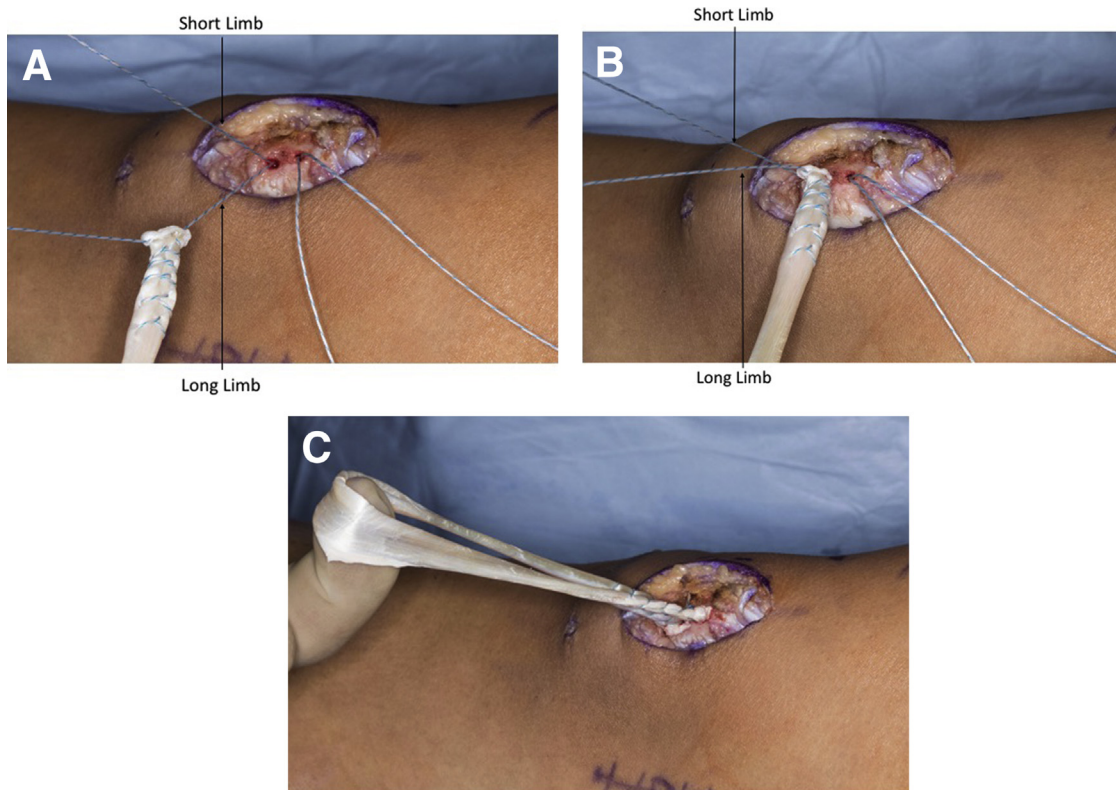


Fig 6. Once the graft is thawed and cut to the appropriate length, the long limb of each suture anchor is whipstitched to 1 end of the graft (A) and the short limb of the suture is then pulled to cinch the graft into the bone trough (B). (C) After both ends are fixed and tied into the trough, a looped graft with 2 limbs on the patella is created, simulating the anatomic insertion of the native medial patellofemoral ligament on the patella.

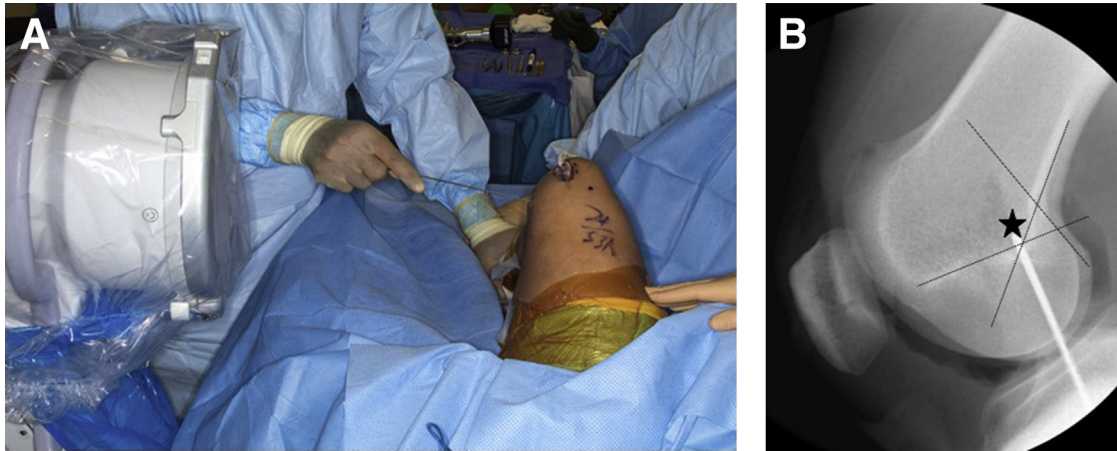


Fig 7. (A) Once the femoral incision is dissected down to the medial epicondyle, the knee is flexed to approximately 90° and fluoroscopy is used to isolate the Schöttle point on a perfect lateral radiograph. (B) This point (star) is located approximately 1 mm anterior to the posterior cortex of the femur, 2.5 mm distal to the posterior origin of the medial femoral condyle, and proximal to the posterior point of the Blumensaat line.

(peroneus longus or posterior tibial tendon allograft) is thawed and cut to the appropriate length, the long limb of suture from each anchor is whipstitched to each end of the tendon. The short limb of suture is then pulled to cinch the graft into the previously prepared bone trough. After both ends are fixed and tied into the trough, a looped graft with 2 limbs on the patella is created, simulating the anatomic insertion of the native MPFL on the patella (Fig 6).

Attention is then turned to the femur. The femoral incision is dissected down to the medial epicondyle. The knee is then flexed to approximately 90°, and fluoroscopy is used to obtain a perfect lateral radiograph. Under fluoroscopic guidance, a small Beath pin (Arthrex, Naples, FL) is used to isolate the Schöttle point. This is located approximately 1 mm anterior to the posterior cortex of the femur, 2.5 mm distal to the posterior origin of the medial femoral condyle, and proximal to the posterior point of the Blumensaat line (Fig 7). The pin is passed across the knee, aiming slightly anterior and proximal, and exits through the lateral soft tissues. This allows for an increased tunnel length while also avoiding the notch or posterior cortex of the femur. The looped portion of the graft is then sized, and the corresponding reamer is used to drill over the Beath pin, near but not through the lateral cortex. A curved Kelly clamp is used to bluntly create a soft-tissue plane between the second and third layers of the retinaculum from the medial patella to the medial epicondyle. The graft is then tunneled in this layer and passed through the femoral tunnel using a passing suture. With the leg in approximately 30° of flexion, tension is pulled on the graft through the lateral side and the graft is fixed into place with a BioComposite interference screw (Arthrex) 1 size larger than the diameter of the tunnel (Fig 8). During tensioning, a

Kocher clamp is placed underneath the graft at the medial incision site to prevent over-tightening.

After fixation, the retinaculum is closed in a pants-over-vest configuration with No. 0 FiberWire suture (Arthrex) in a figure-of-8 knot. The knee is then taken through full range of motion, and patellar tracking and excursion are assessed both clinically and arthroscopically. Table 1 presents pearls and pitfalls of this technique. A demonstration of our technique is given in Video 1.

Discussion

The MPFL has been determined to be the primary restraint to lateral translation of the patella from 0° to 30° of knee flexion, and its biomechanical properties are critical for both patellar stability and normal kinematics of the patellofemoral joint.^{8,9,21-23} Most acute patellar dislocations result in disruption of the MPFL, and the high rate of recurrent dislocations can be attributed to

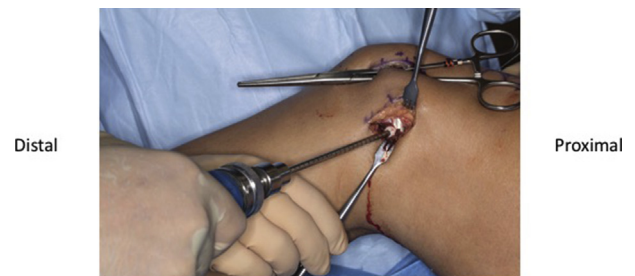

Fig 8. In approximately 30° of flexion, tension is pulled on the graft through the lateral side and the graft is fixed into place with a BioComposite interference screw 1 size larger than the diameter of the tunnel. It should be noted that during tensioning, a Kocher clamp is placed underneath the graft at the medial incision site to prevent over-tightening.

Table 1. Pearls and Pitfalls

Outline the femoral incision in 90° of knee flexion.
During patella drilling, ensure the drill does not penetrate the articular surface or anterior cortex.
Tug on the Q-Fix suture before whipstitching to the tendon to ensure slack is removed from the anchor.
Tension the graft in 30° of knee flexion.
To prevent over-tightening, place a Kocher clamp underneath the graft at the medial incision during tensioning.

insufficiency or loosening of the ligament.^{5,24,25} Consequently, MPFL reconstruction is advocated in recurrent dislocations to restore native patellar constraints. Fixation of the MPFL graft to the medial border of the patella can be achieved through various methods including bone tunnels, interference screws, or SAs.⁹ Patellar fracture and damage to the articular surface are 2 of the most significant complications to occur during MPFL reconstruction. These are traditionally associated with bone tunnel (PBT) techniques in which full-thickness tunnels through the patellar bone create stress risers.^{9,20} In attempts to reduce complications, authors have described the use of SAs for patellar fixation, negating the need for bone tunnels. Theoretically, PBT techniques have 2 advantages over SA fixation: First, pullout fixation strength is expected to be higher compared with SA fixation, and second, the PBT technique provides wide bone and graft contact areas, which enhance tendon-to-bone healing.⁹ However, biomechanical studies comparing fixation strength have found no difference in tensile strength or ultimate load values between SA and PBT fixation techniques.^{15,26} Moreover, SA fixation has been determined to provide adequate strength of fixation in reconstruction and fail at tensile loads similar to the native MPFL.^{20,27} In addition, the creation of the bony sulcus in SA fixation should provide adequate biological characteristics for tendon healing. The literature has shown that results comparable with those of the PBT technique can be achieved with SAs while providing the advantages of a simpler technique, allowing use regardless of patella size, and allowing anatomic reconstruction of the MPFL completely inside the native patellar footprint. [Table 2](#) shows the advantages and disadvantages of the described technique.

Table 2. Advantages and Disadvantages

Advantages
No creation of stress risers in patella, decreasing risk of patellar fracture and articular surface violation
Improved cosmesis without need for lateral parapatellar incision
Allows for reconstruction with shorter graft
Disadvantages
Theoretical decrease in tendon-to-bone healing
Theoretical decrease in pullout fixation strength because of reduced volume of suture anchor

ASAs are composed of high-molecular-weight polyethylene sutures that pass through a flexible tube of braided material and have recently been used for arthroscopic repairs and reconstructions in shoulder, hip, and ankle joints. Their use in MPFL reconstruction has been theorized to reduce the risk of patellar fracture and violation of the articular surface even further than solid SAs.²⁰ This is achieved because of the all-soft nature of the anchor with reduced volume compared with solid SAs, which allows them to be placed in smaller-diameter tunnels.²⁰ The literature has shown that even with the reduced volume of ASAs, they provide adequate fixation. ASAs have been shown to have no difference in ultimate load to failure and pullout strength in shoulder pathology compared with solid SAs.^{18,19} In an evaluation of their use in MPFL reconstruction, no biomechanical differences were found in ultimate load to failure, displacement, or stiffness between ASA and SA fixation.²⁰ ASAs were also shown to exceed the ultimate load to failure of the native MPFL and deemed appropriate fixation for reconstruction.^{20,26}

Different techniques have been described in MPFL reconstruction for the proper tensioning of the graft, on either the patellar or femoral side. To date, there have not been any biomechanical studies evaluating whether a better anatomic reconstruction is achieved through patellar- or femoral-sided tensioning. In this technique, each individual limb is first secured into the patellar trough, re-creating the anatomic insertion of the MPFL, and then the looped graft is tensioned at the femur. In our experience, it is more challenging to tension 2 different points at the same time; therefore, tensioning the single loop on the femoral side creates an equally tensioned graft in a more reliable fashion.

The use of ASA fixation in MPFL reconstruction has the ability to decrease the risk of patellar fracture and articular surface damage even further than solid SAs while still providing adequate fixation. Further clinical studies are warranted to determine whether their use in MPFL reconstruction reduces complications.

References

1. Vetrano M, Oliva F, Bisicchia S, et al. I.S.Mu.L.T. first-time patellar dislocation guidelines. *Muscles Ligaments Tendons J* 2017;7:1-10.
2. Fithian DC, Paxton EW, Stone ML, et al. Epidemiology and natural history of acute patellar dislocation. *Am J Sports Med* 2004;32:1114-1121.
3. Mäenpää H, Huhtala H, Lehto MU. Recurrence after patellar dislocation. Redislocation in 37/75 patients followed for 6-24 years. *Acta Orthop Scand* 1997;68:424-426.
4. Buckens CFM, Saris DBF. Reconstruction of the medial patellofemoral ligament for treatment of patellofemoral instability: A systematic review. *Am J Sports Med* 2010;38:181-188.

5. Nomura E, Horiuchi Y, Inoue M. Correlation of MR imaging findings and open exploration of medial patellofemoral ligament injuries in acute patellar dislocations. *Knee* 2002;9:139-143.
6. Amis AA, Firer P, Mountney J, Senavongse W, Thomas NP. Anatomy and biomechanics of the medial patellofemoral ligament. *Knee* 2003;10:215-220.
7. Desio SM, Burks RT, Bachus KN. Soft tissue restraints to lateral patellar translation in the human knee. *Am J Sports Med* 1998;26:59-65.
8. Kyung H-S, Kim H-J. Medial patellofemoral ligament reconstruction: A comprehensive review. *Knee Surg Relat Res* 2015;27:133-140.
9. Song SY, Kim IS, Chang HG, Shin J-H, Kim HJ, Seo Y-J. Anatomic medial patellofemoral ligament reconstruction using patellar suture anchor fixation for recurrent patellar instability. *Knee Surg Sports Traumatol Arthrosc* 2014;22:2431-2437.
10. Christiansen SE, Jacobsen BW, Lund B, Lind M. Reconstruction of the medial patellofemoral ligament with gracilis tendon autograft in transverse patellar drill holes. *Arthroscopy* 2008;24:82-87.
11. Mikashima Y, Kimura M, Kobayashi Y, Miyawaki M, Tomatsu T. Clinical results of isolated reconstruction of the medial patellofemoral ligament for recurrent dislocation and subluxation of the patella. *Acta Orthop Belg* 2006;72:65-71.
12. Panni AS, Alam M, Cerciello S, Vasso M, Maffulli N. Medial patellofemoral ligament reconstruction with a divergent patellar transverse 2-tunnel technique. *Am J Sports Med* 2011;39:2647-2655.
13. Thauinat M, Erasmus PJ. Recurrent patellar dislocation after medial patellofemoral ligament reconstruction. *Knee Surg Sports Traumatol Arthrosc* 2008;16:40-43.
14. Toritsuka Y, Amano H, Mae T, et al. Dual tunnel medial patellofemoral ligament reconstruction for patients with patellar dislocation using a semitendinosus tendon autograft. *Knee* 2011;18:214-219.
15. Hapa O, Akşahin E, Özden R, et al. Aperture fixation instead of transverse tunnels at the patella for medial patellofemoral ligament reconstruction. *Knee Surg Sports Traumatol Arthrosc* 2012;20:322-326.
16. Schöttle PB, Fucentese SF, Romero J. Clinical and radiological outcome of medial patellofemoral ligament reconstruction with a semitendinosus autograft for patella instability. *Knee Surg Sports Traumatol Arthrosc* 2005;13:516-521.
17. Brown CA, Hurwit D, Behn A, Hunt KJ. Biomechanical comparison of an all-soft suture anchor with a modified Broström-Gould suture repair for lateral ligament reconstruction. *Am J Sports Med* 2014;42:417-422.
18. Galland A, Airaudi S, Gravier R, Le Cann S, Chabrand P, Argenson J-N. Pullout strength of all suture anchors in the repair of rotator cuff tears: A biomechanical study. *Int Orthop* 2013;37:2017-2023.
19. Mazzocca AD, Chowanec D, Cote MP, et al. Biomechanical evaluation of classic solid and novel all-soft suture anchors for glenoid labral repair. *Arthroscopy* 2012;28:642-648.
20. Saper MG, Meijer K, Winnier S, Popovich J, Andrews JR, Roth C. Biomechanical evaluation of classic solid and all-soft suture anchors for medial patellofemoral ligament reconstruction. *Am J Sports Med* 2017;45:1622-1626.
21. Nomura E, Horiuchi Y, Kihara M. Medial patellofemoral ligament restraint in lateral patellar translation and reconstruction. *Knee* 2000;7:121-127.
22. Sandmeier RH, Burks RT, Bachus KN, Billings A. The effect of reconstruction of the medial patellofemoral ligament on patellar tracking. *Am J Sports Med* 2000;28:345-349.
23. Smirk C, Morris H. The anatomy and reconstruction of the medial patellofemoral ligament. *Knee* 2003;10:221-227.
24. Elias DA, White LM, Fithian DC. Acute lateral patellar dislocation at MR imaging: Injury patterns of medial patellar soft-tissue restraints and osteochondral injuries of the inferomedial patella. *Radiology* 2002;225:736-743.
25. Sanders TG, Morrison WB, Singleton BA, Miller MD, Cornum KG. Medial patellofemoral ligament injury following acute transient dislocation of the patella: MR findings with surgical correlation in 14 patients. *J Comput Assist Tomogr* 2001;25:957-962.
26. Mountney J, Senavongse W, Amis AA, Thomas NP. Tensile strength of the medial patellofemoral ligament before and after repair or reconstruction. *J Bone Joint Surg Br* 2005;87:36-40.
27. Russ SD, Tompkins M, Nuckley D, Macalena J. Biomechanical comparison of patellar fixation techniques in medial patellofemoral ligament reconstruction. *Am J Sports Med* 2015;43:195-199.