

● IMAGING IN NEURAL REGENERATION

Optic radiation injury in a patient with intraventricular hemorrhage: a diffusion tensor tractography study

Optic radiation (OR) injury can occur following various brain injuries and it is usually accompanied by visual field defects (Zhang et al., 2006). OR is very important for performing activities of daily living and providing safety. However, the OR cannot be clearly demarcated from adjacent neural structures and thereby conventional brain MRI has limited specificity in diagnosis of OR injury. Diffusion tensor tractography (DTT), which is derived from diffusion tensor imaging (DTI), has enabled three-dimensional reconstruction of the OR. Many DTT studies have reported OR injury following various brain injuries (Shinoura et al., 2010; Lee et al., 2012; Seo et al., 2013; Jang and Seo, 2015), however, few DTT studies on OR injury have been reported.

In this study, we reported DTT findings of OR injury in one 58-year-old male patient. The patient was diagnosed with spontaneous subarachnoid hemorrhage, intraventricular hemorrhage (IVH), and intracerebral hemorrhage (ICH) in the left subcortical white matter, and underwent endovascular embolization and right frontal extraventricular drainage for ruptured arteriovenous malformation at the department of neurosurgery of a local hospital (Figure 1A). He complained of a right homonymous visual field defect and mild right hemiparesis since the onset, and visited a university hospital for precise evaluation at 12 months after onset. Brain MRI showed a leukomalactic lesion in the left subcortical white matter below the posterior limb of the internal capsule; however, no specific lesion was observed on the occipital lobe. Right bilateral homonymous hemianopia was detected in Humphrey Visual Field (HVF) test (Figure 1C).

After providing signed informed consent, the patient was included in this study under the approval by Institutional Review Board of Yeungnam University, Republic of Korea.

DTI data were acquired at 12 months after onset using a 1.5-T Philips Gyroscan Intera system (Philips, Ltd, Best, the Netherlands) equipped with a synergy-L Sensitivity Encoding (SENSE) head coil utilizing a single-shot, spin-echo planar imaging pulse sequence. For each of the 32 noncollinear and noncoplanar diffusion sensitizing gradients, 67 contiguous slices were acquired parallel to the anterior commissure-posterior commissure line. Imaging parameters were as follows: acquisition matrix = 96×96 ; reconstructed matrix = 192×192 ; field of view = 240×240 mm²; repetition time/echo time = 10,398/72 ms; SENSE factor = 2; EPI factor = 59, $b = 1,000$ s/mm², NEX = 1, slice thickness = 2.5 mm. Fiber tracking was performed using the fiber assignment continuous tracking (FACT) algorithm implemented within the DTI task card software (Philips Extended MR Workspace 2.6.3; Philips, Ltd, Best, the Netherlands). Each of the DTI replications was intra-registered to the baseline “b0” images in order to correct for residual eddy-current image distortions and head motion effect, using a diffusion registration package (Philips Medical Systems) (threshold fractional anisotropy = 0.15, angle = 27). ORs were ascertained by selection of

fibers passing through ROIs. The seed ROI was placed on the lateral geniculate nucleus (LGN) on the color map, and the target ROI was placed on the bundle of the OR at the middle portion between LGN and occipital pole (Hofer et al., 2010; Jang and Seo, 2015).

The right OR was reconstructed from the LGN to the primary visual cortex, while the left OR showed a discontinuation at the middle portion around the temporal horn of the lateral ventricle. Green color density of the left OR was largely decreased around the middle portion of the left OR (Figure 1B).

We reported on a patient who showed a left OR injury on DTT following SAH, IVH, and ICH, which was not detected by conventional brain MRI. This evidence of the left OR injury on DTT coincided well with the right bilateral homonymous hemianopia on the visual field test. According to the previous studies, all types of hemorrhages (SAH, IVH, and ICH) in this patient could cause neural injury (Chua et al., 2009; Yeo et al., 2011; Seo et al., 2013; Jang and Kim, 2015; Jang and Yeo, 2015). However, considering the anatomical locations of hemorrhages within the OR, the ICH around the LGB appeared to be the most plausible cause of the left OR injury. However, DTT showed discontinuation of the left OR in the middle portion around the temporal horn of the lateral ventricle, indicating an injury of the left OR by the hemorrhage in the lateral ventricle. Previous studies have suggested that injury to periventricular white matter by IVH could occur through mechanical (increased intracranial pressure or direct mass) or chemical mechanisms (a blood clot itself can cause extensive damage) (Chua et al., 2009; Yeo et al., 2011; Jang and Yeo, 2015). In this study, considering that the middle portion of the left OR is close to the temporal horn of the lateral ventricle, and the middle portion of the left OR appeared to be affected by hematoma in this ventricle.

In conclusion, we report on a patient who had a left OR injury detected by DTT. Our results suggest that DTT is a useful technique for detection of the OR injury not detected on conventional brain MRI. Therefore, we think that DTT for the OR should be recommended for more precise evaluation along with conventional brain MRI for patients who complain of visual field defect following brain injury. To the best of our knowledge, this is the first study to demonstrate OR injury following SAH, IVH, and ICH. However, this study is limited because it is a case report. Further complementary studies involving larger numbers of patients are warranted.

This work was supported by the National Research Foundation (NRF) of Korea Grant funded by the Korean Government (MSIP), No. 2015R1A2A2A01004073.

Sung Ho Jang, Jeong Pyo Seo*

Department of Physical Medicine and Rehabilitation, College of Medicine, Yeungnam University, Daemyungdong, Namku, Daegu, Republic of Korea

*Correspondence to: Jeong Pyo Seo, Ph.D., raphael0905@hanmail.net.

Accepted: 2015-10-10

orcid: 0000-0002-2695-7957 (Jeong Pyo Seo)

doi: 10.4103/1673-5374.184507

How to cite this article: Jang SH, Seo JP (2016) Optic radiation injury in a patient with intraventricular hemorrhage: a diffusion tensor tractography study. *Neural Regen Res* 11(6):1013-1014.

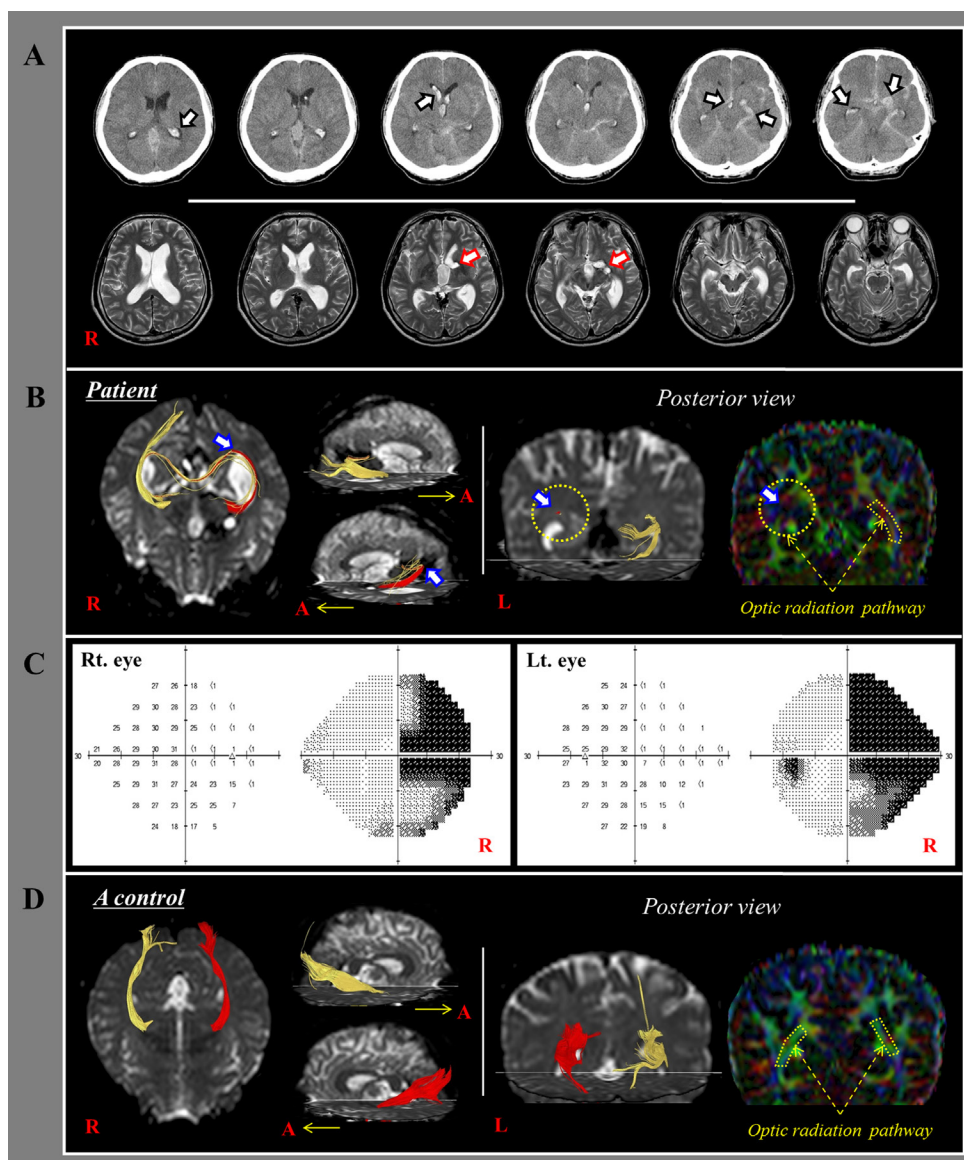


Figure 1 Results of CT, MRI, diffusion tensor tractography (DTT), and Humphrey visual field test in a 58-year-old male patient with intraventricular hemorrhage.

(A) Brain CT images (upper row) at onset show subarachnoid hemorrhage, intraventricular hemorrhage, and intracerebral hemorrhage (arrows) in the left subcortical white matter. Brain MR images (lower row) at 12 months after onset show a leukomalactic lesion (arrows) in the left subcortical white matter below the internal capsule. (B) On 12-month DTT, the left optic radiation (OR) is discontinued (arrow) at the middle portion around the temporal horn of the lateral ventricle. Green color density of the left OR is greatly decreased (arrow) around the middle portion of the left OR. (C) The Humphrey visual field test of the patient shows right bilateral homonymous hemianopsia. (D) DTT for the OR in a normal 57-year-old male subject. R or Rt.: Right; A: anterior; L or Lt.: left.

References

- Chua CO, Chahboune H, Braun A, Dummula K, Chua CE, Yu J, Ungvari Z, Sherbany AA, Hyder F, Ballabh P (2009) Consequences of intraventricular hemorrhage in a rabbit pup model. *Stroke* 40:3369-3377.
- Hofer S, Karaus A, Frahm J (2010) Reconstruction and dissection of the entire human visual pathway using diffusion tensor MRI. *Front Neuroanat* 4:15.
- Jang SH, Seo JP (2015) Damage to the optic radiation in patients with mild traumatic brain injury. *J Neuroophthalmol* 35:270-273.
- Jang SH, Kim HS (2015) Aneurysmal subarachnoid hemorrhage causes injury of the ascending reticular activating system: relation to consciousness. *AJNR Am J Neuroradiol* 36:667-671.
- Jang SH, Yeo SS (2015) Injury of the lower portion of the ascending reticular activating system in a patient with intraventricular hemorrhage. *Int J Stroke* 10 Suppl A100:162-163.
- Lee AY, Shin DG, Park JS, Hong GR, Chang PH, Seo JP, Jang SH (2012) Neural tracts injuries in patients with hypoxic ischemic brain injury: diffusion tensor imaging study. *Neurosci Lett* 528:16-21.
- Seo JP, Choi BY, Chang CH, Jung YJ, Byun WM, Kim SH, Kwon YH, Jang SH (2013) Diffusion tensor imaging findings of optic radiation in patients with putaminal hemorrhage. *Eur Neurol* 69:236-241.
- Shinoura N, Suzuki Y, Yamada R, Tabei Y, Saito K, Yagi K (2010) Relationships between brain tumor and optic tract or calcarine fissure are involved in visual field deficits after surgery for brain tumor. *Acta Neurochir (Wien)* 152:637-642.
- Yeo SS, Choi BY, Chang CH, Jung YJ, Ahn SH, Son SM, Byun WM, Jang SH (2011) Periventricular white matter injury by primary intraventricular hemorrhage: a diffusion tensor imaging study. *Eur Neurol* 66:235-241.
- Zhang X, Kedar S, Lynn MJ, Newman NJ, Biouesse V (2006) Homonymous hemianopia in stroke. *J Neuroophthalmol* 26:180-183.