



# Negative Chronotropic Cardiovascular Changes in Lumbar Spine Surgery: A Potential Spinal-Cardiac Reflex?

Kashif Ali Sultan<sup>1</sup> Mohammad Ashraf<sup>2</sup> Attika Chaudhary<sup>2</sup> Lulwa Al Salloum<sup>2</sup>  
 Naseeruddin Ghulam<sup>1</sup> Nazir Ahmed<sup>1</sup> Hassan Ismahel<sup>2</sup> Minaam Farooq<sup>3</sup> Javed Iqbal<sup>3</sup>  
 Naveed Ashraf<sup>1</sup>

<sup>1</sup>Department of Neurosurgery, Allama Iqbal Medical College, Jinnah Hospital, Lahore, Pakistan

<sup>2</sup>Wolfson School of Medicine, University of Glasgow, Scotland, United Kingdom

<sup>3</sup>School of Medicine, King Edward Medical University, Lahore, Pakistan

Address for correspondence Kashif Ali Sultan, MD, MS (Neurosurgery), FACS (Neurosurgery), Department of Neurosurgery, Allama Iqbal Medical College, Jinnah Hospital, Faisal Town, Lahore, 54550, Pakistan (e-mail: sultankashif11@gmail.com).

AJNS 2023;18:404–409.

## Abstract

Cardiovascular changes following lumbar spine surgery in a prone position are exceedingly rare. Over the past 20 years, a total of six cases have been published where patients experienced varying degrees of bradycardia, hypotension, and asystole, which could be attributed to intraoperative dural manipulation. As such, there is emerging evidence for a potential neural-mediated spinal-cardiac reflex. The authors report their experience of negative chronotropy during an elective lumbar spine surgery that coincided with dural manipulation and review the available literature. A 34-year-old male presented with a long-standing history of lower back pain recently deteriorating to bilaterally radiating leg pain, with restricted left leg raise, and numbness at the left L5 dermatomal territory. The patient was an athletic police officer with no comorbidities or past medical history. Magnetic resonance imaging lumbosacral spine revealed spinal stenosis most pronounced at L4/L5 and disc bulges at L3/L4 and L5/S1. The patient opted for lumbar decompression surgery. After an unremarkable comprehensive preoperative workup, including cardiac evaluation (electrocardiogram, echocardiogram), the patient was induced general anesthesia in a prone position. A lumbar incision was made from L2 to S1. When the left L4 nerve root was retracted while removing the prolapsed disc at L4/L5, the anesthetist cautioned the surgeon of bradycardia (34 beats per minute [bpm]), and the surgery was immediately stopped. The heart rate improved to 60 bpm within 30 seconds. When the root was later retracted again, a second episode of bradycardia occurred for 4 minutes with heart rate declining to 48 bpm. The surgery was stopped, and after 4 minutes, the anesthetist administered 600 µg of atropine. The heart rate then rose to 73 bpm within 1 minute. Other potential causes for bradycardia were excluded. The total blood loss was estimated to be 100 mL. He remains well at his 6-month follow-up and has returned to work as normal.

## Keywords

- ▶ bradycardia
- ▶ negative chronotropy
- ▶ lumbar spine
- ▶ mechanism
- ▶ spinal-cardiac reflex

article published online  
 June 16, 2023

DOI <https://doi.org/10.1055/s-0043-1769894>.  
 ISSN 2248-9614.

© 2023. Asian Congress of Neurological Surgeons. All rights reserved.

This is an open access article published by Thieme under the terms of the Creative Commons Attribution-NonDerivative-NonCommercial-License, permitting copying and reproduction so long as the original work is given appropriate credit. Contents may not be used for commercial purposes, or adapted, remixed, transformed or built upon. (<https://creativecommons.org/licenses/by-nc-nd/4.0/>)

Thieme Medical and Scientific Publishers Pvt. Ltd., A-12, 2nd Floor, Sector 2, Noida-201301 UP, India

Akin to previously published cases, each episode of bradycardia coincided with dural manipulation, which may indicate a possible reflex between the spinal dura mater and the cardiovascular system. Such a rare adverse event may occur even in seemingly healthy, young individuals, and anesthetists should caution the operating surgeon of bradycardias to exclude operative manipulation of the dura as the cause. While this phenomenon is only reported in a handful of lumbar spine surgery cases, it provides evidence for a potential spinal-cardiac physiological reflex in the lumbar spine that may be neural mediated and should be investigated further.

## Introduction

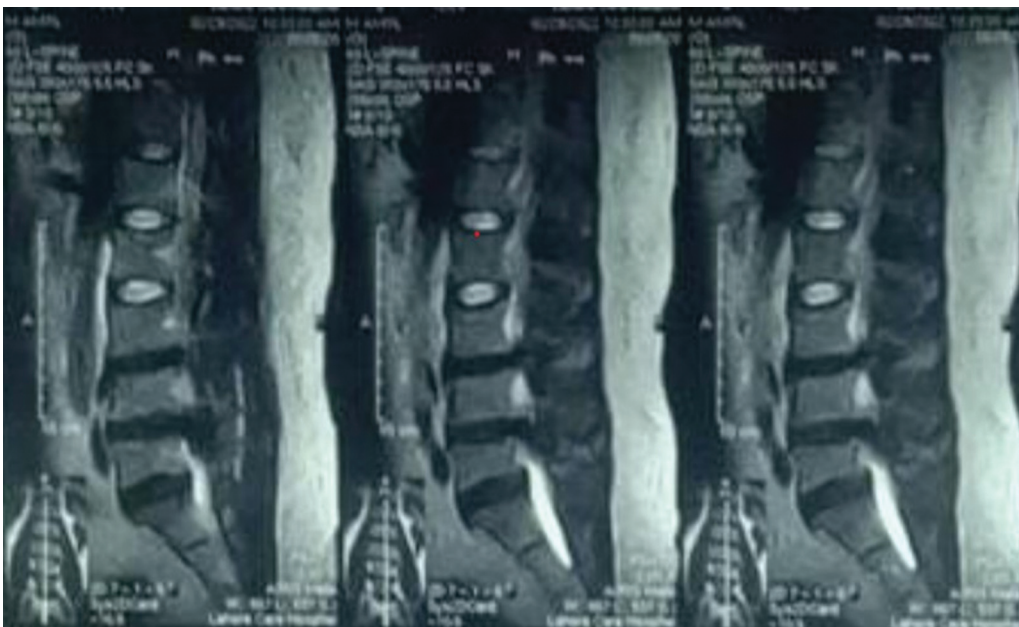Back pain is a common reason to seek emergency care.<sup>1</sup> Lower back pain is a symptom and not a specific disease.<sup>2</sup> Lower back pain has many potential causes, the vast majority of which can and should be managed conservatively, while many require surgical management.<sup>1-3</sup> Examples of cases which require surgical interventions include nonradicular lower back pain with degenerative changes (disc disease), discectomy for radiculopathy with lumbar disc herniation, and decompressive laminectomy (with or without fusion) for symptomatic spinal stenosis.<sup>3</sup> In general, such spinal surgery is safe, especially in healthy young individuals without comorbidities, where early surgery may be important in allowing patients to regain important day-to-day function and return to work.<sup>4,5</sup>

The interaction between the cardiovascular system and the nervous system is complex. Acute hemodynamic disturbance due to neural mechanisms is well known in cranial neurosurgical patients and spinal surgery in the cervical and upper dorsal segments.<sup>6-8</sup> However, adverse cardiovascular changes during lumbosacral spinal surgery are exceedingly rare, with only six reported papers as of 2023. Of these, only

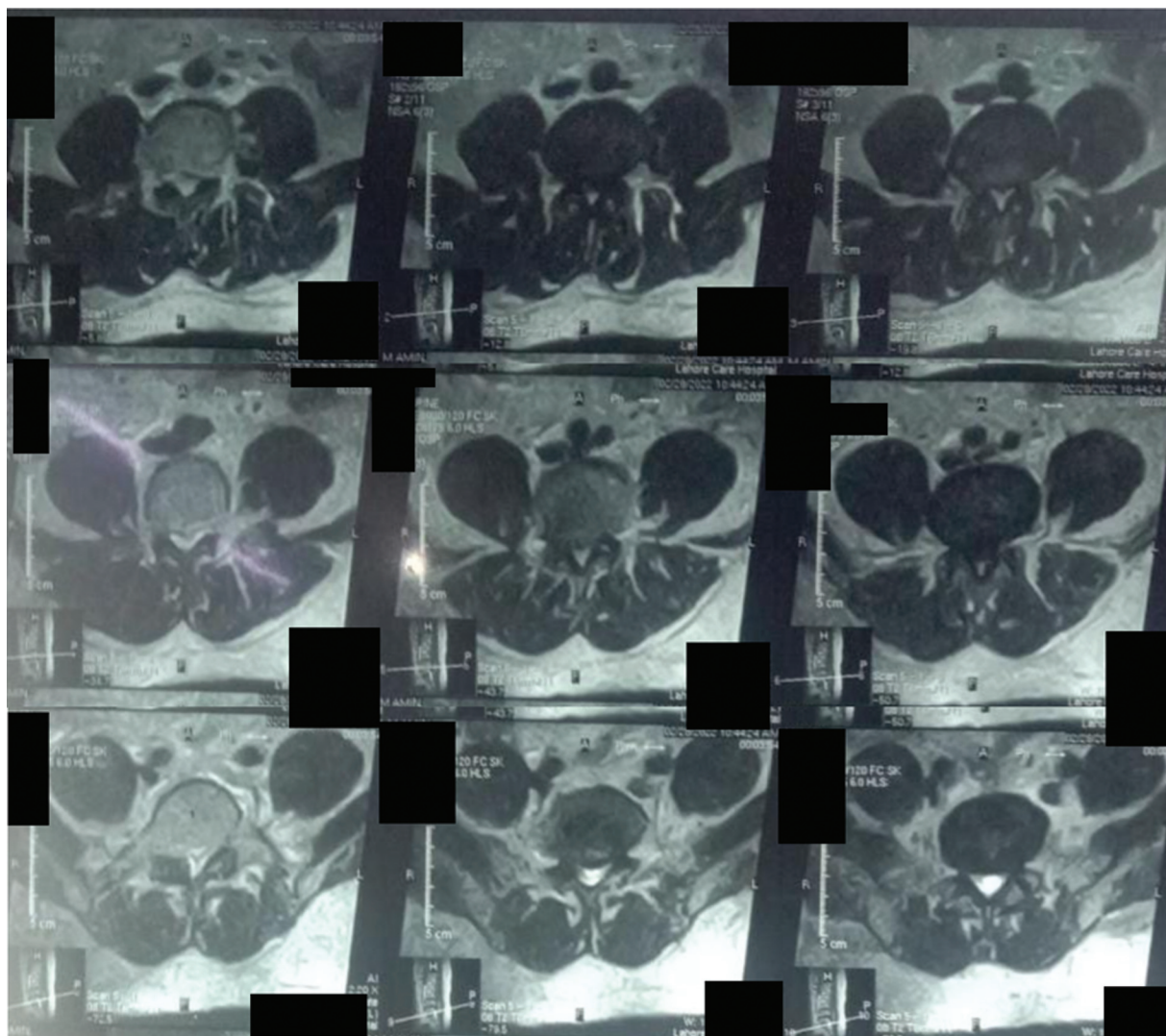
four are case reports, while two are letters/commentaries. The authors report a case of elective lumbosacral decompression surgery where negative chronotropic changes were encountered and review the available literature on cardiovascular changes during lumbar spine surgery.

## Case Presentation

A 34-year-old male presented due to our neurosurgery department with a long-standing history of lower back pain, which began radiating bilaterally to his lower limbs over the last 4 months. His condition had deteriorated further over the last 10 days with increasing pain, restricted straight left leg raising ability, and numbness at the L5 dermatomal territory in his left foot. Power was 5/5 (Medical Research Council scale) bilaterally, and reflexes were mildly brisk. An magnetic resonance imaging of the lumbosacral spine revealed lumbar stenosis most pronounced at L4/L5 and disc bulges at L3/L4 and L5/S1 (–Figs. 1 and 2). His visual analogue pain score (VAS) was now 6. The patient was a police officer whose symptoms now severely hindered his job, causing time off and stress, significantly impairing his



**Fig. 1** Magnetic resonance imaging lumbosacral spine T2 sequence. Sagittal view showing lumbar stenosis most pronounced at L4/L5 and prolapsed intervertebral discs at L3-L4 and L5-S1.



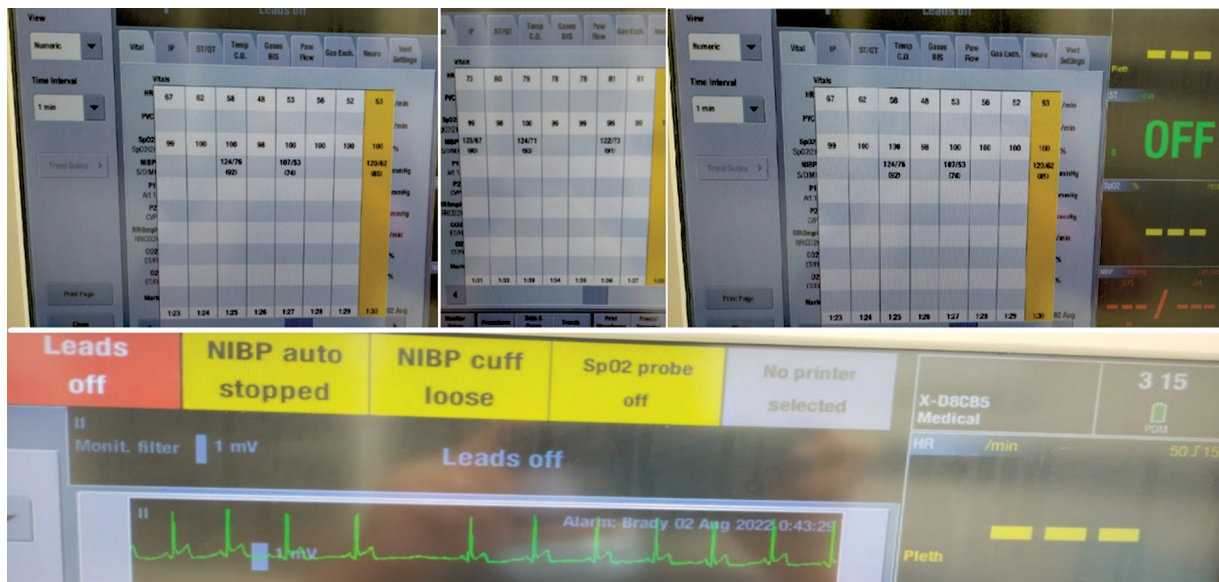
**Fig. 2** Magnetic resonance imaging lumbosacral spine T2 sequence. Axial view of posterior intervertebral discs and stenosis. Top row shows tight stenosis at L3-L4. Middle row showing mild stenosis at L4-L5. Bottom row shows mild stenosis at L5-S1.

quality of life. Given his clinical condition, it was decided to opt for surgical intervention. The patient was booked for surgery the next day. As per our hospital's protocol for any major surgery, a comprehensive anesthetic and cardiology evaluation was performed, including blood work, electrocardiogram, and echocardiogram. This is our hospital's anesthesia department policy for patients undergoing their first surgery, as there is often a lack of previous medical input/primary care information in our country due to poor infrastructure. The patient had no prior medical history and had an athletic build, weighing 90 kg and was 6 feet tall (body mass index 26.9). He did not have any past medical, pharmacological, or family history, nor did he smoke or drink alcohol.

General anesthesia was induced in a prone position with propofol 180 mg, midazolam 2 mg, nalbuphine 10 mg, and suxamethonium 100 mg. A lumbar incision was made from L2 to S1. The muscles were separated, and the spinous process of L4 was completely removed, while the L3 and L5 spinous process and laminae were partially removed. Intraoperatively, it was noted that there was very tight

stenosis from a thickened ossified ligamentum flavum at L3/L4 and L4/L5 and bilateral compression of nerve roots at both levels. The lateral ligaments were removed at the level of L3/L4 and partially at L5/S1. The left L4 nerve root was retracted while removing the prolapsed disc at L4/L5, and suddenly, the anesthetist cautioned the surgeon of bradycardia, 34 beats per minute (bpm), and the surgery was immediately stopped with the heart rate (HR) improving to 60 bpm within 30 seconds. When the root was retracted again after 3 minutes, a second episode of bradycardia occurred, with the HR declining to 48 bpm. The surgery was stopped again, and after 4 minutes, the anesthetist administered 600 µg of atropine. The HR then jumped to 73 bpm, after which the surgery resumed. During the operation, there was no point where the patient experienced a drop in oxygen saturation, end-tidal CO<sub>2</sub>, temperature, or an upset in acid-base balance. These changes and their time of occurrence are shown on the anesthesia monitor (→ Fig. 3). An intraoperative literature search suggested this phenomenon to be attributed to nerve root manipulation and/or dural traction; therefore, the discectomy proceeded with extreme caution and was





**Fig. 3** The second bradycardia occurring at 1:26 PM (heart rate 48 beats per minute). Bradycardia was sustained for 4 minutes, and atropine was administered at 1:30 PM, after which the heart rate rose to 73 beats per minute at 1:31 PM.

uneventful. Total blood loss was estimated to be approximately 100 mL.

Discussing with our cardiology and anesthesia colleagues, we all felt this was not an allergic reaction to the anesthesia medication as the episode was specific to dural manipulation; therefore, anaphylaxis workup was not performed (e.g., mast cell tryptase). Additionally, our cardiology colleagues advised transferring our patient to our neurointensive care unit for continuous cardiac monitoring for 24 hours. The patient was then transferred to the general neurosurgical ward with cardiac monitoring, which was also unremarkable. The patient was discharged without complication on the fourth postoperative day with a VAS score of 3. Given his preoperative cardiac workup and postoperative monitoring, cardiology also did not feel the need for continuous cardiac monitoring such as a Holter monitor. At the 6-month follow-up, the patient was well and resumed his occupational activity levels to what they were before his back pain 1 month postoperatively.

### Discussion

There is a scarcity of cases demonstrating hemodynamic changes during spinal surgery,<sup>9-14</sup> but their existence suggests that there may be a reflex mechanism in the spine as there is in the autonomous cerebral system similar to the trigeminocardiac reflex (TCR).<sup>15</sup> The current understanding of such a phenomenon is based on the current case in the literature. These are summarized in **Table 1**.

While cardiovascular changes occur in cranial neurosurgical patients from several mechanisms/reflexes such as Cushing's syndrome, neurogenic, brainstem, the TCR, hemodynamic changes in spinal surgeries are limited to major bleeds, shock, autonomic dysreflexia, anesthesia related, medications and interactions, venous air embolisms, acid-base upset, prone positioning, hypothermia, and anaphylax-

is.<sup>6-8</sup> In our case and the six reported cases in the literature, each of these potential reasons could be excluded, and a cause-and-effect relationship could be established as the bradycardia coincided with the surgical stimulus.<sup>9-14</sup> The appearance of negative chronotropic changes in all cases was noted during dural manipulation (direct or indirect), suggesting an underlying neurogenic control. Chowdhury and Schaller<sup>15</sup> postulate this results from parasympathetic nerve activation, resulting in a negative chronotropic response similar to a vasovagal reflex.<sup>15</sup> This may be due to a mechanical stretch of the dura, which has both intrinsic and extrinsic innervation.<sup>16</sup> There may also be a certain threshold triggering such a reflex, which may explain why every dural manipulation won't trigger such a response.

The most recent reported case by Mahajan et al<sup>14</sup> observed decreases in HR (38bpm) and blood pressure (72/34 mm Hg) three times, each coinciding with dural manipulation during transforaminal dilation.<sup>14</sup> This is similar to our case where the bradycardia occurred twice, each time coinciding with nerve root retraction, but unlike Mahajan et al's case<sup>14</sup> the first episode improved in 30 seconds, but the second episode of bradycardia was sustained for over one and a half minutes, and the anesthetist deemed it appropriate to push atropine. Mahajan et al's case<sup>14</sup> is the only case where cardiovascular changes reverted after withdrawal of the surgical stimulus, but the remaining five cases used anticholinergic and sympathomimetic drugs.<sup>9-14</sup> This may be due to the former waiting slightly longer to observe natural improvement, while the remaining cases had a low threshold to intervene.

A parallel example is the TCR that also results from a stretch response during direct or indirect manipulation of the cranial dura leading to bradycardia and hypotension when the sensory branches of the trigeminal nerve are stimulated.<sup>8</sup> This spinal-cardiac reflex observed by dural manipulation may be its own entity. Human anatomical

**Table 1** The published cases on negative chronotropic changes during lumbar spine surgery

Author	Age/Sex	Procedure	Position	Cardiac rhythm	Management	Outcome
Deschamps and Carvalho 2004 <sup>9</sup>	37/F	L5-S1 spine decompression	Prone	Several episodes of bradycardia	IV adrenaline	Alive without neurological deficits
Mandal 2004 <sup>10</sup>	36/M	L4/5 Discectomy	Prone	Two episodes of bradycardia	IV atropine	Alive without neurological deficits
Dooney 2010 <sup>11</sup>	43/M	L4-L5 microscopic discectomy	Prone	Severe bradycardia followed by asystole	IV adrenaline and CPR	Alive without neurological deficits
Chowdhury et al 2012 <sup>13</sup>	58/F	Lumbar decompression and fusion	Prone	Several severe hypotensive and hypertensive episodes	Fentanyl	Alive without neurological deficits
Chowdhury et al 2017 <sup>12</sup>	72/F	Lower lumbar transforaminal interbody fusion	Prone	Severe bradycardia and hypotension	Removal of stimulus and ephedrine	Alive without neurological deficits
Mahajan et al 2015 <sup>14</sup>	72/F	L2-L5 Lumbar spine decompression and transforaminal interbody fusion	Prone	Several episodes of bradycardia and hypotension	Removal of stimulus	Alive without neurological deficits

Abbreviations: CPR, cardiopulmonary resuscitation; F, female; M, male; IV, intravenous.

studies confirm the existence of extrinsic and intrinsic innervation of the spinal dura mater.<sup>16</sup> Surgical manipulation from decompression/dilation provokes the stimulation of afferent parasympathetic fibers and inhibition of sympathetic fibers, providing evidence for a unique afferent but a similar efferent pathway to the TCR.<sup>8,15,16</sup> Finally, some authors who observed hypotension (in addition to bradycardia) have suggested that this underlying spinal-cardiac reflex may be more parallel to a vasovagal (reflex celiac) reaction or the Bezold-Jarisch reflex.<sup>14,17</sup> Or, there may be a possible link with pelvic visceral afferent pathways where fibers around the L5-S1 nerve roots can, in rare cases, be activated via afferent parasympathetic pathways.<sup>14</sup> The Breuer-Lockhart reflex produces a comparable response to this whereby there is the activation of the afferent parasympathetic fibers in response to anal/perianal stimulation.<sup>14</sup> While the specific nuance of this spinal-cardiac reflex is yet to be fully understood, we agree with previous cases that there must be some central brain stem connection for this apparent lumbar spine-brainstem-heart loop that results in the negative chronotropic changes.<sup>9-15</sup>

Negative chronotropy/hypotension during spinal surgery may necessitate intervention with fluids, anticholinergic medication, and pressors. It is important to remember that while such rare events are reported in the literature, they may not necessarily be transient changes, as one reported case on this spinal-cardiac reflex transitioned to asystole.<sup>11</sup> Most of the patients where this spinal-cardiac reflex was reported were young, fit individuals without any comorbidities (including cardiac), which may mean young age is a risk factor similar to vasovagal responses.<sup>8,12,15</sup> As invasive hemodynamic monitoring is not always done in elective spinal surgeries and this spinal-cardiac reflex may be transient, this may be one reason why only so few cases have been reported. Future research should evaluate this phenomenon in both clinical and laboratory settings.

## Conclusion

Lumbar spine surgery in a prone position may lead to negative chronotropic changes secondary to the activation of an unidentified underlying neural mechanism that triggers a physiological reflex. The most likely trigger for this is dural manipulation. The anesthetist must carefully monitor cardiovascular changes in seemingly simple elective spinal surgeries, and the surgeon must be cautioned of bradycardia so a dural stimulus can be ruled out, along with the established causes. Future studies should evaluate the potential neuronal pathways that may lead to hemodynamic changes in lumbar spinal surgery.

### Informed Consent

Complete written informed consent was obtained from the patient prior to publication for the anonymized use of their clinical information and radiological images.

### Funding

None.

### Conflict of Interest

None declared.

## References

- 1 Freburger JK, Holmes GM, Agans RP, et al. The rising prevalence of chronic low back pain. *Arch Intern Med* 2009;169(03):251-258
- 2 Bartleson JD. Low back pain. *Curr Treat Options Neurol* 2001;3(02):159-168
- 3 Chou R, Baisden J, Carragee EJ, Resnick DK, Shaffer WO, Loeser JD. Surgery for low back pain: a review of the evidence for an American Pain Society Clinical Practice Guideline. *Spine* 2009;34(10):1094-1109
- 4 Khan I, Bydon M, Archer KR, et al. Impact of occupational characteristics on return to work for employed patients after elective lumbar spine surgery. *Spine J* 2019;19(12):1969-1976

- 5 Singh S, Ailon T, McIntosh G, et al. Time to return to work after elective lumbar spine surgery. *J Neurosurg Spine* 2021. Doi: 10.3171/2021.2.SPINE202051
- 6 Partida E, Mironets E, Hou S, Tom VJ. Cardiovascular dysfunction following spinal cord injury. *Neural Regen Res* 2016;11(02):189–194
- 7 Chowdhury T, Petropolis A, Cappellani RB. Cardiac emergencies in neurosurgical patients. *BioMed Res Int* 2015;2015:751320
- 8 Chowdhury T, Mendelowith D, Golanov E, et al; Trigemino-Cardiac Reflex Examination Group. Trigemino-cardiac reflex: the current clinical and physiological knowledge. *J Neurosurg Anesthesiol* 2015;27(02):136–147
- 9 Deschamps A, Carvalho G. Lumbo-sacral spine surgery and severe bradycardia. *Can J Anaesth* 2004;51(03):277
- 10 Mandal NG. More on lumbo-sacral spine surgery and bradycardia. *Can J Anaesth* 2004;51(09):942–943
- 11 Dooney N. Prone CPR for transient asystole during lumbosacral spinal surgery. *Anaesth Intensive Care* 2010;38(01):212–213
- 12 Chowdhury T, Sapra H, Dubey S. Severe hypotension in transforaminal lumbar interbody fusion surgery: is it vasovagal or? *Asian J Neurosurg* 2017;12(01):149–150
- 13 Chowdhury T, Narayanasamy S, Dube SK, Rath GP. Acute hemodynamic disturbances during lumbar spine surgery. *J Neurosurg Anesthesiol* 2012;24(01):80–81
- 14 Mahajan S, Swami AC, Kumar A. Cardiovascular changes and lumbar spine surgery: a neglected entity. *Asian J Neurosurg* 2019;14(04):1253–1255
- 15 Chowdhury T, Schaller B. The negative chronotropic effect during lumbar spine surgery: a systemic review and aggregation of an emerging model of spinal cardiac reflex. *Medicine (Baltimore)* 2017;96(01):e5436
- 16 Groen GJ, Baljet B, Drukker J. The innervation of the spinal dura mater: anatomy and clinical implications. *Acta Neurochir (Wien)* 1988;92(1–4):39–46
- 17 Kinsella SM, Tuckey JP. Perioperative bradycardia and asystole: relationship to vasovagal syncope and the Bezold-Jarisch reflex. *Br J Anaesth* 2001;86(06):859–868