

Malignant peripheral nerve sheath tumor: A rare malignancy

Sheetal Sharma, Jigna S Shah¹, Harleen Bali²

Department of OMR, AIIMS, New Delhi, ¹Department of OMR, GDCH, Ahmedabad, Gujarat, India, ²Department of OMR, Dhulikhel Hospital, Kathmandu University, School of Medical Sciences, Nepal

Abstract

Malignant peripheral nerve sheath tumor (MPNST) is also termed as spindle cell malignancy of the peripheral nerve Schwann cell. It is a rare and highly aggressive, soft-tissue sarcoma of ectomesenchymal origin that accounts for 10% of all sarcomas and only 10%–12% of all lesions occur in the head-and-neck region, thus making it a rare entity. It arises *de novo* or from the preexisting benign neurofibroma. The diagnosis of MPNST is one of the most elusive among the soft-tissue tumors because of its greater variability in overall presentation both clinically and histologically. This difficulty can be overcome by the use of immunohistochemistry. This article presents a rare case of MPNST of the oral cavity in a 40-year-old female patient with a brief review of the current literature.

Keywords: Malignant nerve sheath tumor, neurofibromatosis, peripheral nerve origin, rare malignancy, S-100 protein

Address for correspondence: Dr. Sheetal Sharma, G-7 Leela Homes, Vaishali, Ghaziabad, Uttar Pradesh, India.
E-mail: sheetalsharma527@gmail.com

Received: 08.01.2020, **Accepted:** 10.01.2020, **Published:** 28.02.2020

INTRODUCTION

Malignant peripheral nerve sheath tumors (MPNSTs) are the sarcoma of aggressive nature having a neural origin and show a close association with peripheral nerve or may show features of neural differentiation.^[1,2] It is an extremely rare malignancy representing 10% of all soft-tissue sarcomas.^[1-3] It accounts for only 10%–12% of all lesions that occur in the head-and-neck region, which makes it a rare entity.^[1-4] It is encountered commonly, that is, around 50% of patients with neurofibromatosis (NF) Type I.

The diagnosis of MPNST has been described as one of the most difficult and elusive among soft-tissue tumors because of its nonspecific presentation both clinically as well as histopathologically. This enigma can be overcome

using immunohistochemistry (IHC).^[1] The treatment of choice is surgical excision, with adjuvant radiation and/or chemotherapy. This article aims to highlight, in depth, its various clinicopathological characteristics and the role of IHC findings that differentiate MPNST from other commonly encountered spindle cell malignancies. The unique feature in our report is the short duration of the tumor in a young patient, which might raise suspicion of malignancy.

CASE REPORT

A 40-year-old female patient reported to the department of oral medicine and radiology with a swelling on the right side of the mandible for 2 months. The lesion grew rapidly to reach the present size with no other associated symptoms. The patient's medical and family histories were noncontributory. Extraoral examination revealed a

This is an open access journal, and articles are distributed under the terms of the Creative Commons Attribution-NonCommercial-ShareAlike 4.0 License, which allows others to remix, tweak, and build upon the work non-commercially, as long as appropriate credit is given and the new creations are licensed under the identical terms.

For reprints contact: reprints@medknow.com

How to cite this article: Sharma S, Shah JS, Bali H. Malignant peripheral nerve sheath tumor: A rare malignancy. *J Oral Maxillofac Pathol* 2020;24:S86-90.

Access this article online

Quick Response Code:



Website:

www.jomfp.in

DOI:

10.4103/jomfp.JOMFP_9_20

well-defined oval-shaped swelling of size approximately 4 cm × 3 cm on the right side of the face. The skin over the swelling was stretched and surrounding tissues appeared normal. The swelling was firm in consistency, nonfluctuant, nonreducible with no evidence of paresthesia, or weakness on examination of both sensory and motor branches of mandibular nerve [Figure 1]. The intraoral examination showed obliteration of the right buccal vestibule with no expansion of cortical plates.

Contrast-enhanced computed tomogram showed a large heterogeneous enhancing space-occupying lesion of the soft-tissue density measuring 3.5 × 6.2 × 2.5 in relation to the right gingivobuccal sulcus. The lesion abuts right submandibular gland and displaced it inferiorly suggesting possible neoplastic etiology [Figure 2]. For confirmation, an incisional biopsy was done which revealed streaming fascicles of atypical spindle-shaped cells interspersed with hypocellular and myxoid regions. The atypical spindled lesional cells demonstrate wavy or comma-shaped hyperchromatic nuclei with indistinct cytoplasm. Cellular and nuclear pleomorphism is seen. Sections were of poorly differentiated malignant tumors with extensive involvement of skeletal muscle [Figures 3 and 4]. IHC was advised to rule out the possibility of fibrosarcoma, leiomyosarcoma, and synovial sarcoma using Vimentin, S-100, leukocyte common antigen, and all these markers showed strong immunopositivity for tumor cells, hence, favoring the diagnosis of MPNST [Figures 5 and 6]. Based on information obtained by clinical, histopathological, and immunohistochemical investigations, a final diagnosis of MPNST was made.

MPNST has a rare possibility of metastasis, so to rule, a chest radiograph was advised, which was reported to be normal. The patient underwent a wide local excision under general anesthesia postoperative histopathological findings and IHC confirmed the diagnosis. Subsequently, the patient was treated with radiotherapy, that is, 60 Gy in 10 fractions. She was subsequently kept under follow-up. No evidence of recurrence was noted in the 6-month follow-up period [Figure 7].

DISCUSSION

The principal malignancy of peripheral nerve origin is preferably called a MPNST.^[1-3] Previously, various terminologies such as neurogenic sarcoma, neurilemmosarcoma, malignant fibrosarcoma, and malignant neurilemmoma had been used, but the World Health Organization has recently adopted the term “MPNST” to denote such tumors and it corresponds

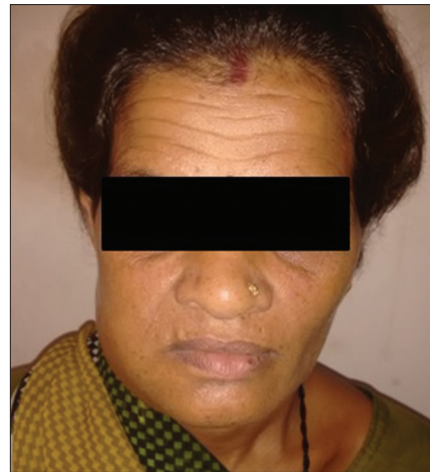

Figure 1: Extraoral photograph showing diffuse swelling on the right lower third of the face

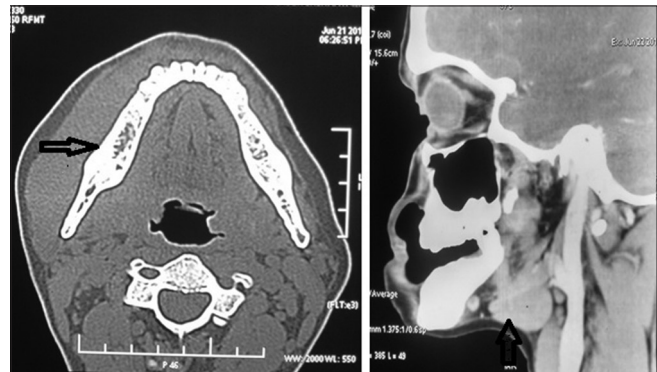


Figure 2: Computed tomography scan (axial and sagittal section) showing large heterogeneous density lesion of size measuring 3.5 × 6.2 × 2.5 in inferior aspect of the right gingivobuccal sulcus. The lesion abuts submandibular gland and displaces it inferiorly with no bony involvement

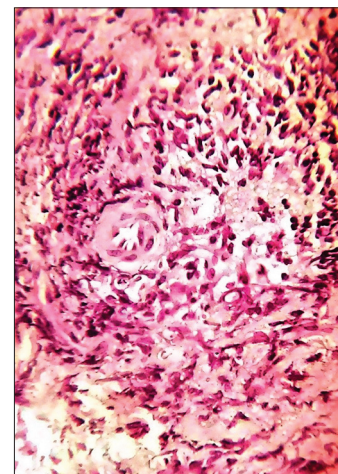


Figure 3: Histological picture showing spindle-shaped cells (H&E, ×40)

to the malignant proliferation of any cell of the nerve sheath: Schwann cell, perineural fibroblast, or endoneurial fibroblast.^[2,5,6]

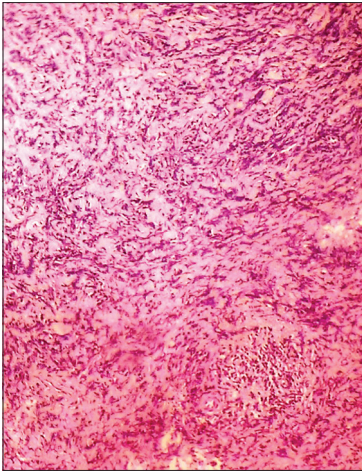


Figure 4: Alternating fascicles of hypercellular and hypocellular areas arranged in a streaming pattern (H&E, ×10)

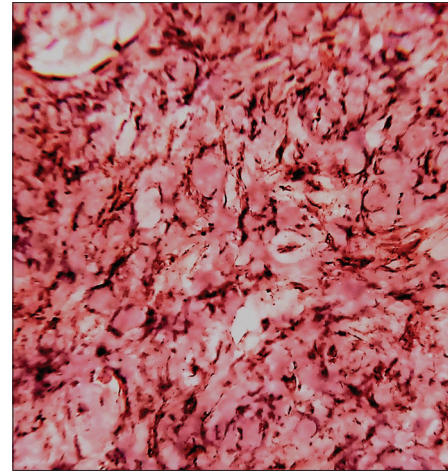


Figure 5: Photomicrograph showing immunopositivity for S-100 (×40)

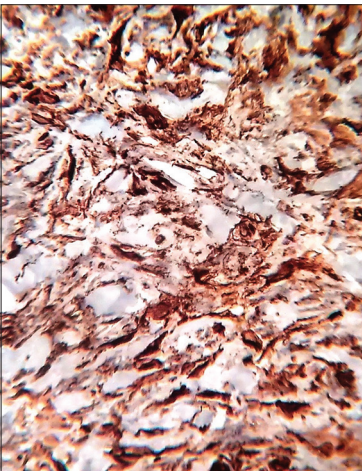


Figure 6: Photomicrograph showing immunopositivity for Vimentin (×40)

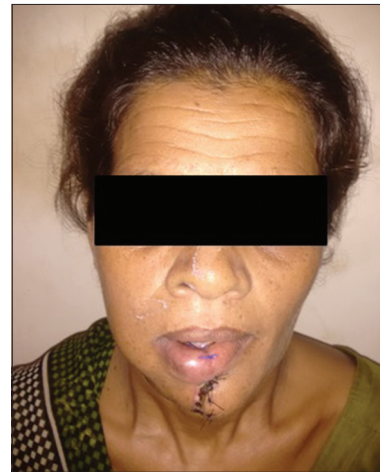

Figure 7: Extraoral postoperative photograph

A sarcoma is defined as an MPNST when at least one of the following criteria is met: it arises from a peripheral nerve or/it arises from a preexisting benign nerve sheath tumor (neurofibroma) or/it demonstrates Schwann cell differentiation on histologic examination.^[2,3] Although the histogenesis of MPNST remains unclear,^[1-3,6] its development is thought to be a multistep and multigene process with etiology being the loss of chromosomal arm 17q sequence, including complete inactivation of NF1 gene. This gene encodes a protein known as neurofibromin, which is believed to be important in the control of cell growth through their downregulation of *ras* gene products. Even though the precise chromosomal location of the *NF-1* gene on chromosome 17 is known, neither the primary defect in *NF-1* nor the mechanism leading to malignant transformation is understood at present. About 40%–50% of MPNST is associated with a family history of NF1.^[2,3]

It may also arise in areas previously treated with radiation therapy.^[1-4,6,7] Since our patient denied any previous benign

pathology that may have been likened to be NF, a *de novo* origin was considered for the present case.

This tumor occurs in the age group of 20–50 years having equal sex predilection.^[1-7] Usually, it occurs in the extremities, trunk and seldom found in the head-and-neck region.^[1-7] The tumors may occur anywhere in the oral cavity, but the most common sites are the mandible, lips, buccal mucosa, paranasal sinus, nasal cavity, orbit, cranial nerves, larynx, parapharyngeal or pterygomaxillary space, minor salivary glands, and the thyroid gland.^[1,3,6,8,9] Clinically, presenting as an enlarging mass, often associated with pain and nerve deficit. As such these malignancies are fleshy inconsistency and are confluent with adjacent tissues from where they spread through direct extension, hematogenous extension, and perineural spread. Lymph node metastasis is rare.^[1-3]

The present case comprised an extremely unique presentation of this malignancy involving the right buccal

mucosa in a 40-year-old female. The patient presented with enlarging swelling, which was not associated with pain, nerve deficit, NF Type I and nodal/distant metastasis.

In the radiographic examination, no significant bony involvement was seen in our reported case, as it was soft-tissue tumor, but the intraosseous tumor of the oral cavity will show a complete destructive pattern with bony expansion, erosion, and tooth mobility, or radiolucency's within distinct margins or/an enlargement of the mandibular canal or mental foramen.^[10]

Histologically, this tumor does not have any defined or classical appearance. Approximately 80%–85%^[3] having fasciculating patterns showing four or more mitotic figures/high-power field. The cytoplasmic borders are indistinct and arranged in bundles or fascicles.^[1-4] Subtle features such as the proliferation of small vessels and tumor cells in the subendothelial zone of vessels, presence of neurofibromatous component (more evident in patients with NF-1), and geographic necrosis with pseudopalisading.^[2-4,7] The remaining 15% of MPNST exhibit variable differentiation, allowing them to be subclassified as distinct entities.^[3] In the present case, similar features were seen. The hypocellular and myxoid regions were also present, but these features may also be seen in leiomyosarcoma, malignant fibrous histiocytoma, and fibrosarcoma.^[2] Hence to rule out other similar pathologies, IHC was done, as it plays an important role in diagnosing and in excluding other similar lesions.^[1,2] The tumor cells showed immune reactivity for S-100, Vimentin, and Bcl-2, suggestive of neural origin. Immunonegativity of desmin and spinal muscular atrophy ruled out the possibility of muscle-specific spindle cell malignancies. Nonreactivity to CD99, epithelial membrane antigen (EMA), cytokeratin (CK-7), and melanocytic markers eliminated other plausible neoplasms, including synovial sarcoma and melanoma.^[1-8] The same marker was used in this case, which showed tumor cells staining positive, hence confirming the diagnosis.

The diagnosis of MPNST is considered to be the most difficult and elusive among soft-tissue malignancy because of its nonspecific presentation both clinically as well as histopathologically and lack of standardized criteria.^[2] This enigma can be overcome by the correlating clinical features, histopathologic, and IHC findings for a conclusive diagnosis. However, in many cases, it not always possible to demonstrate the origin from a nerve, especially when it arises from a small peripheral branch as seen in our reported case. S-100 protein is the universal diagnostic marker for MPNST^[2] and was diagnostic in our case.

Differential diagnosis

The differential diagnosis of MPNST includes fibrosarcoma, monophasic synovial sarcoma, leiomyosarcoma, desmoplastic melanoma, solitary fibrous tumor, and nodular fasciitis.

Fibrosarcoma shows a uniform fasciculated growth pattern and shares histologic features similar to those of an MPNST but lacks the evidence of nerve sheath differentiation and characteristically shows cells arranged in long, sweeping fascicles. Immunoreactivity for CK, EMA, and S-100 is a negative and positive stain for smooth muscle or muscle-specific actin.

Synovial sarcoma shows a uniform fasciculated growth pattern and contains fibroblast-like spindle cells. Approximately 90% of display immunoreactivity for CKs and EMA, CD99, a product of MIC-2, can be used as a differentiation marker for synovial sarcoma and is positive in 60%–70% of cases. S-100 positivity is not seen in other spindle cell sarcomas.

Leiomyosarcoma shows classical histopathological features, cells with centrally placed blunt-ended/cigar-shaped nuclei, having deeply eosinophilic cytoplasm, with juxtannuclear vacuoles. Furthermore, leiomyosarcoma shows immunoreactivity to most of the smooth muscle markers, unlike MPNST.

Metastatic melanomas are clinically present as a soft-tissue mass. Features including the history of primary cutaneous melanomas, lymph node involvement, and immunoreactivity to melanocytic markers such as HMB-45, Melan-A, tyrosinase and microphthalmia transcription factor easily exclude melanoma from MPNST.

Other lesions such as solitary fibrous tumor and nodular fasciitis have limited growth potential with specific histopathological features indicating lesions of a benign nature.^[1-4,6,8,10]

The diagnosis of MPNST is favored by the positivity for S-100, nestin, HMGA2, and SOX10 Treatment of choice for MPNST is surgical intervention.^[1-11] Prophylactic neck dissection is usually not warranted due to the low probability of lymphatic spread.^[2] The role of chemotherapy is controversial as shown by a meta-analysis; the overall survival rate is small and insignificant. Our patient was treated surgically with adjuvant radiotherapy. At 6-month follow-up, the patient did not show any recurrence or complications. Prognosis is generally poor with an overall survival rate of 5 years (40%–75%). Prognosis is influenced by tumor site, size and involvement of vital structures.^[1,2,4,6,8,11]

CONCLUSION

MPNST is a very rare condition of the head-and-neck region having an aggressive nature. The diagnosis of MPNSTs in the head-and-neck region is difficult, as there are no standardized radiological and histological criteria demarcating them from other spindle cell tumors, and this often poses a great challenge for pathologists.

A combination of clinical, pathological, and immunohistochemistry remains the mainstay of diagnosing MPNST. Although multiple treatment modalities are available, the aggressiveness and local recurrence of this tumor influence the treatment and prognosis.

Declaration of patient consent

The authors certify that they have obtained all appropriate patient consent forms. In the form the patient(s) has/have given his/her/their consent for his/her/their images and other clinical information to be reported in the journal. The patients understand that their names and initials will not be published and due efforts will be made to conceal their identity, but anonymity cannot be guaranteed.

Financial support and sponsorship

Nil.

Conflicts of interest

There are no conflicts of interest.

REFERENCES

1. Patil K, Mahima VG, Ambika L. Malignant peripheral nerve sheath tumor: An elusive diagnosis. *Indian J Dent Res* 2007;18:19.
2. Janardhanan M, Rakesh S, Vinod Kumar R. Intraoral presentation of multiple malignant peripheral nerve sheath tumors associated with neurofibromatosis-1. *J Oral Maxillofac Pathol* 2011;15:46-51.
3. Yaga US, Shivakumar R, Kumar MA, Sathyaprakash. Malignant peripheral nerve sheath tumor: A rarity. *Indian J Dent* 2015;6:53-6.
4. Senel Y, Bolulu A, Erdal F, Köybaşıoğlu F. Malignant schwannoma located in the retroauricular region. *Int J Pediatr Otorhinolaryngol* 1995;33:81-7.
5. Majumdar S, Kotina S, Mahesh N, Uppala D, Kumar SP. Malignant peripheral nerve sheath tumor – A rare malignancy in mandible. *J Clin Diagn Res* 2016;10:ZD12-3.
6. Ramalingam WV, Nair S, Mandal G. Malignant peripheral nerve sheath tumor of the oral cavity. *J Oral Maxillofac Surg* 2012;70:e581-5.
7. Chao JC, Ho HC, Huang CC, Tzeng JE. Malignant schwannoma of the mandible: A case report. *Auris Nasus Larynx* 2007;34:287-91.
8. Hamakawa H, Kayahara H, Sumida T, Tanioka H. Mandibular malignant schwannoma with multiple spinal metastases: A case report and a review of the literature. *J Oral Maxillofac Surg* 1998;56:1191-6.
9. Stone JA, Cooper H, Castillo M, Mukherji SK. Malignant schwannoma of the trigeminal nerve. *Am J Neuroradiol* 2001;22:505-7.
10. Muruganandhan J, Prasad TS, Selvakumar T, Kumar SN. Ancient neurilemmoma: A rare oral tumor. *J Oral Maxillofac Pathol* 2013;17:447-50.
11. Patel S, Pathak J, Dekate K, Mohanty N. Malignant peripheral nerve sheath tumour (MPNST) of mandible: Solving the perplexity. *BMJ Case Rep* 2015;2015. pii: bcr2014207790.