

Available online at www.sciencedirect.com

ScienceDirect

journal homepage: www.elsevier.com/locate/radcr

Late diagnosis of anomalous right pulmonary artery originated from ascending aorta: Associated with small pulmonary artery aneurysm ^{☆,☆☆,★}

Almushayqih Musab Hamoud, MBBS^{a,*}, Aloufi Mshari Fahad, MBBS^b, Albaradi Atheer Abdullah, MBBS^a, Aljomah Ali Mohamad, MBBS^a, Aloufi Faisal Fahad, MBBS^a

^a Diagnostic Radiology Resident at King Faisal Specialist Hospital and Research Center, Zahrawi St, Al Maather 'Al Maazer, Riyadh 12713, Saudi Arabia

^b Medical Intern at King Saud bin Abdulaziz University for Health Sciences, Riyadh, Saudi Arabia

ARTICLE INFO

Article history:

Received 18 July 2020

Revised 16 August 2020

Accepted 19 August 2020

Keywords:

Anomalous origin of the right pulmonary artery from the ascending aorta
 Congenital heart disease
 Cardiac MRI
 CT chest
 Angiogram
 Pulmonary artery aneurysm

ABSTRACT

Anomalous origin of the right pulmonary artery from the ascending aorta (AORPA) is an extremely rare congenital cardiac malformation, commonly observed early in life. Patients with AORPA usually present with nonspecific clinical symptoms, commonly associated with other congenital cardiac anomalies and some complications as pulmonary hypertension and heart failure. A high index of clinical suspicion and noninvasive diagnostic imaging studies play an important role in diagnosis and preventing high mortality rates.

We report a case of anomalous origin of the right pulmonary artery from the ascending aorta in a 15-year-old girl that was diagnosed with severe pulmonary hypertension, pulmonary hemorrhage, and small pulmonary artery aneurysm. Clinical, radiographic imaging and other investigations' findings are described. To the best of our knowledge, this is the first reported case of anomalous origin of the right pulmonary artery from the ascending aorta with large patent ductus arteriosus associated with a small pulmonary artery aneurysm.

© 2020 The Authors. Published by Elsevier Inc. on behalf of University of Washington.

This is an open access article under the CC BY-NC-ND license (<http://creativecommons.org/licenses/by-nc-nd/4.0/>)

Introduction

Normally the pulmonary trunk will divide into a right and left main pulmonary arteries. The presence of the right pulmonary artery originating from the ascending aorta is a rare congenital malformation and usually referred to as an

anomalous origin of the right pulmonary artery from the ascending aorta (AORPA).

Most of AORPA cases diagnosed during infancy with 95% and only 5% reported in adults [1]. The AORPA is usually diagnosed with other congenital cardiac anomalies [2]. The most common congenital association with AORPA is patent ductus arteriosus (PDA), while the anomalous origin of the left pulmonary artery associated with right-sided aortic arch [1,3].

[☆] Conflicts of Interest: There are no conflicts of interest.

^{☆☆} Acknowledgments: No benefits in any form have been received or will be received from a commercial party related directly or indirectly to the subject of this paper.

^{*} Funding: No funds were received in support of this study.

^{*} Corresponding author.

E-mail address: mousab2@gmail.com (A. Musab Hamoud).

<https://doi.org/10.1016/j.radcr.2020.08.068>

1930-0433/© 2020 The Authors. Published by Elsevier Inc. on behalf of University of Washington. This is an open access article under the CC BY-NC-ND license (<http://creativecommons.org/licenses/by-nc-nd/4.0/>)

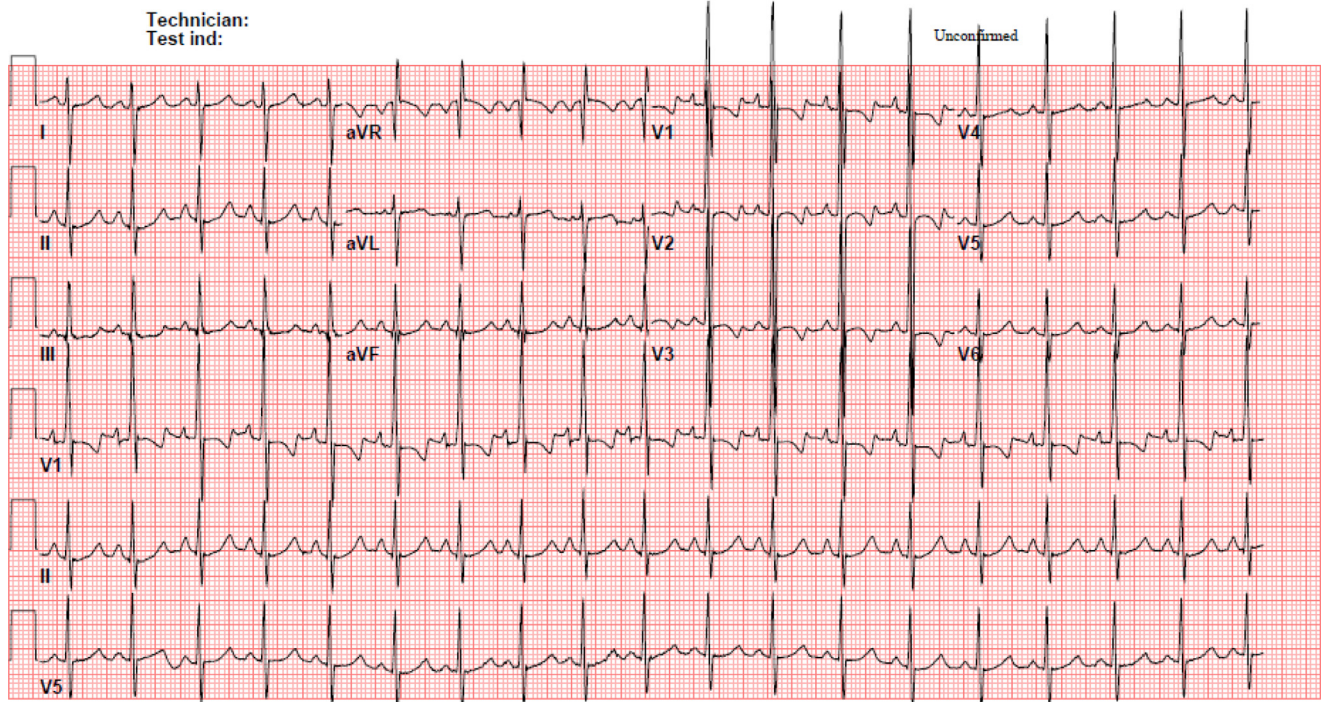


Fig. 1 – Twelve leads ECG shows right ventricular enlargement with P mitral and right axis deviation.

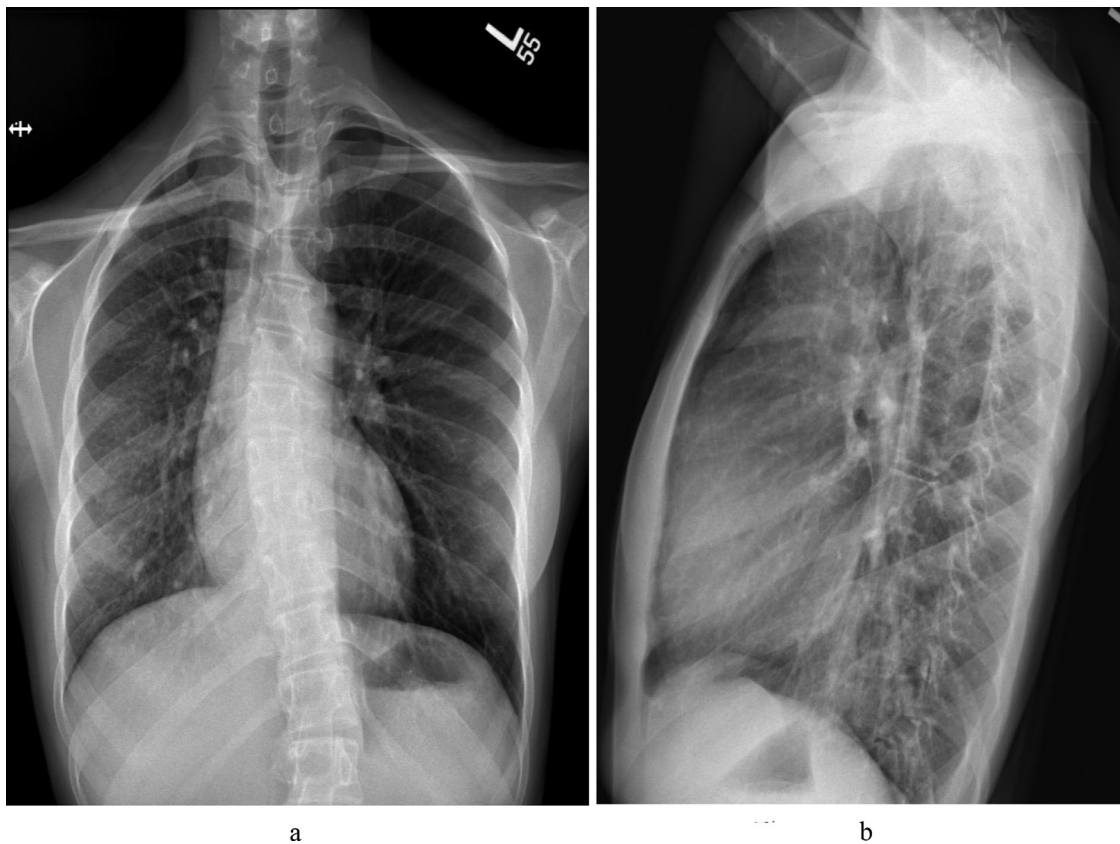


Fig. 2 – Frontal (a) and lateral (b) chest radiographs show mild volume loss of the right lung with mild rightward mediastinal shift. Heart size is normal. There are ground-glass opacities of the right lung and mild interstitial thickening. No pleural effusion. Spinal scoliosis is seen, which is of no clinical significance to our case.

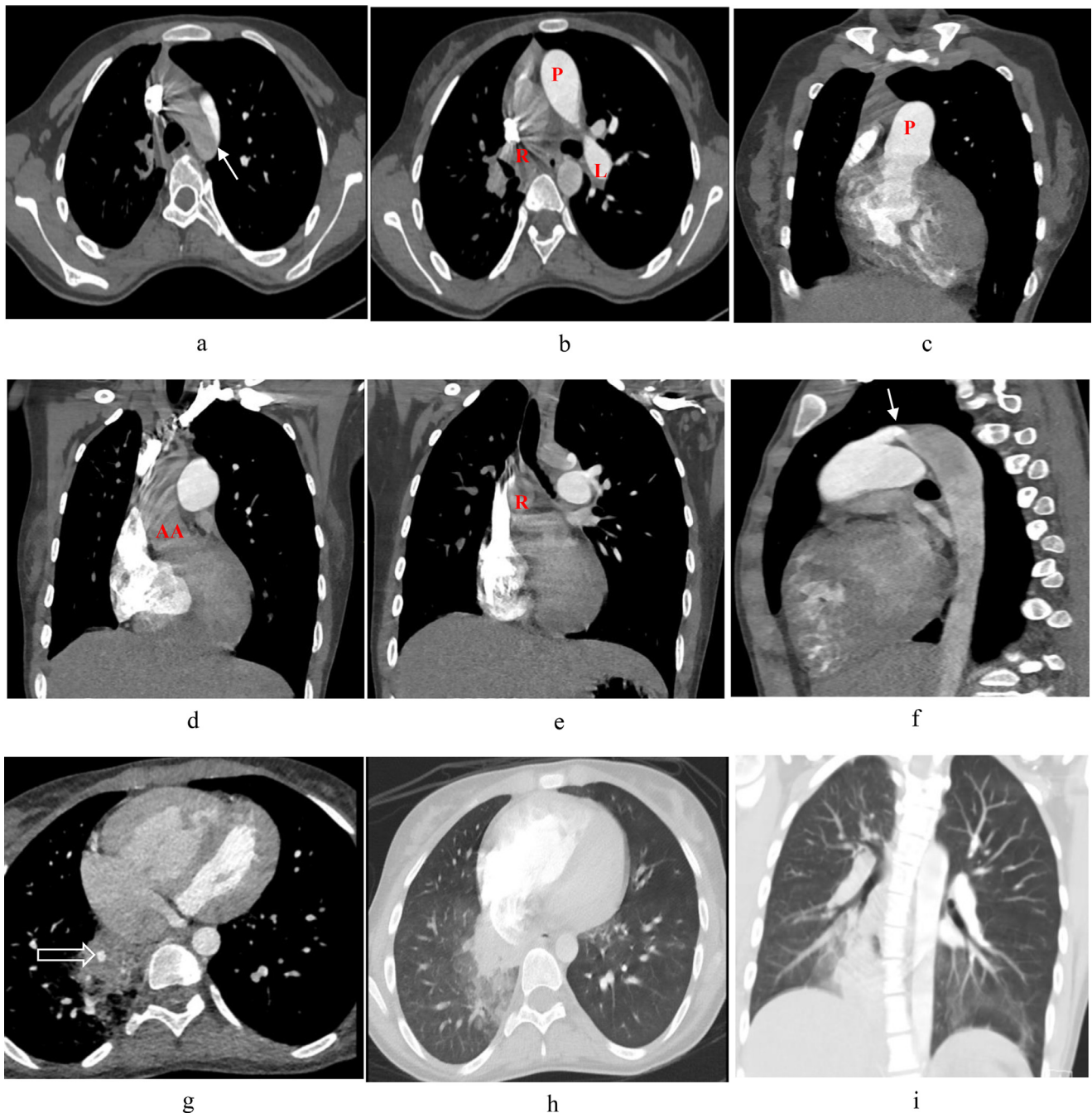


Fig. 3 – Axial (a-c), coronal (d-e) and sagittal (f) chest CT scan with intravenous contrast shows normal opacification of pulmonary trunk [P] and left pulmonary artery [L]. Right pulmonary artery [R] is not opacified with contrast, it's likely originated from the ascending aorta [AA] causing mass effect and narrowing of the right main bronchus. Patent ductus arteriosus (white arrow) is seen connecting between pulmonary trunk and aortic arch (a, f). Magnified axial (g) chest CT scan shows segmental pulmonary aneurysm [empty arrow head] within the right lower lobe. Axial (h) and coronal (i) lung window demonstrate irregular consolidation of the medial segment of right lower lobe, surrounded by ground glass opacities.

Patients with AORPA usually present with non-specific clinical symptoms, and they can present lately with complications like pulmonary hypertension or heart failure [2]. However, they commonly present with dyspnea and cyanosis with cardiac murmur during auscultation [4].

Presence of AORPA usually carryout a poor prognosis [5]. Surgical intervention is recommended as early in life as possible. In the case of no surgical intervention, the mortality rate found to exceed 80% during the first year of life [6].

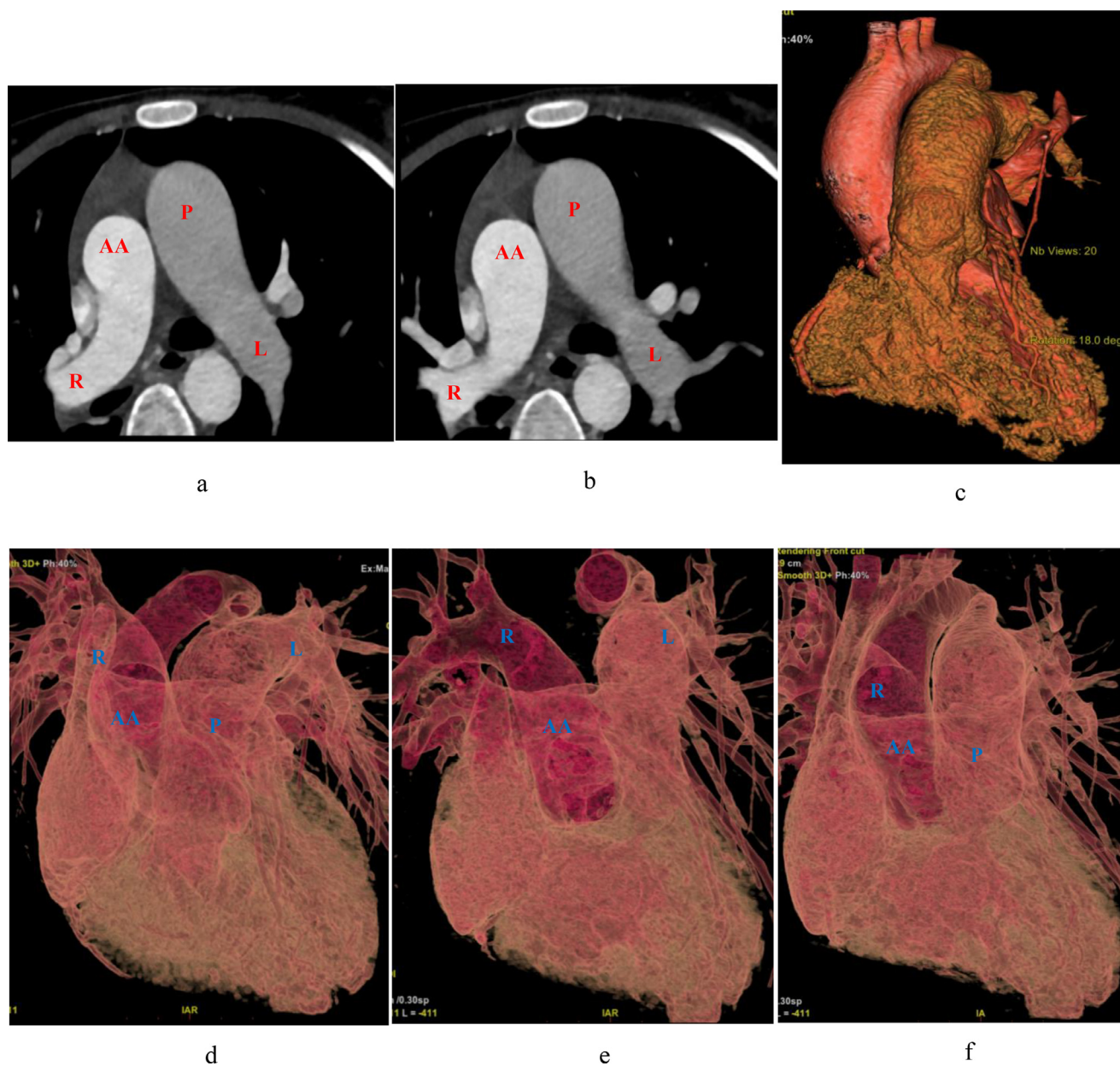


Fig. 4 – Axial (a, b) cardiac CT scan, 3D volume rendering (c) images and Software created diagrams (d-f) confirmed that the left pulmonary artery [L] originated from the pulmonary trunk [P] and an anomalous right pulmonary artery [R] originated from ascending aorta [AA].

We present a rare case of AORPA with PDA, associated with small pulmonary artery aneurysm, confirmed by CT scan and multiple other radiological investigations in a 15-year-old girl.

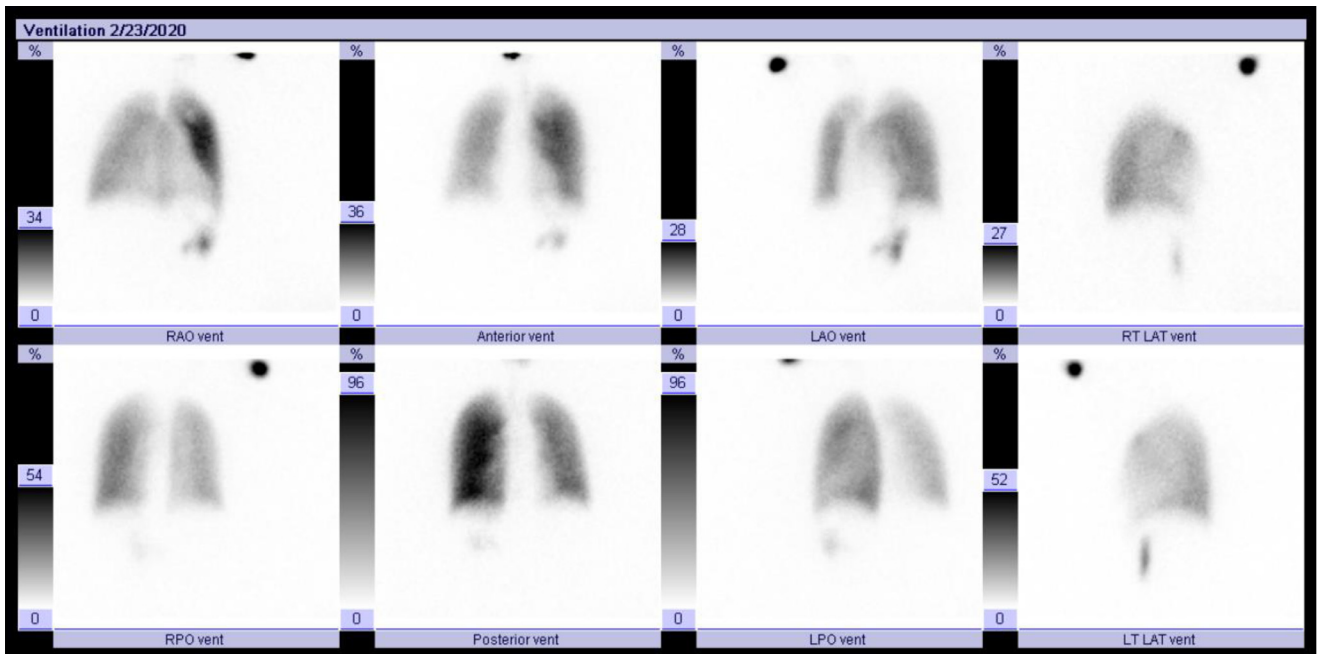
Case Report

A 15-year-old, girl, was referred to our institution from a secondary hospital with 2 months history of exertional dyspnea, dry cough, and hemoptysis. The patient has been diagnosed with severe pulmonary hypertension based on a transthoracic

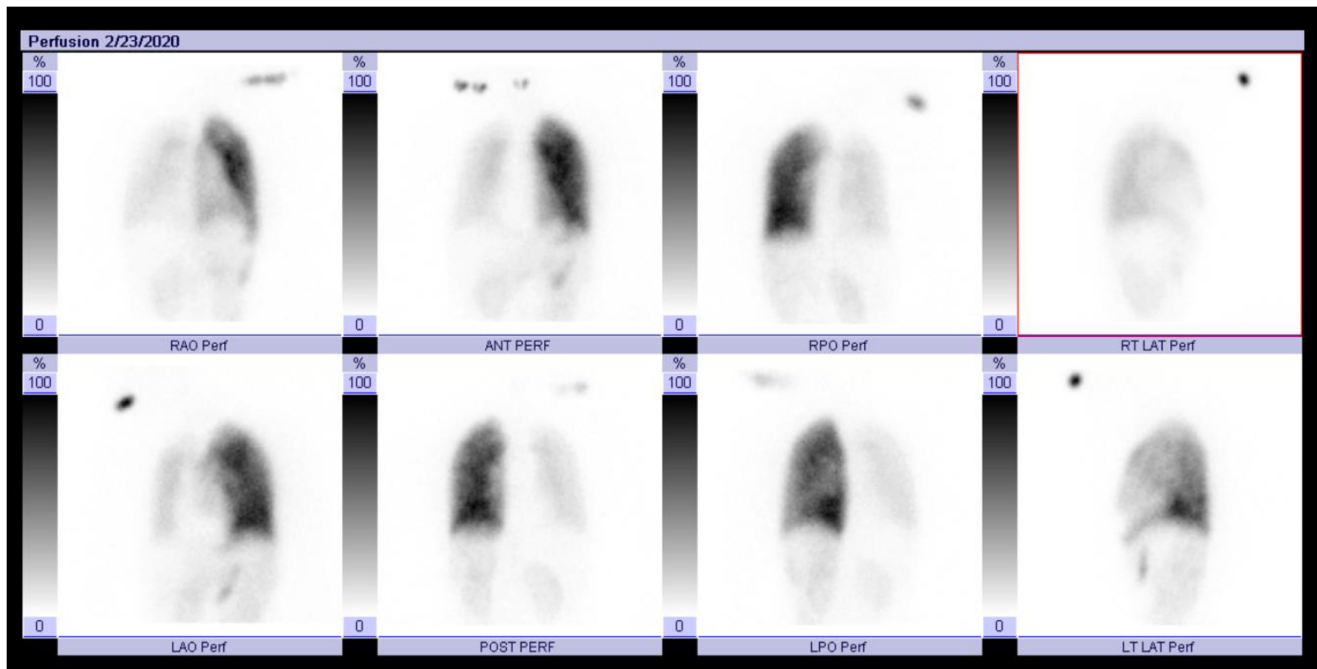
echocardiogram (TTE) report. She was referred to our hospital for further workup and management.

The patient presented with exertional dyspnea that worsened with time, and mildly improved with resting. Associated with dry cough and minimal red-stained sputum (hemoptysis), which developed recently. She did not give any history of chest pain, dizziness, palpitation, or lower limb edema. The patient had a history of recurrent epistaxis for 5 years, which was treated by cauterization 3 months ago without significant improvement.

Her vital signs showed mild increased peripheral pulse (112 pulse/min) with normal blood pressure and oxygen saturation. A complete physical examination was performed and



a



b

Fig. 5 – Planer ventilation images (a) demonstrate normal and homogenous radiotracer distribution of both lungs. Planer perfusion images (b) demonstrate markedly decreased perfusion throughout the right lung. Left lung perfusion images are normal and homogenous. Incidental abnormal increase radiotracer uptake of bilateral kidneys in perfusion images, suggesting presence of right to left shunt.

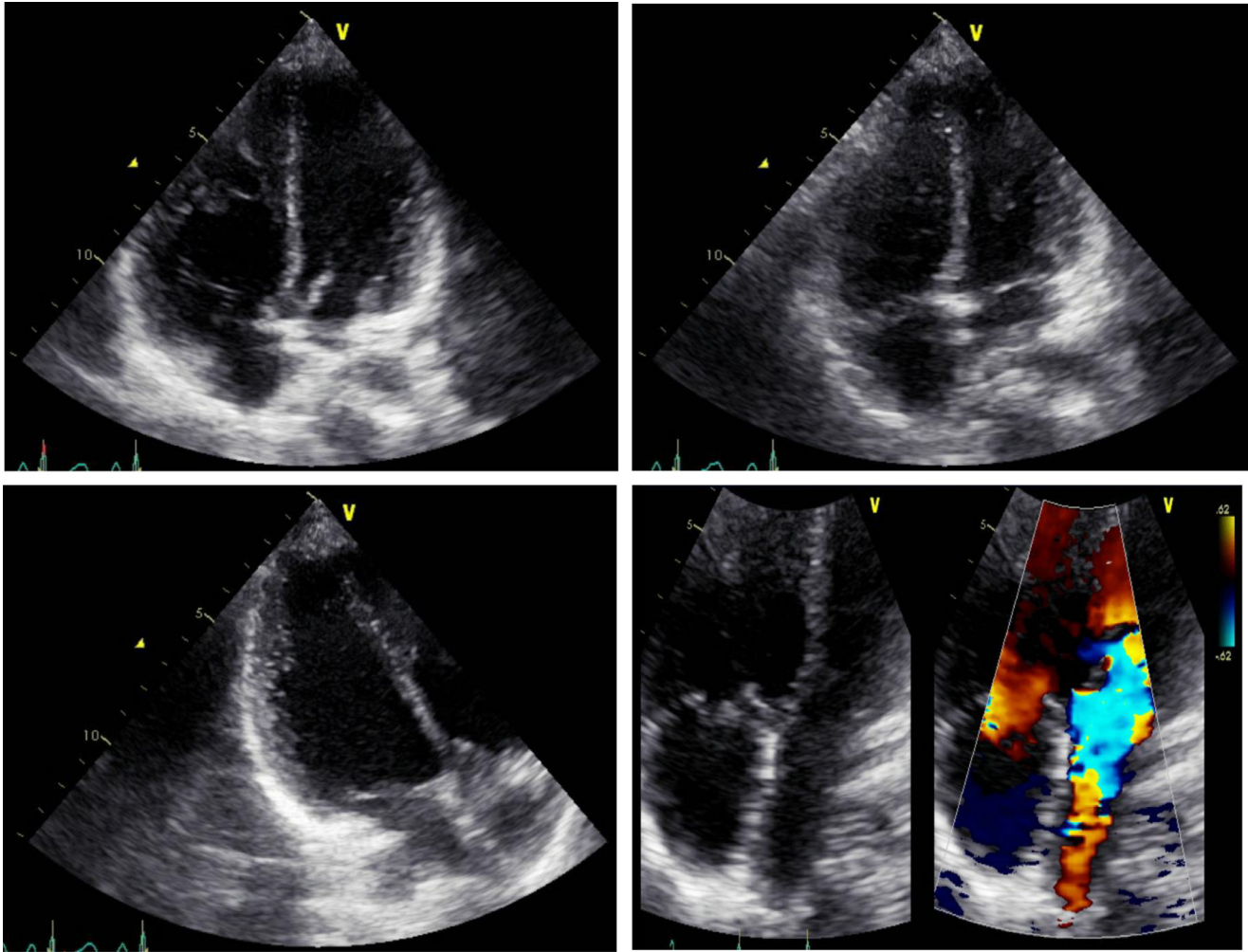


Fig. 6 – Grayscale and color-Doppler Transthoracic echocardiogram show hyper-trabeculated right ventricle with normal wall-thickness, moderately to severely dilated right ventricle. The right ventricular systolic pressure (RVSP) was 100-105 mmHg with flattening of interventricular septum, suggestive of right ventricular pressure/volume overload. The right atrium was mildly to moderately dilated and there was mild to moderate tricuspid regurgitation.

was unremarkable. At the time of admission, her ECG (Fig. 1) showed signs of right ventricular enlargement with right axis deviation, suggestive of right ventricular strain. Her chest radiograph (Fig. 2) showed mild volume loss of the right lung with a mild rightward mediastinal shift. There are ground-glass opacities of the right lung and interstitial thickening. The patient admitted to pediatric cardiology for further workup.

A Chest CT scan (Fig. 3) showed PDA and right pulmonary artery arising from the ascending aorta. Also, there was a small segmental pulmonary aneurysm in the right lower lobe, surrounded by pulmonary hemorrhage. There was no pulmonary embolism. Cardiac CT scan (Fig. 4) confirms the presence of only the left pulmonary artery originated from the pulmonary trunk and anomalous right pulmonary artery originating from ascending aorta. A Ventilation/Perfusion scan (Fig. 5) demonstrated markedly decreased perfusion throughout the right lung, while the perfusion to the left lung was normal.

A TTE (Fig. 6) was repeated in our hospital that demonstrated hyper-trabeculated right ventricle, normal wall-thickness, and moderately to severely dilated right cardiac chambers. The right ventricular systolic pressure was 100-105 mmHg, flattening of the interventricular septum, and D-shaped left ventricle. The rest of the TTE evaluation was normal.

After that, a cardiac MRI/MRA (Fig. 7) was arranged which demonstrated similar findings to the previous investigations. In addition, the right ventricular ejection fraction was 37%, evidence of focal fibrosis on gadolinium up-take at basal, and mid RV/LV insertion points. The rest of the myocardium appeared normal. The left pulmonary artery was the only branching artery from the pulmonary trunk, while the right pulmonary artery was arising from the ascending aorta which consistent with AORPA. Adding to that, there was a large PDA that measured 6-7 mm.

After extensive workup, the patient's hemoptysis was explained by the presence of a left segmental pulmonary

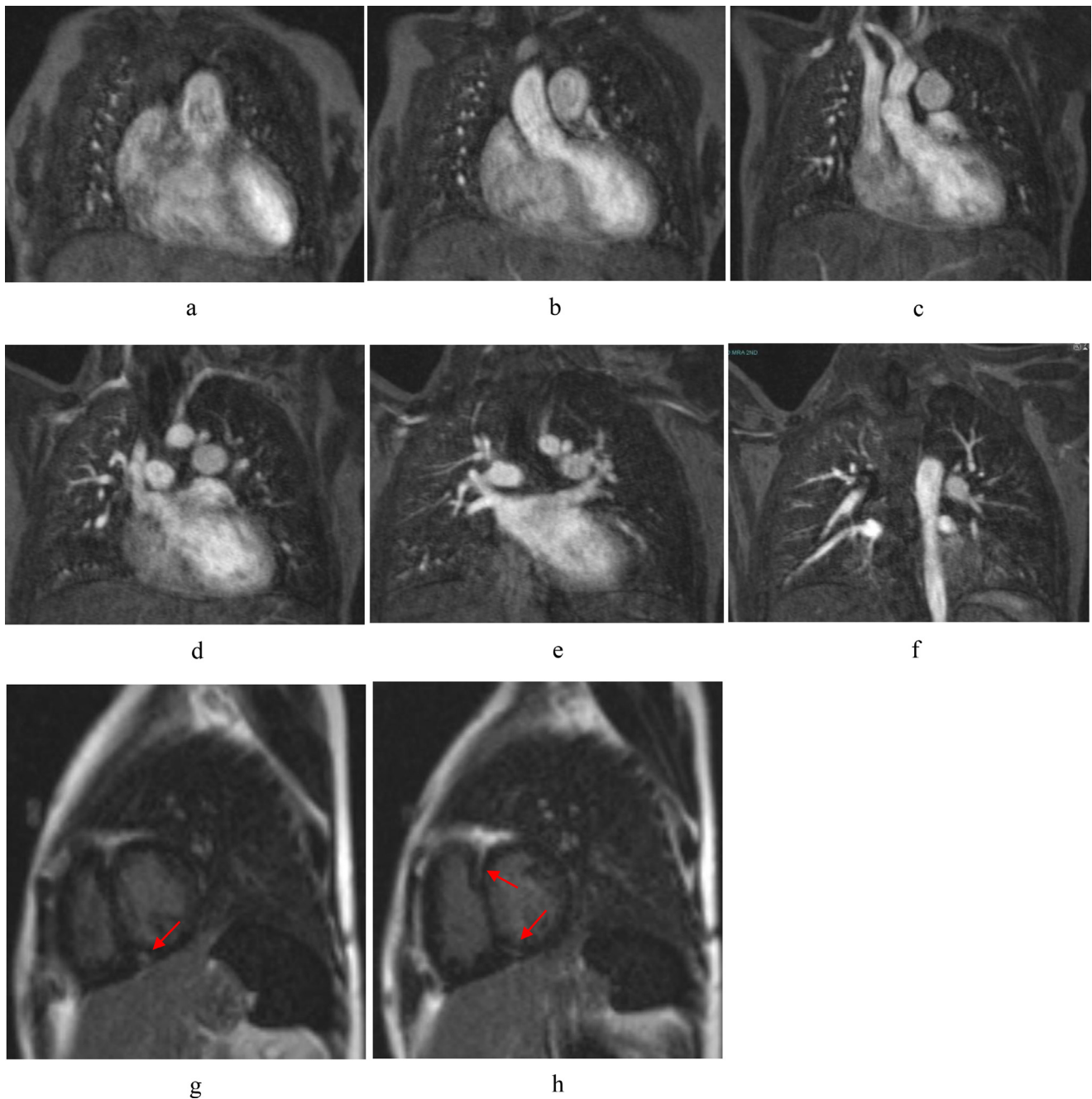


Fig. 7 – Coronal cardiac MRA (a-f) shows left pulmonary artery was the only branching artery from the pulmonary trunk, while the right PA was arising from the ascending aorta which was consistent with AORPA. Sagittal Cardiac MRI delayed gadolinium enhancement images (g,h) shows evidence of focal fibrosis on gadolinium up-take at mid RV/LV insertion points (red arrows).

aneurysm, which was seen on a CT scan. The aneurysm was treated successfully by the interventional radiology team without any complications (Fig. 8). The severe pulmonary hypertension due to the large PDA was treated medically without closure of the shunt. The patient mildly improved. A surgical option was provided, and the patient was discharged in close follow-up with pediatric cardiology and cardiac surgery teams.

Discussion

AORPA is an extremely rare cardiac malformation, some studies mention that it's very rare and accounts for 0.1% of all congenital heart defects [5]. AORPA usually arises from the posterior aspect of the ascending aorta [1], in our case the right

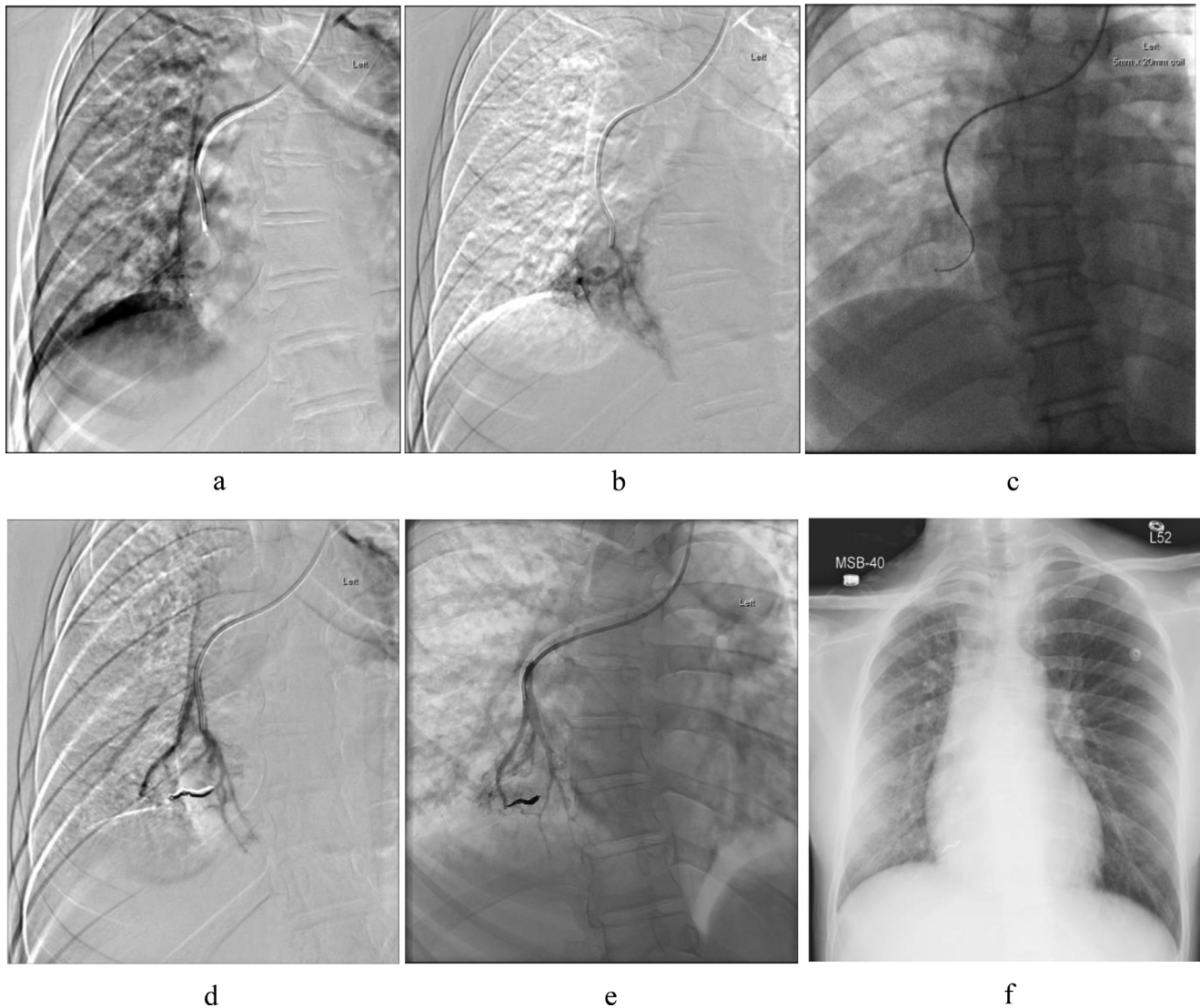


Fig. 8 – Under sedation and aseptic technique, left brachial artery was accessed using a 21-gauge needle with 5-french vascular sheath. (a-e) A glide wire was advanced to the aortic arch and selection of right pulmonary artery was performed. A small aneurysm arising from the medial segment of right lower pulmonary artery identified. Embolization was performed using a Cencerto detachable coil. Post embolization angiogram showed complete stasis with no further filling of the aneurysm. Post embolization CXR shows a hyperdense coil with no complication.

pulmonary artery originates from the right lateral side of the ascending aorta (Fig. 3, 4).

A few AORPA from the ascending aorta cases have been described in the literature, and it's known that AORPA is seen 4-8 times more than anomalous origin of the left pulmonary artery [2,4]. More than 95% of AORPA diagnosed within the first year of life [7]. However, clinical suspicion of the congenital disease usually required in young patients with unexplained mild symptoms, as seen in our study.

Literature review revealed that some congenital heart diseases were found to be associated with AORPA, most commonly PDA, which is seen in two-thirds of the cases [2]. Other congenital anomalies include aortopulmonary septal defect, tetralogy of Fallot, hypoplastic aortic arch, patent foramen oval, and ventricular septal defect [2]. In our case, we can see a

large PDA that measured 6-7 mm in both Cardiac CT scan and MRI.

In clinical evaluation, most of AORPA patients present with nonspecific symptoms. They can present with cyanosis, respiratory distress, failure to thrive, recurrent hemoptysis, and other signs of heart failure that may also present [1,2,4,8]. Our patient presented with progressive exertional dyspnea, dry cough, and hemoptysis, which were likely related to the small pulmonary artery aneurysm and pulmonary hemorrhage.

Early diagnosis of AORPA with surgical repair plays an important role in prognosis in these patients [9]. More than two-thirds of the AORPA patients show cardiomegaly and increase pulmonary vascularity in chest radiographs [2], but we did not see those in our patients. There was only low right lung

volume with ground glass opacities of the right lower lobe related to pulmonary hemorrhage.

CT cardiac angiogram is considered the gold standard of diagnosis and surgical planning. It provides a noninvasive accurate diagnosis with the ability to provide 3-dimensional and cross-sectional images to determine the anatomic relations between the pulmonary artery and adjacent structures, as well as to evaluate the cardiac structures from various angles [5].

Supportive medical management is not the optimal treatment in such cases. These kinds of congenital anomalies are found to have a high mortality rate, resulting from pulmonary hypertension and heart failure in nonsurgically repaired patients [4]. This can be explained by the presence of high pressure and overloaded right pulmonary artery from the systemic circulation of the left ventricle. Surgical intervention is the main treatment of AORPA [5]. Early diagnosis and corrective surgery are improving the prognosis in case of isolated AORPA in those patients, who do not develop pulmonary hypertension yet [10]. Pulmonary hypertension and heart failure are the main complications of untreated AORPA [4,5,9,10]. To the best of our knowledge, the pulmonary artery aneurysm association with AORPA is the first time to be described in the literature.

Conclusion

The AORPA is a rare cardiovascular congenital malformation in adults, due to the high mortality that presents in the first years of life if it is not treated surgically.

A high index of clinical suspicion is required, especially in infancy with unexplained heart failure, recurrent hemoptysis, and pulmonary hypertension. Noninvasive imaging studies play a very important role in the diagnosis and follow-up, as seen in our case.

Informed consent

The consent was not required from institutional review board in our institute due to the anonymized and retrospective nature of this report.

Patient consent

Verbal patient's consent was taken however, the consent was not required from institutional review board in our institute due to the anonymized and retrospective nature of this case report.

REFERENCES

- [1] Haywood L, Chakryan Y, Kim D, Boltzer T, Rivas G, Shavelle D. Abnormal origin of the right pulmonary artery from ascending aorta (Hemitruncus Arteriosus). *J Investigat Med High Impact Case Rep* 2014. doi:10.1177/2324709614536139.
- [2] Fontana GP, Spach MS, Effmann EL, Sabiston DC. Origin of the right pulmonary artery from the ascending aorta. *Ann Surg* 1987;206(1):102–13.
- [3] Stanton R, Durmin R, Fyler D, Lindesmith G, Meyer B. Right pulmonary artery originating from ascending aorta. *Jama Netw* 1968;115(4):403–13.
- [4] Talwar S, Kothari SS, Sharma P, Chauhan S, Gulati GS, Choudhary SK. Successful surgical correction of anomalous origin of the right pulmonary artery from the aorta in an adult. *J Cardiac Surg* 2011;26(2):201–4.
- [5] Bu H and Gong X. Image diagnosis: an anomalous origin of right pulmonary artery from the ascending aorta. *J Cardiovasc Comput Tomograph*. Doi: <https://doi.org/10.1016/j.jcct.2018.12.053>.
- [6] Vida VL, Sanders SP, Bottio T, Maschietto N, Rubino M, Milanesi O. Anomalous origin of one pulmonary artery from the ascending aorta. *Cardiol Young* 2005;15(2):176–81.
- [7] Garg P, Talwar S, Kothari SS, Saxena A, Juneja R, Choudhary SK. The anomalous origin of the branch pulmonary artery from the ascending aorta. *Interact Cardiovasc Thoracic Surg* 2012;15(1):86–92.
- [8] Weintraub R, Fabian C, Adams D. Ectopic origin of one pulmonary artery from the ascending aorta. *Radiol Soc North Am* 1966;86(4):666–76.
- [9] Amir G, Frenkel G, Bruckheimer E, Dagan T, Katz J, Berant M, et al. Anomalous origin of the pulmonary artery from the aorta: early diagnosis and repair leading to immediate physiological correction. *Cardiol Young* 2010;20(6):654–9.
- [10] Va'zquez RM, Cha'vez IO, Lo'pez ME, Bahena EJ, Za'rate RC, Flores AC. Anomalous origin of pulmonary branches from the ascending aorta. A report of five cases and review of the literature. *J Cardiol Cases* 2015;11(1):1–6.