

# A case of bronchiectasis needing lung isolation for cerebello pontine angle tumor excision: Anesthetic challenges

## ABSTRACT

The main goals of neuroanesthesia are the maintenance of adequate cerebral perfusion pressure, avoidance of hypercarbia, hypoxemia, and to provide better brain relaxation. Providing anesthesia for a patient with bronchiectasis needing lung isolation for craniotomy can be challenging. A 56-year-old male patient, case of right lung bronchiectasis with a right cerebello pontine angle tumor underwent excision in the left lateral position. Since he had severe bronchiectasis of the right lung, we had isolated the right lung using right-sided double lumen tube to avoid spillage. Intraoperative split lung test was performed to assess the right lung contribution on carbon dioxide (CO<sub>2</sub>) elimination and found that there was a significant contribution from the right lung. Hence, both lungs were ventilated to control CO<sub>2</sub>. The importance of lung isolation to prevent spillage and avoidance of one lung ventilation to control the arterial CO<sub>2</sub> are highlighted in this case report. By providing a balanced anesthetic keeping both, the neurosurgical and thoracic concerns are important for better postoperative outcome.

**Key words:** Anesthesia, bronchiectasis, craniotomy, lung isolation

## Introduction

Maintaining adequate cerebral perfusion pressure and avoidance of hypoxemia, and hypercarbia are the key elements of neuroanesthesia in patients with raised intracranial pressure (ICP). Main intraoperative concerns during the posterior fossa surgery are to facilitate surgical access and to maintain respiratory and cardiovascular stability.

Providing anesthesia for a patient with bronchiectasis who requires lung isolation during the neurosurgical procedure can be quite challenging. Intraoperative hypoxemia and hypercarbia associated with one lung ventilation (OLV) can be detrimental to patients with raised ICP. Even though,


there is no direct evidence of an increase in ICP associated with OLV, there is a possibility of an increase in ICP because of an associated hypercarbia and hypoxia during OLV.<sup>[1-3]</sup> Hence, it is better to isolate diseased lung and provide two lung ventilation to avoid hypoxia, hypercarbia-induced increase in ICP.

We like to report a case of bronchiectasis involving the right lung who underwent a right retromastoid craniectomy, and excision of right vestibular schwannoma in the left lateral position and its anesthetic challenges. An informed consent was obtained from the patient for publishing the case report.

This is an open access article distributed under the terms of the Creative Commons Attribution-NonCommercial-ShareAlike 3.0 License, which allows others to remix, tweak, and build upon the work non-commercially, as long as the author is credited and the new creations are licensed under the identical terms.

**For reprints contact:** reprints@medknow.com

**How to cite this article:** Srinivasan C, Kurian GP, Mariappan R. A case of bronchiectasis needing lung isolation for cerebello pontine angle tumor excision: Anesthetic challenges. Saudi J Anaesth 2016;10:359-61.

Access this article online	
<b>Website:</b> <a href="http://www.saudija.org">www.saudija.org</a>	<b>Quick Response Code</b> 
<b>DOI:</b> 10.4103/1658-354X.174923	

**SRINIVASAN C, KURIAN GP, MARIAPPAN R**

Department of Anesthesia, Christian Medical College, Vellore, Tamil Nadu, India

**Address for correspondence:** Dr. Ramamani Mariappan, Department of Anesthesia, Christian Medical College, Vellore, Tamil Nadu, India.  
 E-mail: ramamani@cmcvellore.ac.in

## Case Report

A 51-year-old man (height 168 cm, weight 79 kg) presented with right vestibular schwannoma and an underlying bronchiectasis of the right lung. He had presented with the symptoms of progressive loss of hearing and imbalance while walking.

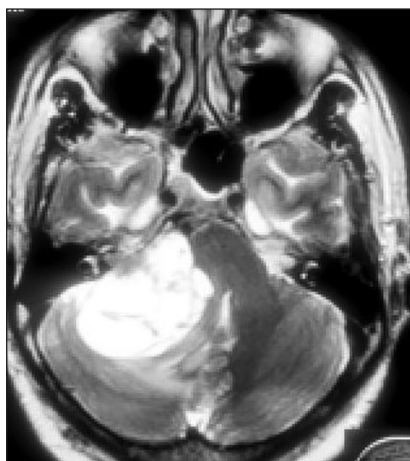He gave a history of a cough with expectoration and recurrent lung infections since childhood and was evaluated for tuberculosis and found to be negative. During this admission, he had a cough but he could not bring out the sputum. Since there were no signs of active lung infection, we did not perform a bronchoscopy to evaluate cause for bronchiectasis. He is a hypertensive for 20 years on treatment with amlodipine 5 mg once daily. On examination, he had extensive crepitation over the right hemithorax, and tracheal shift to the right. His magnetic resonance imaging brain (T2-weighted image), showed a large vestibular schwannoma (5.2 cm × 4.3 cm × 3.5 cm in size) with obstructive hydrocephalus [Figure 1]. His chest X-ray findings showed right-sided bronchiectasis and fibrosis with the gross mediastinal shift [Figure 2]. Spirometry revealed a moderate obstructive pulmonary disease. Preoperative arterial blood gas analysis (ABG) on room air showed compensated respiratory acidosis with the pH of 7.43, PaO<sub>2</sub> of 74 mmHg and partial pressure of arterial carbon dioxide (PaCO<sub>2</sub>) of 48 mmHg with HCO<sub>3</sub> of 31 mmHg. An echocardiogram revealed left ventricular (LV) hypertrophy with normal LV systolic function, and there was no pulmonary hypertension.

In view of severe bronchiectasis and long duration surgery in the left lateral position (diseased side of the lung being up), decided to isolate the right lung using right-sided double lumen tube (RDLT). In this case, we chose to put a RDLT because of the following reasons.

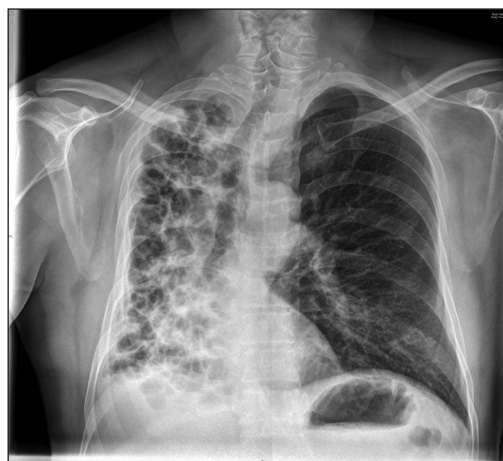1. The angle between bronchus and trachea was obliterated because of lung fibrosis with the mediastinal shift. Right bronchus was almost in a straight line with the trachea [Figure 2]. Hence, placement of RDLT will be easy when compared to the left.
2. With a left DLT, secretion from the right lung can get accumulated above the left bronchial cuff. The presence of low pressure cuff cannot provide a tight seal against spillage. Hence, we felt that presence of RDLT will give better protection than the left DLT.

In the operating theater, standard monitors including electrocardiogram, pulse oximetry, and noninvasive blood pressure were connected. His room air saturation was 94%. Modified rapid sequence induction was done using 2 µg/kg of fentanyl and 2 mg/kg of propofol, and was then paralyzed with 1.0 mg/kg of rocuronium and intubated with 39F RDLT. Mallinckrodt™ the tube position was confirmed by fiberoptic bronchoscopy (FOB). Both the lungs were suctioned separately before placing the patient in the left lateral position. After positioning, the head was fixed using Mayfield head clamp, repeat FOB was done to confirm the lung isolation. Copious thick purulent secretion was suctioned out from the right lung. To assess the contribution of the right lung on CO<sub>2</sub> elimination split lung ventilation was performed by ventilating only diseased lung (right side). There was a significant ETCO<sub>2</sub> value noted (20 mmHg) while ventilating the right lung, we have decided ventilate both lungs. The patient was ventilated with pressure controlled ventilation using lung protective ventilation strategies. The end-tidal CO<sub>2</sub> was maintained between 35 and 37 mm of Hg.

Intraoperatively, anesthesia was maintained using air, oxygen (FiO<sub>2</sub> 0.6) and isoflurane, and vecuronium infusion. Intermittent bolus doses of fentanyl and intravenous



**Figure 1: Magnetic resonance imaging brain (T2-weighted image) showing the right cerebello pontine angle tumor**



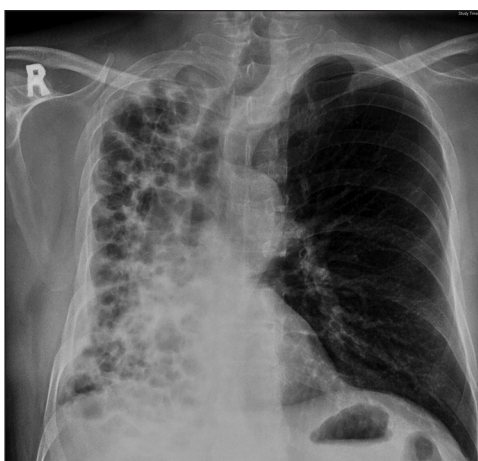
**Figure 2: Preoperative chest X-ray showing bronchiectasis and fibrosis involving the right lung with the shift of mediastinum to the right**

paracetamol were given for analgesia. Serial ABG's were taken to ensure the adequacy of ventilation. PaCO<sub>2</sub> was maintained between 40 and 45 mmHg (baseline value was 49 mmHg). Vitals were stable throughout the surgery. Brain relaxation was reported adequate during the surgery.

The surgery lasted for 6 h. At the end of surgery, bilateral endobronchial suctioning was done in the lateral position. An intravenous lignocaine (1.5 mg/kg) was given to prevent coughing before placing the patient in supine oblique (left side up). Residual neuromuscular blockade was reversed with neostigmine (0.05 mg/kg) and glycopyrrolate (0.01 mg/kg). The trachea was extubated when the patient was fully awake. The patient was shifted to the Neurosurgical Intensive Care Unit (NICU) in the right lateral position. His postoperative chest X-ray showed clear lung field on the left side [Figure 3]. He was monitored in NICU for 2 days and shifted to ward. Later, he was discharged from the hospital in a good clinical state.

## Discussion

Though, the patient did not give a history of productive sputum or show signs of active infection preoperatively, there was copious, thick purulent sputum was suctioned out from the right lung after positioning. Hence, it is wise to isolate the diseased lung even if, there is no history of productive sputum during the preoperative period. Though the chance of spillage of secretion is high with lateral decubitus position, the V/Q mismatch is minimal with this position. Placing the healthy lung independent position increases the blood flow to the better ventilated lung thereby promotes V/Q matching, which intern decreases the shunt.<sup>[4]</sup>



**Figure 3:** Postoperative chest X-ray showing clear lung fields over the left lung

Intraoperative DLT malposition and its associated complications were considered. Since the head is fixed in Mayfield head clamp, the chance of DLT malposition during neurosurgery is very minimal. Hence, we have decided to isolate the right lung with RDLT, and the surgery was performed in the left lateral position uneventfully.

While ventilating the patient with chronic hypercarbia, it is very important to maintain the pH to near normal value. An abrupt increase in minute ventilation to reduce the PaCO<sub>2</sub> can cause profound metabolic alkalosis leading to seizures.<sup>[5]</sup> In our case, we had maintained the pH to near normal value by ventilating the lung using lung protective ventilation strategies for preventing seizures as well as acute lung injury.

## Conclusion

In our case, the patient's pathology required balancing both, neuroanesthetic and thoracic concerns. The importance of lung isolation (to prevent spillage) and avoidance of OLV for better CO<sub>2</sub> elimination and the hazards of hyperventilating a patient who is chronically hypercarbic are highlighted in this report. Thorough understanding of patient pathophysiology, meticulous planning, and better communication with the surgeons are necessary for the successful patient outcome.

## Financial support and sponsorship

Nil.

## Conflicts of interest

There are no conflicts of interest.

## References

1. Kazan R, Bracco D, Hemmerling TM. Reduced cerebral oxygen saturation measured by absolute cerebral oximetry during thoracic surgery correlates with postoperative complications. *Br J Anaesth* 2009;103:811-6.
2. Karzai W, Schwarzkopf K. Hypoxemia during one-lung ventilation: Prediction, prevention, and treatment. *Anesthesiology* 2009;110:1402-11.
3. Sutton CJ, Naguib A, Puri S, Sprenker CJ, Camporesi EM. One-lung ventilation in infants and small children: Blood gas values. *J Anesth* 2012;26:670-4.
4. Remolina C, Khan AU, Santiago TV, Edelman NH. Positional hypoxemia in unilateral lung disease. *N Engl J Med* 1981;304:523-5.
5. Addington WW, Kettel LJ, Cugell DW. Alkalosis due to mechanical hyperventilation in patients with chronic hypercapnia. *Am Rev Respir Dis* 1966;93:736-41.