



Endoscopic vacuum therapy for a large esophageal perforation after bariatric stent placement

Diogo Turiani Hourneaux de Moura, MD, MSc, PhD,¹ Vitor O. Brunaldi, MD, MSc,¹
 Mauricio Minata, MD, MSc,¹ Daniel Riccioppo, PhD,² Marco Aurelio Santo, MD, PhD,²
 Eduardo Guimarães Hourneaux de Moura, MD, MSc, PhD³

Postoperative leaks pose a significant risk to patients undergoing sleeve gastrectomy (SG).¹ Currently, self-expandable metal stent (SEMS) placement is the mainstay

of the treatment of early bariatric leaks.² The stent works by covering the orifice of the fistula and also shaping the stomach and promoting a distal dilation, treating

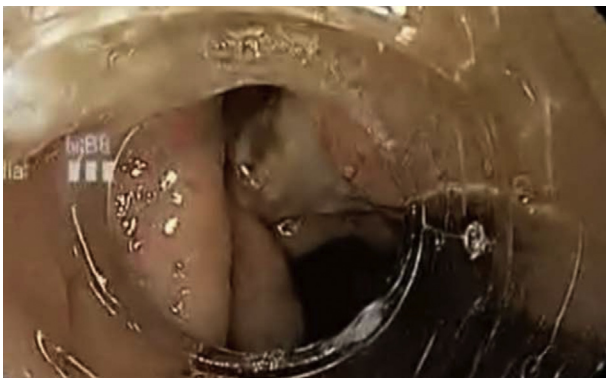

Figure 1. Acute gastric leak identified during upper endoscopy.

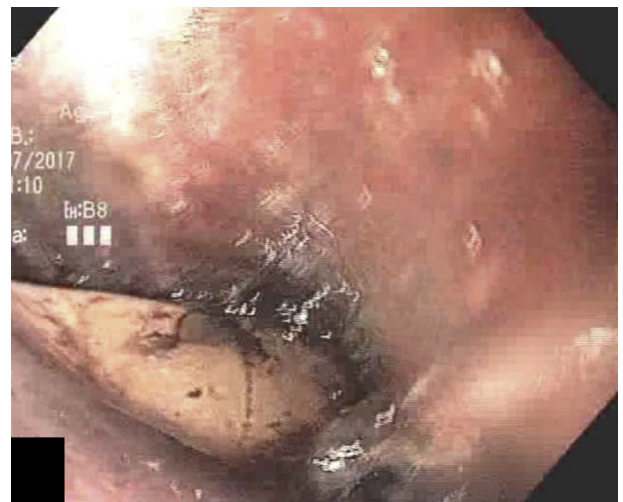

Figure 3. Larger perforation in distal esophagus identified during upper endoscopy.

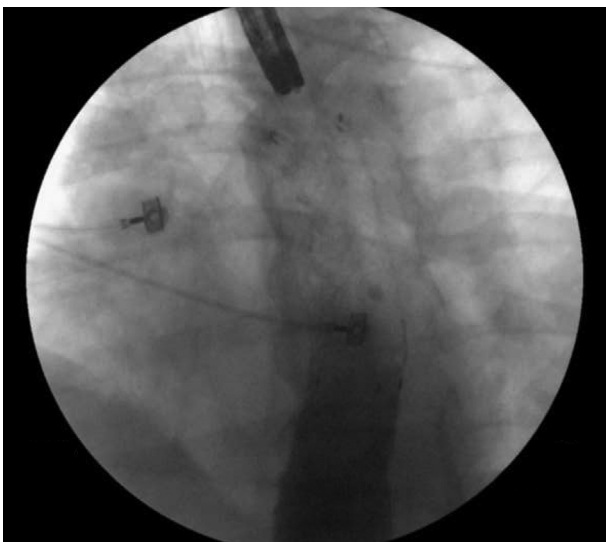


Figure 2. Bariatric stent occluding the leak.

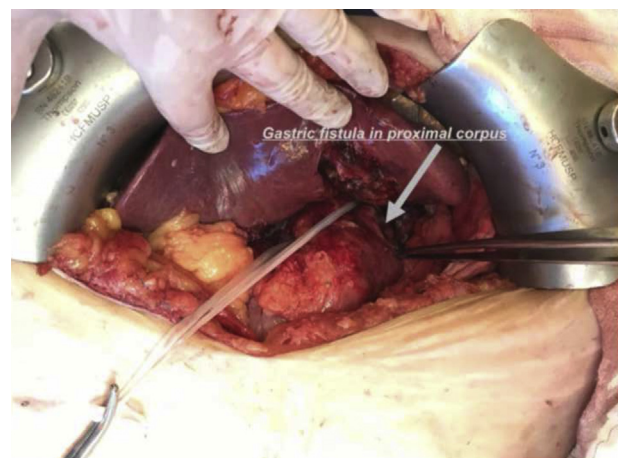


Figure 4. Gastric leak identified during surgery.

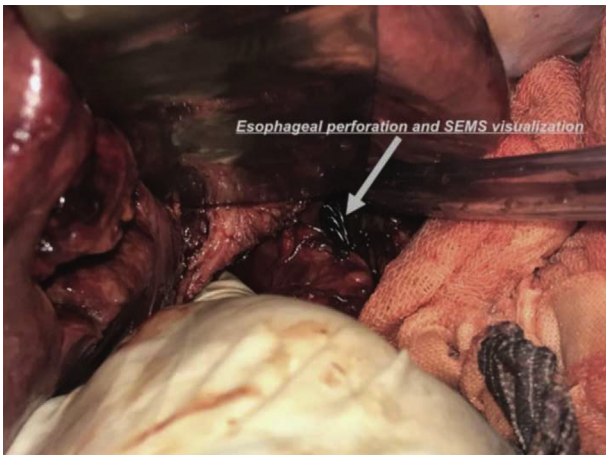


Figure 5. Large esophageal perforation identified during surgery. SEMS, Self-expandable metal stent.



Figure 7. Sponge vacuum system.

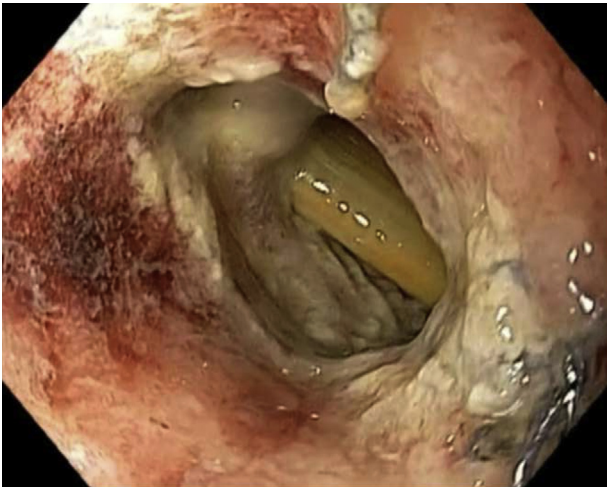


Figure 6. Complete dehiscence of the esophageal perforation and the mediastinal drainage.

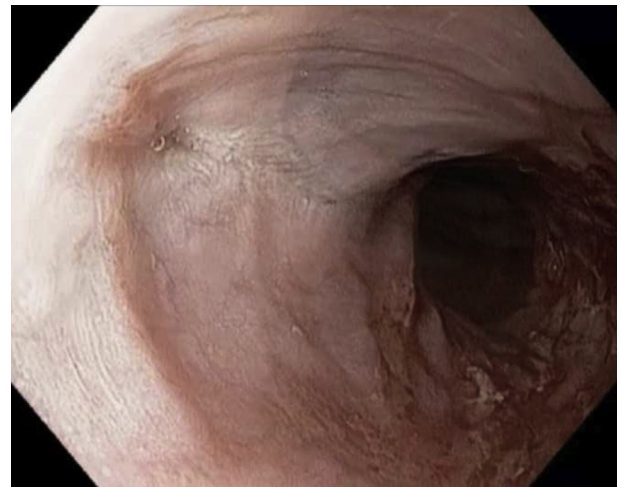


Figure 8. Scar after esophageal closure with endoscopic vacuum therapy.

downstream obstruction.^{3,4} The overall success rate of stent use was 72.8%, with a migration rate of 28.2%.² Recently, a newer stent, the megastent, has also emerged as an interesting option because its long and large shape adequately fits the tortuous anatomy of the SG, demonstrating superior results in comparison with esophageal stents in the management of sleeve leaks; however, serious adverse events may arise.⁴⁻⁶

A 55-year-old morbidly obese woman underwent SG and experienced a gastric leak on the seventh postoperative day (Fig. 1). She was in clinically stable condition and was referred to our endoscopy unit for SEMS placement (Video 1, available online at www.VideoGIE.org). We opted for a fully covered bariatric megastent (28 mm × 24 cm), which completely occluded the leak at the proximal corpus (Fig. 2). Ten days later, the drain output increased and became darkish. An endoscopic reassessment identified a large perforation (Fig. 3) at the

distal part of the esophagus where the proximal edge of the SEMS was anchored. The patient underwent emergency surgery. Intraoperatively, both the esophageal perforation (Fig. 4) and the gastric fistula (Fig. 5) were identified. We repaired both defects and placed mediastinal and peritoneal drains. Ten days later, we removed the stent and observed complete dehiscence of the esophageal perforation (Fig. 6) with a mediastinal drain into the orifice. We removed the drain from the orifice and placed the SEMS, with sponge system exchanges (Fig. 7) every 3 to 5 days. Nine vacuum system exchanges and 50 days were needed to completely close the esophageal perforation (Fig. 8). Moreover, treatment of the gastric leak entailed the removal of surgical staples and 2 septotomies (Fig. 9). Control endoscopy and upper GI series showed no signs of leaks. The patient was discharged 3 months after the SG with normal oral nutritional intake and was asymptomatic.

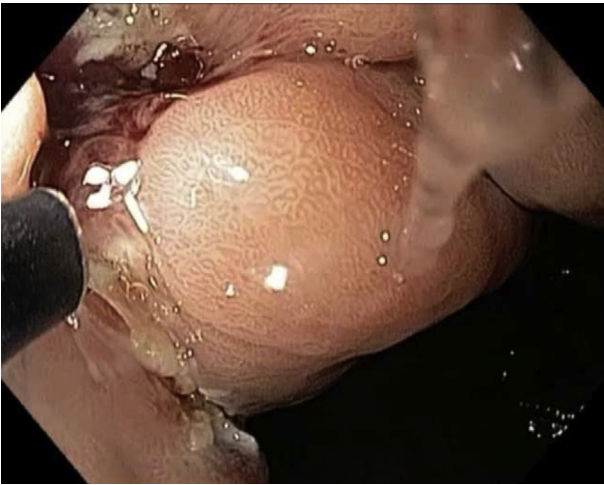


Figure 9. Septotomy with needle-knife close to the leak in the proximal corpus.

In conclusion, the megastent should be used with caution because it may carry serious adverse events. Endoscopic vacuum therapy is a noteworthy option to treat large esophageal perforations. Treatment of leaks may require multiple endoscopy sessions and a combination of different techniques.

DISCLOSURE

Dr Eduardo G. H. de Moura is a consultant for Boston Scientific and Olympus. All other authors disclosed no financial relationships relevant to this publication.

Abbreviations: SEMS, self-expandable metal stent; SG, sleeve gastrectomy.

REFERENCES

1. Marquez MF, Ayza MF, Lozano RB, et al. Gastric leak after laparoscopic sleeve gastrectomy. *Obes Surg* 2010;20:1306-11.
2. Okazaki O, Bernardo WM, Brunaldi VO, et al. Efficacy and safety of stents in the treatment of fistula after bariatric surgery: a systematic review and meta-analysis. *Obes Surg* 2018;28:1788-96.
3. Baretta G, Campos J, Correia S, et al. Bariatric postoperative fistula: a life-saving endoscopic procedure. *Surg Endosc* 2015;29:1714-20.
4. van Wezenbeek MR, de Milliano MM, Nienhuijs SW, et al. A specifically designed stent for anastomotic leaks after bariatric surgery: experiences in a tertiary referral hospital. *Obes Surg* 2016;26:1875-80.
5. Galloro G, Magno L, Musella M, et al. A novel dedicated endoscopic stent for staple-line leaks after laparoscopic sleeve gastrectomy: a case series. *Surg Obes Relat Dis* 2014;10:607-11.
6. Shehab H, Abdallah E, Gawdat K, et al. Large bariatric-specific stents and over-the-scope clips in the management of post-bariatric surgery leaks. *Obes Surg* 2018;28:15-24.

Endoscopy Unit (1), Bariatric Surgery (2), Endoscopy Unit (3), Gastrointestinal Department, Hospital das Clínicas da Faculdade de Medicina da Universidade de São Paulo, São Paulo, Brazil.

Copyright © 2018 American Society for Gastrointestinal Endoscopy. Published by Elsevier Inc. This is an open access article under the CC BY-NC-ND license (<http://creativecommons.org/licenses/by-nc-nd/4.0/>).

<https://doi.org/10.1016/j.vgie.2018.08.009>