

Intrauterine growth restriction associated with excessively long umbilical cord

Ann Schmid, Yves Jacquemyn,
Jeannette De Loor

Department of Obstetrics and
Gynaecology, Antwerp University
Hospital UZA, Edegem, Belgium

Abstract

We present a 37-week female baby, known with intrauterine growth restriction since 25 weeks of pregnancy, born with a placenta with an excessive long umbilical cord (ELUC), without any other abnormalities. ELUC is mostly an incidental finding after delivery, but represents a potentially detectable intrauterine cause of growth restriction. A system that allows ultrasound measurement of the length of the umbilical cord could highly increase antenatal diagnosis of ELUC.

Introduction

Intrauterine growth restriction (IUGR) is a common diagnosis in obstetrics and carries an increased risk of perinatal mortality and morbidity. The etiology of IUGR in a specific case often stays unknown. We present a case of early onset IUGR related to an excessive long umbilical cord (ELUC), without any other abnormalities.

Case Report

A 22-year-old woman visited our hospital for the prenatal care of her first pregnancy. At 25 weeks gestational age intrauterine growth restriction was diagnosed on ultrasound. There was no history of any medical condition nor any abuse that could explain the IUGR in this on ultrasound structurally normal fetus. Doppler velocimetry in the umbilical artery and the middle cerebral artery always was within normal limits. The amniotic fluid index was normal and amniocentesis showed a normal karyotype, 46 XX. The estimated fetal weight at 37 weeks of pregnancy was 1600 grams. It was decided to induce labor at 37 weeks gestational age. This was performed using an extra-amniotic balloon, followed after 6 h by extra-amniotic administration of prostaglandin (0.5 mg dinoprost, Prepidil gel®, Pfizer, Belgium). On the patients demand, epidural

analgesia was given. Cardiotocography at that moment demonstrated a normal reactive pattern. Dilation progressed slowly, after 12 h fetal bradycardia, to 60 bpm, developed, with normalization at 8 min. At that moment cervical dilation was 4 cm and monitoring for ST-analysis was placed (Figure 1). Two hours later, syntocinon was given because of bad progression in labor. But it had to be interrupted because of a suboptimal pattern at the cardiotocography. Because of not progressive labor and the impossibility to raise the uterotonica, the gynecologist decided to perform caesarian section. The patient delivered a female infant weighing 1550 g, with an Apgar-score of 9 after 1 and 5 min and 10 after 10 min. The pH-values on the umbilical cord blood samples were normal (arterial 7.31 and venous 7.35). The child did well in the intermediate care nursery.

Macroscopic evaluation of the placenta showed an excessively long umbilical cord, measuring 125 cm, a size of 13 cm by 13 cm and a thickness of 2 cm (Figure 2). The weight of the placenta was 270 grams, which is small for 37 weeks of pregnancy (<P10).

Microscopic evaluation showed a normal maturation of the villi, normal decidua, but a subchorial thrombus, perivillous fibrin deposition and a placental infarction.

Discussion

IUGR is a common diagnosis in obstetrics and carries an increased risk of perinatal mortality and morbidity. Decreased intrauterine growth may have a negative effect on brain growth and mental developmental potential. It is important to identify IUGR because proper evaluation and management can result in a favorable outcome. This case illustrates the association between an extremely long umbilical cord and intrauterine growth restriction. It is known that in an excessive long cord, the risk of clinical umbilical cord entanglement (*i.e.* true knots or cord loops around the neck or body parts) and circulatory stasis and vascular thrombosis is higher.^{1,2} This can cause perinatal complications, like intrauterine growth restriction, neurological complications and fetal death. A normal umbilical cord is about 50 to 60 cm. We talk about a short umbilical cord if it is less than 30 to 40 cm and a long one from 70 to 80 cm.³

The umbilical cord is responsible for the transport of nutrition, oxygen and fluid necessary for the intrauterine existence of a fetus. So it's not surprising there is an association between gross cord abnormalities and adverse perinatal outcome.

It is assumed that length of an umbilical cord is determined by environmental as well as genetical factors. ELUC is associated with

Correspondence: Ann Schmid, Zaaldenrode 2,
2640 Mortsel, Belgium.
Tel.: +32.486.22.93.64.
E-mail: ann.schmid@live.be

Contributions: SA, manuscript writing; JY, diagnosis and treatment, correcting manuscript; DLJ revised this case report critically for important intellectual content and translation.

Conflict of interests: the authors declare no potential conflict of interests.

Key words: umbilical cord, intrauterine growth restriction, cord abnormality.

Received for publication: 14 February 2013.

Revision received: 16 April 2013.

Accepted for publication: 24 April 2013.

This work is licensed under a Creative Commons Attribution NonCommercial 3.0 License (CC BY-NC 3.0).

©Copyright A. Schmid *et al.*, 2013
Licensee PAGEPress, Italy
Clinics and Practice 2013; 3:e23
doi:10.4081/cp.2013.e23

early miscarriages.³ This suggests that umbilical cord length is already established early in pregnancy and so it could be a reliable parameter during the ultrasound follow up in prenatal care. Baergen *et al.* did a big case-control study in New York. They found an association between ELUC and women with systemic diseases and with postpartum and perpartum complications.³ There was also a significant correlation with higher birth weight, adverse neonatal outcome, low apgar-scores, male fetuses, fetal anomalies and cord entanglement. Fetal and neonatal mortality and IUGR were seen in a higher number in the ELUC-group, but there was no statistical significance. But Tantbirojn *et al.* did an evaluation of placentas with gross cord abnormalities and their relationship to adverse clinical outcomes and stasis-associated histologic changes in the placenta.⁴ They found that gross cord abnormalities were significantly associated with stillbirth, intrauterine growth restriction, non-reassuring fetal tracing, meconium-stained amniotic fluid, and increased rate of emergency cesarean section. At microscopic evaluation, cases with gross cord abnormalities showed a statistically significant association with both ectasia and thrombosis in the fetal vasculature, as well as changes of fetal thrombotic vasculopathy in the terminal villi. Considering individual gross cord abnormalities, long cord and nuchal cord had the highest rate of thrombosis-related histopathology. Finally, cases with both abnormal cords and histologic thrombosis had significantly higher rates of adverse outcomes, including IUGR and

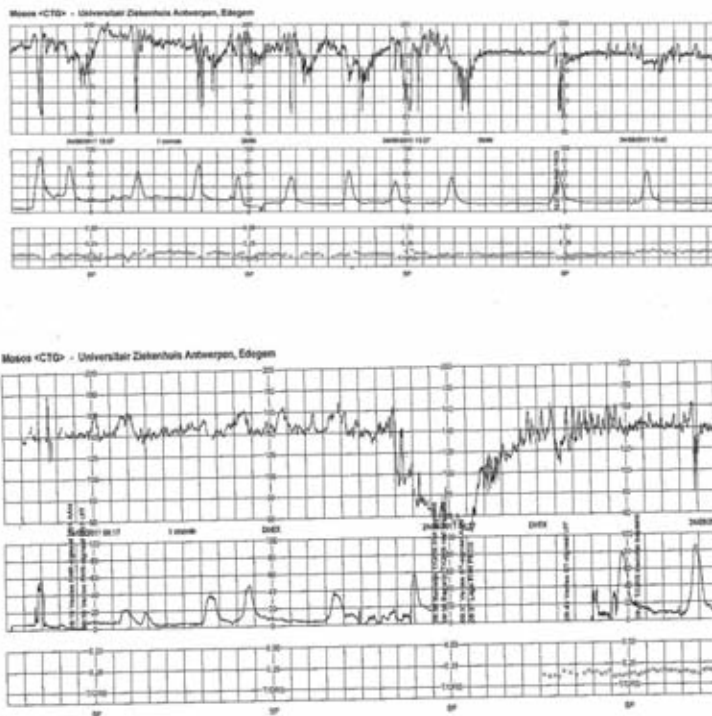


Figure 1. Fetal heart rate monitoring. Fetal bradycardia can be related to intrauterine growth restriction as well as to excessive long umbilical cord (ELUC) (for example cord entanglement is more frequently seen in ELUCs).

stillbirth. We can find this association of an abnormal cord, histologic thrombosis and IUGR also in our case. Unfortunately these histological findings are only detectable postpartum, but it is not unimaginable to examine the umbilical cord during prenatal care.

Ultrasound evaluation of the umbilical cord should not be very incriminating in the assessment of a fetus in the prenatal care.

Asia Saleemuddin describes that in a study of placentas reviewed for adverse neurodevelopmental outcome, fetal thrombotic vasculopathy showed to be most commonly associated with grossly abnormal umbilical cords (including excessively long umbilical cords, nuchal cords, or cords showing hypertwisting and/or abnormal insertions) which predispose to cord compression and compromise fetal blood flow.⁵ It is remarkable that fetal thrombotic vasculopathy was originally suspected to be mainly a marker for fetal and/or maternal thrombophilia, but however, later studies found similar rates of fetal/maternal thrombophilias in placentas with or without fetal thrombotic vasculopathy. Andres et al described an association between massive perivillous fibrin deposition, also called maternal floor infarction, and IUGR.⁶ Mana Tawevisit⁷ presented a case of a 37-week male stillborn fetus whose placenta had an excessively long umbilical cord and no other cord abnormalities associated with fetal thrombotic vasculopathy (FTV). This case

illustrates the unusual occurrence of FTV of such severe extent in association with ELUC leading to fetal demise. This case illustrates that ELUC alone may be enough to predispose the placenta to massive FTV. We present this case to emphasize the role of umbilical cord length as a predictor of adverse perinatal outcome. Umbilical cord abnormalities can be an *early warning system* for fetal problems. A lean or hypo-coiled umbilical cord has been described as a factor contributing to IUGR and perinatal complications.⁸ Studies have been published on the relation between umbilical cord thickness⁹ even from the first trimester and perinatal outcome,¹⁰ and prenatal indices for coiling and umbilical cord diameter have been published¹¹ and related to fetal outcome, but no simple and reliable methods has been developed to evaluate umbilical cord length sonographically, only sophisticated experimental models not yet applicable in clinical medicine have been developed.¹²

More research is needed to evaluate the role of umbilical cord length and to determine the possibility to develop simple methods, for which we propose for instance the number of transverse cuts through the umbilical cord in the four quadrants such as used in the amniotic fluid index, to measure umbilical cord length during routine sonographical examination or in cases of IUGR.

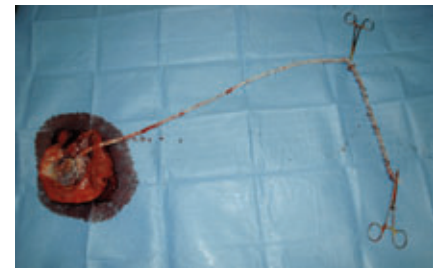


Figure 2. Placenta with excessive long umbilical cord: 125 cm.

References

1. Redline RW. Clinical and pathological umbilical cord abnormalities in fetal thrombotic vasculopathy. *Hum Pathol* 2004;35:1494-98.
2. Chan JS, Baergen RN. Gross umbilical cord complications are associated with placental lesions of circulatory stasis and fetal hypoxia. *Pediatr Dev Pathol* 2012;15:487-94.
3. Baergen RN, Malicki D, Behling C, Benirschke K. Morbidity, mortality, and placental pathology in excessively long umbilical cords: retrospective study. *Pediatr Dev Pathol* 2001;4:144-53.
4. Tantbirojn P, Saleemuddin A, Sirois K. Gross abnormalities of the umbilical cord: related placental histology and clinical significance. *Placenta* 2009;30:1083-8.
5. Saleemuddin A, Tantbirojn P, Sirois K. Obstetric and perinatal complications in placentas with fetal thrombotic vasculopathy. *Pediatr Dev Pathol* 2010;13:459-64.
6. Andres RL, Kuyper W, Resnik R. The association of maternal floor infarction of the placenta with adverse perinatal outcome. *J Clin Pathol* 2008;61:1276-84.
7. Tawevisit M, Scott Thorner P. Massive fetal thrombotic vasculopathy associated with excessively long umbilical cord and fetal demise: case report and literature review. *Pediatr Dev Pathol* 2010;13:112-5.
8. El Behery MM, Nouh AA, Alanwar AM, Diab AE. Effect of umbilical vein blood flow on perinatal outcome of fetuses with lean and/or hypo-coiled umbilical cord. *Arch Gynecol Obstet* 2011;283:53-8.
9. Ghezzi F, Raio L, Günter Duwe D, et al. Sonographic umbilical vessel morphometry and perinatal outcome of fetuses with a lean umbilical cord. *J Clin Ultrasound* 2005;33:18-23.
10. Goynumner G, Ozdemir A, Wetherilt L, et al. Umbilical cord thickness in the first and early second trimesters and perinatal outcome. *J Perinat Med* 2008;36:523-6.
11. de Laat MW, Franx A, Bots ML, et al. Umbilical coiling index in normal and complicated pregnancies. *Obstet Gynecol* 2006;107:1049-55.
12. Rousian M, Verwoerd-Dikkeboom CM, Koning AH, et al. First trimester umbilical cord and vitelline duct measurements using virtual reality. *Early Hum Dev* 2011;87:77-82.