



OPEN ACCESS

Integrated approach to treatment-resistant atrial fibrillation: additional value of acupuncture

F A M Jonkman,^{1,2,3} M L Jonkman-Buidin^{1,2,3}

¹Department of Acupuncture, Acupuncture Outpatient Clinic Heel de Mens, Heelsum, The Netherlands

²Department of Cardiology, Stichting Cardiologie Heelsum, Heelsum, The Netherlands

³Training Centre Acupuncture and Integrative Medicine, Human Balance Teachings, Heelsum, The Netherlands

Correspondence to

F A M Jonkman, Human Balance Teachings, Training Centre Acupuncture and Integrative Medicine, Veentjesbrug 5, 6866 NC Heelsum, The Netherlands; info@humanbalance.nl, fokke@zorggroepjonkman.nl

Received 19 April 2013

Accepted 3 July 2013

Published Online First

24 July 2013

ABSTRACT

A 62-year-old patient with chronic bronchitis had treatment-resistant atrial fibrillation. Electrical cardioversion was performed, but sinus rhythm (SR) lasted only for some minutes. Administration of amiodarone was withheld in favour of a course of acupuncture treatment in order to increase the success rate of a second attempt of electrical cardioversion. After two acupuncture treatments, spontaneous conversion to SR occurred. Relapses into atrial fibrillation in the following five winters, associated with attacks of bronchitis, also responded to acupuncture. The mechanisms of action of the acupuncture treatment and the value of this integrated approach to treatment are discussed.

INTRODUCTION

Atrial fibrillation (AF) is a rhythm disorder which increases in prevalence with age. It is known to be precipitated by hypertension, valve disorders, heart failure and coronary artery disease, after surgery and by pulmonary problems.^{1 2}

Amiodarone is very effective in the treatment of paroxysmal AF but may cause severe side effects. It is often administered prior to electrical cardioversion in order to increase the success rate of restoring and preserving sinus rhythm (SR).¹

In a Chinese study, two groups of 40 patients with AF were treated with amiodarone and acupuncture, respectively. Acupuncture was shown to be as effective as intravenous amiodarone in conversion of AF into SR.³ Several other case studies suggest the efficacy of acupuncture in preventing AF.^{4 5}

CASE STUDY

On 24 March 2006 a 62-year-old patient presented with dyspnoea and loss of physical condition in a nearby clinic (clinic A). The treating cardiologist diagnosed AF with rapid ventricular response

and the patient was prescribed oral anticoagulants as well as digoxin for ventricular rate reduction. Prior to the occurrence of AF, the patient suffered from periods of overwork and chronic bronchitis. Since echocardiography could not be performed in this clinic within 3 months, the patient was referred to our clinic (clinic B) on 5 May 2006 with AF and still a mean ventricular response of 113 beats/min (figure 1) and blood pressure of 120/70 mm Hg. Echocardiography was reported as showing dilation of the left ventricle (LV) with globally reduced systolic ventricular function, left ventricular end diastolic diameter (LVED) 60 mm and minor mitral regurgitation and dilation of the left atrium (LA) of 40×57 mm. The dimensions of the right side of the heart were higher but without tricuspid regurgitation.

The patient was administered sotalol in order to further reduce the ventricular rate and facilitate easier conversion to SR. Quinapril was added for afterload reduction to enable remodelling of the tachycardia-induced dilation of the LV and additional sedation of the neurohumoral renin-angiotensin-aldosterone system (RAAS). These and several other mechanisms could be the pathogenic pathways by which inhibition of the RAAS prevents AF.^{6–8} Because of a pre-existent chronic cough, additional diagnostics were requested by his GP.

Eleven days later, on 16 May 2006, cardioversion was performed with 100 and 200 Joule of triggered electrical cardioversion (ECV) in clinic C, resulting in short-lasting SR before recurrence of AF. In order to improve the outcome of a future ECV, the attending cardiologist of clinic C suggested adding amiodarone to the medication as preparation for a second attempt. Amiodarone, although very effective in the treatment of AF, may



Open Access
Scan to access more
free content

To cite: Jonkman FAM, Jonkman-Buidin ML. *Acupunct Med* 2013;**31**:327–330.

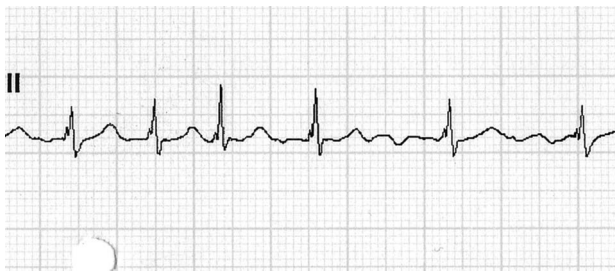


Figure 1 ECG upon referral to our clinic: atrial fibrillation with ventricular response of 113 beats/min.

cause many side effects (blurred vision, gastrointestinal problems, oversensitivity to sunlight, pulmonary fibrosis, in many patients thyroid disorders on chronic use). The choice of medication and other routes were discussed with the patient and we chose to avoid amiodarone in agreement with the cardiologist of clinic C. Consequently, the dose of sotalol was increased from 80 mg twice daily to 160+80 mg each day, and the patient was referred to our acupuncture clinic for treatment as an intermediate measure in preparing him for a second attempt of ECV.

The treatment goals of acupuncture treatment were:

- ▶ Sedation of the RAAS and noradrenergic autonomic nerve system.⁹
- ▶ Stabilisation of the parasympathetic autonomic nerve system.^{10 11}
- ▶ Improvement of pulmonary condition.¹²
- ▶ Reduction of impact of circumstantial stress (patient was overworked).¹³
- ▶ Improvement of general condition.

We intended that the second cardioversion should be performed after 6 weeks of weekly acupuncture treatment.

ACUPUNCTURE TREATMENT

During the initial consultation according to traditional Chinese medicine (TCM) principles, the patient's tongue showed the presence of coating with red sides and tip and stagnation in the sublingual veins. The pulse showed an empty quality of the Heart, Lung and Kidney positions and a slippery quality in the Spleen position. The TCM diagnosis was Liver, Lung and Kidney Yin deficiency, Dampness and Blood stagnation.

Two acupuncture treatments were administered on 30 May and 6 June 2006. Stimulation of the needles was kept at an even method, which means no stimulation or sedation, for the length of 30 min per session. Treatment plans and points used were as follows:

- ▶ Tonify Liver, Kidney and Heart Yin: LR8, KI3-BL23, HT6-PC6
- ▶ Promote Qi and blood circulation: LR3-LI4, SP6-BL17
- ▶ Disperse Damp and tonifying Lung Qi: ST40, LU7
- ▶ Regulate sympathetic system: GB20
- ▶ Ear needles: Shen Men, Heart-Lung point.

OUTCOME

The third acupuncture treatment was scheduled for 14 June 2006. At this point the patient reported feeling substantially better and indicated he had started working again. His GP had ordered a chest x-ray which proved to be normal. Given the patient's self-assessment, an ECG was performed which showed a regular SR of 52 beats/min and incomplete right bundle branch block (figure 2). In spite of this new presentation, acupuncture was nevertheless administered in a supportive role but there was no need for a second ECV. The patient showed further general improvement with acupuncture treatment.

In the following years the patient's AF recurred almost annually upon exacerbation of his chronic bronchitis. Each time he was treated with acupuncture for his pulmonary complaints, at which point his AF converted to SR again. In 2009 his GP diagnosed chronic obstructive pulmonary disease GOLD stage II and started inhalation therapy. The presence of predominantly SR resulted in complete restoration of the shape of the LV (echocardiography 22 Nov 2011: LVED 49 mm). The blood pressure over this period was 100–120/60–70 mm Hg.

In 2012 the recurrence of AF was resistant to the therapeutic measures that had proved effective since 2006. Given his comorbid condition, our intention was to avoid amiodarone and instead opt for catheter ablation, which had developed into a common and effective treatment in recent years. The restoration of the shape of the LV upon conversion to SR was an important argument by the electrophysiological team of clinic D to accept this patient for the ablation procedure. In the preparation of the catheter ablation an MRI showed a thoracoabdominal aneurysm. Although correction of the aneurysm and ablation was planned in one procedure in clinic E, the surgical intervention was restricted to the aneurysm because it proved to be too extensive. The postoperative course was delayed due to difficulties in weaning the patient off artificial ventilation given the existing pulmonary weakness. Incidentally, the surgeon in charge of the procedure reported that pulmonary function was abnormal upon thoracotomy: the lungs showed no collapse under pressure changes to the chest cavity but required manual assistance to be held aside as 'big rigid sacs'.

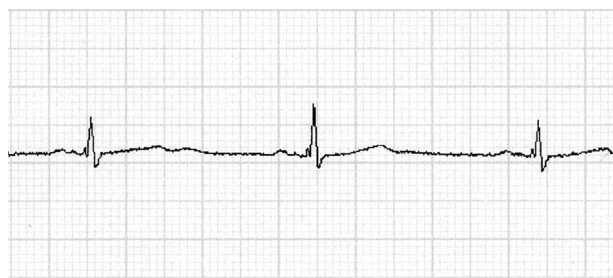

Figure 2 ECG after conversion: sinus rhythm of 52 beats/min.

DISCUSSION

Acupuncture has been shown to be effective in achieving and maintaining SR in patients with paroxysmal AF. From a western point of view, we suggest that the pathogenic mechanisms that may be involved in acupuncture could be:

1. Reduction of sympathetic tone.⁹ An additional advantage of acupuncture is that sympathetic tone can be reduced without considerable hypotension, which is a common drawback of many cardiovascular drugs and is especially important in patients with a compromised left ventricular function.^{13 14}
2. Prevention of unstable bursts of adrenergic and vagal tone.^{10 11}
3. Improvement of the pulmonary condition,¹² which can be considered a contributing factor in AF. The yearly success in restoring SR after relapses of AF due to exacerbations of his chronic bronchitis is in line with the importance of a good pulmonary condition in this type of patient with existing comorbid conditions. The restoration of SR through acupuncture in this patient suggests that pulmonary function was even more crucial than first assumed; the chance of pulmonary fibrosis under an average dose of amiodarone is small, but could have been detrimental to the health status of this particular patient.
4. Improvement of the general condition.

There is much ongoing research related to the efficacy of inhibitors of the RAAS in primary and secondary prevention of AF.^{7 8} Apart from the known beneficial effects such as neurohormonal sedation and afterload reduction, other direct effects on the arrhythmogenic substrate in the LA are discussed: inhibition of fibrosis, inflammation^{14 15} and LA remodelling as a pathogenic mechanism in the prevention of AF. Further research could help to determine similar mechanisms through acupuncture since the existing data suggest that acupuncture sedates the neurohormonal systems⁹⁻¹¹ and inhibits the inflammatory processes.¹⁵⁻¹⁸

In this patient with chronic bronchitis, 'spontaneous' conversion to SR without the need for administration of amiodarone or ECV proved to be an effective route and underlines the value of an integrative approach. These findings indicate the need for additional clinical research in order to further determine the mechanism of action in acupuncture and establish its place in the integrative treatment of AF.

Contributors FAMJ was responsible for the western medical and pharmacological part; MLJ-B was responsible for the TCM part.

Competing interests None.

Patient consent Obtained.

Provenance and peer review Not commissioned; internally peer reviewed.

Open Access This is an Open Access article distributed in accordance with the Creative Commons Attribution Non Commercial (CC BY-NC 3.0) license, which permits others to distribute, remix, adapt, build upon this work non-

commercially, and license their derivative works on different terms, provided the original work is properly cited and the use is non-commercial. See: <http://creativecommons.org/licenses/by-nc/3.0/>

REFERENCES

- 1 Fuster V, Rydén LE, Cannom DS, *et al.* 2011 ACCF/AHA/HRS focused updates incorporated into the ACC/AHA/ESC 2006 guidelines for the management of patients with atrial fibrillation: a report of the American College of Cardiology Foundation/American Heart Association Task Force on practice guidelines. *Circulation* 2011;123:269–367.
- 2 Camm AJ, Lip GYH, De Caterina R, *et al.* 2012 focused update of the ESC guidelines for the management of atrial fibrillation: an update of the 2010 ESC guidelines for the management of atrial fibrillation. Developed with the special contribution of the European Heart Rhythm Association. *Eur Heart J* 2012;33:2719–47.
- 3 Xu HK, Zhang YF. Comparison between therapeutic effects of acupuncture and intravenous injection of amiodarone in the treatment of paroxymal atrial fibrillation and atrial flutter. *Zhongguo Zhen Jiu* 2007;27:96–8.
- 4 Lombardi F, Belletti S, Battezzati PM, *et al.* Acupuncture for paroxysmal and persistent atrial fibrillation: an effective non-pharmacological tool? *World J Cardiol* 2012;4:60–5.
- 5 Lomuscio A, Belletti S, Battezzati PM, *et al.* Efficacy of acupuncture in preventing atrial fibrillation recurrences after electrical cardioversion. *J Cardiovasc Electrophysiol* 2011;22:241–7.
- 6 Lozano HF, Conde CA, Florin T, *et al.* Treatment and prevention of atrial fibrillation with non-antiarrhythmic pharmacologic therapy. *Heart Rhythm* 2005;2:1000–7.
- 7 Savelieva I, Kakouros N, Kourliouros A, *et al.* Upstream therapies for management of atrial fibrillation: review of clinical evidence and implications for European Society of Cardiology guidelines. Part I: primary prevention. *Europace* 2011;13:308–28.
- 8 Savelieva I, Kakouros N, Kourliouros A, *et al.* Upstream therapies for management of atrial fibrillation: review of clinical evidence and implications for European Society of Cardiology guidelines. Part II: secondary prevention. *Europace* 2011;13:610–25.
- 9 Longhurst JC. Acupuncture cardiovascular actions: a mechanistic perspective. *Acupunct Med* 2013;25:101–13.
- 10 Lombardi F, Tarricone D, Tundo F, *et al.* Autonomic nervous system and paroxysmal atrial fibrillation: a study based on the analysis of RR interval changes before, during and after paroxysmal atrial fibrillation. *Eur Heart J* 2004;25:1242–8.
- 11 Bettoni M, Zimmermann M. Autonomic tone variations before the onset of paroxysmal atrial fibrillation. *Circulation* 2002;105:2753–9.
- 12 Zhang W-P. Effects of acupuncture on the pulmonary function and heart rate variability in different state of bronchial asthma. *Zhen Ci Yan Jiu* 2007;32:42–8.
- 13 Middlekauff HR, Hui K, Yu JL, *et al.* Acupuncture inhibits sympathetic activation during mental stress in advanced heart failure patients. *J Card Fail* 2002;8:399–406.
- 14 Middlekauff HR. Acupuncture in the treatment of heart failure. *Cardiol Rev* 2004;12:171–3.
- 15 Israel CW. Effect of statins in "upstream therapy" of atrial fibrillation: better reliability with implantable cardiac monitors. *Eur Heart J* 2008;29:1798–9.
- 16 Boos CJ, Anderson RA, Lip GYH. Is atrial fibrillation an inflammatory disorder? *Eur Heart J* 2006;27:136–49.

- 17 Kristen AV, Schuhmacher B, Strych K, *et al.* Acupuncture improves exercise tolerance of patients with heart failure: a placebo-controlled pilot study. *Heart* 2010;96:1396–400.
- 18 Kavoussi B, Ross BE. The neuroimmune basis of anti-inflammatory acupuncture. *Integr Cancer Ther* 2007;6:251–7.