

Received: 2020.03.05

Accepted: 2020.03.30

Available online: 2020.05.21

Published: 2020.06.08

# A Novel Guidewire Pull-Through Technique in Endovascular Treatment for Severely Calcified Infrapopliteal Occlusion

## Authors' Contribution:

Study Design A  
Data Collection B  
Statistical Analysis C  
Data Interpretation D  
Manuscript Preparation E  
Literature Search F  
Funds Collection G

ABCDE **Daisuke Ueno**  
ABEF **Tetsuya Nomura**  
F **Satoshi Tasaka**  
F **Kenshi Ono**  
F **Yu Sakaue**  
F **Naotoshi Wada**  
AF **Natsuya Keira**  
G **Tetsuya Tatsumi**

Department of Cardiovascular Medicine, Kyoto Chubu Medical Center, Nantan, Kyoto, Japan

**Corresponding Author:** Tetsuya Nomura, e-mail: [t2ya821@yahoo.co.jp](mailto:t2ya821@yahoo.co.jp)  
**Conflict of interest:** None declared

**Patient:** Female, 74-year-old  
**Final Diagnosis:** Arteriosclerosis obliterans  
**Symptoms:** Skin ulcers  
**Medication:** —  
**Clinical Procedure:** —  
**Specialty:** Cardiology

**Objective:** Unusual or unexpected effect of treatment


**Background:** In practical settings of endovascular treatment (EVT) for below-the-knee arteries, we often encounter cases of severe calcification. To overcome problems regarding device uncrossing due to severe calcifications, a bidirectional approach and subsequent guidewire externalization is one of critical methods.

**Case Report:** A 74-year-old female with refractory skin ulcers on the lower frontal thigh and necrotic toes on the left side showed occlusion in both the anterior tibial artery (ATA) and tibio-peroneal trunk. Both occluded vessels were accompanied with dense calcification. In the process of EVT targeting the occluded ATA, the retrograde guidewire successfully passed the occlusion and was advanced into the antegrade guide sheath. Next, we attempted guidewire externalization, but severe calcification of the ATA hampered the procedure. Therefore, we introduced a guide extension catheter and a balloon catheter in an antegrade fashion to establish a system of trapping the retrograde guidewire between these devices. Then, we pulled the system back outside the guide sheath, which completed guidewire externalization. We performed prolonged balloon dilatation and finally achieved favorable revascularization of the ATA.

**Conclusions:** Our novel method led to successful retrograde guidewire externalization, overcoming severely calcified lesions. It is generally essential for clinicians to increase their expertise regarding EVT procedures to attain better outcomes.

**MeSH Keywords:** Arteriosclerosis Obliterans • Case Reports • Endovascular Procedures • Ischemia • Skin Ulcer

**Full-text PDF:** <https://www.amjcaserep.com/abstract/index/idArt/924057>



1300



4



5



## Background

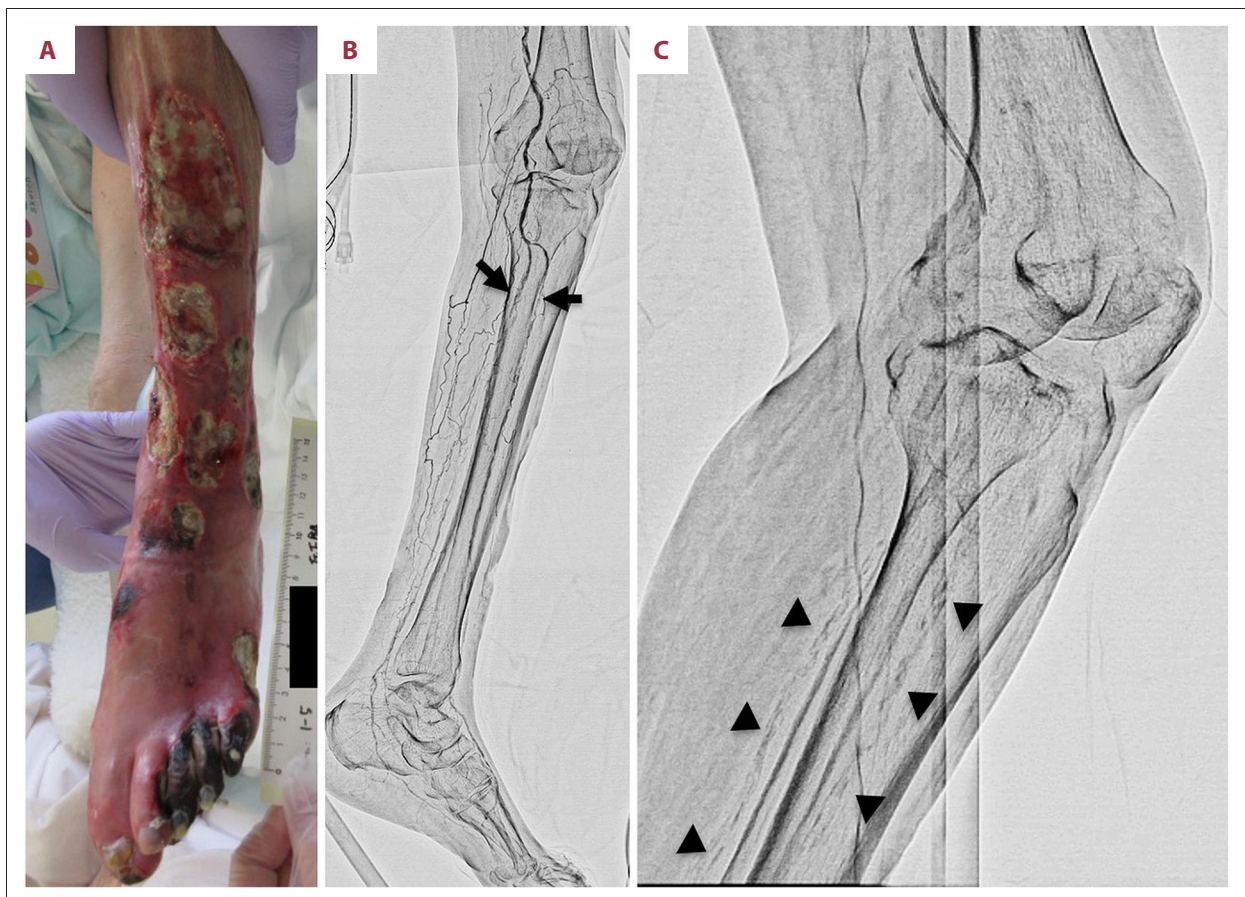
In practical settings of endovascular treatment (EVT) for below-the-knee arteries, we often encounter cases of severe calcification. Such calcified lesions often hamper the delivery of devices such as a guidewire, microcatheter, or balloon catheter, and sometimes result in incomplete vessel dilatation. To overcome problems regarding device uncrossing due to severe calcifications, a bidirectional approach and subsequent guidewire externalization is one of the critical methods used. However, it is not always easy to establish a bidirectional approaching system in cases with severe calcifications.

## Case Report

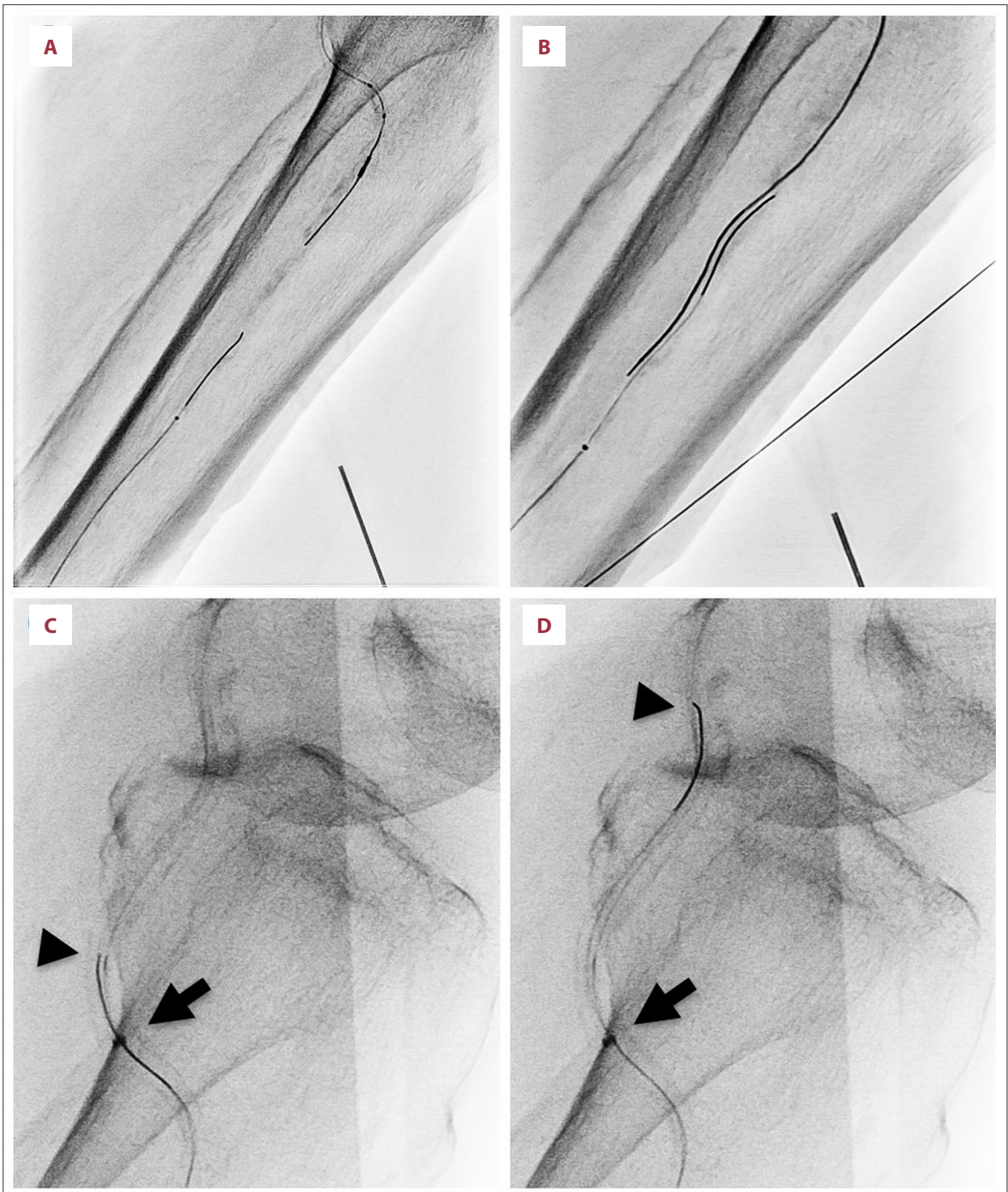
A 74-year-old female was admitted to our hospital complaining of refractory skin ulcers on the lower frontal thigh and necrotic toes on the left side, which corresponded to a Rutherford grade of 6 (Figure 1A). She had a past medical history of cerebral infarction and her comorbidities were type 2 diabetes

mellitus, hypertension, and dyslipidemia. Physical examination and laboratory data showed inflammatory signs possibly caused by local wound infection. Intravenous administration of antibiotics controlled the local infection. However, mummification of the left second to fifth toes and multiple unhealed ulcerations on the dorsum pedis persisted. Her ankle brachial pressure index was unmeasurable on both sides. Skin perfusion pressure (SPP) was 21 mmHg at the left dorsum of the foot. The Wiffl classification of the left lower extremity was Wound 2 Ischemia 3 Foot Infection 1, which corresponded to Stage 4 [1]. That meant she had high risk of 1-year limb amputation. Computed tomography angiography showed occlusion below the popliteal artery with severe calcification. We suspected an ischemic etiology of the refractory ulcerations and performed angiography of the below-the-knee arteries.

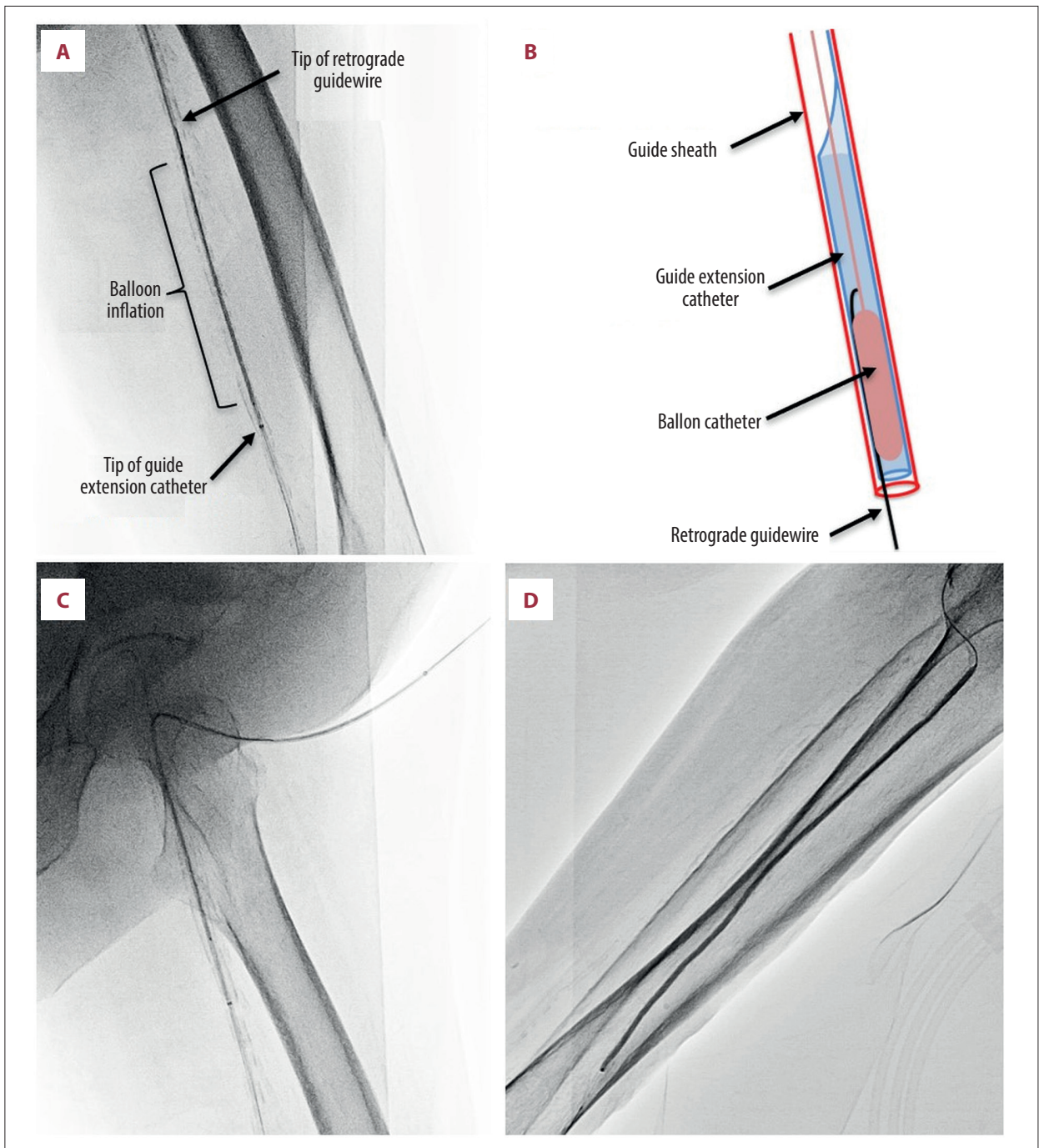
Initial angiography showed occlusion in both the anterior tibial artery (ATA) and tibio-peroneal trunk (Figure 1B). Both occluded vessels were accompanied with dense calcification (Figure 1C). We started EVT initially targeting the occluded ATA with severe calcification. Because of supposed difficulty in procedure



**Figure 1.** (A) Refractory skin ulcers on the lower frontal thigh, and necrotic toes on the left side. (B) Initial angiography showing occlusion in both the anterior tibial artery and tibio-peroneal trunk. (C) Dense calcification as a landmark of the running direction of below-the-knee arteries.



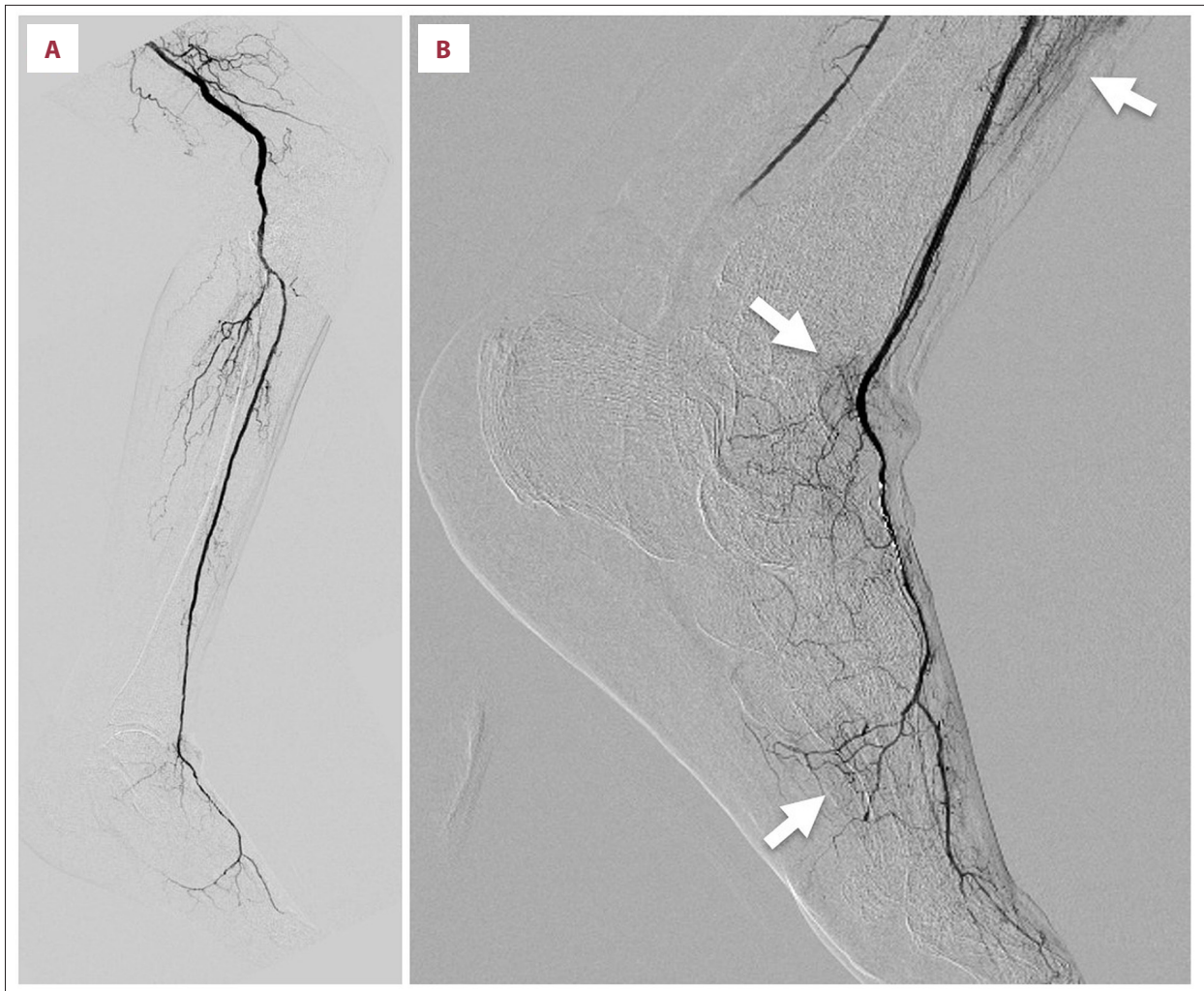
**Figure 2.** (A) Bidirectional approach targeting calcification as the landmark of the running direction of the anterior tibial artery. (B) Antegrade guidewire advancement in the subintimal space. (C) Retrograde guidewire going into the antegrade guide sheath (arrow: tip of antegrade guide sheath, arrowhead: tip of retrograde guidewire). (D) Retrograde guidewire advancement as far as the mid portion of the popliteal artery in the guide sheath.



**Figure 3.** (A) Trapping the retrograde guidewire with balloon inflation inside the guide extension catheter. (B) Schema of the system. (C) Pulling the system back outside the guide sheath. (D) Prolonged balloon dilatation in the anterior tibial artery.

via solely antegrade approach, we established a bidirectional approach from the beginning of the session. A 4.5-Fr guide sheath, Parent Plus 58 cm (Medikit, Tokyo, Japan), was inserted via the left common femoral artery and Ichibanyari PAD microcatheter (Kaneka, Osaka, Japan) via the left dorsalis pedis artery. We advanced an Atrato XS 9-40 guidewire (ASAHI Intecc, Aichi, Japan) in an antegrade fashion and retrogradely

advanced a Ruby super hard guidewire (Kaneka, Osaka, Japan) targeting calcification as a landmark of the running direction of the ATA (Figure 2A). However, the antegrade guidewire was blocked by a dense proximal calcification and sheared off into the subintimal space (Figure 2B). After negotiating bidirectional guidewires, we could advance the retrograde guidewire in the right direction through intraluminal space. And, the retrograde



**Figure 4.** (A) Final angiography showing one straight vessel to digital arteries. (B) Favorable wound blushes at the lesions with ulcerations.

guidewire reached the popliteal artery and entered in the guide sheath (Figure 2C, 2D). Next, we tried to retrogradely advance the microcatheter by trapping the retrograde guidewire by balloon inflation inside the guide sheath. However, the microcatheter could not be advanced over the retrograde guidewire due to tight friction of severe calcification. Therefore, we could accomplish neither further advancement of the retrograde guidewire nor exchanging it for another one.

Next, we introduced a 6-Fr guide extension catheter, Guideliner PV Catheter (Japan Lifeline, Tokyo, Japan) in an antegrade fashion, and trapped the retrograde guidewire with a SHIDEN 3.0/100-mm balloon catheter (Kaneka, Osaka, Japan) by inflating it inside the guide extension catheter (Figure 3A, 3B). Then, we pulled the guide extension catheter back outside the guide sheath, and finally succeeded in “pull-through” of the retrograde guidewire (Figure 3C). We dilated the ATA for a prolonged period with a SHIDEN HP 2.5/20-mm balloon catheter

(Kaneka, Osaka, Japan) (Figure 3D) and favorably achieved one straight line (Figure 4A). We could see favorable wound blushes at the lesions with ulcerations (Figure 4B). After the successful EVT, SPP at the left dorsum of the foot recovered to 60 mmHg, and the refractory skin ulcers on the lower frontal thigh were gradually getting better. However, before achieving completely healed ulcers, she passed away due to aspiration pneumonia.

## Discussion

We demonstrated a successful EVT for a severely calcified infrapopliteal occlusion with a novel guidewire pull-through technique. Infrapopliteal artery disease is predominant in critical limb ischemia [2]. Bidirectional approaches such as distal site puncture and a trans-pedal approach are critical for successful outcomes [3]. However, even under the strategy of a

bidirectional approach, some difficulties often hamper the successful completion of EVT. One of them is a severely calcified lesion [4]. In EVT for below-the-knee lesions with severe calcification, we encounter some cases in which no device can pass even after the guidewire has passed the lesions. In this situation, we can use the BAD FORM technique for device delivery in condition that the guidewire externalization has been established [5]. However, guidewire externalization itself was difficult to achieve in our case.

After the retrograde guidewire reached the antegrade guide sheath, it could not be advanced further due to severe friction of the calcified lesions. We could not retrogradely advance a microcatheter by trapping the retrograde guidewire by balloon inflation inside the guide sheath as well. However, this balloon trapping procedure provided us a novel tip to overcome this situation. Referring to the concept of the BAD FORM technique which recommends a pull maneuver rather than push one, we devised to apply the pull maneuver for guidewire externalization in this situation. However, if the retrograde guidewire is trapped directly with the antegrade guide sheath, we cannot complete guidewire externalization while keeping the guide sheath inside the artery. To avoid this situation, we introduced a guide extension catheter in which the retrograde guidewire could be trapped by balloon inflation, and we were able to pull the system back outside the guide sheath while keeping the position of the guide sheath.

We further considered what kind of balloon trapping system inside the guide extension catheter is the most suitable for achieving this procedure. The GuideLiner PV guide extension catheter is a monorail-type “child” support catheter that comprises of a 25-cm silicon-coated guide extension catheter connected via a metal “collar” with a 125-cm stainless steel shaft to a proximal positioning tab. Because the inner diameter of the 6-Fr GuideLiner PV catheter is 0.056-inch/1.42-mm, we applied a balloon catheter with 3.0-mm diameter at nominal pressure inflation to tightly fix the guidewire in the guide extension catheter. The maximum length of the candidate balloon

catheter for trapping a guidewire is 25 cm in accordance with the length of guide extension catheter. The longer the length of the trapped guidewire with balloon inflation, the stronger the degree of fixing the guidewire inside the guide extension catheter. However, the retrograde guidewire advanced in the guide extension catheter as far as only 10 cm proximally in our case. Therefore, we used a balloon catheter with 10-cm length to trap the retrograde guidewire. As a result, our choice of balloon catheter with 3.0 mm in diameter and 10 cm in length worked well for completing our strategy.

Instead of the method as shown in this paper, it would be easy and effective to ensnare the retrograde guidewire with a size-adjusted snare catheter in an antegrade fashion and achieve guidewire externalization. However, due to unavailability of a suitable snare catheter at that time in our hospital, we devised a novel guidewire pull-through technique under conditions of restricted guidewire maneuverability by utilizing existing products.

## Conclusions

In contemporary EVT for below-the-knee lesions, a bidirectional approach and subsequent guidewire externalization are very useful procedures for revascularization. Calcification is one of the toughest obstacles in EVT for below-the-knee lesions, but our novel method led to successful retrograde guidewire externalization, overcoming severely calcified lesions. Although there are alternative methods, such as a snaring guidewire, that can be used in this situation, our technique could become one of the useful options. It is generally essential for clinicians to increase their expertise regarding EVT procedures to attain better outcomes.

## Conflicts of interest

None.

## References:

1. Darling JD, McCallum JC, Soden PA et al: Predictive ability of the society for vascular surgery wound, ischemia, and foot infection (WIFI) classification system following infrapopliteal endovascular interventions for critical limb ischemia. *J Vasc Surg*, 2016; 64: 616–22
2. Kawarada O, Zen K, Hozawa K et al: Contemporary critical limb ischemia: Asian multidisciplinary consensus statement on the collaboration between endovascular therapy and wound care. *Cardiovasc Interv Ther*, 2018; 33: 297–312
3. Welling RHA, Bakker OJ, Scheinert D et al: Below-the-knee retrograde access for peripheral interventions: A systematic review. *J Endovasc Ther*, 2018; 25: 345–52
4. Mustapha JA, Diaz-Sandoval LJ, Saab F: Infrapopliteal calcification patterns in critical limb ischemia: Diagnostic, pathologic and therapeutic implications in the search for the endovascular holy grail. *J Cardiovasc Surg*, 2017; 58: 383–401
5. Nakabayashi K, Ando H, Kaneko N et al: A novel lesion crossing technique: Balloon deployment using forcible manner (badform) technique. *Catheter Cardiovasc Interv*, 2017; 90: 1161–65