



Navigation in Shoulder Arthroplasty Surgery

Navegação em cirurgia de artroplastia de ombro

Luis Gustavo Prata Nascimento¹ Roberto Yukio Ikemoto^{1,2} Thomas Wright³

¹Division of Shoulder and Elbow, Faculdade de Medicina do ABC, Santo André, SP, Brazil

²Department of Orthopedics, Hospital Ipiranga, São Paulo, SP, Brazil

³Center for Musculoskeletal Training & Research, University of Florida, Gainesville, Florida, United States

Address for correspondence Roberto Yukio Ikemoto, MD, Division of Shoulder and Elbow, Faculty of Medicine of ABC, Santo André, SP 09060-870, Brazil (e-mail: rob.ike@hotmail.com).

Rev Bras Ortop 2022;57(4):540–545.

Abstract

The indication of shoulder arthroplasties has increased progressively. Accurate positioning of the components may have significant implications for clinical results. The navigation used to aid in the performance of anatomical and reverse total arthroplasties has provided greater precision in implant placement, especially on the glenoid. The development of the technique, material, and prosthesis design have shown encouraging results and led to a trend toward its expansion. In this way, we estimate a higher survival of the arthroplasties resulting from lower rates of dislocation and early loosening. We aim to describe the current technique and to present the results of the literature with navigation. However, comparative clinical studies with long term follow-up are necessary to prove the efficacy in the final results of total shoulder arthroplasties.

Keywords

- ▶ shoulder
- ▶ arthroplasty/ methods
- ▶ surgery, computer assisted

Resumo

A indicação de artroplastias do ombro aumentou progressivamente. O posicionamento preciso dos componentes pode ter implicações significativas para os resultados clínicos. A navegação utilizada para auxiliar no desempenho de artroplastias totais anatômicas e reversas tem proporcionado maior precisão na colocação do implante, especialmente no glenoide. O desenvolvimento da técnica, do material e do desenho da prótese têm mostrado resultados encorajadores e levado a uma tendência de expansão. Dessa forma, estimamos uma maior sobrevida das artroplastias resultantes de menores taxas de luxação e afrouxamento precoce. Nosso objetivo é descrever a técnica atual e apresentar os resultados da literatura com navegação. No entanto, estudos clínicos comparativos com acompanhamento de longo prazo são necessários para comprovar a eficácia nos resultados finais das artroplastias totais do ombro.

Keywords

- ▶ ombro
- ▶ artroplastia/métodos
- ▶ cirurgia assistida por computador

received
October 15, 2019
accepted
March 10, 2020
published online
November 23, 2020

DOI <https://doi.org/10.1055/s-0040-1712989>.
ISSN 0102-3616.

© 2020. Sociedade Brasileira de Ortopedia e Traumatologia. All rights reserved.

This is an open access article published by Thieme under the terms of the Creative Commons Attribution-NonDerivative-NonCommercial-License, permitting copying and reproduction so long as the original work is given appropriate credit. Contents may not be used for commercial purposes, or adapted, remixed, transformed or built upon. (<https://creativecommons.org/licenses/by-nc-nd/4.0/>)

Thieme Revinter Publicações Ltda., Rua do Matoso 170, Rio de Janeiro, RJ, CEP 20270-135, Brazil

Introduction

Both anatomic total shoulder arthroplasty (ATSA) and reverse total shoulder arthroplasties (RTSAs) require the correct positioning of the glenoid component as one of the most critical factors for the success of the procedure.

In ATSA, the malposition of the glenoid component can result in eccentric loading, which can lead to instability and early loosening of the glenoid component. This eccentric directed force will cause overloading of the implant-bone interface and result in premature failure. Consequently, it increases its instability, early loosening, the failure rate of the implant, and deteriorates the clinical results.¹⁻³ The biggest issue is implanting the glenoid component in excessive retroversion or having it incompletely supported. Moving an anatomic glenoid component superiorly may lead to better loading characteristics as an ATSA humeral component generally rides slightly superiorly, but if the glenoid implant is somewhat superior, it will be well-centered. However, with ATSA, we do not want them positioned excessively superiorly inclined, as this can result in cuff failure and secondary glenoid loosening.

In RTSA, the baseplate superiorly on the glenoid or with a superior inclination may develop scapular notching, which is erosion in the lower region of the scapula due to the polyethylene impingement. On the advanced stage, early loosening of the component, reduced function, and pain may occur.⁴

The correct positioning of the glenoid component may be challenging to get even for experienced shoulder surgeons, especially in the case of deformity of the glenoid.⁵

Based on this consideration, preoperative planning is always necessary. A conventional technique can perform it with a two-dimensional CT scan (2D CT). However, that method proved to be inaccurate, especially in severe deformity of the glenoid.^{4,6} Three-dimensional CT scan reconstruction (3D CT) and the development of the software allow us to visualize a virtual surgical procedure, achieve preoperative planning, and to make a patient-specific guide for each case assisting the surgeon intraoperatively to positioning the glenoid component, according to software planning.⁷ It provides greater precision, better functional results, and probably higher survival of the prosthesis.⁴

The literature has shown greater accuracy to correct bone deformities as well as the setting on the glenoid component of both ATSA and RTSA using the preoperative planning based on 3D CT.^{4,6} However, the specific guides require a period to be made, may suffer the influence of soft tissues impairing its accuracy, add cost, and take time to be made. These guides do not allow the surgeon to alter their preoperative plan as well.^{4,7,8}

Computer navigation was developed earlier in spinal surgery and after in the knee and hip joints.^{9,10} The first report of navigation in shoulder surgery was in 2007 by Bicknell et al. The authors described the use of that technique in four-part fractures treated by hemiarthroplasty. They have proved effectivity for the determination of the offset of the humerus head.⁹

Currently, there is only one commercially navigation system, the Guided Personalized Surgery (GPS) (Exactech Inc., Gainesville, FL, USA), but it is not available in Brazil.

There is considerable variability in preoperative surgical planning for both ATSA and RTSA. There currently is no clinical data to support one preoperative plan over another. However, in general, most surgeons aim to preserve as much glenoid bone as possible, minimizing reaming. The preservation of the bone has been more comfortable with the advent of augmented implants. The recommendation for ATSA is to reduce reaming, great use of augmenting glenoid while keeping retroversion between 0° and 7° and inclination from inferior <10° to superior >10°. The anatomic implant is moved slightly superior and anterior to the Friedman line to facilitate central loading of the humeral head on the glenoid as the humeral head tends to ride superiorly.

The planning is very different for RTSA. A version for RTSA can run from retroversion of 10° to anteversion of 5°. Recognize that as the baseplate is further retroverted and inferiorly inclined, so the glenosphere will be more challenging to place on the baseplate. One of the authors uses augmented baseplates in > 90 percent of cases to minimize reaming. There is a general surgeon consensus that the RTSA baseplate should not be superiorly inclined. The present author likes to obtain 4 mm of inferior glenosphere overhang to almost eliminate notching.

Surgical Technique

There are several software systems for ATSA and RTSA surgical planning. All of them acquire a 2D CT scan sliced image; after that, the 3D CT image reconstruction of the shoulder joint is processed. The software provides information for surgical planning, especially for the glenoid. The version and slope of the glenoid acquired allow the implantation of the glenoid component virtually. We can correct eventual deformities, either with a bone graft or with augmented elements, which specifically address each case. Once the planning is done, the generated file is exported to the GPS computer to be used in the operating room.

Similarly to the technologies seen in hip and knee arthroplasties, the GPS uses a fixed point in the anatomy of the patient (Friedman Axis). All instruments are then referenced to this 3D mapping and correlated with preoperative planning to ensure a precise location at the desired location.

That system of navigation assists intraoperatively in the positioning of the glenoid component. The GPS station has a camera, a touch screen, sterile transparent protection, and can be handled during the surgical procedure (►Fig. 1). It should be set < 1 meter from the surgical field, and no object can be located between the fixed sensor on the coracoid process and the navigation station. Sensors are routed to the camera of the station. Particular attention should be given to the positioning of the head of the patient; the intubation cannula should be taken off the opposite side from the operated shoulder, as well as the respirator hose, so that they are not obstacles to communication with the navigation station.

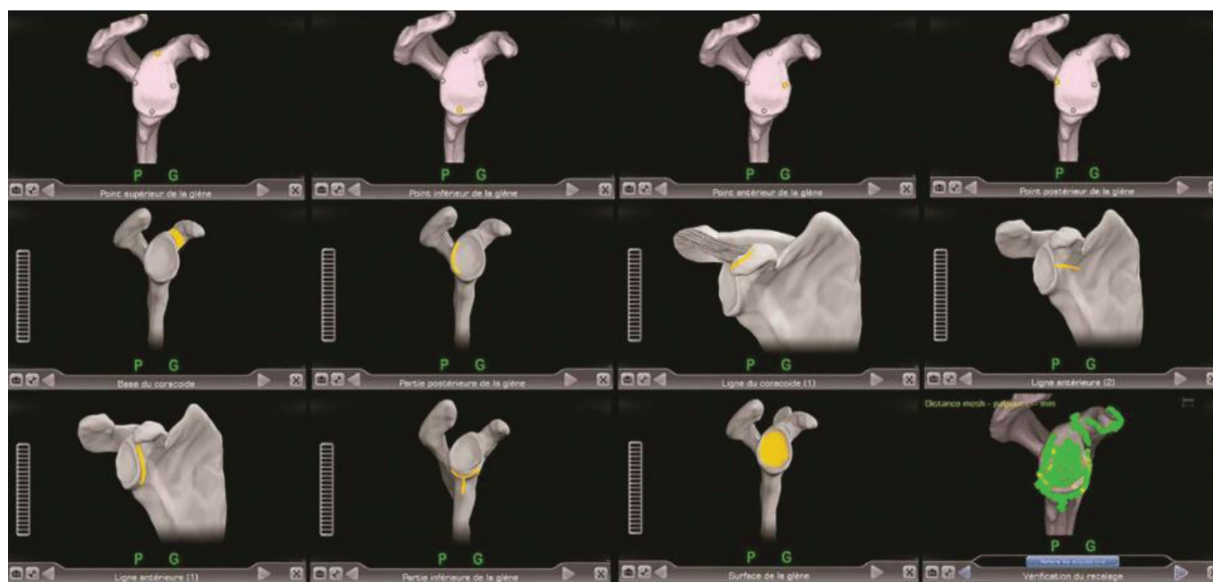


Fig. 1 Image of the GPS station during the process of acquiring the anatomy of the patient. (Courtesy of Exactech, INC, Gainesville, FL, USA).

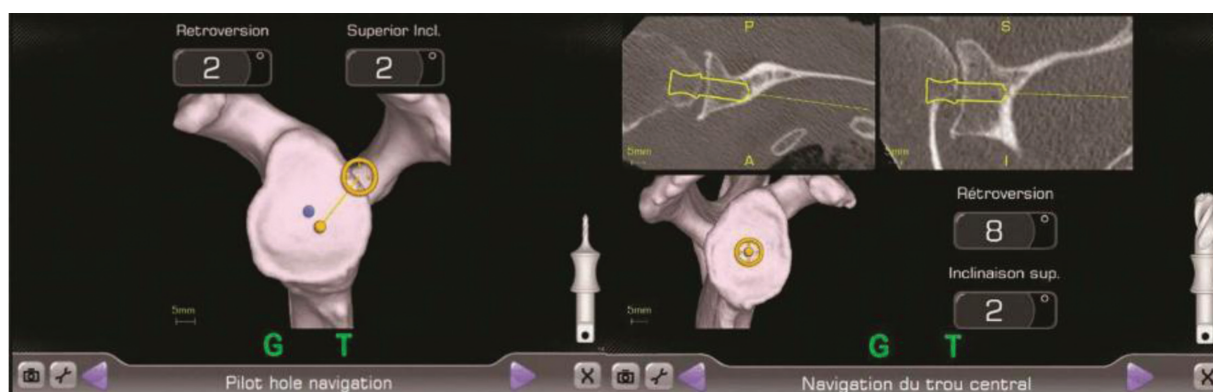


Fig. 2 Image of the GPS station during the process of locating the entry point to perform the initial hole. (Courtesy of Exactech, INC, Gainesville, FL, USA).

The system was designed for use with the deltopectoral access pathway for both ATSA and RTSA. The incision will begin ~ 1 to 2 cm proximal to the standard deltopectoral path, that is, at the lower edge of the clavicle, to allow access to the coracoid process that should be exposed, and the electrocautery used to remove the periosteal from the superior aspect; this will provide a support zone for the sensor. The tracker is attached to the coracoid using two screws with the posterior one, the most extended screw, which is the most important one. The attachment has to be stable, and all assistants should avoid hitting it and destabilizing it during the course of the surgery. If the tracker gets loose during the course of the operation, the navigation will no longer be accurate. After the tracker is placed on the coracoid process, the next step is to acquire information from the local anatomy through the use of a sensor probe. That probe has to set on points, and surfaces arranged successively on the navigation station screen. The system guides the surgeon in this process of acquiring the information (► **Fig. 2**).

Acquisition and registration of the glenoid data must not be done over soft tissue, labrum, or cartilage, which need to be removed before registration. Time is required for the place-

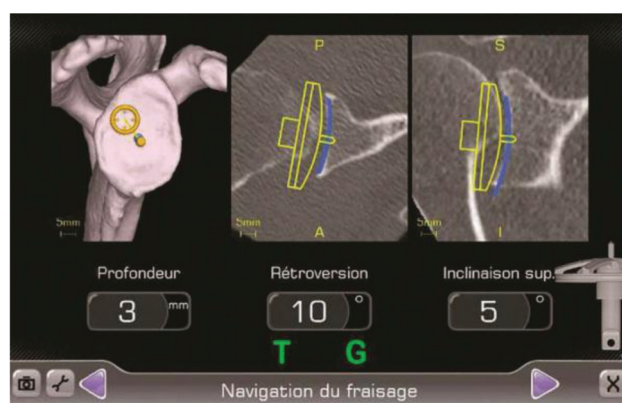


Fig. 3 Image of the GPS station during the milling process after the initial hole is performed. (Courtesy of Exactech, INC, Gainesville, FL, USA).

ment of the coracoid tracker, for soft tissue removal, and the registration typically adds ~ 6 minutes.⁵ Once the data are recorded, we confront the information with the preoperative planning. At this time, standard instrumentation with a tracker on it can be used in a navigated manner to ensure optimum angle and reaming depth according to the preset plan.

We start to operate with a sensor fixed to the coracoid process, as previously described, and another sensor coupled to a gauntlet, which connects both to the drill and to the reamer cutter used in the preparation of the glenoid (► Fig. 3).

The tip of the instrument is presented in yellow on the screen of the navigation station and must correspond to the blue dot corresponding to the preoperative planning. We have to align the instrument shaft with the target, which is centered on the yellow dot. Computed tomography scan image slices are arranged on the screen at the same time assisting in the correct location of the drill and reamer cutter. The version and tilt axes are numerically indicated with high real-time accuracy. The insertion of screws to settle the base plate of the glenosphere can also be guided by navigation, which assists in the orientation and length of the screws.

Results

Clinical studies with long-term follow-up periods comparing surgery with and without navigation assistance are necessary and should be published in the future. However, the initial results are promising.^{4,5}

In one of the first experiments with the aid of intraoperative computation, Bicknel et al,⁹ in 2007, used a computer-assisted surgical technique for the treatment of four-part fractures using hemiarthroplasty. They showed a statistically significant difference when using the computer-assisted method in determining the offset of the humeral head. The mean variation of the data obtained with the normal anatomy was 2.94 mm for the assisted surgery and 10.07 mm for the traditional technique ($p = 0.02$).⁹

Edwards et al,¹⁰ in 2008, performed an initial study on cadavers to study the retroversion, inclination, and humeral head diameter assisted by computer navigation. On the glenoid side, they recorded the tilt and version of the surface related to the native bone. This study was followed by a cohort of 27 patients treated with ATSA or RTSA according to the pathology. The navigation system presented an accuracy of 2.6°. The authors reported that the procedure is safe and provides valuable parameters for the surgeon.¹⁰

In 2009, Kircher et al¹ published the first comparative study involving ATSA. They evaluated prospectively the correction of glenoid retroversion and the positioning of the prosthesis component assisted by computer navigation. The correction was from 15.4° to 3.7° postoperatively in the assisted group. Compared with the control group without navigation, this value was from 14.4° to 10.9°; there was a statistically significant difference ($p = 0.021$). Higher accuracy was achieved to position the glenoid component using navigation. In six cases, the authors gave up the use of the computer due to technical difficulties. The authors also observed that the surgical time was significantly higher, on average 31 minutes, in the navigation group.¹

Briem et al,¹¹ in 2011, in cadavers, compared the correction of the glenoid retroversion assisted by navigation with the conventional method. They established a 10° correction of the retroversion. In the assisted group, the mean of

correction was 9.8°, while in the control group, it was 5.1° ($p < 0.05$). The authors recommend the navigation technique, but the increased surgical time and the cost are the main obstacles. The evolution of the technology is necessary for better applicability.

Also, in the same year, Verborgt et al analyzed the version and inclination of the glenoid component of the RTSA on a cadaver. They evaluated the accuracy of the glenoid component insertion guided by navigation comparing with the conventional method. The parameter of the version was a neutral position. In the first group, they obtained 3.1° of anteversion compared with 8.7° in the control group. Regarding the inclination, they established the parameter of 10° inferior tilt. The navigated group achieved 5.4°, and the control group 0.9°. Therefore, they conclude that the insertion of the glenoid component with assistance navigation has greater precision when compared with the conventional technique.¹²

Stubig et al,¹¹ in 2013, evaluated the central guide wire positioning on the glenoid to perform RTSA. The objective was to implant the wire at 12 mm to the lower limit of the glenoid, with 10° inferior inclination, and centered with the axial axis of the scapula. They obtained better accuracy to determine the axial scapular plane. The mean guide wire deviation was 1.6° in the group assisted by navigation and 11.5° in the control group with the conventional technique ($p = 0.004$). However, they did not find any difference related to the position from the inferior edge of the glenoid neither to the inferior inclination that could help to prevent scapular notching.¹³

In a systematic review, Sadoghi et al,¹⁴ in 2015, found a significant improvement in the accuracy of the glenoid version evaluation, but the clinical results are questionable when compared with conventional methods.

Venne et al,¹⁵ in 2015, analyzed the precision of the baseplate insertion and screws positioning on the RTSA comparing two groups, assisted by navigation and conventional technique. The navigation helped to measure the length of the central pin of the baseplate, and the sizes and angulation of the screws. No significant difference was observed between the entry point of both the baseplate and the screws.

Theopold et al,¹⁶ in 2016, evaluated the guidewire positioning in the glenoid. They used 34 scapulas of sheep in 2 groups, oriented by navigation and freehand technique. The wire angulation was 2.2° and 4.7°, respectively ($p = 0.01$). The authors also established a central line in the glenoid, and the angulation of the wire to this was 14.4° and 17.2°, respectively ($p = 0.02$). They concluded that the navigation provided greater accuracy in the positioning of the guidewire.¹⁶

Discussion

Shoulder arthrosis affects one in three people > 60 years old, and total shoulder arthroplasty (TSA) is frequently indicated, especially in the most severe cases.¹⁷ The current literature shows that < 3% of surgeons perform > 10 shoulder

arthroplasties annually. Also, almost 80% perform only 1 to 2 per year.^{6,18}

Preoperative planning improves the precision of the glenoid component insertion, especially with the 3D technology platforms. It minimizes the incidence of bone perforation by the implant, even without specific guides or navigation.^{6,19,20} The first hole of the glenoid is the most important step in which navigation can help the surgeon. It is considered the main moment that causes technical error in performing a TSA by the conventional method.²⁰ Moreover, the navigation in TSA is an important assistance tool for training and learning for less experienced surgeons;¹⁴ eliminating the use of guides, replaced by sensors, facilitating the surgical technique and the learning curve. A comprehensive review of the literature confirmed its superior accuracy to the conventional method regarding the positioning of the glenoid component.¹⁴

The navigation has benefits for both ATSA^{1,10,16} and RTSA,^{12,15,16,21} especially when the anatomy is distorted by fractures, revisions, wear, or dysplasia of the glenoid.^{9,10}

The contraindications to navigation are the same for shoulder arthroplasties, such as active or latent infection and generally poor health. In some patients who had a prior coracoid transfer, there is not enough coracoid remaining to fix the tracker. Besides, severe osteopenia may compromise the safety of fixation of the tracking device. Unlike hip and knee, obesity does not compromise the accuracy of registration and fixation of screening devices during TSA navigation. So, it is not considered a contraindication. A total of 13 out of the 27 patients in the series by Edwards et al had a body mass index (BMI) > 30 (3 with BMI > 40) without loss of navigation functioning, even for the largest patient, with a BMI of 64.10

The surgical time added to the procedure is important, especially at the beginning of the learning curve. According to the literature, the surgical time is increased around 6 up to 31 minutes.^{1,5,10,12} In another study, the navigated surgery was 2.2 minutes faster, but not statistically significant ($p = 0.07$).¹⁵

Barrett et al described 2 cases (5.5%) of coracoid process fracture due to the fixation of the sensor. One of them was a patient with low bone density, observed only in the postoperative period.⁵ Therefore, it is recommended to be careful in attempting to identify situations with higher risk due to the morphology of the coracoid process and bone density of the patient. Other authors reported no complications, not even related to the fixation of the sensor.^{10,12,16}

Kircher et al¹ reported no complications, but the navigation was aborted in 6 cases (37.5%) due to technical difficulties related to the method.

Barrett et al⁵ also described that the navigation was interrupted due to a technical failure in 1 case out of 36 patients (2.7%). Therefore, navigation is not considered a standard procedure.

The cost of surgery is another important factor. The technique involves a significant initial investment in technology. Increased surgical time also provides an additional cost.⁵ However, the greater accuracy in the positioning of the prosthesis components will decrease the complication rates,

theoretically. In RTSA, scapular notching, early loosening, and complications resulting from the length and angulation of the screw can be prevented. It may damage the suprascapular nerve or even cause a fracture of the base of the scapular spine. In ATSA, avoiding the malpositioning of the glenoid component prevents early loosening and increases the survival rate. Consequently, it decreases the cost of revisions in general.⁵

Long-term prospective comparative clinical studies are needed in the future to determine the functional outcome and the cost-benefit of computer-assisted technology in TSA.⁴

Final Considerations

The indication of ATSA and RTSA has increased. The development of navigation in shoulder surgery promises better results with expected increased survival rate, especially in the most severe cases involving a significant deformity of the glenoid.

Financial Support

There was no financial support from public, commercial, or non-profit sources.

Conflict of Interests

Dr. Thomas W. Wright is a consultant of Exactech Inc. The other authors have not received any financial payments or other benefits from any commercial entity related to the subject of the present article.

References

- Kircher J, Wiedemann M, Magosch P, Lichtenberg S, Habermeyer P. Improved accuracy of glenoid positioning in total shoulder arthroplasty with intraoperative navigation: a prospective-randomized clinical study. *J Shoulder Elbow Surg* 2009;18(04):515-520
- Walch G, Badet R, Boulahia A, Khoury A. Morphologic study of the glenoid in primary glenohumeral osteoarthritis. *J Arthroplasty* 1999;14(06):756-760
- Nyffeler RW, Sheikh R, Atkinson TS, Jacob HA, Favre P, Gerber C. Effects of glenoid component version on humeral head displacement and joint reaction forces: an experimental study. *J Shoulder Elbow Surg* 2006;15(05):625-629
- Verborgt O, Vanhees M, Heylen S, Hardy P, Declercq G, Bicknell R. Computer navigation and patient-specific instrumentation in shoulder arthroplasty. *Sports Med Arthrosc Rev* 2014;22(04):e42-e49
- Barrett I, Ramakrishnan A, Cheung E. Safety and Efficacy of Intraoperative Computer-Navigated Versus Non-Navigated Shoulder Arthroplasty at a Tertiary Referral. *Orthop Clin North Am* 2019;50(01):95-101
- Iannotti JP, Greeson C, Downing D, Sabesan V, Bryan JA. Effect of glenoid deformity on glenoid component placement in primary shoulder arthroplasty. *J Shoulder Elbow Surg* 2012;21(01):48-55
- Walch G, Vezeridis PS, Boileau P, Deransart P, Chaoui J. Three-dimensional planning and use of patient-specific guides improve glenoid component position: an in vitro study. *J Shoulder Elbow Surg* 2015;24(02):302-309
- Iannotti J, Baker J, Rodriguez E, et al. Three-dimensional preoperative planning software and a novel information transfer technology improve glenoid component positioning. *J Bone Joint Surg Am* 2014;96(09):e71

- 9 Bicknell RT, DeLude JA, Kedgley AE, et al. Early experience with computer-assisted shoulder hemiarthroplasty for fractures of the proximal humerus: development of a novel technique and an in vitro comparison with traditional methods. *J Shoulder Elbow Surg* 2007;16(3, Suppl):S117–S125
- 10 Edwards TB, Gartsman GM, O'Connor DP, Sarin VK. Safety and utility of computer-aided shoulder arthroplasty. *J Shoulder Elbow Surg* 2008;17(03):503–508
- 11 Briem D, Ruecker AH, Neumann J, et al. 3D fluoroscopic navigated reaming of the glenoid for total shoulder arthroplasty (TSA). *Comput Aided Surg* 2011;16(02):93–99
- 12 Verborgt O, De Smedt T, Vanhees M, Clockaerts S, Parizel PM, Van Glabbeek F. Accuracy of placement of the glenoid component in reversed shoulder arthroplasty with and without navigation. *J Shoulder Elbow Surg* 2011;20(01):21–26
- 13 Stübig T, Petri M, Zeckey C, et al. 3D navigated implantation of the glenoid component in reversed shoulder arthroplasty. Feasibility and results in an anatomic study. *Int J Med Robot* 2013;9(04):480–485
- 14 Sadoghi P, Vavken J, Leithner A, Vavken P. Benefit of intraoperative navigation on glenoid component positioning during total shoulder arthroplasty. *Arch Orthop Trauma Surg* 2015;135(01):41–47
- 15 Venne G, Rasquinha BJ, Pichora D, Ellis RE, Bicknell R. Comparing conventional and computer-assisted surgery baseplate and screw placement in reverse shoulder arthroplasty. *J Shoulder Elbow Surg* 2015;24(07):1112–1119
- 16 Theopold J, Pieroh P, Schrage ML, et al. Improved accuracy of K-wire positioning into the glenoid vault by intraoperative 3D image intensifier-based navigation for the glenoid component in shoulder arthroplasty. *Orthop Traumatol Surg Res* 2016;102(05):575–581
- 17 Menge TJ, Boykin RE, Byram IR, Bushnell BD. A comprehensive approach to glenohumeral arthritis. *South Med J* 2014;107(09):567–573
- 18 Sabesan VJ, Callanan M, Youderian A, Iannotti JP. 3D CT assessment of the relationship between humeral head alignment and glenoid retroversion in glenohumeral osteoarthritis. *J Bone Joint Surg Am* 2014;96(08):e64
- 19 Berhouet J, Gulotta LV, Dines DM, et al. Preoperative planning for accurate glenoid component positioning in reverse shoulder arthroplasty. *Orthop Traumatol Surg Res* 2017;103(03):407–413
- 20 Werner BS, Hudek R, Burkhart KJ, Gohlke F. The influence of three-dimensional planning on decision-making in total shoulder arthroplasty. *J Shoulder Elbow Surg* 2017;26(08):1477–1483
- 21 Nguyen D, Ferreira LM, Brownhill JR, et al. Improved accuracy of computer assisted glenoid implantation in total shoulder arthroplasty: an in-vitro randomized controlled trial. *J Shoulder Elbow Surg* 2009;18(06):907–914