

Intermaxillary fixation screws versus Erich arch bars in mandibular fractures: A comparative study and review of literature

Access this article online

Website:
www.amsjournal.com

DOI:
10.4103/2231-0746.186129

Quick Response Code:



Ahtesham Ahmad Qureshi, Umesh K. Reddy¹, Warad N. M.², Sheeraz Badal, Amjad Ali Jamadar³, Nilofar Qurishi

Department of Oral and Maxillofacial Surgery, MIDSr Dental College, ³Department of Orthopedics, MIMSr Medical College, Latur, Maharashtra, ¹Department of Oral and Maxillofacial Surgery, Oxford Dental College, Bengaluru, ²Department of Oral and Maxillofacial Surgery, Al-Ameen Dental College, Bijapur, Karnataka, India

Address for correspondence:

Dr. Ahtesham Ahmad Qureshi, Department of Oral and Maxillofacial Surgery, MIDSr Dental College, Latur, Maharashtra, India.
E-mail: drahtesham007@yahoo.co.in

ABSTRACT

Objective: Various techniques have been employed from time to time to achieve maxillomandibular fixation. Although arch bars provide an effective and versatile means of maxillomandibular fixation, their use is not without shortcomings. However the introduction of intermaxillary fixation screws (IMF) has eliminated many of these issues of arch bars. The aim of the present study was to compare the advantages and disadvantages of intermaxillary fixation screws over the Erich arch bars in mandibular fractures.

Materials and Methods: Sixty dentulous patients who reported to Department of Oral and Maxillofacial Surgery, Al-Ameen Dental College and Hospital, Bijapur with mandibular fractures and required intermaxillary fixation as a part of treatment plan followed by open reduction and internal fixation under GA were selected and randomly divided into 2 groups of 30 patients each that is Group A and Group B. Group A included patients who received intermaxillary fixation with Erich arch bars. Group B includes patients who received intermaxillary fixation with IMF Screws. The parameters compared in both the groups included, surgical time taken, gloves perforation, post-operative occlusion, IMF stability, oral hygiene, patient acceptance and comfort and non-vitality characteristics. **Results:** The average surgical time taken and gloves perforations were more in Group A, the patient acceptance and oral hygiene was better in Group B, there was not much statistically significant difference in postoperative occlusion and IMF stability in both groups. Accidental root perforation was the only limitation of IMF screws. **Conclusion:** Intermaxillary fixation with IMF screws is more efficacious compared to Erich arch bars in the treatment of mandibular fractures.

Keywords: Erich arch bars, intermaxillary fixation screws, mandibular fractures

INTRODUCTION

The principles of treatment for mandibular fractures have changed recently although the objective of reestablishing the occlusion and masticatory function remains the same. Even though the rigid internal fixation has become the standard method in reduction and fixation of simple and complex facial fractures,^[1,2] intraoperative temporary intermaxillary fixation (IMF) or postoperative wire or elastic placement has traditionally been achieved with the use of Erich arch

This is an open access article distributed under the terms of the Creative Commons Attribution-NonCommercial-ShareAlike 3.0 License, which allows others to remix, tweak, and build upon the work non-commercially, as long as the author is credited and the new creations are licensed under the identical terms.

For reprints contact: reprints@medknow.com

Cite this article as: Qureshi AA, Reddy UK, Warad NM, Badal S, Jamadar AA, Qurishi N. Intermaxillary fixation screws versus Erich arch bars in mandibular fractures: A comparative study and review of literature. Ann Maxillofac Surg 2016;6:25-30.

bars, interdental eyelet wiring, external pin fixation, bonded brackets, embrasure wires, cast metal splints, and pearl steel wires. Although arch bars provide an effective and versatile means of maxillomandibular fixation, their use is not without consequence. Risk of penetrating injury to surgeon, increased surgical time both in removal and placement, trauma to periodontium, and compromised oral hygiene are all shortcomings of traditional arch bars.^[3,4]

In 1989, however, the self-drilling IMF screws were introduced, which have eliminated many of the above mentioned issues of arch bars.^[2] Self-drilling IMF screws are quick and easy to use and greatly shorten the operating time to achieve maxillomandibular fixation. They are relatively inexpensive and reduce the risk of needle stick type injuries associated with wires. They do not cause trauma to the gingival margins and gingival health is easier to maintain as compared with arch bars.^[1]

In our study, a comparison was made regarding the advantages and disadvantages of IMF screws over arch bars and also to record the incidence of complications with both techniques.

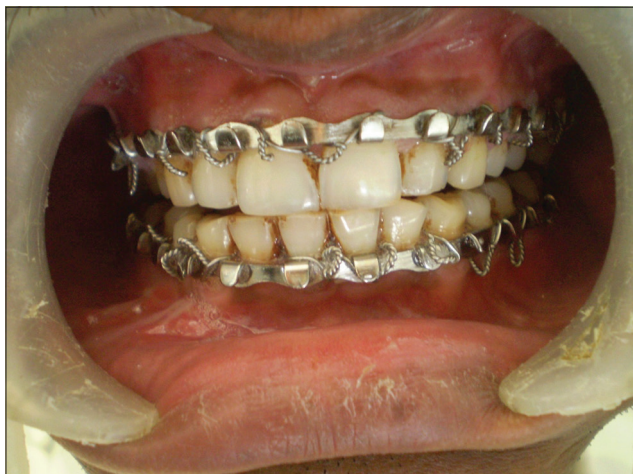

Figure 1: Arch bar fixation done

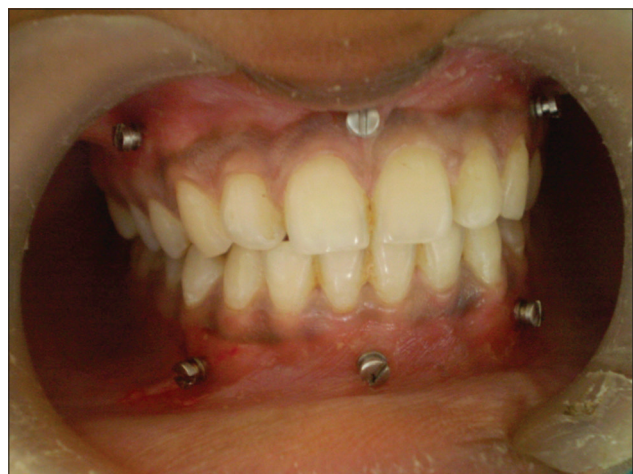

Figure 3: Intermaxillary fixation screws in position

MATERIALS AND METHODS

In this study, 60 dentulous patients who reported to the Department of Oral and Maxillofacial Surgery, Al-Ameen Dental College and Hospital, Bijapur, with mandibular fractures and required IMF followed by open reduction and internal fixation under general anesthesia as a part of treatment plan were selected.

The patients between the age group of 16–60 years with single unilateral mandibular parasymphyseal fracture were included in this study. Edentulous patients, patients with underlying systemic disease (American Society of Anesthesiologists III and IV), pathologic fractures, comminuted fracture of mandible, patients with multiple fractures (parasymphyseal with angle, associated condylar fractures, and maxillary fractures), comorbidities such as fractures in other bones of body (pelvic bone fractures, femur fractures, etc.), and patients having primary and mixed dentition were excluded from the study.

The selection of the patients was done by simple randomized enveloped method and designated as Group A and Group B. In this, the first patient of the study was selected by a draw and allotted Group A, after this all subsequent patients were divided alternately into Group A and Group B randomly without taking into consideration any parameter other than the inclusion criteria. Group A patients received IMF with Erich arch bars and Group B patients received IMF with IMF screws.

The method used for the placement of Erich arch bar is as follows.

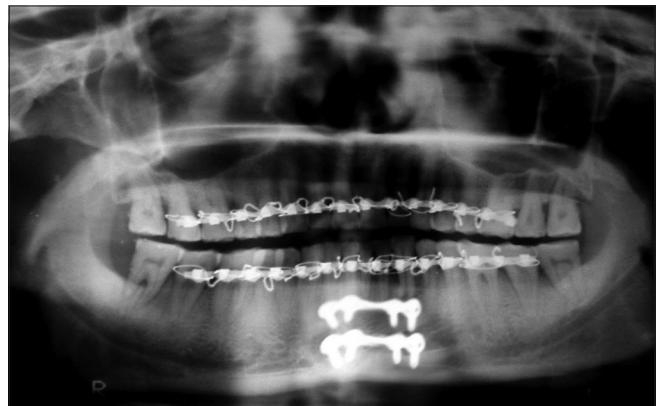

Figure 2: Open reduction and fixation done after arch bar fixation

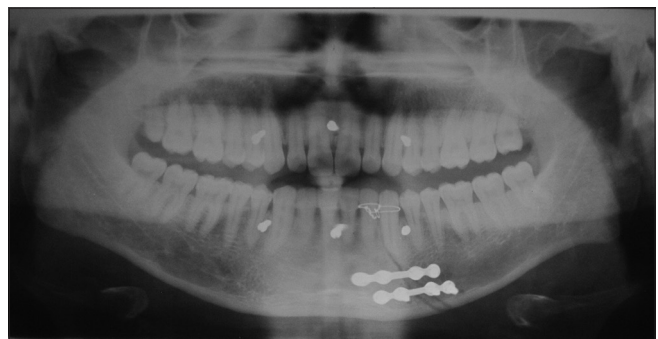


Figure 4: Open reduction and internal fixation done after placement of intermaxillary fixation screws

After appropriate anesthesia, a prefabricated arch bar with hooks incorporated on the outer surface with flat malleable stainless steel metal strip was cut accurately to the length of both upper and lower dental arches. On the upper jaw, the hooks were arranged in an upward direction and to the lower jaw in a downward direction. The arch bar was adapted to the buccal surface of each arch and given shape of the arch by bending it, starting from the mesial part of last tooth progressing past the midline and finishing at the other end. It was fixed to each tooth, using prestretched 26-gauge stainless steel wire, which is passed from mesial surface of tooth to the lingual side and back on the buccal side from the distal surface of the tooth, making sure that one end of the wire is passing above the arch bar and the other below it. After this, both ends of the wire were twisted together in a clockwise manner and the arch bar was attached securely and firmly to the necks of each tooth on the buccal surface of the arch. Open reduction and internal fixation were then carried out using conventional miniplate/screw system with a single design and configuration, i.e., 2 mm thickness, 4-hole plate with gap in all cases based on Champy's lines of osteosynthesis. Arch bar was left in place for 4–6 weeks to enable the postoperative traction to correct the small discrepancies in occlusion [Figures 1 and 2].

In Group B patients, IMF was achieved by the use of six stainless steel IMF screws of 2 mm diameter and 8 mm or 10 mm length. After appropriate anesthesia, holes are drilled through mucosa with 1.5 mm or 1.7 mm drill bits, without any gingival incision preferably between the canine and first premolar teeth in each quadrant, and the third pair of IMF screws was inserted in the same way in the upper and lower dental midlines. After this, IMF screws were inserted through the predrilled holes, taking care not to penetrate the lingual or palatal mucosa. IMF was achieved using wires or elastic bands. Open reduction and internal fixation were then carried out using conventional miniplate/screw system with a single design and configuration, i.e., 2 mm thickness, 4-hole plate with gap in all cases based on Champy's lines of osteosynthesis [Figures 3 and 4]. Screws were left in place for 4–6 weeks. The placement of the screws was evaluated immediately postinsertion, using a panoramic radiograph or intraoral periapical radiographs, and a second radiograph was taken after screw removal. A clinical follow-up of 1 month following removal of IMF screws and Erich arch bar was included. During the whole study, only one operating surgeon was involved although the assistants varied. The following parameters were recorded, tabulated, and subjected to statistical analysis.

Surgical time taken in minutes from start of procedure till IMF was achieved. Needle stick injury and incidence of perforations in the gloves of surgeon and first assistant were identified by water inflation method. Vitality of teeth was checked using electronic pulp tester preoperatively and postoperatively at the time of splint removal. Oral hygiene index simplified given by Greene and Vermillion was used to evaluate the oral hygiene status of the patient at the time of 1st and 6th weeks. It was recorded as good and poor. The degree of patient comfort and acceptance were judged by hardware tolerability (pain due to impingement of hardware on soft tissues) and graded as good, fair, and poor. Postoperative occlusion and IMF stability were recorded as satisfactory or unsatisfactory based on Angles classification. In both groups, gender distribution and mechanism of injury were also recorded.

In Group B patients, parameters such as loss of screw, screw breakage, screw covered by mucosa, and iatrogenic damage to dental roots (checked radiographically) were also recorded.

The statistical analysis of follow-up was performed using *t*-test, Fisher's exact test, and Chi-square test with the help of MS Excel/Word R-3.2.3 Version software. $P < 0.05$ was considered statistically significant [Table 1].

RESULTS

In Group A, mean age of patients was 37.53 years in comparison to 37.96 years in Group B, indicating no significant difference in the age of two groups ($P = 0.8827$). In Group A, of the thirty patients treated, 21 (70%) were males and 9 (30%) were females; in Group B, 23 (76%) patients were male and 7 (24%) were females ($P = 0.771$).

In Group A, in 18 (60%) patients, the mechanism of injury was road traffic accidents in 6 (20%) assault and in the remaining 6 (20%) patients, injury was due to miscellaneous reasons which included falls or occupational injuries. In Group B, the etiology was road traffic accidents in 20 (67%), assaults in 6 (20%), and miscellaneous in 4 (13%) patients ($P = 0.776$).

The average surgical time taken was 94.67 min for the Group A and 15.56 min for Group B ($P = 0.0021$). The perforation in the gloves was found more in Group A 20 cases and only 2 cases in Group B, ($P = 0.0017$). The patient acceptance and comfort were found good in Group B 21 cases compared to only 5 cases in Group A ($P = 0.0001607$).

Postoperative nonvitality characteristics were more significant in Group B (6 teeth) compared to only 2 teeth in Group A ($P = 0.0420$). The IMF stability was found satisfactory in 22 patients of Group A when compared to 24 patients of Group B ($P = 0.7611$). There was not much difference in the postoperative occlusion status of both groups ($P = 0.748$). Oral hygiene status was significantly more good in Group B 27 cases in comparison to 7 cases in Group A ($P = 0.0029$) [Table 2].

In this study, the effect of body mass index (BMI) on the surgical outcome of surgery was not considered because most of the studies that were published at the time of this study had concluded that BMI that is overweight or underweight status of patient has no significant role on the outcome of surgery regarding time taken, postoperative complications, stay in hospital, overall cost, etc.

In Group B, loss of screw was recorded in 3 cases, iatrogenic damage to dental roots was seen in 6 cases, and screw was covered by mucosa in 4 cases.

DISCUSSION

Any discussion on management of mandibular fractures opens with history, evolution of treatment, and dates back to Edwin Smith, an ancient Greek, who provided a clear cut documentation for the treatment of mandibular fractures dating back as early as 17th century. Between 25 BC and 11th century AD, surgeons and writers such as Sushruta (India), Celsus (Rome),

Table 1: Statistical analysis

Parameter evaluated	Test used	t	95% CI	P	OR	df	Mean/SD
Patient comfort/acceptance	Chi-square test	NA	NA	0.0001607	0.632	2	NA
Postoperative occlusion	Fisher's exact test	NA	LL: 0.3546 UL: 6.9507	0.748	1.511118	NA	NA
Surgical time taken in min	Simple t-test	32.877	LL: 74.1867 UL: 84.0132	0.0021 (<i>P</i> <2.2e-16)	NA	30.047	Group A=94.66667 Group B=15.56667
Gloves perforation	Fisher's exact test	NA	LL: 0.0037 UL: 0.1999	0.0017 (<i>P</i> <1.908e-06)	26.118	NA	NA
Oral hygiene	Fisher's exact test	NA	LL: 5.9493 UL: 183.390	0.0029	27.23	NA	NA
IMF stability	Fisher's exact test	NA	LL: 0.1684 UL: 2.6952	0.7611	0.6918	NA	NA
Mechanism of injury	Chi-square test	NA	LL: 0.1684 UL: 2.6952	0.7768	0.6918	2	NA

P<0.05 considered significant finding. LL=Lower limit; UL=Upper limit; CI=Confidence interval; NA=Not applicable; df=Degree of freedom; IMF=Intermaxillary fixation; Group A=Patients treated with arch bars; Group B=Patients treated with IMF screw; SD=Standard deviation; OR=Odds ratio

Table 2: Comparison of intra- and post-operative parameters

Parameter evaluated	Erich's arch bar	IMF screws	P
Patient acceptance			
Good	5	-21	0.0001607
Fair	15	6	
Poor	10	3	
Postoperative occlusion			
Satisfactory	23	25	0.748
Nonsatisfactory	7	5	
Surgical time taken in min			
Range	70-120	12-20	0.0021
Gloves perforation			
Present	20	2	0.0017
Absent	10	28	
Oral hygiene			
Good	7	27	0.0029
Poor	23	3	
Stability of IMF			
Adequate	22	24	0.7611
Inadequate	8	6	

P<0.05 considered significant finding. IMF=Intermaxillary fixation

and Avicenna (Middle East) described conservative means of treating jaw fractures. Sushruta advocated the use of manual manipulation and complicated bandaging to treat mandibular fractures. Avicenna (980–1037 AD) emphasized the importance of occlusion during the treatment of these injuries. He advocated the use of supportive dressing around the jaw as well as splints along the teeth. This is the fundamental unique feature in the management of jaw fractures as compared to any other bones in the body.^[5] The introduction of bone plating system has reduced the prolonged periods of IMF or sometimes not required in a patient with the fracture of mandible. However, there is a need for temporary IMF intraoperatively to assist in reduction of fractures with the teeth in correct occlusion and postoperatively to assist in fixation or to correct minor occlusal discrepancies.^[2]

The arch bar has been the mainstay for the management of maxillomandibular bony injuries since the World War I although other methods such as interdental eyelet wiring, external pin fixation, bonded brackets, cast metal splints, embrasure wires, and pearl steel wires are also reported.^[3] The originators of arch bar technique, Sauer in Germany, and Gilmer in the US used an ordinary round bar flattened on one side that was ligated to the teeth with brass ligature wires. Blair and Ivy's modification

was a flattened on one side that was about 2 mm in width to conform better to the teeth and provide greater stability.^[6] Although arch bars provide an effective and versatile means of maxillomandibular fixation, their use is not without consequence. Risk of penetrating injury to surgeon, increased surgical time both in removal and placement, trauma to periodontium, and compromised oral hygiene are all shortcomings of traditional arch bars.^[3,4] The other disadvantages of using arch bar include movement of teeth in lateral and extrusive direction, constant traction applied to the wire can distract the fracture parts and possibly cause additional complications, difficulty to secure arch bar in isolated posterior teeth, and it is not suitable for dentition that carry extensive crown and bridge work.^[1,2,6]

To overcome the drawbacks of arch bars, the self-tapping intermaxillary screws were first introduced by Arthur and Berardo in 1989.^[7] They used self-tapping bone screws of 2 mm diameter. The maxillary screws were placed in the pyriform rim and zygomatic buttress areas. The mandibular screws were placed between the root apices and mental foramen. The advantages of this technique were the use of minimal amount of hardware, decreased operation time, and no risk of needle stick injuries.^[7]

Jones used threaded titanium screws of 2 mm diameter and 10 or 16 mm length with a Capstan head. According to him, screws with Capstan style head are important as it allows the wires and elastics to be held away from the gingival tissue. These screws are quick to insert, have fewer risks of needle stick injury, and reduced operating time; this type of screw is suitable for dentition that carry out extensive crown and bridge work. He recommended the use of these screws for temporary intraoperative IMF and postoperative elastic traction.^[2] In the present study, stainless steel intermaxillary screws of 2 mm diameter and 10 mm length were used. They were inserted at the junction of free and attached gingiva between the roots of canine and first premolar and one more pair were used in the midline between central incisors. The same technique was reported by Arthur and Berardo and Jones.^[2,7] In this study, the maximum time taken for arch bar fixation was 120 min and in case of IMF screws only 20 min. The results were in consistent with the data from previous studies conducted by Arthur and Berardo, Jones, Fabbroni et al., Rocchia et al., and Coletti et al.^[1,4,8] The incidence of needle stick injuries

and perforation of gloves and subsequently the risk of transmission of blood-borne diseases such as hepatitis and acquired immuno deficiency syndrome are much higher in cases of arch bar fixation as compared to IMF screws.^[2,7-9] In our study, glove perforation was found in 20 cases where arch bars were used compared to only 2 cases where IMF screws were used. The patient comfort and acceptance were significantly high in patients with IMF screws good in 21 patients compared to only 5 patients where arch bar was used. It was found that compared to IMF screws, there is more trauma to the periodontium, difficulty in wire placement and removal, more chances of induced ulceration due to soft tissue injuries, and difficulty in mastication with the use of arch bars.^[4]

In the present study, the postoperative nonvitality characteristics were found more in patients with IMF screws than arch bars due to improper angulations of drill bit during drilling of hole for insertion of IMF screw resulting in root impingement. Similar findings were reported by Coletti *et al.*, Roccia *et al.*, and Borah and Ashmead in their respective studies.^[1,8,10] Oral hygiene of all the patients was good, and in fact, it had improved postoperatively after meticulous oral hygiene instructions with IMF screws, but it was very poor in patients with Erich arch bars. In the present study, only in 3 cases where IMF screws were used, the oral hygiene was poor; in one case, it was due to the presence of ulcers in mouth; and in two patients, it was attributed to patient's negligence. Similar results were reported by Fabbroni *et al.* and Roccia *et al.*^[4,8]

The postoperative occlusion was satisfactory in 23 patients with arch bars and 25 patients with IMF screws. However, in 7 cases of arch bars and 5 cases of IMF screws, the occlusion was nonsatisfactory, which was attributed to the inadequate reduction of fractures. Our findings were in accordance with those reported by Roccia *et al.* and Gordon *et al.*^[8,9] IMF stability was found equally adequate with both groups. However, in 8 cases of arch bars and 6 cases of IMF screws, IMF stability was found inadequate which was attributed to the improper tightening of wires making the arch bars loose, and in case of patients treated with IMF screws, it was due to loss of screw or loosening of screw.

Coburn *et al.* reported a case of fracture of screw at the junction of screw head and threaded portion. They recommended a careful drilling of bur hole, with slow bur speed and copious irrigation with sterile saline and screw should be inserted at an even speed and not be forced if resistance is encountered.^[11] A similar complication was also reported by Holmes and Hutchison; they advocated caution with use of bicortical screws and suggested the technique of two forward turns followed by one backward turn to exclude the shaft from the pitch of the screw during insertion and removal.^[12] In the present study, no such case of screw fracture was encountered.

In the present study, the loosening of screw was recorded in 3 cases, which was found to be due to either improper tightening of IMF screw or screw placed in fracture line. In both situations, screws had come out before healing period. Similar complication was reported by Coletti *et al.* and Roccia *et al.*^[1,8] Swallowing of IMF screws was reported by Coletti *et al.* due to loosening of screw although no such complication was encountered in our study. In the present study, in 4 cases, the IMF screw was covered by mucosa. In such cases, a stab incision was given and screw

was exposed and removed. Similar complication was reported by Roccia *et al.* and Gordon *et al.*^[8,9] Iatrogenic injury to dental roots was recorded in 6 patients, which was due to improper angulations of drill bit and overcrowding of teeth in area of screw insertion and the presence of ankylosed teeth. All such teeth were treated by endodontic treatment. Similar complication was reported by Coletti *et al.* and Roccia *et al.*^[1,8]

The results achieved with the present study indicate that IMF screw technique is a good alternative to Erich arch bars for temporary IMF in mandibular fractures. It is a safe and time sparing technique; however, it is not without limitations or potential consequences which the surgeon must be aware of to provide safe and effective treatment.

CONCLUSION

IMF with IMF screws is more efficacious compared to conventional Erich arch bars in the treatment of mandibular fractures. Although both techniques offer good temporary fixation intraoperatively to check occlusion and postoperatively for IMF, the IMF screws reduce the operating time and the risk of needle stick injuries to the surgeon and subsequently the transmission of diseases. They are associated with good maintenance of oral hygiene, less trauma to the periodontium, and good patient acceptance compared to arch bars.

Considering the results, we conclude that IMF screws provide an effective alternative to traditional arch bar technique for the treatment of uncomplicated mandibular fractures. However, IMF screws are not indicated where the function of tension band and postoperative directional traction are required as in multiple comminuted mandibular fractures, pediatric patients with unerupted teeth, and patients with severe osteoporosis. These findings need to be carefully interpreted due to small sample size and it needs further research to be carried out on a large sample size along with specificity of technique to extend their use in management of mandibular fractures.

Acknowledgment

We would like to show our gratitude toward all the patients who were a part of this study for being cooperative and supporting throughout the research. We are highly grateful to Dr. N. P. Jamadar, Prof and Head, Department of Anaesthesia, MIMSR Medical College, Latur, for his valuable advices during the study. Moreover, finally, we would like to show our sincere gratitude to all those who directly and indirectly became a part of our study.

Financial support and sponsorship

Nil.

Conflicts of interest

There are no conflicts of interest.

REFERENCES

1. Coletti DP, Salama A, Caccamese JF Jr. Application of intermaxillary fixation screws in maxillofacial trauma. *J Oral Maxillofac Surg* 2007;65:1746-50.

2. Jones DC. The intermaxillary screw: A dedicated bicortical bone screw for temporary intermaxillary fixation. *Br J Oral Maxillofac Surg* 1999;37:115-6.
3. Aldegheri A, Blanc JL. The pearl steel wire: A simplified appliance for maxillomandibular fixation. *Br J Oral Maxillofac Surg* 1999;37:117-8.
4. Fabbroni G, Aabed S, Mizen K, Starr DG. Transalveolar screws and the incidence of dental damage: A prospective study. *Int J Oral Maxillofac Surg* 2004;33:442-6.
5. Mukerji R, Mukerji G, McGurk M. Mandibular fractures: Historical perspective. *Br J Oral Maxillofac Surg* 2006;44:222-8.
6. Baurmash H, Farr D, Baurmash M. Direct bonding of arch bars in the management of maxillomandibular injuries. *J Oral Maxillofac Surg* 1988;46:813-5.
7. Arthur G, Berardo N. A simplified technique of maxillomandibular fixation. *J Oral Maxillofac Surg* 1989;47:1234.
8. Roccia F, Tavolaccini A, Dell'Acqua A, Fasolis M. An audit of mandibular fractures treated by intermaxillary fixation using intraoral cortical bone screws. *J Craniomaxillofac Surg* 2005;33:251-4.
9. Gordon KF, Reed JM, Anand VK. Results of intraoral cortical bone screw fixation technique for mandibular fractures. *Otolaryngol Head Neck Surg* 1995;113:248-52.
10. Borah GL, Ashmead D. The fate of teeth transfixed by osteosynthesis screws. *Plast Reconstr Surg* 1996;97:726-9.
11. Coburn DG, Kennedy DW, Hodder SC. Complications with intermaxillary fixation screws in the management of fractured mandibles. *Br J Oral Maxillofac Surg* 2002;40:241-3.
12. Holmes S, Hutchison I. Caution in use of bicortical intermaxillary fixation screws. *Br J Oral Maxillofac Surg* 2000;38:574.

Form IV

Statement of ownership and other particulars about the publication, [Annals of Maxillofacial Surgery] as per Rule	
1. Place of publication	M/S MEDKNOW PUBLICATIONS AND MEDIA PVT. LTD) B9, KANARA BUSINESS CENTER, OFF LINK ROAD, GHATKOPAR (EAST), MUMBAI - 400075, INDIA
2. Periodicity of its publication	Semi Annually
3. Printer's name	Mr. HEMANT RAMESHCHANDRA MANJREKAR
Nationality	INDIAN
(a) Whether a citizen of India?	YES
(b) If a foreigner, the country of origin	NA
Address	B9, KANARA BUSINESS CENTER, OFF LINK ROAD, GHATKOPAR (EAST), MUMBAI - 400075, INDIA
4. Publisher's name	Mr. HEMANT RAMESHCHANDRA MANJREKAR
Nationality	INDIAN
(a) Whether a citizen of India?	YES
(b) If a foreigner, the country of origin	NA
Address	B9, KANARA BUSINESS CENTER, OFF LINK ROAD, GHATKOPAR (EAST), MUMBAI - 400075, INDIA
5. Editor's name	DR. S.M. BALAJI
Nationality	INDIAN
(a) Whether a citizen of India?	YES
(b) If a foreigner, the country of origin	NA
Address	Annals of Maxillofacial Surgery, No. 30, K.B. Dasan Road, Teynampet, Chennai - 600 018, Tamil Nadu, India
6. Names and addresses of individuals who own the newspaper and partners or shareholders holding more than one per cent of the total capital	NA
I, Mr. HEMANT RAMESHCHANDRA MANJREKAR, hereby declare that the particulars given above are true to the best of my knowledge and belief.	
HEMANT RAMESHCHANDRA MANJREKAR	
(Signature of Publisher)	
Dated: 1 July, 2016	