



Received: 2016.04.30
Accepted: 2016.06.13
Published: 2017.02.16

Authors' Contribution:

- A** Study Design
- B** Data Collection
- C** Statistical Analysis
- D** Data Interpretation
- E** Manuscript Preparation
- F** Literature Search
- G** Funds Collection

Role of MRI in Evaluation of Malignant Lesions of Tongue and Oral Cavity

Amandeep Singh^{1ABCDEF}, Chuni Lal Thukral^{1ABCDEF}, Kamlesh Gupta^{1CDEF},
Arvinder Singh Sood^{2ABCDEF}, Hanish Singla^{3ABCDEF}, Kunwarpal Singh^{3ACDE}

¹ Department of Radiodiagnosis and Imaging, Sri Guru Ramdas Institute of Medical Sciences and Research, Vallah, Amritsar, Punjab, India

² Department of Otorhinolaryngology (ENT), Sri Guru Ramdas Institute of Medical Sciences and Research, Vallah, Amritsar, Punjab, India

³ Department of Radiodiagnosis, Sri Guru Ramdas Institute of Medical Sciences and Research, Vallah, Amritsar, Punjab, India

Author's address: Amandeep Singh, Department of Radiodiagnosis and Imaging, Sri Guru Ramdas Institute of Medical Sciences and Research, 469, East Mohan Nagar, Sultanwind Road, Amritsar, Punjab 143001, India,
e-mail: dr.amancs@gmail.com

Summary

Background:

Aim of the present study was to evaluate the role of MRI in staging of malignant lesions of the oral cavity and to correlate MRI findings with clinical/surgical and anatomical-pathological findings, wherever possible.

Material/Methods:

The study included 50 patients who presented with malignant lesions of the oral cavity and were referred to radiology departments for MRI. All patients included were subjected to a detailed physical examination following which MRI was carried out on Philips Gyroscan Achieva 1.5 Tesla unit.

Results:

In the study, the highest number of patients were found to have tongue malignancy (82%) followed by buccal mucosa and gingivobuccal sulcus malignancy (18%). The highest number of patients was in the age group of 51–60 years (32%). The incidence was higher in males (96%). There was moderate agreement ($k=0.537$) for T stage between the clinical and MRI staging assessments. The agreement for N stage between clinical and MRI staging assessments was fair ($k=0.328$). The final diagnosis was made by histopathology in 22 patients. The agreement for T stage was good/substantial ($k=0.790$) and for N stage was moderate ($k=0.458$) between MRI and histopathology staging assessments.

Conclusions:

MRI provides satisfactory accuracy for preoperative estimation of tumor thickness and predicting occult cervical nodal metastasis. MRI is the preferred modality in evaluation and staging of oral cavity malignancy which helps a clinician for planning of treatment.

MeSH Keywords:

Magnetic Resonance Imaging • Mouth • Neoplasm Staging • Tongue Neoplasms

PDF file:

<http://www.polradiol.com/abstract/index/idArt/899352>

Background

Oral cavity cancers form a significant percentage of cancers in India. Tobacco chewing and alcohol are dominant causes [1]. They are classified into following subsites [2]:

1. Buccal mucosa;
2. Alveolus and gingival;
3. Hard palate;
4. Tongue and floor of the mouth.

MRI is used to assess the extent of loco-regional tumor spread, depth of invasion and extent of lymphadenopathy. The invasion of the floor of the mouth by the tumor is depicted well in the coronal plane [3–5]. Non-contrast T1W sequences demonstrate cortical erosion and marrow invasion. Contrast-enhanced T1W images help assess marrow invasion [6], perineural spread, soft tissue extent, tumor thickness and best demonstrate necrosis in nodes [7]. The T2W images are sensitive to the presence of tumor tissue,

Table 1. American Joint Committee on Cancer (AJCC) TNM staging.

Stage	Description
TX	Primary tumor cannot be assessed
T0	No evidence of primary tumor
Tis	Carcinoma <i>in situ</i>
T1	Tumor ≤2 cm in greatest dimension
T2	Tumor >2 cm but ≤4 cm in greatest dimension
T3	Tumor >4 cm in greatest dimension
T4a	Moderately advanced local disease, – invades through cortical bone, into deep (extrinsic) muscles of tongue, maxillary sinus, or skin of face
T4b	Very advanced local disease, – invades masticator space, pterygoid plates, or skull base and/or encases internal carotid artery
NX	Regional lymph nodes cannot be assessed
N0	No regional lymph node metastasis
N1	Metastasis in a single ipsilateral lymph node, ≤3 cm in greatest dimension
N2a	Metastasis in single ipsilateral lymph node, >3 cm but ≤6 cm in greatest dimension
N2b	Metastases in multiple ipsilateral lymph nodes, none >6 cm in greatest dimension
N2c	Metastases in bilateral or contralateral lymph nodes, none >6 cm in greatest dimension
N3	Metastasis in a lymph node >6 cm in greatest dimension
M0	No distant metastasis
M1	Distant metastasis

which is usually hyperintense compared with the surrounding muscles [3–5].

The staging of oral cavity squamous cell carcinoma (SCC) is currently based on American Joint Committee on Cancer (AJCC) criteria [3,8] (Table 1).

Aims and objectives

Evaluation of the role of MRI in loco-regional staging of malignant lesions of the oral cavity and to correlate the MRI findings with clinical/surgical findings and anatomical-pathological findings, wherever possible.

Material and Methods

This was a prospective study comprising fifty patients of all age groups with malignant lesions involving the oral cavity. An initial Informed consent was taken. The following patients were excluded from the study:

1. Those with any contraindication to undergo MRI;
2. Those having any previous history of surgical treatment of the oral cavity.

The clinical history and detailed local examination of all the patients was recorded. Examination of the mucosa of the cheek, vestibule of the mouth, gums in both upper and lower jaws, hard and soft palate, floor of the mouth, retro-molar trigone, tonsils and pillars was done to look for any

ulcer, mass and bulge. Examination of the tip, dorsum, lateral borders and undersurface of the tongue was done to look for any ulcers, white patch and proliferative growth. Movements of the tongue were looked for, with the base of the tongue and vallecula being examined by indirect laryngoscopy and finger palpation. Tumor data, including site, subsite and extent (infiltration of the surrounding structures) were collected to carry out clinical TNM staging. (AJCC Staging system – Table 1).

After clinical staging was made, MRI was conducted in each patient included in the study. Afterwards surgery and histopathological staging were performed, wherever possible.

MR technique

MR scan was carried out on Philips Gyroscan Achieva 1.5 Tesla unit.

MR imaging protocol

T1W images were acquired in all planes (axial, sagittal and coronal). The T2W images and diffusion weighted images were acquired in the axial plane. STIR images were acquired in the coronal and sagittal planes. The intravenous contrast used was Gadopentate dimeglumine (0.1 mmol/kg) (Table 2).

Table 2. Pre- and postcontrast.

SEQ	FOV	RFV	MATRIX	THK (MM)	GAP (MM)	NSA	TR	TE
Pre contrast								
STIR (COR)	250	75	272/512	3.0	1.3	3	4340	14
T1W COR	250	75	352/512	3.0	1.3	4	460	12
T2W FSTRA	250	80	352/512	4.0	0.4	3	2548	80
STIR SAG	250	75	272/512	3.0	1.3	3	4341	14
T1W FSTRA	250	80	352/512	4.0	0.4	4	664	12
T1 axial	250	80	352/512	4.0	0.4	4	460	12
Diffusion axial	230	80	112/80	5.0	0.5	4	460	12
Post contrast								
T1W FS	250	80	352/512	4.0	0.4	4	664	12
T1W COR	250	80	352/512	3.0	1.3	3	460	12

Table 3. Incidence of individual cancer.

Site	Number of patients	Percentage
Tongue	41	82%
Buccal mucosa and alveolar	9	18%
Hard palate	0	0%
Total	50	100%

Table 3 shows that maximum number of patients were of tongue malignancy followed by buccal mucosa and alveolar malignancy.

Table 4. Age incidence.

Age group in years	No. of patients	Percentage
≤20	0	0%
21–30	2	4%
31–40	11	22%
41–50	13	26%
51–60	16	32%
>60	8	16%
Total	50	100%

Table 4 shows that maximum number of patients were in the age group of 51–60 followed by the age group of 41–50 years.

Results

A total of fifty patients were included in the study. After an initial thorough clinical examination, Magnetic Resonance Imaging was done. Data were analyzed using the Statistical Package for the Social Sciences – version 18. The observations found clinically, on histopathology examination

Table 5. Sex incidence.

Sex	Number of patients	Percentage
Male	48	96%
Female	2	4%
Total	50	100%

Table 5 shows that incidence of the oral cancers is higher in males than females. Males were predominant in this study with 96% of the total patients were males and 4% were females. Male to female ratio is 24: 1.

and on MR imaging were correlated using Pearson's chi-squared test and kappa index. The observations are as follows:

The present study comprised of all oral cavity cancers of squamous cell type. The highest number of patients were found to have tongue malignancy constituting about 82% of the patients followed by gingival and buccal mucosa malignancy which constitutes about 18% of the total number of patients (Table 3). 32% of the patients belonged to age group of 51–60 years, which was the maximum followed by the age group of 41–50 years comprising of 26% of the patients (Table 4). The incidence of the oral cancers is higher in males constituting 96% of total patients (Table 5). There was moderate agreement ($k=0.537$) for the T stage between the clinical and MRI staging assessments as shown in Table 6. N stage agreement between MRI and clinical staging assessments was fair ($k=0.328$) as shown in Table 7. In 22 patients, the confirmatory diagnosis was made by surgery/histopathology. Good/substantial ($k=0.790$) agreement for the T stage was seen between MRI and histopathology staging assessments as depicted in Table 8. The agreement for the N stage was moderate ($k=0.458$) between MRI and histopathology staging assessments (Table 9). The agreement for the T stage was poor ($k=0.085$) between the clinical and histopathology staging

Table 6. Correlation between clinical tumour (T) staging and MRI tumour (T) staging.

Clinical 'T' staging	MRI 'T' staging				Total
	T1	T2	T3	T4	
T1	2	0	0	0	2
T2	0	12	1	0	13
T3	0	5	11	3	19
T4	0	1	6	9	16
Total	2	18	18	12	50

Table 6 correlates the MRI and clinical tumour (T) staging. By applying the chi square test and kappa statistics, p value and k value comes out to be 0.01 and 0.537 respectively showing moderate agreement between the clinical and MRI staging assessments.

Table 7. Correlation between clinical nodal (N) staging and MRI nodal (N) staging.

Clinical 'N' staging	MRI 'N' staging			Total
	N0	N1	N2	
N0	7	4	8	19
N1	1	9	11	21
N2	0	0	10	10
Total	8	13	29	50

Table 7 correlates the MRI and clinical nodal (N) staging. By applying the chi square test and kappa statistics, p and k value comes out to be 0.02 and 0.328 respectively which shows fair agreement between the clinical and MRI staging assessments.

Table 8. Correlation between MRI tumour (T) staging and histopathological tumour (T) staging.

MRI 'T' staging	Histopathological 'T' staging				Total
	T1	T2	T3	T4	
T1	1	0	0	0	1
T2	0	9	0	0	9
T3	0	2	6	0	8
T4	0	1	0	3	4
Total	1	12	6	3	22

Table 8 correlates the MRI and histopathological tumour (T) staging. By applying the chi square test and kappa statistics, p and k value comes out to be 0.01 and 0.790 respectively which shows good/substantial agreement between the clinical and MRI staging assessments.

assessments (Table 10). Table 11 shows that the agreement for the N stage was poor ($k=0.185$) between the clinical and histopathology staging assessments.

Discussion

Oral cavity cancers include buccal mucosa, alveolus and gingival, hard palate and tongue and floor of the mouth cancers. Tumor Node Metastasis (TNM) classification is currently the most commonly used system for describing malignant tumors and their extent of spread (both regional and distant). This staging system is the guide for every radiologist for assessment of oral carcinomas as well as for reporting relevant studies.

MRI is a very useful tool for providing the details of structures within the oral cavity and also of the adjacent structures. Excellent soft-tissue discrimination of MRI readily reveals tumor invasion and spread to surrounding structures (Figure 1). MRI is used to assess the extent of local and regional tumor spread, the depth of invasion, and the extent of lymphadenopathy (Figure 2). The major advantage of MRI over computed tomography (CT) is that it provides excellent soft tissue details as compared to CT and does not expose the patients to any harmful radiations. MRI can detect marrow invasion by tumor earlier than CT. MRI provides information about the involvement of the base of the tongue, floor of the mouth, and is very useful to see the tumor extension into the oro-pharynx that is extremely difficult to be seen on CT (Figure 3). The gadolinium chelates used as MRI contrast agents are associated with a much

Table 9. Correlation between MRI nodal (N) staging and histopathological nodal (N) staging.

MRI 'N' staging	Histopathological 'N' staging			Total
	N0	N1	N2	
N0	3	0	0	3
N1	3	3	1	7
N2	4	0	8	12
Total	10	3	9	22

Table 9 correlates the MRI and histopathological (N) staging. By applying the chi square test and kappa statistics, p and k value comes out to be 0.01 and 0.458 respectively which shows moderate agreement between the clinical and MRI staging assessments.

Table 10. Clinical (T) staging vs. histopathological (T) staging.

Clinical 'T' staging	Histopathological 'T' staging				Total
	T1	T2	T3	T4	
T1	1	0	0	0	1
T2	0	6	1	0	7
T3	0	3	3	1	7
T4	0	3	2	2	7
Total	1	12	6	3	22

Table 10 correlates the clinical and histopathological tumour (T) staging. By applying the chi square test and kappa statistics, p and k value comes out to be 0.01 and 0.085 respectively which shows poor agreement between the clinical and MRI staging assessments.

Table 11. Clinical (N) staging vs. histopathological (N) staging.

Clinical 'N' staging	Histopathological 'N' staging			Total
	N0	N1	N2	
N0	4	0	3	7
N1	5	3	4	12
N2	1	0	2	3
Total	10	3	9	22

Table 11 correlates the clinical and histopathological (N) staging. By applying the chi square test and kappa statistics, p and k value comes out to be 0.01 and 0.185 respectively which shows poor agreement between the clinical and MRI staging assessments.

lower incidence of allergic/anaphylactic reactions and are less nephrotoxic in the doses used than the iodinated contrast agents used in CT [9].

Results of the study showed that the highest number of patients had tongue malignancy (about 82% of the patients). Early tumors of the tongue tend to be confined within the tongue (Figure 1). The advanced tumors can invade the surrounding structures like the floor of the mouth, tongue base, mandible and the anterior tonsillar pillar (Figure 4). Contrast-enhanced T1W images help assess marrow invasion, soft tissue extent, tumor thickness and best demonstrate necrosis in nodes (Figure 3). MRI is also used to assess the extent of lymphadenopathy. It is used to assess the presence of occult metastatic lymph nodes. So the present study emphasized the importance of MR imaging as a valuable tool for carrying out the loco-regional staging of oral cavity

cancers with an extreme degree of precision. The extent of primary tumor (T) and metastasis to regional lymph nodes (N) was initially evaluated by clinical examinations followed by MR imaging in this study. The final diagnosis was made by histopathological examination. Kappa Index was used for data analysis. Our study shows that there is moderate agreement (kappa value 0.537) between the clinical and MRI T staging. Clinical T staging changes in 32% of patients after performing MRI, which is finally proven by histopathological examination. This is consistent with the studies performed by Paiva RR et al. [10] and Paiboon JJ et al. [11] which also showed that mis-staging by clinical examination in the overall stage grouping was high.

Our study shows good/substantial agreement (kappa value 0.790) for the T staging (tumor depth and width) between MRI and pathological assessments. The final staging as

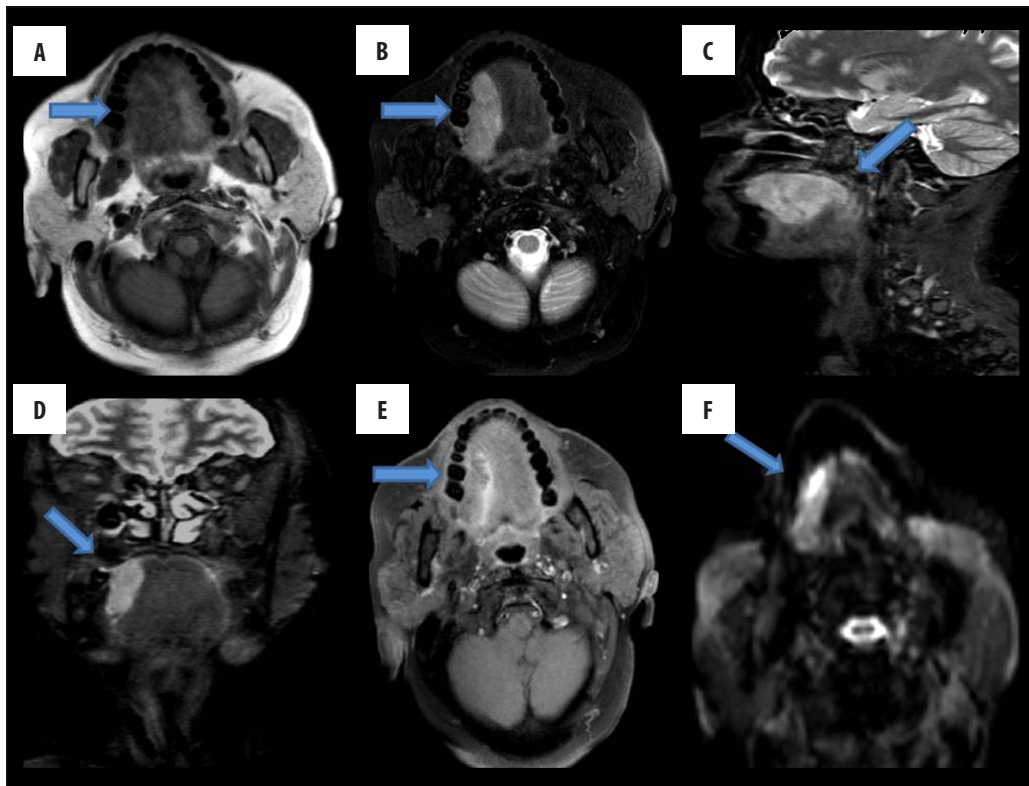


Figure 1. Shows a mass lesion with soft tissue signal intensity involving the right lateral border of the tongue, appearing isointense on T1W images (A), hyperintense on T2W (B), STIR sagittal (C), STIR coronal images (D), extending posteriorly to involve the posterior margin of the tongue, showing mild contrast enhancement on post-contrast T1W F5 images (E) and restriction on diffusion weighted images (F).

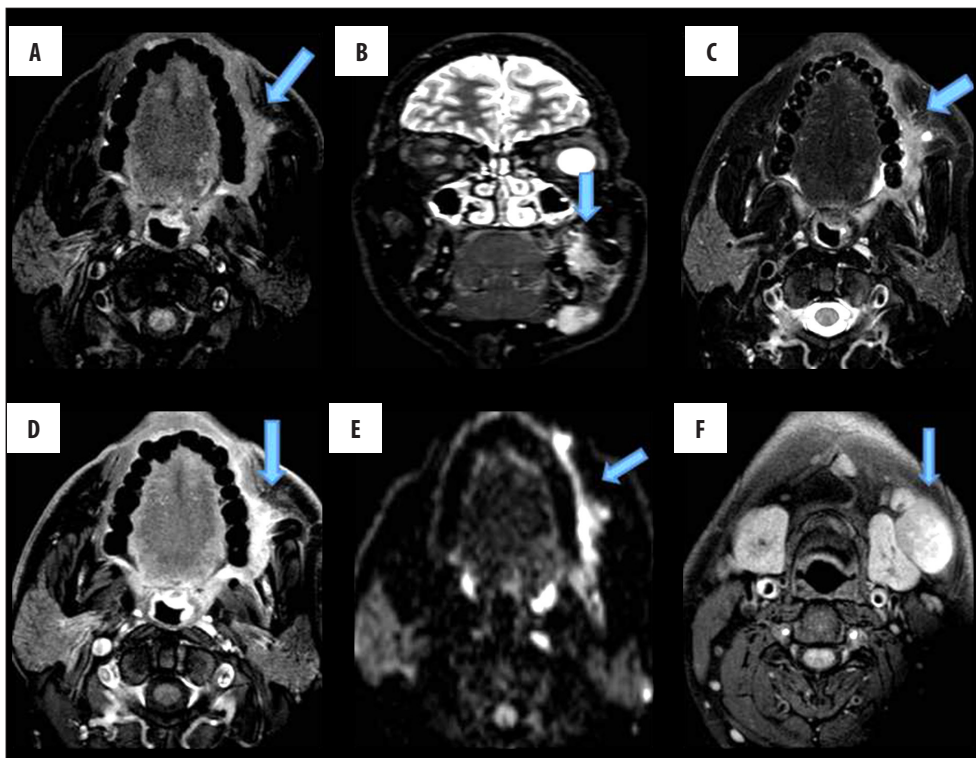


Figure 2. Shows a mass lesion with ill-defined soft tissue signal intensity, involving the buccal mucosa on the left side, opposite the second, third molars, appearing isointense on T1W (A), hyperintense on STIR coronal (B), T2W (C) images, extending to the left retromolar trigone with loss of fat planes with the buccinator muscle, showing minimal enhancement (D) and restriction on DWI (E). (F) shows enlarged lymph nodes at levels Ib, II on both sides.

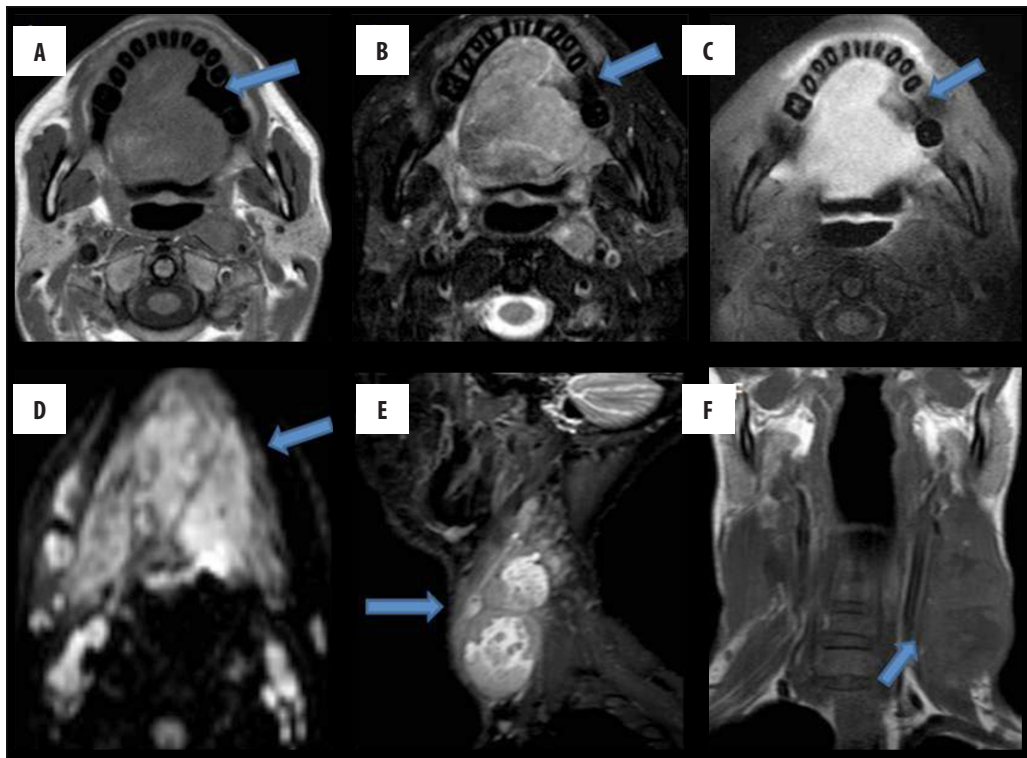


Figure 3. Shows a lesion with ill-defined soft tissue signal intensity, involving almost the whole tongue, appearing isointense on T1W (A), heterogeneously hyperintense on T2W images (B), showing moderate contrast enhancement (C). On DWI, it shows restriction (D). Posteriorly, it involves the base of the tongue and obliterates the oropharyngeal lumen. Multiple heterogeneously-enhancing lymph node masses seen along both jugular chains (E, F).

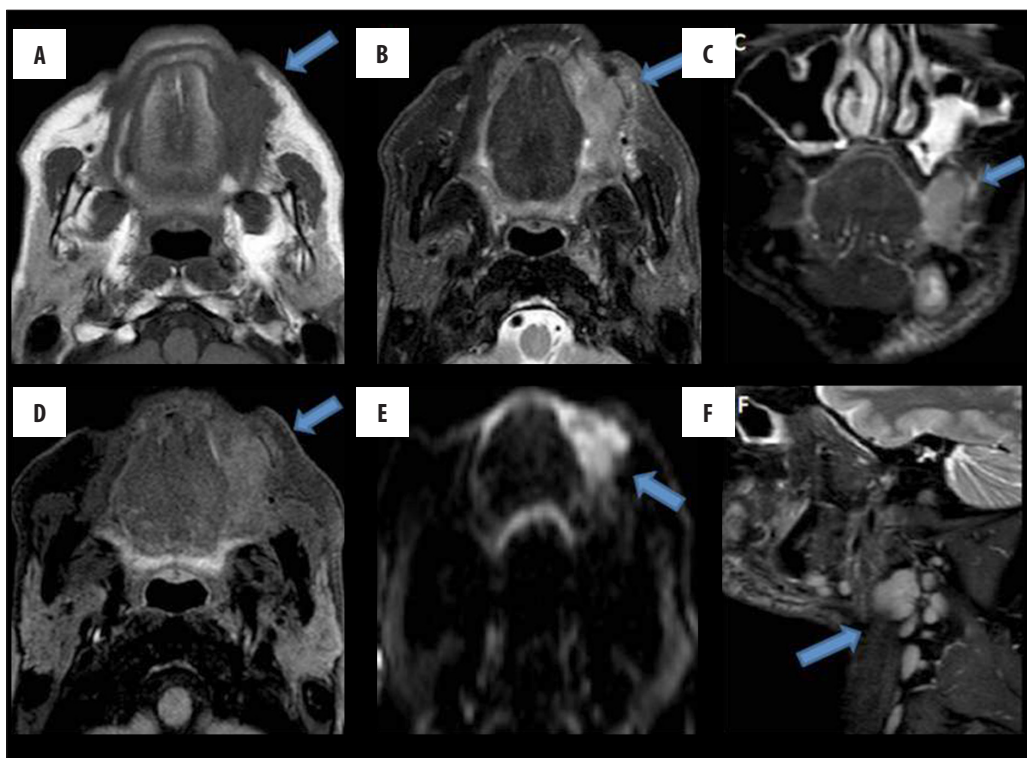


Figure 4. Shows a mass lesion with ill-defined soft tissue signal intensity, involving the buccal space on the left side, appearing isointense on T1W (A), hyperintense on T2W (B) and STIR coronal images (C), showing mild enhancement (D). Restriction on DWI (E). Laterally, reaching up to subcutaneous tissues. Medially, indenting the left lateral margin of the tongue with well-defined fat planes in between. (F) shows enlarged lymph nodes at levels 1b, II, III on the left side.

assessed by MR imaging in our study remains the same in 19 out of 22 patients who underwent surgery and final staging by histopathological means. These results are consistent with the study conducted by Tetsumura A et al. [12] in which the tumor depth and width were measured on both MR images and histo-pathological sections and the authors observed a high correlation between the values measured by MRI and histopathology.

Zeng et al. [13] also conducted similar studies and founded that MRI showed good performance in displaying tumor invasion, invasion depth and extension. This is consistent with the present study which also shows good/substantial agreement (kappa value 0.790) for the T staging but shows only fair agreement (kappa value 0.458) for the N staging between MRI and pathological staging assessments.

Our study shows that MRI is an adequate technique for the assessment of oral cavity malignancies, in the evaluation of depth invasion, presence and extension of mandibular involvement (T stage), and shows excellent agreement with the final T staging by histopathology. This is consistent with the study conducted by Vidiri et al. [14] which also shows similar results.

Paul Lam et al. [15] also conducted a study in which the radiological tumor thickness on contrast-enhanced

T1-weighted and T2-weighted images was compared with the histological tumor thickness. They concluded that MR images provide satisfactory accuracy for the measurement of tumor thickness and staging of oral tongue cancer. This is consistent with the results of our present study which also shows good/substantial agreement (kappa value 0.790) for the T staging between MRI and pathological staging assessments.

Conclusions

A high correlation was found between the values measured by MRI and histopathology for thickness of the mucosal epithelium and both depth and width of tumors. MRI provides satisfactory accuracy for preoperative estimation of tumor thickness and paralingual distance, valuable for predicting occult cervical nodal metastasis. The mucosal epithelium, lamina propria and muscles of the tongue were clearly identifiable on MRI. MRI is the imaging modality of choice for staging of malignancy of the oral cavity and tongue using TNM classification which helps a clinician in planning treatment like glossectomy/marginal mandibulectomy or radiotherapy or both.

Conflicts of interest

None.

References:

- Arya S, Chaukar D, Pai P: Imaging in oral cancers. *Indian J Radiol Imaging*, 2012; 22: 195-20
- Sobin LH, Wittekind CH: UICC TNM classification of malignant tumors. 6th Ed. New York: Wiley-Liss, 2002; 52-56
- Castelijns JA: Diagnostic radiology of head and neck oncology. *Curr Opin Oncol*, 1991; 3(3): 512-18
- Van den Brekel MW, Castelijns JA, Snow GB: The role of modern imaging studies in staging and therapy of head and neck neoplasms. *Semin Oncol*, 1994; 21(3): 340-48
- Madison MT, Remley KB, Latchaw RE, Mitchell SL: Radiologic diagnosis and staging of head and neck squamous cell carcinoma. *Radiol Clin North Am*, 1994; 32(1): 163-81
- Imaizumi A, Yoshino N, Yamada I et al: A potential pitfall of MR imaging for assessing mandibular invasion of squamous cell carcinoma in the oral cavity. *Am J Neuroradiol*, 2006; 27(1): 114-22
- Yasumoto M, Shibuya H, Takeda M, Korenaga T: Squamous cell carcinoma of the oral cavity: MR findings and value of T1- versus T2-weighted fast spin-echo images. *Am J Roentgenol*, 1995; 164(4): 981-87
- Edge SB, Byrd DR, Compton CC: AJCC cancer staging manual. 7th ed. New York: Springer, 2010; 241-49
- Singh D, Sahoo S, Gupta V, Srivastava D: Latest advancements in imaging of oral and maxillofacial neoplasm: A comprehensive review. *J Oral Maxillofac Radiol*, 2013; 1: 37-42
- Rogério RP, de Souza PT, Leite AF et al: Oral cancer staging established by magnetic resonance imaging. *Braz Oral Res*, 2011; 25(6): 512-18
- Hirunpat S, Paiboon JJ, Angunsri N, Chowchuvech V: When should MRI be recommended for the accurate clinical staging of base of tongue carcinoma. *Asian Pacific J Cancer Prev*, 2007; 8(2): 310-14
- Tetsumura A, Yoshino N, Amagasa T et al: High-resolution magnetic resonance imaging of squamous cell carcinoma of the tongue: An *in vitro* study. *Dentomaxillofac Radiol*, 2001; 30(1): 14-21
- Zeng H, Liang CH, Zhou ZG et al: Study of preoperative MRI staging of tongue carcinoma in relation to pathological findings. *Di Yi Jun Yi Da Xue Xue Bao*, 2003; 23(8): 841-43
- Vidiri A, Ruscito P, Pichi B et al: Oral cavity and base of the tongue tumors. Correlation between clinical, MRI and pathological staging of primary tumor. *J Exp Clin Cancer Res*, 2007; 26(4): 575-82
- Lam P, Au-Yeung KM, Cheng PW et al: Correlating MRI and histologic tumor thickness in the assessment of oral tongue cancer. *Am J Roentgenol*, 2004; 182(3): 803-8.