

Abdominal Total Hysterectomy: The Modified Aldridge's Procedure with Noda's Method

Yoh Watanabe, MD, PhD¹

¹Department of Obstetrics and Gynecology, Tohoku Medical and Pharmaceutical University, Sendai, Japan

Surg J 2019;5(suppl S1):S22–S26.

Address for correspondence Yoh Watanabe, MD, PhD, Department of Obstetrics and Gynecology, Tohoku Medical and Pharmaceutical University, 1-15-1, Fukumuro, Miyagino-ku, Sendai 983-8536, Japan (e-mail: ywatanabe@tohoku-mpu.ac.jp).

Abstract

Although laparoscopic surgery or robotic surgery has recently been the main procedure adopted for managing benign uterine tumors, abdominal total hysterectomy must still be learned as a basic surgical skill for obstetricians and gynecologists. Total hysterectomy is divided into two types: the extrafascial and intrafascial approaches. Intrafascial hysterectomy, represented by the Aldridge's method, is a useful and safe procedure for treatment when the patient has no cervical malignancy, including cervical intraepithelial neoplasia. Furthermore, the intrafascial approach is safely performed even in patients with firm adhesion in the Douglas's pouch and/or around the uterine cervix due to endometriosis, pelvic inflammatory diseases, or a history of intrapelvic surgery. The intrafascial approach can also effectively prevent descent of the vaginal stump after hysterectomy via the partial preservation of the uterine retinaculum. Although the Aldridge's method was originally reported to start via an intrafascial approach at the position of the internal cervical os using scissors, Dr. Kiichiro Noda created a modified version of the procedure that increases its ease and safety by changing the position and management of the parametrial tissue including the uterine artery. The details of this modified Aldridge's procedure using Noda's method are explained below.

Keywords

- ▶ abdominal hysterectomy
- ▶ intrafascial method
- ▶ Aldridge's procedure
- ▶ gynecologic surgery
- ▶ benign tumor

The Preoperative Evaluation

A cytological examination of the uterine cervix must be performed to detect any cervical neoplastic diseases. The collection of detailed clinical information on endometriosis and the medical history concerning colorectal surgery is also important.

In-Depth Explanation

Opening the Pelvic Cavity

The length of the low abdominal wound depends on the size of the uterus; the skin incision should be started two fingerbreadths above the pubis. Of note, the extension of the skin incision toward the pubis will not improve the visibility of the operating field.

Processing of Ligaments of the Uterine Corpus and Exfoliation of the Urinary Bladder

While holding the uterus with the fallopian tube, ovarian ligament and round ligament using long forceps, cut and ligate the round ligament and cut the anterior broad ligament of the uterus to exfoliate the urinary bladder from the uterine cervix. Cut and ligate the mesosalpinx to release the fallopian tube, and cut and ligate the ovarian ligament as close as possible to the uterus when performing an ovarian-preserving procedure. Cut the infundibulopelvic ligament and place double ligatures when performing salpingo-oophorectomy. After treatment of the bilateral salpinx or ovaries, cut the posterior broad ligament of the uterus as far as the point of uterine attachment of the uterosacral ligament to safely separate the ureter from the uterine cervix. After confirming the center of the uterine cervix by palpitation, the bladder is released from its attachment to

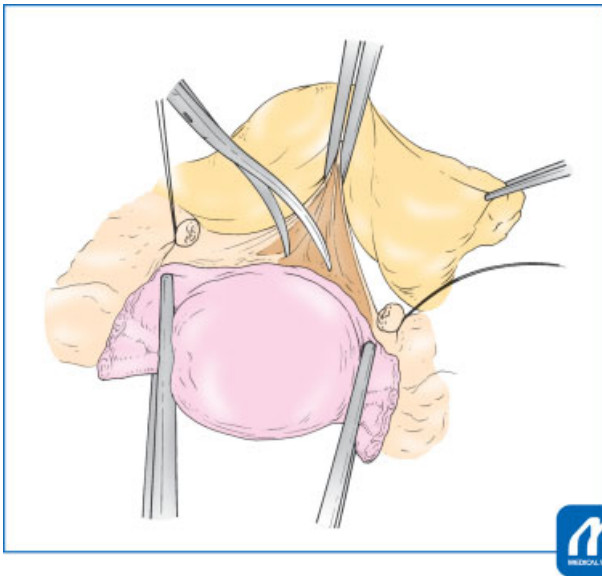


Fig. 1 Exfoliate the urinary bladder from the uterine cervix using scissors. Exfoliation should not be performed any more than is necessary by considering the parametrial clamping position. (Reproduced with permission from Watanabe Y, Nagaoka A, Hoshiai H. Aldridge method modified by Noda. In: Hiramatsu Y, Konishi I, Sakuragi N, Takeda S, eds. Mastering the Essential Surgical Procedures OGS NOW, No.2 Total Abdominal Hysterectomy (Japanese). Tokyo: Medical View; 2010: 74-83. Copyright © Medical View).¹

the uterine cervix by sharp dissection of the conjunctive tissue using scissors under traction of the vesicouterine peritoneum (► **Fig. 1**).

Processing of the Parametrial Tissues

To confirm the uterine artery, cut the connective tissue around the uterine cervix with upward traction of the uterus and

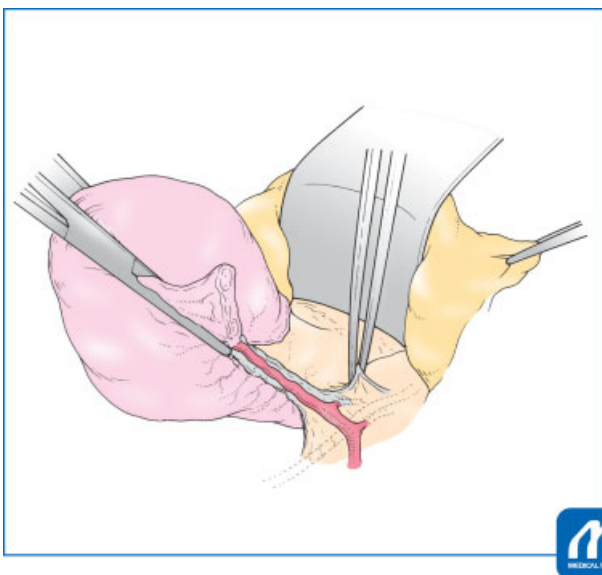


Fig. 2 Arrange the parametrial tissues. Cut the connective tissue around the uterine cervix and parametrium to ensure safe clamping of the parametrium. (Reproduced with permission from Watanabe Y, Nagaoka A, Hoshiai H. Aldridge method modified by Noda. In: Hiramatsu Y, Konishi I, Sakuragi N, Takeda S, eds. Mastering the Essential Surgical Procedures OGS NOW, No.2 Total Abdominal Hysterectomy (Japanese). Tokyo: Medical View; 2010: 74-83. Copyright © Medical View).¹

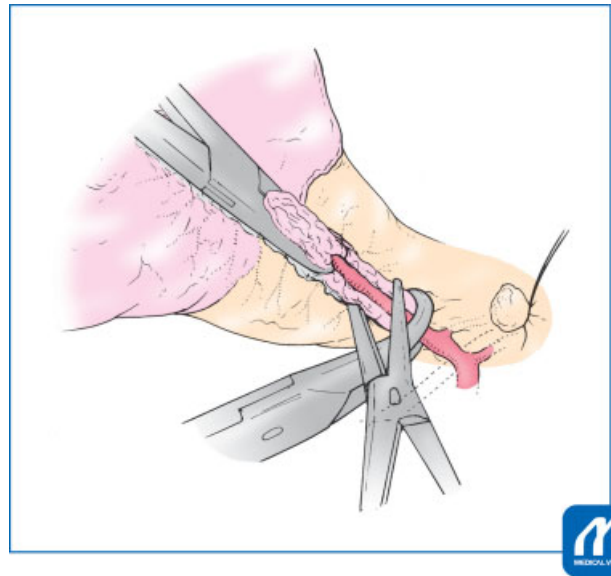


Fig. 3 Clamp the parametrial tissues. The parametrial tissues are clamped at the intermediate position between the internal and external cervical os, including part of the longitudinal muscle layer of the uterine cervix. (Reproduced with permission from Watanabe Y, Nagaoka A, Hoshiai H. Aldridge method modified by Noda. In: Hiramatsu Y, Konishi I, Sakuragi N, Takeda S, eds. Mastering the Essential Surgical Procedures OGS NOW, No.2 Total Abdominal Hysterectomy (Japanese). Tokyo: Medical View; 2010: 74-83. Copyright © Medical View).¹

lateral traction of the peritoneum using forceps for safe preparation (► **Fig. 2**). Although the original Aldridge's procedure involves clamping the parametrial tissue directly beneath the internal cervical os, the Noda's method involves placing parametrial clamps at the intermediate position between the internal and external cervical os. Furthermore, it is easy to

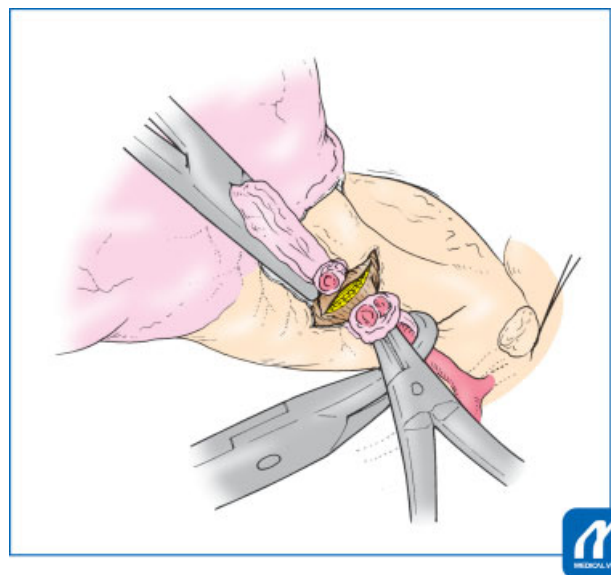


Fig. 4 Cut the parametrial tissues. The parametrial tissues are cut, including part of the longitudinal muscle layer of the uterine cervix. (Reproduced with permission from Watanabe Y, Nagaoka A, Hoshiai H. Aldridge method modified by Noda. In: Hiramatsu Y, Konishi I, Sakuragi N, Takeda S, eds. Mastering the Essential Surgical Procedures OGS NOW, No.2 Total Abdominal Hysterectomy (Japanese). Tokyo: Medical View; 2010: 74-83. Copyright © Medical View).¹

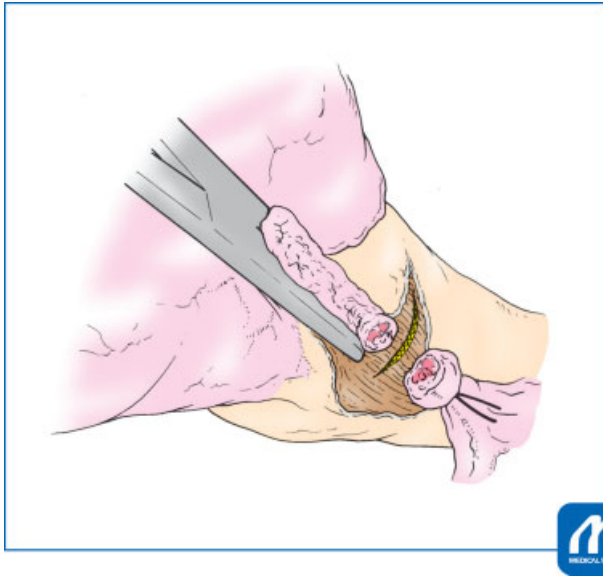


Fig. 5 Ligate the parametrial tissue with sutures. Ligation of the parametrial tissues should be made not to the Douglas's pouch but to the uterine cervix. (Reproduced with permission from Watanabe Y, Nagaoka A, Hoshiai H. Aldridge method modified by Noda. In: Hiramatsu Y, Konishi I, Sakuragi N, Takeda S, eds. *Mastering the Essential Surgical Procedures OGS NOW, No.2 Total Abdominal Hysterectomy (Japanese)*. Tokyo: Medical View; 2010: 74-83. Copyright © Medical View).¹

perform the intrafascial approach, including the longitudinal muscle layer of the uterine cervix when the parametrial tissue is appropriately clamped (→ Fig. 3). However, the position of parametrial clamping should be shifted to the upper position when firm adhesion around the uterine cervix is observed.

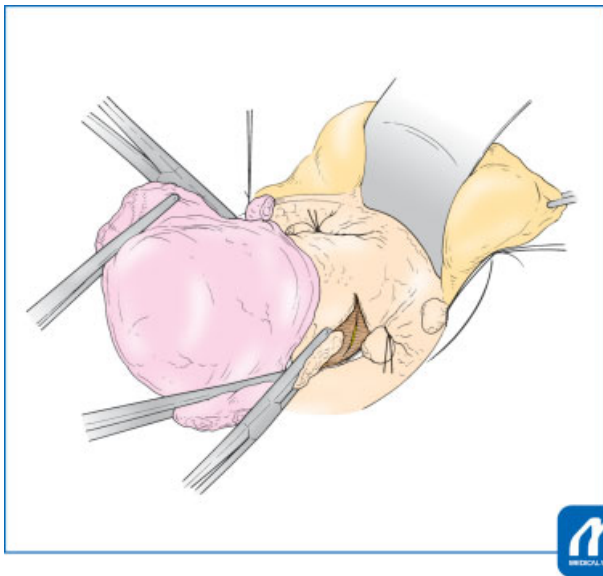


Fig. 6 Confirm the parametrial status. When starting the intrafascial approach, confirm that part of the longitudinal muscle layer of the uterine cervix has been cut. (Reproduced with permission from Watanabe Y, Nagaoka A, Hoshiai H. Aldridge method modified by Noda. In: Hiramatsu Y, Konishi I, Sakuragi N, Takeda S, eds. *Mastering the Essential Surgical Procedures OGS NOW, No.2 Total Abdominal Hysterectomy (Japanese)*. Tokyo: Medical View; 2010: 74-83. Copyright © Medical View).¹

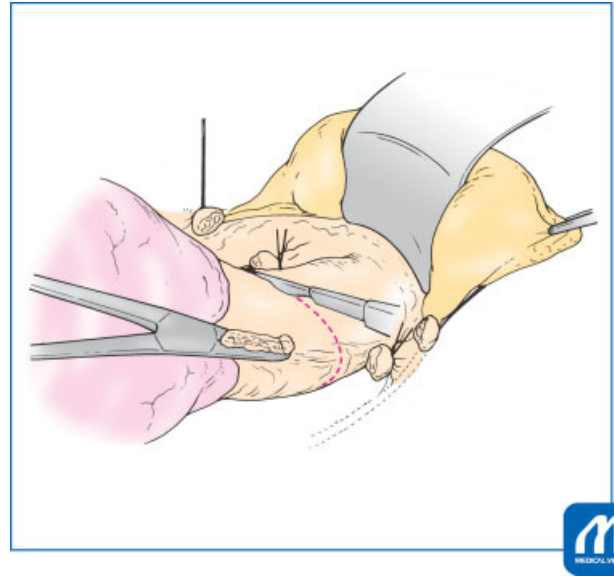


Fig. 7 Start the intrafascial approach. Connect the bilateral cutting tips of the cervical longitudinal muscle layer. (Reproduced with permission from Watanabe Y, Nagaoka A, Hoshiai H. Aldridge method modified by Noda. In: Hiramatsu Y, Konishi I, Sakuragi N, Takeda S, eds. *Mastering the Essential Surgical Procedures OGS NOW, No.2 Total Abdominal Hysterectomy (Japanese)*. Tokyo: Medical View; 2010: 74-83. Copyright © Medical View).¹

Intrafascial Approach

Cut the bilateral parametrial tissues with scissors including a part of the longitudinal muscle layer of the uterine cervix. (→ Fig. 4) and suture-ligated with delayed absorbable material (→ Fig. 5). Ligation should be made just under the forceps,

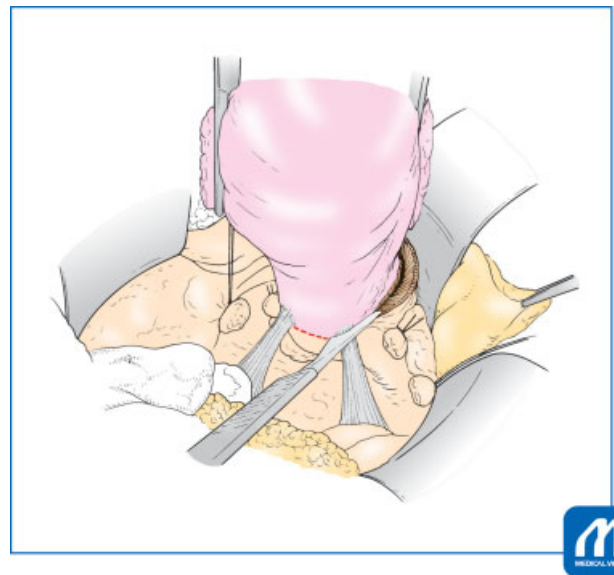


Fig. 8 Cut the utero-sacral ligaments. The uterosacral ligaments were cut under sufficient traction of the uterus, allowing the uterus to be markedly elevated. (Reproduced with permission from Watanabe Y, Nagaoka A, Hoshiai H. Aldridge method modified by Noda. In: Hiramatsu Y, Konishi I, Sakuragi N, Takeda S, eds. *Mastering the Essential Surgical Procedures OGS NOW, No.2 Total Abdominal Hysterectomy (Japanese)*. Tokyo: Medical View; 2010: 74-83. Copyright © Medical View).¹

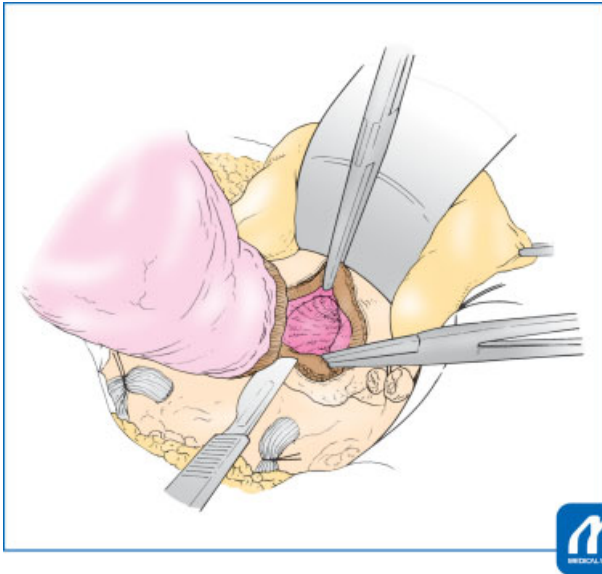


Fig. 9 Open the vaginal canal. Because the vaginal canal will spontaneously open with proper performance of the intrafascial approach, the vaginal cuff should not be resected any more than is necessary. (Reproduced with permission from Watanabe Y, Nagaoka A, Hoshiai H. Aldridge method modified by Noda. In: Hiramatsu Y, Konishi I, Sakuragi N, Takeda S, eds. *Mastering the Essential Surgical Procedures OGS NOW, No.2 Total Abdominal Hysterectomy (Japanese)*. Tokyo: Medical View; 2010: 74-83. Copyright © Medical View).¹

toward not the Douglas's pouch but the uterine cervix. After processing the bilateral parametrial tissues (►Fig. 6), confirm that the urinary bladder has been exfoliated below the ligation position of the parametrial tissue. Connect the bilateral cutting tips of the cervical longitudinal muscle layer using a cold or electronic scalpel under sufficient traction of

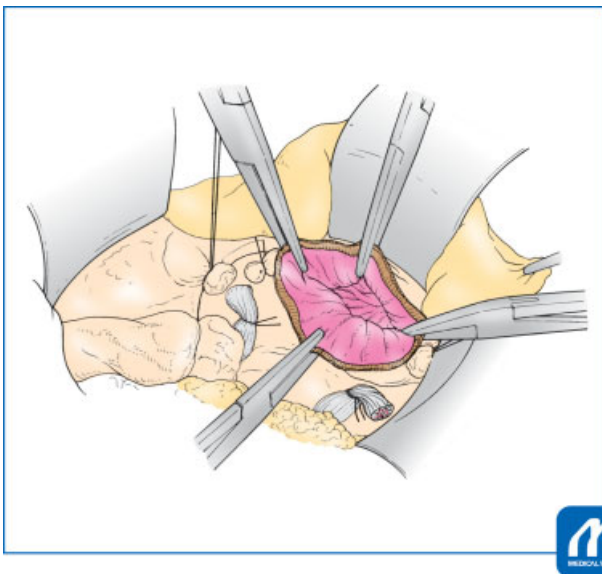


Fig. 10 Confirm hysterectomy has been performed by checking for remnants of the uterine cervix. (Reproduced with permission from Watanabe Y, Nagaoka A, Hoshiai H. Aldridge method modified by Noda. In: Hiramatsu Y, Konishi I, Sakuragi N, Takeda S, eds. *Mastering the Essential Surgical Procedures OGS NOW, No.2 Total Abdominal Hysterectomy (Japanese)*. Tokyo: Medical View; 2010: 74-83. Copyright © Medical View).¹

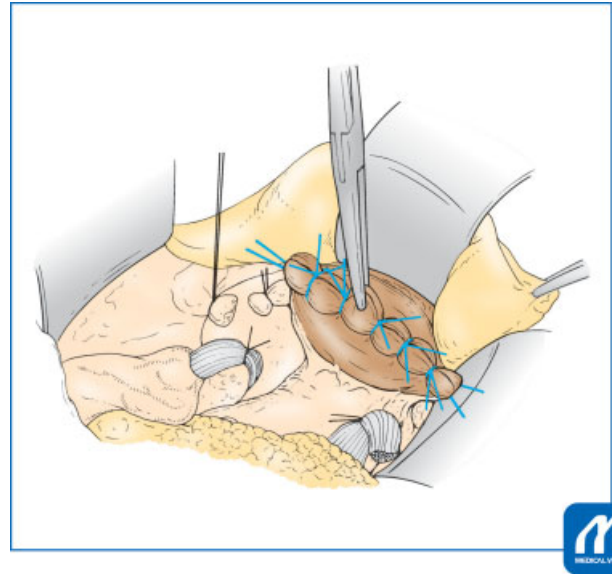


Fig. 11 Close the vaginal canal. Lack of bleeding from the bilateral parametrium and the uterosacral ligaments should be confirmed. (Reproduced with permission from Watanabe Y, Nagaoka A, Hoshiai H. Aldridge method modified by Noda. In: Hiramatsu Y, Konishi I, Sakuragi N, Takeda S, eds. *Mastering the Essential Surgical Procedures OGS NOW, No.2 Total Abdominal Hysterectomy (Japanese)*. Tokyo: Medical View; 2010: 74-83. Copyright © Medical View).¹

the uterus (►Fig. 7). Then gradually elevate the uterus by cutting the longitudinal muscle layer, notably elevating it when cutting the uterosacral ligament (►Fig. 8). The vaginal canal will spontaneously open when the intrafascial approach is properly performed (►Fig. 9).

Closure of the Vaginal Cuff and Abdomen

It is important to confirm that no uterine cervix remains and hold the vaginal canal, including the vaginal mucous membrane, using long forceps (►Fig. 10). After sterilization and confirmation of bleeding at the vaginal stump, close the vaginal cuff by ligation with sutures and delayed absorbable material (►Fig. 11). Place antiadhesive material on both the visceral and parietal cut ends of the peritoneum and close the abdomen.

Tips and Warnings

Important points for successful performance of the intrafascial approach include imaging as not “cut down” the uterine cervix but “pull out” the uterine cervix under enough traction of the uterus. The uterus should be clearly elevated when cutting the proper longitudinal muscle layer of the uterine cervix. Because the vaginal canal will open spontaneously with the proper performance of the intrafascial approach, do not cut into the vaginal canal forcibly.

References

- 1 Watanabe Y, Nagaoka A, Hoshiai H. Aldridge method modified by Noda. In: Hiramatsu Y, ed. *Mastering the Essential Surgical Procedures: Total Abdominal Hysterectomy (Japanese)*. Tokyo: Medical View; 2010:74–83