

# Bullous eczema presenting as bullous pemphigoid-like eruption: A case series



George Atteh, BS, Emily F. Cole, MD, MPH, Adam J. Perricone, MD, PhD, and Ron J. Feldman, MD, PhD  
Atlanta, Georgia

**Key words:** autoimmune blistering disease; bullous eczema; bullous pemphigoid; eczema; general dermatology.

## INTRODUCTION

Bullous pemphigoid (BP) is an autoimmune blistering disease resulting from autoantibodies directed against BP180 and/or BP230 proteins. BP is traditionally diagnosed based on clinical features, histologic assessment of cutaneous biopsies, direct (DIF) and indirect immunofluorescence (IIF) studies, and/or enzyme-linked immunoassay (ELISA) analysis. We here report, 6 elderly patients who presented with multiple tense bullae, clinically mimicking BP in the absence of detectable autoantibodies by DIF, IIF, and ELISA for BP-180, BP-230, and type VII collagen autoantibodies. All patients in this case series had histological overlap between BP and eczema, potentially representing a unique form of bullous eczema. Patient demographics are listed in [Table 1](#) along with clinical images ([Fig 1](#)). Patients were evaluated in the Autoimmune Blistering Disease Clinic at Emory University. All patients had at least 2 negative DIFs on 2 separate occasions. Only 1 patient was subject to systemic immune suppression at the time of biopsy, and no history of diabetes, peripheral edema, or arthropod assault was noted.

## CASE DESCRIPTIONS

Patients were between 68 and 78 years of age. Interestingly, all of the patients presented with a pruritic rash, which was clinically suggestive of eczema prior to the development of blisters. Histologically, patients were also noted to have spongiotic dermatitis, and, notably, eosinophils were observed as a component of the inflammatory infiltrate in at least one biopsy from all 6 patients. Patient 2 had histologic evidence of a superficial and deep dermal inflammatory infiltrate with associated eosinophils in 1 of the 4 biopsies. A deep inflammatory infiltrate was not identified in any of the other

### Abbreviations used:

BP:	bullous pemphigoid
DIF:	direct immunofluorescence
ELISA:	enzyme-linked immunoassay
IIF:	indirect immunofluorescence
PBP:	prodromal bullous pemphigoid

patients included in this case series. Only one of the 6 patients had mucosal involvement. All patients experienced improvement after initiating immunomodulating therapies ([Table 1](#)). Two representative patients are described below:

### Patient 1

In 2013, a 77-year-old Caucasian woman developed a pruritic erythematous rash over her chest, back, arms, and legs after playing golf. She presented to the emergency department where she received a course of steroids. She then developed a widespread scaly rash with biopsies demonstrating hyperkeratosis, irregular epidermal hyperplasia, spongiosis, and a perivascular inflammatory infiltrate with lymphocytes and few eosinophils. DIF was negative. She was diagnosed with eczematous dermatitis and subsequently treated with triamcinolone and narrow-band UVB therapy 3 times weekly. Two months after starting therapy, she developed large bullae, and a repeat biopsy for DIF was negative ([Fig 1](#)). She then continued to develop recurrent large bullae, and, after consultation with another provider in 2014, she underwent another biopsy for DIF, which came out negative for the third time. She was then considered to clinically have BP with eczema, and she received mycophenolate mofetil, which was titrated up to 2.5 grams daily with improvement in her symptoms.

From the Department of Dermatology, Emory University.

Funding sources: None.

Correspondence to: Ron J. Feldman, MD, PhD, Department of Dermatology, Emory University, 1525 Clifton Rd, Suite 100, Atlanta, GA, 30322. E-mail: [ron.j.feldman@emory.edu](mailto:ron.j.feldman@emory.edu).

JAAD Case Reports 2021;10:34-7.

2352-5126

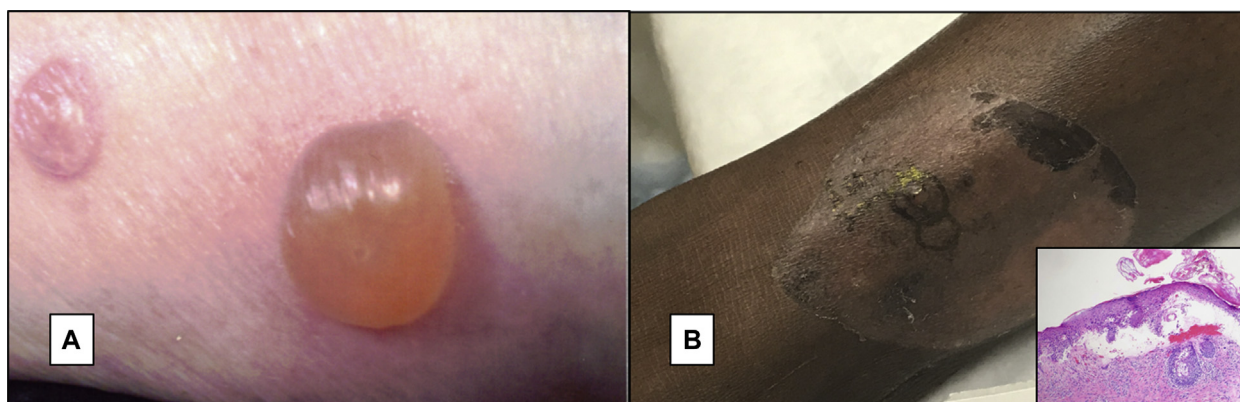
© 2021 by the American Academy of Dermatology, Inc. Published by Elsevier, Inc. This is an open access article under the CC BY-NC-ND license (<http://creativecommons.org/licenses/by-nc-nd/4.0/>).

<https://doi.org/10.1016/j.jidcr.2021.01.032>

**Table I.** Clinical summary of patients 1 to 6

	Age	Sex	Location of blisters	Atopic history	Hematoxylin-eosin-stain			DIF	ELISA	Treatments
					Spongiotic dermatitis	Sub-epidermal bulla				
Patient 1	77	F	Legs	Yes	Yes	No	Negative	Negative	MMF, topicals	
Patient 2	68	M	Feet, legs, arms, back	Yes	Yes	No	Negative	Negative	Dapsone, Mtx, topicals	
Patient 3	75	M	R hand, R wrist	No	Yes	Yes	Negative	Negative	Topicals	
Patient 4	76	F	Thighs, legs, hands	No	Yes	No	Negative	Negative	Topicals	
Patient 5	75	M	Face, arms, legs, feet	Yes	Yes	No	Negative	Negative	Prednisone, topicals	
Patient 6	73	F	Legs and feet	No	Yes	Yes	Negative	Negative	MMF, topicals	

DIF, Direct immunofluorescence; ELISA, enzyme-linked immunoassay; MMF, mycophenolate mofetil; Mtx, methotrexate; R, right.



**Fig 1.** Clinical pictures showing large tense bulla from Patient 1 **A**, and a healing bulla from Patient 2 **B**, Inset: pathologic image demonstrating biopsy result of tense bulla from Patient 3 demonstrating subepidermal bulla with numerous eosinophils.

In 2016, she was referred to the Emory Autoimmune Blistering Disease Clinic, where physical examination revealed crusted plaques on the left shin and ankle and healing bullae on the dorsal aspect of the left foot. IIF and serum ELISA were negative for anti-BP180, anti-BP230, and anti-type VII collagen autoantibodies. With continued improvement, she was slowly tapered on her mycophenolate mofetil dose to 1 gram daily with only occasional outbreaks on her shins and feet; itching was controlled with antihistamines.

### Patient 2

Patient 2 was a 68-year-old African American man, who initially presented to a local dermatologist, reporting recurrent blisters presented in 2016. He subsequently underwent 3 biopsies over the next 3 months with histopathology revealing subacute spongiotic dermatitis with eosinophils in the presence of a negative DIF. The rash was initially thought to reflect a reaction to an arthropod bite, and he was treated with permethrin, doxycycline, and prednisone with some improvement in symptoms. In 2017, he presented to another dermatology clinic complaining of a similar pruritic blistering rash on his

arms, right leg, and trunk, for which he was using clobetasol. A repeat biopsy was performed at that visit, demonstrating mild spongiotic dermatitis with an associated superficial and deep perivascular inflammatory infiltrate comprised of lymphocytes, histiocytes, and eosinophils. Repeat DIF was negative.

The patient was referred to Emory's Autoimmune Blistering Disease Clinic in 2019, and he was noted to have eczematous plaques along with large tense bullae mostly on the lower extremities (Fig 1). A repeat biopsy of a bulla from the right ankle showed a superficial perivascular and interstitial eosinophilic inflammatory infiltrate. Repeat DIF was negative, and IIF and serum ELISA for anti-BP-180, anti-BP-230, and anti-collagen type VII autoantibodies were also negative. He was then treated with dapsone 100 mg daily and triamcinolone and experienced some improvement in his symptoms. However, due to recurrent blisters on dapsone, he was subsequently switched to methotrexate (Mtx) which has provided control of his disease with occasional breakouts mostly on his arms and legs at his last visit in 2020.

## DISCUSSION

This case series describes a group of patients who presented in a manner that clinically and histologically mimics BP, but who were ultimately found to have negative DIF, IIF and ELISA results. Interestingly, there was histological overlap between immunobullous disorders and eczema in these patients. Two of 6 patients had biopsies on separate occasions demonstrating spongiotic dermatitis and subepidermal bullae with eosinophils, and at least one biopsy from each of the 6 patients exhibited spongiotic dermatitis with eosinophils. Three patients had a known history of atopy, which preceded development of bullae.

Our differential diagnosis for these presentations includes BP/prodromal BP (PBP), eczema, bullous contact dermatitis, arthropod hypersensitivity reactions, bullous eosinophilic cellulitis, and bullous tinea or scabies.

Prodromal BP (PBP) has been described, in which patients may present with a variety of dermatologic conditions, including urticarial, eczematous eruptions with histopathology commonly demonstrating spongiotic dermatitis with eosinophils.<sup>1</sup> It is possible that our patients were exhibiting prodromal symptoms of BP, with reports in the literature of PBP lasting from 6 years to 11 years.<sup>2,3</sup> There are conflicting reports regarding detectable autoantibodies by immunofluorescence during the prodromal period.<sup>1,2</sup> Another potential explanation is that the DIF biopsies were false-negative. The sensitivity of DIF for BP is reported to around 90%,<sup>4</sup> and for ELISA, it is around 89%.<sup>4</sup> Repeating DIF in patients with suspected BP and a negative initial DIF result may reveal a change to positivity as discussed previously,<sup>5</sup> proposed mechanisms including sub-threshold levels of bound IgG or degradation, as well as technical and laboratory errors.<sup>6</sup> However, all 6 patients had negative DIF on at least 2 separate occasions.

All of the patients were found to have biopsies demonstrating eosinophilic spongiosis which can be seen both in BP and eczematous dermatitis. The majority of previous studies have described blistering-type eczema as a dyshidrotic eczema, which characteristically presents with vesiculo-bullae mostly on the palms and soles. All of the patients in this series had bullae beyond acral sites, with bullae mostly larger than expected in dyshidrotic eczema. While uncommon, severe forms of eczema have been reported to form blisters, and spongiosis can sometimes lead to vesiculation, bullae formation, and separation of the dermal-

epidermal junction, resulting in a presentation that mimics other blistering disorders but lacks the characteristic autoantibodies against dermal components.<sup>7</sup> Other groups described patients with tense bullae, eosinophilic spongiosis, and negative immunofluorescence as having eczema.<sup>8</sup> Three of the patients in our series had a known history of atopy, which suggests the possibility of bullous eczema. Future studies are needed to clarify this entity.

Bullous contact dermatitis was considered; however, the duration of symptoms, atypical distribution of blisters, and the lack of identifiable triggers in our patients makes this diagnosis unlikely. Bullous eosinophilic cellulitis or Wells syndrome can develop as a reaction to an arthropod bite and present with tense bullae. The diagnosis is unlikely in our patients, given the lack of typical histologic signs; only one of 6 patients in this series had evidence of deep dermal infiltrate on one of 4 biopsies performed, and there was no mention of flame figures or granulomas, which may be seen with resolution. In addition, no identifiable arthropod assault was noted in any patient, and the eruptions were not clinically consistent with cellulitis, making bullous eosinophilic cellulitis an unlikely cause for blistering in these patients.

Infectious causes such as bullous tinea or scabies were unlikely to explain our patients' symptoms, given the atypical distribution of blisters, the chronicity of symptoms, response to treatment, and lack of histological evidence.

In summary, we present a unique group of patients with conditions that mimic BP clinically yet lack histologic and serologic evidence of autoantibodies. All of the patients had biopsies demonstrating eosinophilic spongiosis, suggesting that these patients may exhibit a unique form of bullous eczema, or less likely, BP with a prolonged prodromal phase. Treatment of bullous eczema could include immune-modifying medications such as those listed in [Table I](#) with regular follow-up for monitoring of serologic development of BP. Further studies with larger numbers of patients will help to confirm this observation and develop appropriate diagnostic classifications.

## Conflicts of interest

None disclosed.

## REFERENCES

1. Lamb PM, Abell E, Tharp M, Frye R, Deng JS. Prodromal bullous pemphigoid. *Int J Dermatol*. 2006;45:209-214.
2. Amato DA, Silverstein J, Zitelli J. The prodrome of bullous pemphigoid. *Int J Dermatol*. 1988;27:560-563.

3. Nakatani T, Inaoki M, Takehara K. Bullous pemphigoid with a prolonged prodrome. *J Dermatol*. 2008;35:433-436.
4. Sárdy M, Kostaki D, Varga R, Peris K, Ruzicka T. Comparative study of direct and indirect immunofluorescence and of bullous pemphigoid 180 and 230 enzyme-linked immunosorbent assays for diagnosis of bullous pemphigoid. *J Am Acad Dermatol*. 2013;69:748-753.
5. Fudge JG, Crawford RI. Bullous pemphigoid: a 10-year study of discordant results on direct immunofluorescence. *J Cutan Med Surg*. 2018;22:472-475.
6. Minz RW, Chhabra S, Singh S, Radotra BD, Kumar B. Direct immunofluorescence of skin biopsy: perspective of an immunopathologist. *Indian J Dermatol Venereol Leprol*. 2010;76:150-157.
7. Houck G, Saeed S, Stevens GL, Morgan MB. Eczema and the spongiotic dermatoses: a histologic and pathogenic update. *Semin Cut Med Surg*. 2004;23:39-45.
8. Morais KL, Miyamoto D, Maruta CW, Aoki V. Diagnostic approach of eosinophilic spongiosis. *An Bras Dermatol*. 2019;94:724-728.