

# Histiocyte-rich rhabdomyoblastic tumor of the trunk



Madeline R. Frizzell, MS,<sup>a</sup> Nhan M. Nguyen, MD, MS,<sup>b</sup> Sonal A. Parikh, MD,<sup>b</sup> Maya J. Sinai, MD,<sup>b</sup>  
Howard L. Martin, MD,<sup>c</sup> and Leonard H. Goldberg, MD<sup>b</sup>  
*Bryan and Houston, Texas*

**Key words:** malignant; rhabdomyoblastic; rhabdomyoma; rhabdomyosarcoma; tumor.

## INTRODUCTION

Soft tissue tumors comprise an extensive variety of tumors, each with an even greater variety of subtypes and features. Skeletal muscle tumors are broadly categorized as either benign (rhabdomyoma) or malignant (rhabdomyosarcoma) and then subcategorized based on various aspects such as clinical features, histopathology, immunophenotypes, and genetics. The latest World Health Organization Classification of Tumours of Soft Tissue classifies skeletal muscle tumors into rhabdomyomas, and embryonal, alveolar, pleomorphic, or spindle cell/sclerosing rhabdomyosarcomas.<sup>1</sup> Accurate diagnosis and categorization of these tumors is essential, as the prognosis of each tumor can vary widely. Martinez et al<sup>2</sup> recently described 10 cases of an unusual adult rhabdomyoblastic tumor with distinctive proliferation of nonneoplastic histiocytes. Descriptively termed *histiocyte-rich rhabdomyoblastic tumor of uncertain malignant potential*, this tumor has yet to be further characterized and categorized in the current classification system of skeletal muscle neoplasms.<sup>2</sup> We present the case of a patient with a similar tumor on the back.

## CASE REPORT

An active 68-year-old white man presented with a 2-week history of an untreated, painless mass at his left posterior shoulder. There were no identifiable triggers or trauma corresponding to the onset of the mass. He was otherwise asymptomatic and healthy with an unremarkable medical history. On presentation, there was a solitary, firm, mobile, 5-cm ×

5-cm, nontender subcutaneous mass with no epidermal changes at his left posterior shoulder. Upon wide excision, a well-circumscribed, fibrous, firm, ovoid mass was revealed (Fig 1, A). The tumor was bisected to show a cross-section with irregular light brown to yellow tissue (Fig 1, B).

Histologically, the mass was circumscribed with a well-formed fibrous capsule (Fig 2, A). There was no necrosis or calcification in the tumor. There were areas of variably prominent, large, spindled, polygonal, rounded or even multinucleate cells with abundant eosinophilic cytoplasm. This population of cells contained nuclei with vesicular nuclei and prominent nucleoli (Fig 2, B). Mitotic figures were scarce. These cells were positive for desmin and MyoD1 (Fig 2, C). There were also large numbers of histiocytes, some clustered and some interspersed among the polygonal cells (Fig 2, D). Many of these histiocytes were multinucleated (Fig 2, E). This histiocyte population was strongly positive for PU.1, CD163 and CD68 (Fig 2, F). These findings appear to be consistent with histiocyte-rich rhabdomyoblastic tumor of uncertain malignant potential, a tumor recently identified by Martinez et al in 2019.<sup>2</sup> The patient is doing well without recurrence of the tumor 1 year after diagnosis and initial wide excision.

## DISCUSSION

Histiocyte-rich rhabdomyoblastic tumor of uncertain malignant potential was recently identified by Martinez et al.<sup>2</sup> These unusual tumors have only been described in adults and show skeletal muscle differentiation. However, the distinct histiocytic

From Texas A&M College of Medicine, Bryan<sup>a</sup>; Houston Methodist, DermSurgery Associates<sup>b</sup>; and Sagis Diagnostics, PLLC Houston.<sup>c</sup>

Funding sources: None.

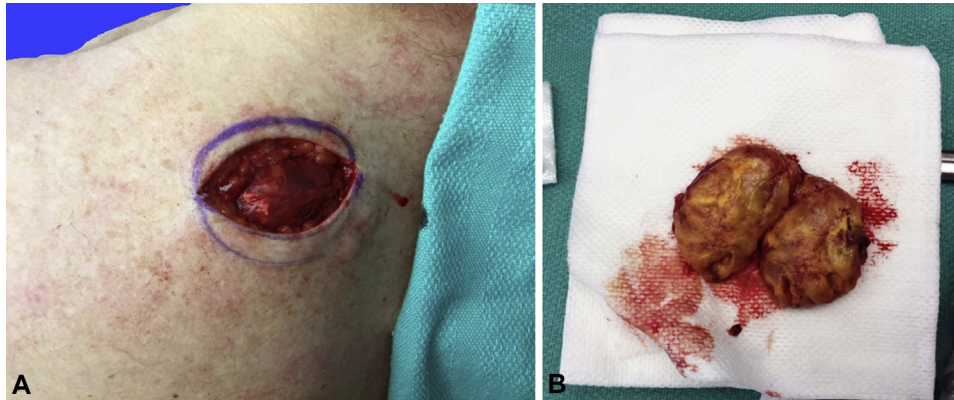
Conflicts of interest: None disclosed.

Correspondence to: Leonard H. Goldberg, MD, Department of Dermatology, DermSurgery Associates, 7515 South Main Street, Suite 240, Houston, TX 77030. E-mail: [goldb1@dermsurgery.org](mailto:goldb1@dermsurgery.org).

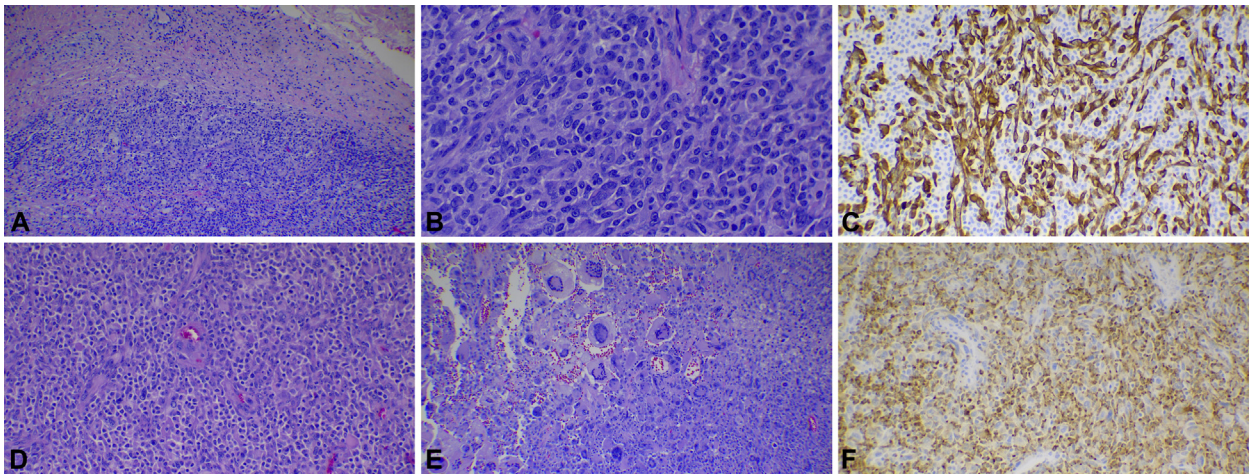
JAAD Case Reports 2020;6:1001-2.  
2352-5126

© 2020 by the American Academy of Dermatology, Inc. Published by Elsevier, Inc. This is an open access article under the CC BY-NC-ND license (<http://creativecommons.org/licenses/by-nc-nd/4.0/>).

<https://doi.org/10.1016/j.jidcr.2020.06.038>



**Fig 1.** **A**, Left posterior shoulder subcutaneous mass found in vivo after incision. **B**, Bisected tumor shows firm, irregular light brown to yellow tissue.



**Fig 2.** **A**, The neoplasm was circumscribed with a fibrous capsule. **B**, The polygonal cells had abundant eosinophilic cytoplasm and contained enlarged, vesicular nuclei with prominent nucleoli. **C**, The polygonal cells were positive for desmin. **D**, Numerous polygonal cells were present with interspersed lymphocytes and histiocytes. **E**, There were notable areas rich in histiocytes, many of those histiocytes being multinucleated. **F**, The histiocytes were positive for CD68. (Original magnifications: **A**, **D**, and **E**:  $\times 100$ ; **B**,  $\times 400$ ; **C** and **F**:  $\times 200$ .)

infiltration and other features of these tumors do not correspond to known skeletal muscle tumors in the World Health Organization Classification of Tumours of Soft Tissue. Our case appears to be consistent with this newly described tumor, noting the tumor in our patient grew quickly in a matter of 2 weeks.

Short-term follow-up and prognosis of these cases after wide excision appears to be favorable, but long-term prognosis is unknown. Much remains to be elucidated about this histiocyte-rich rhabdomyoblastic tumor; thus, close and continued follow-up of

known cases is essential to better characterize the nature of this relatively unknown tumor.

#### REFERENCES

1. Fletcher CDM, Bridge JA, Hogendoorn PCW, eds. *WHO Classification of Tumours of Soft Tissue and Bone*. 4th ed. Lyons: IARC Press; 2013:123-134.
2. Martinez AP, Fritchie KJ, Weiss SW, et al. Histiocyte-rich rhabdomyoblastic tumor: rhabdomyosarcoma, rhabdomyoma, or rhabdomyoblastic tumor of uncertain malignant potential? A histologically distinctive rhabdomyoblastic tumor in search of a place in the classification of skeletal muscle neoplasms. *Mod Pathol*. 2019;32(3):446-457.