






S1 Transforaminal Epidural Anesthesia in Percutaneous Transforaminal Endoscopic Discectomy: A Case-Series Study

Seyed Masoud Hashemi ^{1,2}, Shima Rajaei ^{1,2}, Mani Falsafi ^{3,4}, Ebrahim Golmakani ^{5,6}, Faranak Behnaz ^{1,7}, Alireza Zali ^{7,8,9} and Sogol Asgari ^{10,*}

¹Department of Anesthesiology, School of Medicine, Shahid Beheshti University of Medical Sciences, Tehran, Iran

²Imam Hossein Hospital, Shahid Beheshti University of Medical Sciences, Tehran, Iran

³Department of Surgery, School of Medicine, Babol University of Medical Sciences, Babol, Iran

⁴Shahid Beheshti Hospital, Babol University of Medical Sciences, Babol, Iran

⁵Department of Anesthesiology, School of Medicine, Mashhad University of Medical Sciences, Mashhad, Iran

⁶Imam Reza Hospital, Mashhad University of Medical Sciences, Mashhad, Iran

⁷Shohada-e-Tajrish Hospital, Shahid Beheshti University of Medical Sciences, Tehran, Iran

⁸Department of Neurosurgery, School of Medicine, Shahid Beheshti University of Medical Sciences, Tehran, Iran

⁹Functional Neurosurgery Research Center, Shahid Beheshti University of Medical Sciences, Tehran, Iran

¹⁰Functional Neurosurgery Research Center, Shohada Tajrish Comprehensive Neurosurgical Center of Excellence, Shahid Beheshti University of Medical Sciences, Tehran, Iran

*Corresponding author: Functional Neurosurgery Research Center, Shohada Tajrish Comprehensive Neurosurgical Center of Excellence, Shahid Beheshti University of Medical Sciences, Tehran, Iran. Email: drasgari98429@gmail.com

Received 2022 September 16; Revised 2023 May 29; Accepted 2023 June 09.

Abstract

Background: Percutaneous transforaminal endoscopic discectomy (PTED) has become popular over the years due to its safety and low invasiveness. This surgery can be performed with different anesthesia techniques; however, the extent to which the surgeon and patient are satisfied with the analgesia is debatable.

Objectives: This study investigated the efficiency of the S1 transforaminal epidural block.

Methods: This retrospective study was conducted on 60 patients with L4 - L5 lumbar disc herniation who underwent PTED under the S1 transforaminal epidural block. All patients had clinical symptoms associated with unilateral radiculopathy and were candidates for surgery. Percutaneous transforaminal endoscopy and S1 epidural block were performed by a surgeon for all patients.

Results: Of the 60 evaluated cases, 61.7% and 38.3% were female and male, respectively, with a mean age of 42.98 ± 10.79 years. The mean pain score before surgery was 7.83 ± 0.69 , which decreased to 2.58 ± 0.65 during surgery and 0.50 ± 0.50 48 hours after surgery ($P < 0.001$). The mean duration of operation in these patients was 58.58 ± 16.95 minutes, and the mean onset time was 10.08 ± 3.12 minutes. Moreover, the mean bleeding was 124.17 ± 25.20 cc.

Conclusions: The PTED with S1 epidural anesthesia is a simple, safe, and effective method that causes good analgesia during the operation and cooperates well with the surgeon in neurological monitoring due to patient consciousness.

Keywords: Discectomy, Epidural, Lumbar Disc Herniation, Percutaneous Transforaminal Endoscopic Discectomy, Minimally Invasive Spine Surgery, Radiculopathy, Low Back Pain

1. Background

Percutaneous transforaminal endoscopic discectomy (PTED) is a modern and effective method for the removal of symptomatic lumbar spine hernias that improves refractory pain syndromes (1). This surgical procedure has become a desirable procedure for lumbar disc herniation (LDH) due to its safety, minimal invasion of surrounding tissues, reduction of bleeding during surgery, short hospital stay, and faster return of the patient to daily activities (2). Providing patient analgesia during PTED

surgery is performed through various methods of general anesthesia, sedation, local anesthesia (LA), and epidural anesthesia (EA). To prevent damage to the nervous system, it is best for the patient to be alert during this procedure to report pain due to possible nerve damage (3, 4).

Recently, the use of LA has been considered; however, in clinics, it does not provide the desired analgesia and causes prolonged surgery, increased radiation exposure, and patient and surgeon dissatisfaction. The EA is a good option for patient analgesia during surgery due to the patient's awakening, providing optimal analgesia, and

the possibility of patient neurological monitoring (5). However, studies describing the short-term and long-term safety of using epidural blocks in PTED are rare. Zheng et al. conducted a systematic review to compare the safety of EA and LA. A meta-analysis, including six studies, revealed EA as a safe method in PTED (6).

Due to the posterior interlaminar approach and easier identification of anatomic orientation, some studies have also used interlaminar epidural injections for patient analgesia (7). Nevertheless, in this study, by selecting S1 transforaminal epidural blocks for patients' Pain, due to the simplicity of the technique and the possibility of few side effects, the surgeon can perform the block, and the exposure time and the length of the surgery are also reduced (6).

2. Objectives

This study investigated the efficiency of the S1 epidural block during surgery.

3. Methods

3.1. General Information

This retrospective study was performed on patients who underwent PTED with the S1 epidural block from May 2020 to May 2021. This study was registered in the Research Council of Shahid Beheshti University of Medical Sciences, Tehran, Iran (ethics code: IR. SBMU RETECH.1400.752). The study protocol was in accordance with the Declaration of Helsinki. All the included patients were informed about the purpose of the study, and written consent was obtained from the parents.

This study evaluated 60 patients with LDH from May 2020 to May 2021 who underwent PTED with the S1 epidural block. All hernia patients had L4 - L5 level and unilateral clinical signs, and supportive treatments were not effective after 6 - 12 weeks. The patients subjectively scored their satisfaction out of 10 at intervals before surgery, during surgery, and 48 hours after surgery.

3.2. Criteria for Inclusion and Exclusion

3.2.1. Inclusion Criteria

(1) Patients with a definitive diagnosis of LDH who did not recover after 6 - 12 weeks of supportive and medical treatment and underwent PTED at L4 - L5 level, with the S1 epidural block;

(2) Patients with an age range of 18 - 65 years and American Society of Anesthesiologists grades 1 and 2.

3.2.2. Exclusion Criteria

(1) History of receiving anticoagulants or coagulopathy;

(2) Systemic or local infection at the surgical site;

(3) History of allergies to the drugs used in the study;

(4) History of severe cardiovascular, liver, kidney, and hematology diseases;

(5) Mental disorders;

(6) Lumbar disc herniation in more than one level;

(7) History of lumbar surgery;

(8) Spondylosis or anatomical disorder in the lumbar region.

3.3. Surgical Procedure

Before the operation, an intravenous Line G 18 is inserted for the patient, and the patient is monitored for heart rate, blood pressure, blood oxygen, and electrocardiogram. The patient is placed in the prone position, and a pillow is placed under the abdomen to reduce lumbar lordosis. After prep and drop, the desired sacral surface for the block was identified in the fluoroscopic anterior-posterior view. Line up the superior S1 end plate by tilting the beam cephalad. Squaring off the superior S1 end plate by tilting the fluoroscope cephalad provides an initial starting point for optimizing visualization. The dorsal S1 foramen is better visualized with a slight ipsilateral oblique view. The surgeon places the spinal needle 25 coaxially into the fluoroscopic beam. The needle enters the S1 foramen after hitting the inferior aspect of the S1 pedicle and walk-off superior. Then, 1 - 2 cc of contrast agent is injected to see the S1 epidurogram, and 12 cc of 1% lidocaine is injected to achieve the aim of sensory-motor separation. After analgesia, all the patients underwent transforaminal endoscopy by a surgeon. All the patients were awake during surgery and received no adjuvant intravenous sedation (Figure 1).

3.4. Clinical Evaluation

All the patients were followed up using a questionnaire before, during, and 48 hours after surgery. Pain, cooperation during surgery, and patient and surgeon satisfaction as primary results, and mean arterial pressure and patient heart rate as secondary results were asked in this questionnaire.

The visual analog scale (VAS) was used to measure the degree of back or leg pain in patients. The VAS is characterized by a score range of 0 - 10. Higher scores indicate more severe pain. In this way, a 10 cm line was drawn on the paper; the beginning and end of the line were marked with 0 and 10, and then the patient was asked to show the amount of pain on it (8). According to

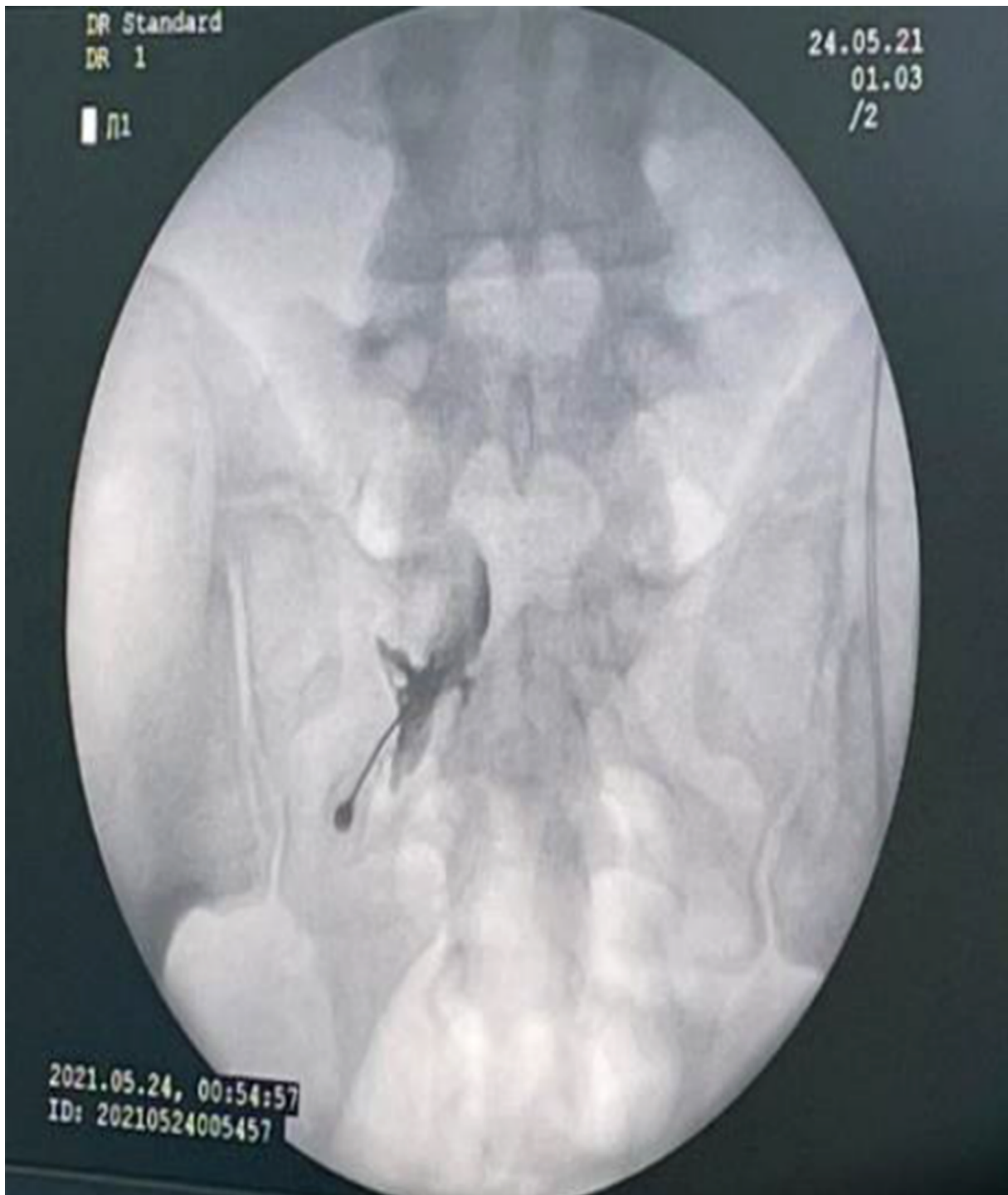

Figure 1. S1 epidurogram view after injection of 1 mL contrast agent

the patient's pain in different degrees, the VAS score was classified as follows:

- 0: Painless;
- 1 to 3: Slight pain;
- 4 to 6: Moderate tolerable pain;
- 7 to 10: Unbearable severe pain.

Patient and surgeon subjective satisfaction was recorded by a numerical scale. Accordingly, the numbers 8 - 10, 4 - 7, and less than 4 showed high satisfaction, average satisfaction, and dissatisfaction of the patient or surgeon, respectively. The surgeon graded the cooperation of patients during surgery. In assessing patient cooperation during surgery, the absence of inappropriate or unwanted movements of the patient during surgery indicates good cooperation, and the presence of these movements occasionally shows moderate cooperation. If the patient's movements disrupt surgery, it shows poor patient cooperation. The time between the onset of EA and the start of surgery (i.e., surgical onset time), the volume of intraoperative bleeding, and the duration of surgery were also recorded.

3.5. Statistical Assessment

All quantitative variables are expressed as mean \pm standard deviation, and qualitative variables are expressed as numbers (percentages). Additionally, a paired *t*-test was used to compare quantitative variables between the two different times. Statistical tests were performed in two domains at a significant level of 5%, and SPSS software (version 26) was used for data analysis.

4. Results

4.1. Patient Demographics

Of the 60 patients evaluated in this study, 61.7% and 38.3% were female and male, respectively. The patients' mean age and weight values were 42.98 ± 10.79 years and 74.27 ± 9.83 kg, respectively (Table 1).

Table 1. Distribution of Patient Gender

Gender	No. (%)
Female	31 (61.7)
Male	23 (35.3)

4.2. Clinical Results

The symptoms of all preoperative patients did not improve with conservative treatment after 6 - 12 weeks. The mean preoperative pain score in these patients was 7.83 ± 0.69 , which decreased to 2.58 ± 0.65 during surgery and

1.50 ± 0.65 48 hours after surgery. Moreover, 48 hours after surgery, the postoperative pain score decreased by an average of 7.33 ± 0.04 units, compared to preoperative time, which was statistically significant ($P < 0.001$) (Figure 2 and Table 2).

Table 2. Clinical Results ^a

Characteristics	Values
Level	
L4 - L5	60 (100)
VAS score	
Before surgery	7.83 ± 0.69
During surgery	2.58 ± 0.65
48 hours after surgery	1.50 ± 0.65

Abbreviation: VAS, visual analog scale.

^a Values are expressed as No. (%) or mean \pm standard deviation.

The mean scores of cooperation, patient satisfaction, and surgeon satisfaction were equal to 1.80 ± 0.40 , 8.88 ± 0.69 , and 8.98 ± 0.89 , respectively (Table 3).

Table 3. Patient Cooperation and Surgeon Satisfaction

Variables	Mean \pm Standard Deviation
Patient cooperation	1.80 ± 0.40
Patient satisfaction	8.88 ± 0.69
Surgeon satisfaction	8.98 ± 0.89

In addition, patients' mean arterial pressure and heart rate at three different times of needle entry into the skin, obturator entry, and endoscope entry had limited changes (Table 4).

Table 4. Mean Arterial Blood Pressure and Heart Rate of Patients at Three Different Times ^a

Variables	Values
Number of patients	60
Mean arterial pressure	
Needle entry time into the skin	74.63 ± 11.48
Obturator arrival time	75.60 ± 11.82
Endoscope arrival time	75.87 ± 11.87
Heart rate	
Needle entry time into the skin	70.00 ± 7.32
Obturator arrival time	71.45 ± 6.96
Endoscope arrival time	71.23 ± 7.29

^a Values are expressed as No. or mean \pm standard deviation.

The mean duration of operation in these patients was 58.58 ± 16.95 minutes, and the mean onset time was $3.12 \pm$

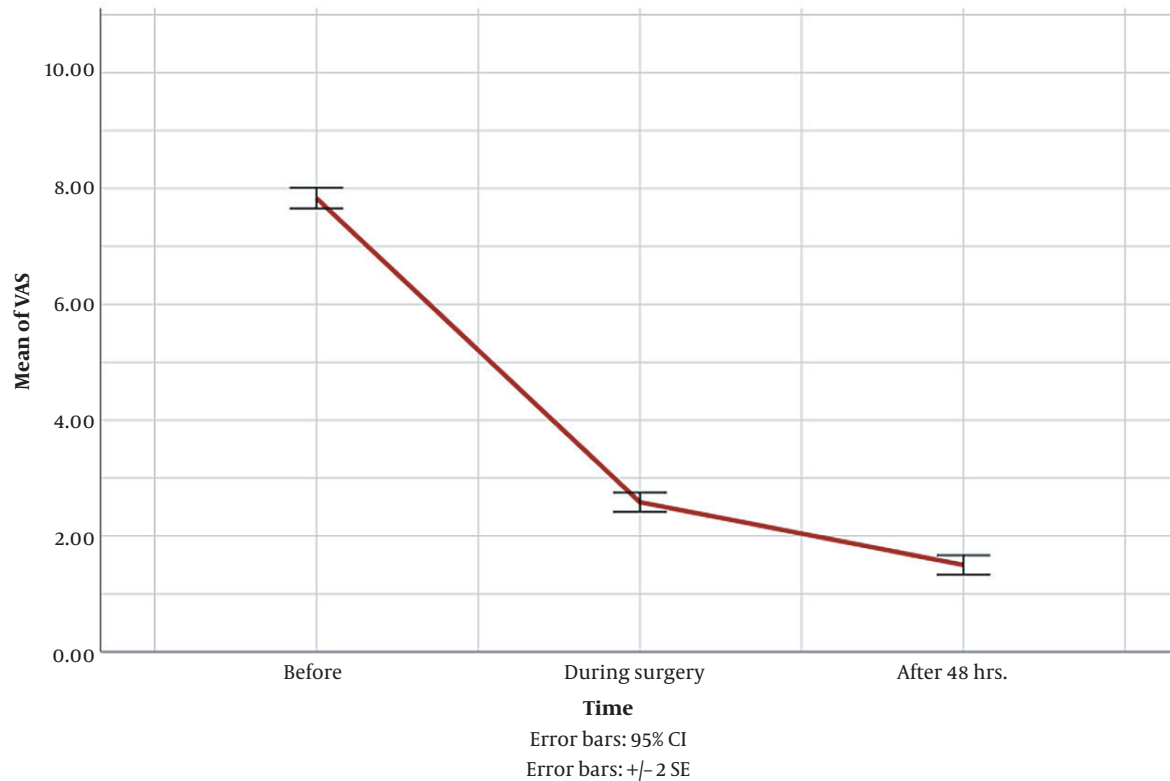


Figure 2. Comparison of visual analog scale (VAS) score to preoperative time

10.08 minutes. Moreover, the mean bleeding was 124.17 ± 25.20 cc (Table 5).

Table 5. Mean Duration of Operation

Variables	Mean \pm Standard Deviation
Total operation time	58.58 ± 16.95
Blood loss	124.17 ± 25.20
Surgical onset time	10.08 ± 3.12

4.3. Complications

There were no immediate or delayed postoperative complications in these cases.

5. Discussion

This retrospective study evaluated 60 patients with L4 - L5 disc herniation candidates for PTED. In this survey, all the included patients underwent the S1 transforaminal EA. Low back pain is observed in 80% of the general population and is one of the most common complaints with a great

impact on society and the economy (9). Disc herniation is a common cause of low back pain and sciatica. Annually, 5 cases per 1,000 individuals develop LDH (10, 11). Lumbar disc herniation can be treated with various methods, such as education, personal care, physiotherapy, medication, interventional pain procedures, and surgery (12, 13). There are several surgical procedures for the treatment of LDH, including open discectomy and minimally invasive procedures.

Open surgery is associated with extensive tissue damage and postoperative pain that will increase the patient's recovery time and have adverse economic and social effects (14, 15). Currently, open microdiscectomy is still the gold standard treatment for LDH, although without class I evidence. Long-term complications of lumbar microdiscectomy include recurrence, epidural fibrosis, and spinal instability, which can be challenging even for an experienced spine surgeon (10, 16). Due to these microdiscectomy limitations, microendoscopic discectomy was introduced. Advances in the use and design of optics and surgical instruments have led to the use of completely endoscopic surgical procedures, such as

endoscopic lumbar discectomy through the skin (3, 17).

Recently, some reports have suggested that PTED could be an alternative treatment for LDH with clinical results comparable to conventional open lumbar discectomy. The advantages of this method include no bone removal, reduction of complications, minor wounds, reduction of bleeding, reduction of fluid requirements, no need for catheterization, reduction of hospitalization period, very low complication rate, rapid recovery, return to work, and reduction of costs. The safety and effectiveness of this treatment have been confirmed by several randomized studies (18-20). On the other hand, because this procedure is performed under LA or EA, the patient is conscious during surgery, and damage to the spinal cord is prevented (13, 21).

Managing patient pain during surgery is very important for patient and surgeon satisfaction and reduction of costs (8). Patient analgesia using LA does not have the side effects of general anesthesia; however, according to previous studies, it has not provided good pain control in patients, especially when implanting working channel and foraminal expansion, which is practically difficult to continue surgery due to the patient pain and, in some cases, requires the use of general anesthesia to continue surgery (22-24). In previous studies, EA has provided acceptable analgesia compared to LA. During this method, the patient is awake and does not feel pain due to sensory-motor separation but can move his/her toes; therefore, the general anesthesia method is preferable in preventing nerve damage and the possibility of monitoring the patient by the surgeon (24, 25). The disadvantages of EA include increasing the time of exposure to radiation, an increase in surgery time, and a long learning curve (22).

Almost all studies showed better pain management in patients who underwent EA. Zhen et al. conducted a meta-analysis, including 1660 patients (26). It was revealed that the intraoperative VAS score in patients with EA was significantly lower than in patients who received LA (26). Similarly, Sun et al. showed that the intraoperative and postoperative lumbar and leg VAS scores in the EA group were significantly lower than LA (27). Another meta-analysis comprising six studies and 529 patients confirmed the same results (6). Consequently, intraoperative and postoperative pain control is significantly better in EA. In this study, the mean VAS score decreased significantly after 48 hours.

In 2022, Zhang et al. included 160 PTED candidates and divided them into two groups, one receiving transforaminal EA and the other LA (28). They showed that the satisfaction rate and lumbar and leg VAS scores were significantly lower in the transforaminal EA group

(28). A systematic review conducted by Zhen et al. also confirmed that the satisfaction rate is statistically higher among patients who received EA (26). Likewise, in a comparative study, the satisfaction scores between these two groups differed significantly, and the EA group had a higher satisfaction rate (23). The mean subjective satisfaction score of the present survey was 8.88, indicative of high patient satisfaction.

By evaluating 160 patients, it was revealed that patients under transforaminal EA had lower mean arterial pressure and heart rate (28). Moreover, there was a discrepancy in results regarding complications. The findings of Sun et al.'s and Zhen et al.'s meta-analyses showed no difference in adverse events between the two groups (26, 27). The findings of Zhang et al. also showed that the complication rate did not vary between patients who received transforaminal EA and LA (28). However, in a randomized control trial, it was concluded that complications, such as nausea, vomiting, dizziness, and drowsiness, were lower in the EA group (1). The same result was repeated in Zheng et al.'s systematic review (6). Nevertheless, by assessing 132 PTED candidates, postoperative dysuria and decrement of lower limb strength were observed in the EA group (23). Therefore, there is no consistent finding about the comparison of adverse events in the two groups.

Wang et al. conducted a randomized control trial and concluded that immune function had better function in patients with EA (1). Furthermore, the inflammatory indices were higher in LA patients (1). Among the evaluated variables, postoperative Oswestry Disability Index, surgical duration, and X-ray exposure did not differ between the two groups (26, 28).

In this study, with the S1 epidural block, in addition to using the benefits of epidural block in controlling patient analgesia, due to the simplicity of the S1 transforaminal epidural technique and short learning curve, it is possible for the surgeon to provide patient analgesia. Due to sensory-motor separation, when the patient is on analgesic, the surgeon can evaluate the patient during surgery and prevent unwanted complications of nerve damage.

5.1. Study Limitations

This study was conducted as a single-center survey. A multi-center study with a larger number of patients is required to obtain more precise results. A longer period of follow-up helps determine the exact mortality rate and other possible delayed complications.

5.2. Conclusions

The PTED with S1 EA is a safe and effective treatment for LDH. The S1 epidural block technique is simple and can be performed by a surgeon. It also causes good analgesia during the operation and cooperates well with the surgeon due to patient consciousness.

Acknowledgments

The authors of this article would like to express their gratitude to Shahid Beheshti University of Medical Sciences for material and spiritual assistance.

Footnotes

Authors' Contribution: Study concept and design: M. H.; acquisition of the data: M. F.; analysis and interpretation of the data: S. R.; drafting of the manuscript: S. A.; critical revision of the manuscript for important intellectual content: S. A.; statistical analysis: A. Z.; administrative, technical, and material support: F. B.; study supervision: M. H.

Conflict of Interests: The authors declare no conflict of interests.

Data Reproducibility: The dataset presented in the study is available on request from the corresponding author during submission or after publication.

Ethical Approval: This study was registered in the Research Council of Shahid Beheshti University of Medical Sciences (ethics code: [IR.SBMU.RETECH.1400.752](https://doi.org/10.1038/nrrheum.2010.3)).

Funding/Support: There was no funding/support for this study.

Informed Consent: All the included patients were informed about the purpose of the study, and written consent was obtained from them.

References

- Wang SJ, Chen BH, Wang P, Liu CS, Yu JM, Ma XX. The effect of percutaneous endoscopic lumbar discectomy under different anesthesia on pain and immunity of patients with prolapse of lumbar intervertebral disc. *Eur Rev Med Pharmacol Sci*. 2017;**21**(12):2793-9. [PubMed ID: [28682439](https://pubmed.ncbi.nlm.nih.gov/28682439/)].
- Chen Z, Zhang L, Dong J, Xie P, Liu B, Wang Q, et al. Percutaneous transforaminal endoscopic discectomy compared with microendoscopic discectomy for lumbar disc herniation: 1-year results of an ongoing randomized controlled trial. *J Neurosurg Spine*. 2018;**28**(3):300-10. [PubMed ID: [29303469](https://pubmed.ncbi.nlm.nih.gov/29303469/)]. <https://doi.org/10.3171/2017.7.SPINE161434>.
- Ahn SS, Kim SH, Kim DW, Lee BH. Comparison of Outcomes of Percutaneous Endoscopic Lumbar Discectomy and Open Lumbar Microdiscectomy for Young Adults: A Retrospective Matched Cohort Study. *World Neurosurg*. 2016;**86**:250-8. [PubMed ID: [26409086](https://pubmed.ncbi.nlm.nih.gov/26409086/)]. <https://doi.org/10.1016/j.wneu.2015.09.047>.
- Ahn SS, Kim SH, Kim DW. Learning Curve of Percutaneous Endoscopic Lumbar Discectomy Based on the Period (Early vs. Late) and Technique (in-and-out vs. in-and-out-and-in): A Retrospective Comparative Study. *J Korean Neurosurg Soc*. 2015;**58**(6):539-46. [PubMed ID: [26819689](https://pubmed.ncbi.nlm.nih.gov/26819689/)]. [PubMed Central ID: [PMC4728092](https://pubmed.ncbi.nlm.nih.gov/PMC4728092/)]. <https://doi.org/10.3340/jkns.2015.58.6.539>.
- Ahn Y. Transforaminal percutaneous endoscopic lumbar discectomy: technical tips to prevent complications. *Expert Rev Med Devices*. 2012;**9**(4):361-6. [PubMed ID: [22905840](https://pubmed.ncbi.nlm.nih.gov/22905840/)]. <https://doi.org/10.1586/erd.12.23>.
- Zheng B, Guo C, Xu S, Jin L, Hong Y, Liu C, et al. Efficacy and safety of epidural anesthesia versus local anesthesia in percutaneous transforaminal endoscopic discectomy: a systematic review and meta-analysis. *Ann Palliat Med*. 2022;**11**(8):2676-84. [PubMed ID: [35871273](https://pubmed.ncbi.nlm.nih.gov/35871273/)]. <https://doi.org/10.21037/apm-21-3413>.
- Yin J, Jiang Y, Nong L. Transforaminal approach versus interlaminar approach: A meta-analysis of operative complication of percutaneous endoscopic lumbar discectomy. *Medicine (Baltimore)*. 2020;**99**(25). e20709. [PubMed ID: [32569205](https://pubmed.ncbi.nlm.nih.gov/32569205/)]. [PubMed Central ID: [PMC7310843](https://pubmed.ncbi.nlm.nih.gov/PMC7310843/)]. <https://doi.org/10.1097/MD.00000000000020709>.
- Tedore T, Weinberg R, Witkin L, Giambone GP, Faggiani SL, Fleischut PM. Acute Pain Management/Regional Anesthesia. *Anesthesiol Clin*. 2015;**33**(4):739-51. [PubMed ID: [26610627](https://pubmed.ncbi.nlm.nih.gov/26610627/)]. <https://doi.org/10.1016/j.anclin.2015.07.005>.
- Manchikanti L, Falco FJ, Pampati V, Cash KA, Benyamin RM, Hirsch JA. Cost utility analysis of caudal epidural injections in the treatment of lumbar disc herniation, axial or discogenic low back pain, central spinal stenosis, and post lumbar surgery syndrome. *Pain Physician*. 2013;**16**(3):E129-43. [PubMed ID: [23703415](https://pubmed.ncbi.nlm.nih.gov/23703415/)].
- Gadjradj PS, Harhangi BS, Amelink J, van Susante J, Kamper S, van Tulder M, et al. Percutaneous Transforaminal Endoscopic Discectomy Versus Open Microdiscectomy for Lumbar Disc Herniation: A Systematic Review and Meta-analysis. *Spine (Phila Pa 1976)*. 2021;**46**(8):538-49. [PubMed ID: [33290374](https://pubmed.ncbi.nlm.nih.gov/33290374/)]. [PubMed Central ID: [PMC7993912](https://pubmed.ncbi.nlm.nih.gov/PMC7993912/)]. <https://doi.org/10.1097/BRS.00000000000003843>.
- van Tulder M, Peul W, Koes B. Sciatica: what the rheumatologist needs to know. *Nat Rev Rheumatol*. 2010;**6**(3):139-45. [PubMed ID: [20142811](https://pubmed.ncbi.nlm.nih.gov/20142811/)]. <https://doi.org/10.1038/nrrheum.2010.3>.
- Ruan W, Feng F, Liu Z, Xie J, Cai L, Ping A. Comparison of percutaneous endoscopic lumbar discectomy versus open lumbar microdiscectomy for lumbar disc herniation: A meta-analysis. *Int J Surg*. 2016;**31**:86-92. [PubMed ID: [27260312](https://pubmed.ncbi.nlm.nih.gov/27260312/)]. <https://doi.org/10.1016/j.ijssu.2016.05.061>.
- Manchikanti L, Buenaventura RM, Manchikanti KN, Ruan X, Gupta S, Smith HS, et al. Effectiveness of therapeutic lumbar transforaminal epidural steroid injections in managing lumbar spinal pain. *Pain Physician*. 2012;**15**(3):E199-245. [PubMed ID: [22622912](https://pubmed.ncbi.nlm.nih.gov/22622912/)].
- Wang H, Zhou Y, Li C, Liu J, Xiang L. Risk factors for failure of single-level percutaneous endoscopic lumbar discectomy. *J Neurosurg Spine*. 2015;**23**(3):320-5. [PubMed ID: [26068272](https://pubmed.ncbi.nlm.nih.gov/26068272/)]. <https://doi.org/10.3171/2014.10.SPINE14442>.
- Stienen MN, Smoll NR, Hildebrandt G, Schaller K, Gautschi OP. Influence of smoking status at time of surgery for herniated lumbar disk on postoperative pain and health-related quality of life. *Clin Neurol Neurosurg*. 2014;**122**:12-9. [PubMed ID: [24908210](https://pubmed.ncbi.nlm.nih.gov/24908210/)]. <https://doi.org/10.1016/j.clineuro.2014.04.015>.
- Doan LV, Narvaez F, Fakhry M, Padjen K, Gharibo CG. Variations of Technique in Transforaminal Epidural Steroid Injections and Periprocedural Practices by Interventional Pain Medicine Physicians in the United States. *Pain Physician*. 2019;**22**(5):E435-40. [PubMed ID: [31561655](https://pubmed.ncbi.nlm.nih.gov/31561655/)].
- Zhou Z, Ni HJ, Zhao W, Gu GF, Chen J, Zhu YJ, et al. Percutaneous Endoscopic Lumbar Discectomy via Transforaminal Approach Combined with Interlaminar Approach for L4/5 and L5/S1 Two-Level Disc Herniation. *Orthop Surg*. 2021;**13**(3):979-88. [PubMed ID: [33821557](https://pubmed.ncbi.nlm.nih.gov/33821557/)]. [PubMed Central ID: [PMC8126944](https://pubmed.ncbi.nlm.nih.gov/PMC8126944/)]. <https://doi.org/10.1111/os.12862>.

18. Bai X, Lian Y, Wang J, Zhang H, Jiang M, Zhang H, et al. Percutaneous endoscopic lumbar discectomy compared with other surgeries for lumbar disc herniation: A meta-analysis. *Medicine (Baltimore)*. 2021;**100**(9). e24747. [PubMed ID: 33655938]. [PubMed Central ID: PMC7939231]. <https://doi.org/10.1097/MD.00000000000024747>.
19. Yoshinari H, Tezuka F, Yamashita K, Manabe H, Hayashi F, Ishihama Y, et al. Transforaminal full-endoscopic lumbar discectomy under local anesthesia in awake and aware conditions: the inside-out and outside-in techniques. *Curr Rev Musculoskelet Med*. 2019;**12**(3):311-7. [PubMed ID: 31236834]. [PubMed Central ID: PMC6684726]. <https://doi.org/10.1007/s12178-019-09565-3>.
20. Zhang R, Zhang SJ, Wang XJ. Postoperative functional exercise for patients who underwent percutaneous transforaminal endoscopic discectomy for lumbar disc herniation. *Eur Rev Med Pharmacol Sci*. 2018;**22**(1 Suppl):15-22. [PubMed ID: 30004565]. https://doi.org/10.26355/eurev_201807_15354.
21. Jing Z, Li L, Song J. Percutaneous transforaminal endoscopic discectomy versus microendoscopic discectomy for upper lumbar disc herniation: a retrospective comparative study. *Am J Transl Res*. 2021;**13**(4):3111-9. [PubMed ID: 34017479]. [PubMed Central ID: PMC8129260].
22. Fang G, Ding Z, Song Z. Comparison of the Effects of Epidural Anesthesia and Local Anesthesia in Lumbar Transforaminal Endoscopic Surgery. *Pain Physician*. 2016;**19**(7):E1001-4. [PubMed ID: 27676669].
23. Zhu Y, Zhao Y, Fan G, Sun S, Zhou Z, Wang D, et al. Comparison of 3 Anesthetic Methods for Percutaneous Transforaminal Endoscopic Discectomy: A Prospective Study. *Pain Physician*. 2018;**21**(4):E347-53. [PubMed ID: 30045601].
24. Zhu Y, Zhao Y, Fan G, Gu G, Sun S, Hu S, et al. Comparison of the effects of local anesthesia and epidural anesthesia for percutaneous transforaminal endoscopic discectomy in elderly patients over 65 years old. *Int J Surg*. 2017;**48**:260-3. [PubMed ID: 29162501]. <https://doi.org/10.1016/j.ijisu.2017.11.029>.
25. Xu T, Tian R, Qiao P, Han Z, Shen Q, Jia Y. Application of continuous epidural anesthesia in transforaminal lumbar endoscopic surgery: a prospective randomized controlled trial. *J Int Med Res*. 2019;**47**(3):1146-53. [PubMed ID: 30632428]. [PubMed Central ID: PMC6421380]. <https://doi.org/10.1177/0300060518817218>.
26. Zhen Z, Zhao J, Chen C, Sun X, Zhang B, Yang Q. Comparing the Effectiveness and Safety Between Local Anesthesia versus Epidural Anesthesia for Percutaneous Transforaminal Endoscopic Discectomy: A Systematic Review and Meta-Analysis. *World Neurosurg*. 2022;**166**:e528-35. [PubMed ID: 35853571]. <https://doi.org/10.1016/j.wneu.2022.07.040>.
27. Sun J, Fang C, Gao F, Wei L, Qian J. Comparison of effectiveness and safety between epidural anesthesia vs local anesthesia for percutaneous transforaminal endoscopic discectomy: A systematic review and meta-analysis. *Medicine (Baltimore)*. 2020;**99**(1). e18629. [PubMed ID: 31895822]. [PubMed Central ID: PMC6946500]. <https://doi.org/10.1097/MD.00000000000018629>.
28. Zhang J, Wang X, Cai Z, Kang J, Liu Y, Nie C, et al. Analgesic effect of epidural anesthesia via the intervertebral foramen approach in percutaneous transforaminal endoscopic discectomy: a retrospective study. *BMC Anesthesiol*. 2022;**22**(1):397. [PubMed ID: 36539695]. [PubMed Central ID: PMC9764488]. <https://doi.org/10.1186/s12871-022-01924-x>.