

Pulmonary embolism caused by myasthenia gravis

A case report

Shan Lin, MM^a, Yan Wang, MM^b, Wei Guan, MD^{b,*}, Yingqing Shi, MM^b

Abstract

Rationale: Pulmonary embolism (PE) is a relatively common disease; however, myasthenia gravis leading to PE has been rarely reported in the literature. We report a case of PE in a patient with myasthenia gravis and discuss the possible mechanism underlying the development of PE. We hypothesize that inflammatory mediators may lead to endothelial injury, resulting in PE or deep venous thrombosis (DVT) in patients with myasthenia gravis.

Patient concerns: A 45-year-old woman had a 9-year history of myasthenia gravis. She was receiving neostigmine bromide for symptomatic relief and had never been on immunosuppressive therapy.

Diagnoses: Myasthenia gravis and pulmonary embolism.

Interventions: Our patient was treated with low-molecular-weight heparin immediately after hospital admission. Thrombolytic therapy was later initiated as her condition deteriorated.

Outcomes: After 2 weeks, the pulmonary artery systolic pressure on echocardiography reduced to 60 mm Hg, and venous ultrasonography showed no evidence of DVT. Her computed tomography pulmonary angiogram revealed a mural thrombus in both the main pulmonary arteries. She refused to undergo immunosuppressive therapy; hence, she was discharged on neostigmine bromide and warfarin. There was no recurrence of PE or DVT at 3- and 6-month follow-ups.

Lessons: Patients with an autoimmune-mediated disease may have an increased risk of DVT and PE. We hypothesize that the risk may increase in the absence of immunosuppressive therapy. Hence, anticoagulant therapy may be administered early to reduce mortality from acute PE.

Abbreviations: BNP = brain natriuretic peptide, CT = computed tomography, DVT = deep venous thrombosis, EC = endothelial cell, eNOS = endothelial nitric oxide synthase, INR = international normalized ratio, LMWH = low-molecular-weight heparin, NO = nitric oxide, PASP = pulmonary artery systolic pressure, PE = pulmonary embolism, TNF- α = tumor necrosis factor- α .

Keywords: anticoagulation, endothelial cells, inflammatory mediators, myasthenia gravis, pulmonary embolism

1. Introduction

Myasthenia gravis is a rare, clinically heterogeneous, autoimmune disorder of the neuromuscular junction characterized by fatigable weakness of voluntary muscles. The prevalence is estimated to be 8 from 20/100,000.^[1] Myasthenia gravis causes a variety of clinical symptoms, including weakness of the skeletal muscles. Besides, can the autoimmune nature of the disease cause endothelial damage and eventually lead to pulmonary embolism? Our search of PubMed, Elsevier, and the Chinese National Knowledge Infrastructure did not yield any reports that suggest

such an association. Hence, we report a case with this relatively uncommon association.

2. Case presentation

A 45-year-old woman, non-smoker, was admitted with chest tightness and dyspnea for a month. She had felt chest tightness and shortness of breath a month previously, during intense physical activity. She developed a dry cough, worse at night, 10 days before admission. The shortness of breath worsened to the point that she felt dyspnea on moderate exertion. She also felt exhausted and felt dull pain of both lower limbs accompanied by mild swelling. There was no fever, weight loss or hemoptysis. In 2008, she had felt drooping of her eyelids and weakness of both upper limbs. At that time, she was diagnosed with myasthenia gravis (type II A by the Osserman classification) following a positive neostigmine test result. A computed tomography (CT) scan showed no evidence of thymoma. She was treated with oral pyridostigmine bromide 120 to 180 mg per day and traditional Chinese medicine regularly from then on; she did not receive immunosuppressive therapy. She had stopped the traditional Chinese medicine 2 years previously and was on pyridostigmine bromide tablets 120 to 180 mg per day at the time of presentation and had no muscle weakness.

Physical examination revealed a blood pressure of 145/92 mm Hg, pulse rate of 100/min, respiratory rate of 22 breaths/min, and temperature of 36.5°C. On examination of the respiratory

Editor: N/A.

The authors have no funding and conflicts of interest to disclose.

^a Qinghai University, ^b Department of Respiratory Medicine, Qinghai University Affiliated Hospital, Xining, China.

* Correspondence: Dr. Wei Guan, Qinghai University Affiliated Hospital, Xining 810001, China (e-mail: weiguan110@163.com).

Copyright © 2018 the Author(s). Published by Wolters Kluwer Health, Inc. This is an open access article distributed under the terms of the Creative Commons Attribution-Non Commercial License 4.0 (CCBY-NC), where it is permissible to download, share, remix, transform, and buildup the work provided it is properly cited. The work cannot be used commercially without permission from the journal.

Medicine (2018) 97:49(e13578)

Received: 20 August 2018 / Accepted: 16 November 2018

<http://dx.doi.org/10.1097/MD.00000000000013578>

system, breath sounds were heard bilaterally, without crackles nor wheeze. On examination of the cardiovascular system, her heart rate was 100 beats per minute and heart sounds were normal; the pulmonary component of the 2nd heart sound was louder than aortic ($P_2 > A_2$). Jugular venous distension was observed and hepatjugular reflux was present on applying pressure over the liver. Her neurological examination was normal.

Arterial blood gas analysis revealed a pH of 7.469, partial pressure of carbon dioxide of 18.90 mm Hg, partial pressure of oxygen of 63.90 mm Hg, bicarbonate level of 13.80 mmol/L, and oxygen saturation of 92.70%. Routine blood test results were as follows: white blood cell count, $15.80 \times 10^9/L$; neutrophil count, $15.24 \times 10^9/L$; red blood cell count, $5.78 \times 10^{12}/L$; hematocrit, 36.20%; hemoglobin, 109 g/L; and platelet count, $341 \times 10^9/L$. Other laboratory findings included a lactate dehydrogenase level

of 485.50 U/L, creatine kinase of 163.70 U/L, MB isoenzyme of creatine kinase of 36.00 U/L, brain natriuretic peptide (BNP) of 868.02 pg/mL, and D-dimer of 1.6 mg/L. Antinuclear antibodies, anti-neutrophil cytoplasmic antibodies, anti-keratin antibodies, and antiphospholipid antibodies were all negative.

The electrocardiogram showed sinus tachycardia. Echocardiography showed a dilated right atrium (42 mm) and right ventricle (27 mm). The velocity of the tricuspid regurgitant jet was 4.5 m/s with a pulmonary artery systolic pressure (PASP) of 98 mm Hg, and a left ventricular ejection fraction of 69%. Her CT pulmonary angiogram revealed a thrombus in the right lower pulmonary artery and branches of the left pulmonary artery (Fig. 1). Ultrasonographic examination showed evidence of DVT in the left popliteal and posterior tibial veins.

Anticoagulant therapy with low-molecular-weight heparin (LMWH), 100 units/kg, 12 hourly was administered immediately

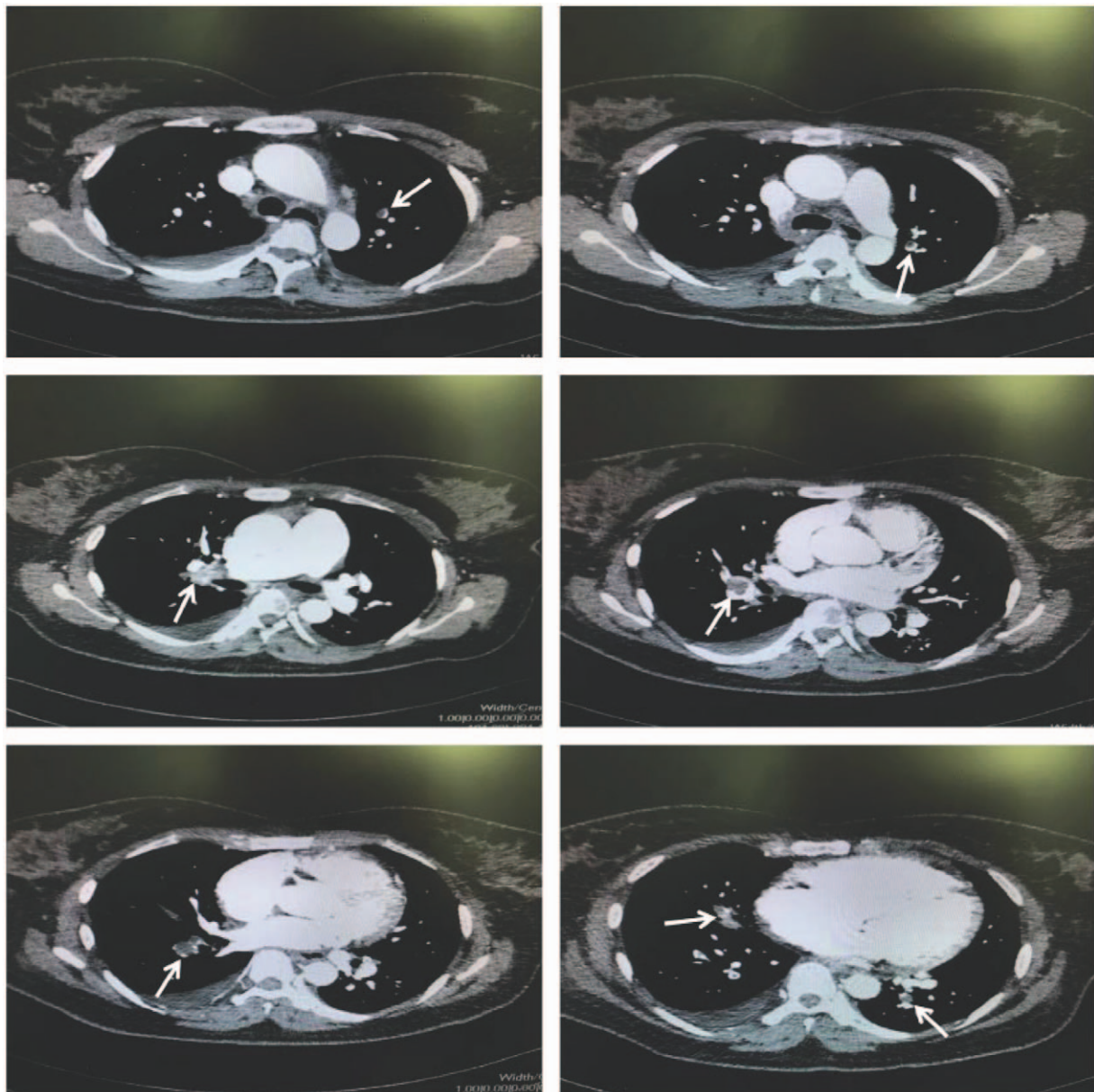


Figure 1. Computed tomography (CT) pulmonary angiography showing thrombus in the right pulmonary artery and branches of the left pulmonary arteries. CT= computed tomography.

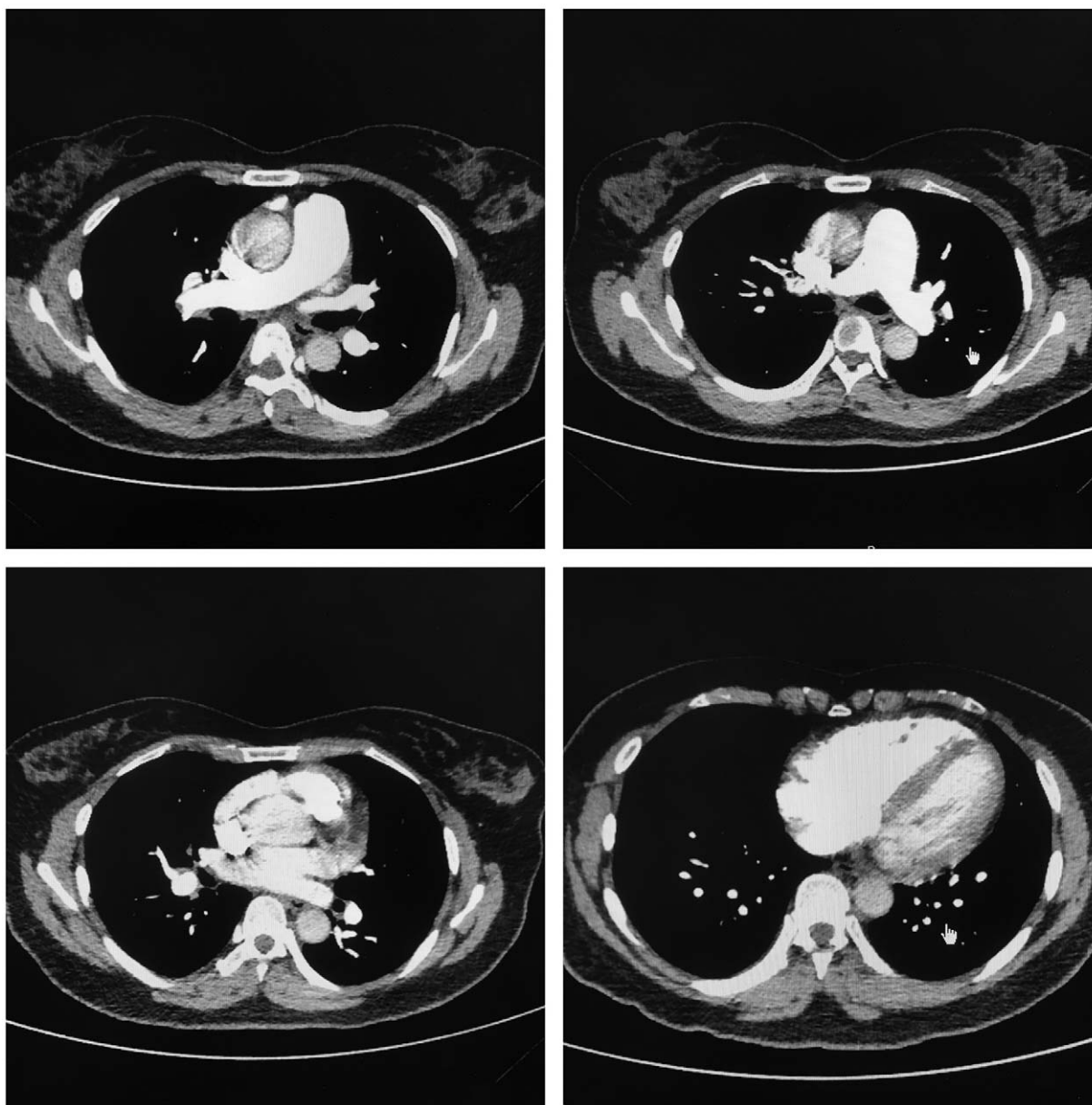


Figure 2. Computed tomography (CT) pulmonary angiography revealed mural thrombus in the right and branches of the left pulmonary arteries. CT= computed tomography.

after hospital admission. On the 3rd day of admission, she deteriorated with dyspnea even on mild exertion, and her oxygen saturation on pulse oximetry had reduced to 89% on 3L/min of oxygen. Based on the simplified pulmonary embolism severity index (≥ 1), echocardiography findings (PASP: 98 mm Hg and dilated right ventricle), and cardiac biomarker levels (BNP: 868.02 pg/mL), she was classified as medium to high risk. We decided to administer thrombolytic therapy. Urokinase was administered in a dose of 20,000 U/Kg as a continuous intravenous infusion over 2 hours. The LMWH treatment was continued and warfarin 2.5 mg was commenced on the 4th day. The LMWH and warfarin were used to maintain the international normalized ratio (INR) between 2 and 3. The LMWH therapy was discontinued once the target INR was achieved. Two weeks later, the PASP on echocardiography had reduced to 60 mm Hg, and venous ultrasound examination showed no evidence

of deep venous thrombosis (DVT); her CT pulmonary angiogram revealed a mural thrombus in the right and left branches of the pulmonary arteries (Fig. 2). Immunosuppressive therapy was declined by the patient; hence, she was discharged on neostigmine bromide and warfarin. No recurrence of pulmonary embolism (PE) or DVT was observed during follow-up at 3 and 6 months.

3. Discussion

A hypercoagulable state, stasis of blood flow, and vascular endothelial cell (EC) damage are the 3 major factors that predispose to thrombosis. Our patient did not have hypercoagulability or stasis of blood flow; hence we considered possible endothelial injury due to myasthenia gravis, resulting in deep venous thrombosis (DVT) and pulmonary embolism (PE). We searched PubMed using the keywords “myasthenia gravis and cytokines” and “endothelial

cells injury and cytokines". There were several reports of inflammatory mediators, including interleukin-1, -4, and -6, and tumor necrosis factor- α (TNF- α) causing EC injury in myasthenia gravis.^[2-4] These cytokines may cause endothelial injury and eventually lead to pulmonary embolism.

The ECs are involved in many aspects of vascular biology.^[4] The ECs can create an active antithrombotic surface that facilitates passage of plasma and cellular components through the vascular system, thereby regulating blood flow.^[5] Under physiological conditions, ECs prevent thrombosis by different pathways of anticoagulant and antiplatelet mechanisms.^[6] Healthy ECs also release nitric oxide (NO) and prostacyclin that cause vasodilatation and inhibit the platelet adhesion and activation.^[7-9] However, inflammation can disrupt these mechanisms and induce ECs to produce prothrombotic and antifibrinolytic microenvironments.^[10] Therefore, ECs play a central role in the control of thrombosis and thrombolysis. A large quantity of inflammatory mediators is released into the blood due to the autoimmune nature of myasthenia gravis that result in damage to ECs. The resulting imbalance between pro and anticoagulant mechanisms may lead to thrombus formation.

Endothelial injury caused by inflammatory mediators may be due to the following reasons.

- 1) Direct inhibition of expression of endothelial nitric oxide synthase (eNOS), decreased eNOS-mediated NO production due to reduced stability of eNOS mRNA, and inhibition of eNOS activity by interference with phosphorylation of serine/threonine kinases.^[11,12]
- 2) Stimulation of monocytes by TNF- α and release of superoxide by ECs, which promote oxidative modification of low-density lipoprotein that aggravates endothelial damage.^[13] Furthermore, oxidized lipoproteins inhibit NO release and decrease the expression of eNOS.^[13]
- 3) Expression of adhesion molecules by ECs that lead to leukocyte adhesion to ECs.^[14] The stimulation of the inflammatory cascade leads to the production of large quantities of oxygen free radicals and hydrogen peroxide that damage ECs and cause platelet activation.^[15] Free radicals can also disrupt the balance between NO and oxygen free radicals, resulting in increased permeability of ECs and allowing toxins to pass into body tissues.^[16]

Multiple factors are thus involved in the perpetuation of endothelial cell injury and eventually results in thrombosis that may lead to life-threatening acute pulmonary embolism. Cholinesterase inhibitors are routinely used for improving muscle weakness in myasthenia gravis. However, immunosuppressive therapy is important, as it may prevent endothelial cell damage and prevent the development of DVT and PE. Our patient was on neostigmine bromide for symptomatic relief; she had never undergone immunosuppressive therapy after being diagnosed with myasthenia gravis 9 years previously. We suspect that although she had symptomatic relief, the inflammatory process had persisted. As our patient refused immunosuppressive therapy, we commenced her on long-term anticoagulation considering the possibility of recurrent PE.

4. Conclusion

Venous thromboembolism, including deep venous thrombosis (DVT) and its most dangerous complication, acute PE, pose a serious threat to health. Due to the high mortality of pulmonary embolism, serious complications may result without timely

diagnosis and treatment. Typical symptoms, including dyspnea and chest pain and corroboratory laboratory findings, including raised levels of D-dimer, beta natriuretic peptide, and troponin-I may suggest pulmonary embolism. Definitive modalities for the diagnosis of pulmonary embolism (PE) include computed tomography (CT) pulmonary angiogram, magnetic resonance pulmonary angiography, ventilation-perfusion scanning, and pulmonary angiography. As one of the markers of endothelial cell injury, von Willebrand factor should be monitored. Our case report highlights the possibility that autoimmune-mediated diseases may increase the risk of DVT and PE. The risk of DVT and PE may vastly increase if immunosuppressive therapy is not administered. Our hypothesis needs to be validated by future studies. Early anticoagulation may need to be considered to reduce mortality due to acute PE in patients who are not on immunosuppressive therapy. The appropriate time for commencement of anticoagulant therapy depends on the clinical status.

Author contributions

All authors diagnosed this disease and collected data, Shan Lin wrote the draft of this article, Wei Guan revised this article. Written consent to publication was obtained.

Data curation: Yan Wang, yingqing shi.

Writing – original draft: Shan Lin.

Writing – review & editing: wei guan.

References

- [1] Li ZY. China guidelines for the diagnosis and treatment of myasthenia gravis. *Neuroimmunol Neuroinflamm* 2016;3:1–9.
- [2] Uzawa A, Kanai T, Kawaguchi N, et al. Changes in inflammatory cytokine networks in myasthenia gravis. *Sci Rep* 2016;6:25886.
- [3] Berrih-Aknin S, Le Panse R. Myasthenia gravis: a comprehensive review of immune dysregulation and etiological mechanisms. *J Autoimmun* 2014;52:90–100.
- [4] Pober JS, Sessa WC. Evolving functions of endothelial cells in inflammation. *Nat Rev Immunol* 2007;7:803–15.
- [5] Cines DB, Pollak ES, Buck CA, et al. Endothelial cells in physiology and in the pathophysiology of vascular disorders. *Blood* 1998;91:3527–61.
- [6] Semeraro N, Ammolto CT, Semeraro F, et al. Sepsis, thrombosis and organ dysfunction. *Thromb Res* 2012;129:290–5.
- [7] Tousoulis D, Kampoli AM, Tentolouris Nikolaos Papageorgiou C, et al. The role of nitric oxide on endothelial function. *Curr Vasc Pharmacol* 2012;10:4–18.
- [8] Nilius B, Droogmans G. Ion channels and their functional role in vascular endothelium. *Physiol Rev* 2001;81:1415–59.
- [9] Rajendran P, Rengarajan T, Thangavel J, et al. The vascular endothelium and human diseases. *Int J Biol Sci* 2013;9:1057–69.
- [10] Ait-Oufella H, Maury E, Lehoux S, et al. The endothelium: physiological functions and role in microcirculatory failure during severe sepsis. *Intensive Care Med* 2010;36:1286–98.
- [11] Kofler S, Nickel T, Michael W. Role of cytokines in cardiovascular diseases: a focus on endothelial responses to inflammation. *Clin Sci* 2005;108:205–13.
- [12] Zhang J, Patel JM, Li YD, et al. Proinflammatory cytokines down-regulate gene expression and activity of constitutive nitric oxide synthase in porcine pulmonary artery endothelial cells. *Res Commun Mol Pathol Pharmacol* 1997;96:71–87.
- [13] Singh U, Devaraj S, Jialal I. Vitamin E, oxidative stress, and inflammation. *Annu Rev Nutr* 2005;25:151–74.
- [14] Gawaz M, Langer H, May AE. Platelets in inflammation and atherogenesis. *J Clin Invest* 2005;115:3378–84.
- [15] Clapp BR, Hingorani AD, Kharbanda RK, et al. Inflammation-induced endothelial dysfunction involves reduced nitric oxide bioavailability and increased oxidant stress. *Cardiovasc Res* 2004;64:172–8.
- [16] Maritim AC, Sanders RA, Watkins JB III. Diabetes, oxidative stress, and antioxidants: a review. *J Biochem Mol Toxicol* 2003;17:24–38.