

EXTRACELLULAR MATRIX REMODELING IN EXPERIMENTAL INTERVERTEBRAL DISC DEGENERATION

CINTIA PEREIRA DE OLIVEIRA¹, LUCIANO MILLER REIS RODRIGUES², MARIA VITÓRIA VENTURA DIAS FREGNI¹, ALBERTO GOTTFRYD³, ANA MARIA MADE⁴, MARIA APARECIDA DA SILVA PINHAL¹

ABSTRACT

Objective: To evaluate the remodeling of the extracellular matrix in intervertebral disc degeneration through the experimental model of intervertebral disc degeneration. **Methods:** The model of disc degeneration induction, using needle 20G and 360° rotation, was applied for 30 seconds between the 6th/7th, and 8th/9th coccygeal vertebrae of Wistar rats. The intermediary level, between the 7th and 8th vertebrae, was taken as control, not being subjected puncture. The distribution of the extracellular matrix components involved in the remodeling and inflammation process, such as proteoglycans (aggrecan, decorin, biglycan), growth factors (TGFβ), heparanase isoforms (HPSE1, HPSE2), metaloproteasom-9 (MMP9) and interleukins (IL-6, IL-10) was analyzed during the post-injury period (15 to 30 days) and in the control group (discs collected immediately after the puncture, day zero). On the 15th day, acute phase of the disease,

a reduced expression of extracellular matrix components had been observed, whilst there were no differences in the interleukins expression. At 30 days, the molecules followed a very similar pattern of expression in the control group (not affected by disc degeneration). **Results:** The results show that during the acute phase significant alterations in the extracellular matrix components occur and in the late phase intervertebral disc returns to a profile similar to noninvolved tissue, probably due to extensive remodeling process of the extracellular matrix that is capable of regenerating the damaged tissue. **Conclusion:** The experimental model used demonstrated the occurrence of significant changes in the extracellular matrix during the period analyzed after induction of intervertebral disc degeneration. **Laboratory investigation.**

Keywords: Intervertebral disc degeneration. Proteoglycans. Interleukins. Rats, Wistar.

Citation: Oliveira CP, Rodrigues LMR, Fregni MVV, Gottfryd A, Made AM, Pinhal MAS. Extracellular matrix remodeling in experimental intervertebral disc degeneration. *Acta Ortop Bras.* [online]. 2013;21(3):144-9. Available from URL: <http://www.scielo.br/aob>.

INTRODUCTION

Intervertebral disc degeneration is a multifactorial process that mainly affects aging individuals, although in some cases it can affect youths as well. The degenerative process frequently results in low back pain, which is often detrimental to the working capacity, and the existing treatments do not prevent its progression, resulting in high costs for the health system both for clinical and surgical treatment. Nowadays, it is known that disc degeneration is due to cellular, biochemical and structural alterations progressing to a reduction in the number of cells in the intervertebral disc and of the extracellular matrix components.¹⁻³ The extracellular matrix of the intervertebral disc is a complex structure, made up of water, proteoglycans, elastic fibers and collagen, mainly types I and II present in the annulus fibrosus (AF). When the high molecular weight proteoglycans (PG) (aggrecan, versican and perlecan) found predominantly in the nucleus pulposus (NP) are negatively charged and bound to

lateral chains with the glycosaminoglycans (GAG), they play a vital role ensuring disc compression resistance during movements. Low molecular weight proteoglycans (decorin, biglycan, fibromodulin and lumican) interact with other extracellular matrix molecules such as collagens and growth factors, signaling processes in disc degeneration.⁴⁻⁶

Heparan sulfate (HS) is a glycosaminoglycan (GAG) that is an important player in extracellular matrix organization. Its chains are cleaved by heparanase (HPSE), an endo-β-glucuronidase, releasing oligosaccharide that potentiate the action of growth factors, cytokines and components involved in angiogenesis and osteogenesis. Studies indicate that heparanase is also involved in other processes, such as cell invasion and inflammation. Two isoforms of this enzyme were described in the literature: heparanase-1 (HPSE1), which has enzymatic activity, and heparanase-2 (HPSE2), whose function is still unknown.⁷⁻⁹ The inflammatory process in disc degeneration is triggered by

All the authors declare that there is no potential conflict of interest referring to this article.

1. Department of Biochemistry, Faculdade de Medicina ABC. Santo André, SP, Brazil.

2. Musculoskeletal System Discipline of Faculdade de Medicina do ABC. Santo André, SP, Brazil.

3. Faculdade de Medicina de Santos. Santos, SP, Brazil.

4. Department of Pathology, Faculdade de Medicina ABC. Santo André, SP, Brazil.

Study conducted at Faculdade de Medicina do ABC. Santo André, SP, Brazil.

Mailing address: Luciano Miller Reis Rodrigues. Rua Borges Lagoa, 1065, São Paulo, SP, Brazil, CEP: 04038-032. luciano.miller@uol.com.br

biochemical mediators such as (TNF- α , prostaglandin E), which stimulate the immunological response, and consequently release proinflammatory cytokines, such as the interleukins (IL-1 β , IL-6, IL-8), and growth factors, causing pain.¹⁰

Metalloproteinases (MMPs) are enzymes that are also involved in extracellular matrix degradation, related to structural alterations of the intervertebral disc.¹¹

In this study, an animal model was used to evaluate the distribution of the main functional and structural extracellular matrix components that are involved in the intervertebral disc degeneration process, aiming to improve the monitoring of the molecules linked to the progression of the disease, achieving a better understanding of the disc degeneration physiopathology. The results will be able to throw light on molecular mechanisms related to the disc degeneration process, evidencing molecules that can be used in the future for diagnosis, prognosis or targeted therapy.

MATERIAL AND METHODS

Animal Model

Three male Wistar (*Rattus norvegicus albinus*) rats aged 12 weeks (complete skeletal maturity), and weighing between 300 and 350 grams were used for the animal model of intervertebral disc degeneration. All the rats were submitted to degeneration induction and only the first animal was euthanized soon after the surgical procedure, classified as control (or Day 0). The second animal was euthanized 15 days after the induction of the intervertebral disc degeneration process and the third animal at 30 days. The animals remained in the care of the vivarium of the faculty between the degeneration induction and the euthanasia. For the intervertebral disc degeneration induction the animal underwent tail antisepsis with an iodized alcohol solution then were anesthetized with an association of ketamine (88 mg/kg) and 2% xylazine (12 mg/kg) administered intraperitoneally. Deep anesthetic plane was confirmed by the absence of corneal reflex and of reaction to the profound pain caused by interdigital compression. The levels between the sixth and seventh and between the eighth and ninth coccygeal vertebrae were identified by palpation. The degeneration induction was performed by percutaneous puncture using a 20G needle. The needle was introduced up to the nucleus pulposus, rotated 360° and kept in the same position for 30 seconds, in accordance with the study by Zhang et al.¹² The intermediary level, located between the seventh and eighth coccygeal vertebrae, was adopted as control, since it was not submitted to puncture. Following confirmation of the deep anesthetic plane, 5mL of arterial blood were drawn from the abdominal aorta, via transabdominal approach, causing euthanasia due to hypovolemic shock. After euthanasia, the tail segments with the discs for study were extracted using a no. 15 scalpel blade. The removed intervertebral discs were stored in properly identified flasks with a formaldehyde solution (10%) and sent to the Molecular Biology laboratory for immunohistochemical analyses. This study was approved in the Committee of Ethics in Animal Experimentation, process 003/2011. It should be noted that the disc degeneration model used on rats reproduces morphological and biochemical alterations that are similar to those observed in the degenerative processes of human intervertebral discs.¹³

Immunohistochemical Analysis

Representative intervertebral disc degeneration areas were chosen based on the staining of the tissue sections with hematoxylin-eosin (HE). Formalin-fixed, paraffin-embedded 3 μ m thick sections were deparaffinized and rehydrated. Antigen recovery was performed by heating the slides to 100°C for 30 minutes in a 10 mmol/L citrate buffer, pH 6.0. Endogenous peroxidase activity was blocked with a 3% hydrogen peroxide aqueous solution for 35 minutes. The sections were then incubated overnight at 4°C with the primary antibodies: anti-HPSE1 (HPA1 L-19), anti-HPSE2 (HPA2 C-17), anti-aggrecan (4F4), anti-decorin (N-15), anti-biglycan (L-15), TGF β 1 (sc-146), anti-MMP-9 (H-129), anti-interleukin-6 (SC-130326) and anti-interleukin-10 (H-160) (Santa Cruz Biotechnology, CA, USA). Finally, the slides were incubated with a peroxidase-labeled streptavidin complex (LSAB[®], DakoCytomation, Glostrup, Denmark) for 30 minutes. The sections were developed using 3,3'-diaminobenzidine (DAB), for 1 minute and were counterstained with hematoxylin. Some samples were incubated with 1M phosphate buffer in the absence of the primary antibody, as negative controls. The presence of brown coloration was considered evidence of positive expression of the respective molecules in the cell.

Digital quantification

The slides were analyzed using of a TS100 Nikon Eclipse[®] light microscope to identify the areas that best represented the immunostaining of the molecules analyzed (hot spots). In each case, the immunostaining quantification was performed using a computer-assisted digital analysis method. The photomicrographs of 640x480 pixels were obtained from non-coincident consecutive fields with magnification of 400X using a 4300 Nikon Coolpix[®] digital camera adjusted to the same parameters. The resulting images were analyzed using the ImageLab[®] image processing and analysis system (Softium Informática[®], São Paulo, Brazil), adjusted to the micrometric scale (μ m).

Positivity index (PI)

In each case, at least 1,000 cells were counted by ImageLab[®], and the observer classified them as positive or negative cells. For this reason, the percentage of marked cells was determined according to the following equation:

$$PI = \frac{\text{number of marked cells}}{\text{total cells counted}} \times 100 \quad [\%]$$

Intensity of expression (ItE)

ImageLab[®] was used to quantify the intensity of the brown color that resulted from the immunostaining. For each case, the same photomicrographs that were used to determine the PI were considered. Twelve cytoplasmic regions of different randomly marked cells were accessed with the same-sized square (a tool of the ImageLab[®] system). The average optical density (OD) of these areas was automatically calculated and represents the mean of the red, green and blue (RGB) color compositions per area of cytoplasm analyzed; the OD was expressed in optical units per square micrometer ($or/\mu\text{m}^2$). the same procedure was applied to obtain the background optical density (BOD) of an area without tissue or vascular space for each photomicrograph. For this purpose, a single area was sufficient, as the background

is homogeneous in each image. The color absolute white that corresponds to the maximum optical density ($320.7 \text{ ou}/\mu\text{m}^2$) is composed of a complete mixture of red, green and blue, while the color black represents the absence of these colors. Therefore, the optical density values calculated by the program involved a decreasing scale, in which the highest values corresponded to the colors that were clearly visible. The equation shown below was used to calculate the immunostaining intensity expression (ItE) in each case. Its values involve an increasing scale that is subtracted from the BOD proportional to the optical density of absolute white.

$$\text{ItE} = 320.7 - \frac{320.7 \times \Sigma \text{DO}}{\Sigma \text{DOF}} \quad [\text{ou}/\mu\text{m}^2]$$

Index of expression (IE)

The index of digital expression (I_{dig}) was obtained by multiplying the percentage of labeled cells (PLC) by the digital immunostaining intensity ($I_{\text{dig}}I$) for each case, according to the following equation:

$$\text{IE} = \frac{\text{PI} \times \text{ItE}}{100} \quad [\text{ou}/\mu\text{m}^2]$$

RESULTS

Sections of the intervertebral disc of each animal were stained with hematoxylin-eosin and analyzed by a pathologist, for evaluation of the histological parameters. It was noted that the alterations were mainly concentrated in the cartilaginous (central) region, except for the presence of neovessels in the fibrous (peripheral) region of the intervertebral disc. The disc degeneration induced at distal level, between the eighth and ninth coccygeal vertebrae, (Table 1) demonstrated moderate levels of apoptosis throughout the degenerative process, besides reduction of the regeneration process in the samples collected 30 days after degeneration induction. Over the course of the degenerative process, the following phenomena were observed in the extracellular matrix: slight presence of calcification, decreased mixoid degeneration, gradual growth of eosinophilic degeneration and formation of neovessels only at 30 days after disc degeneration induction. The degenerated proximal and distal intervertebral discs were collected, but no significant differences were observed between the discs.

The immunostaining analysis for the high molecular weight proteoglycan aggrecan revealed a reduction of 22% in the expression of this proteoglycan, 15 days after intervertebral degeneration induction, in comparison with the control group. However, the results show the occurrence of a 37% increase in the aggrecan expression 30 days after disc degeneration, when compared with the control group. (Figure 1) The expres-

sion levels were confirmed by the digital quantification of the images. (Figure 2)

The low molecular weight proteoglycans, decorin and biglycan, presented notable reduction of expression at 15 days, respectively, 41% and 59%. (Figures 1 and 4) However, 30 days after the induction of the disc degeneration process an increase of 61% was observed in the decorin expression with one of 19% in the biglycan expression, both compared with the control group. The growth factor TGF- β presented considerable reduction (69%), when compared with the intervertebral discs of the animal euthanized at 15 days, after induction of degeneration and control group samples. It is interesting to note that the TGF- β presented significant reduction (24%) of expression at 30 days after disc degeneration in relation to the control group.

The heparanase isoform expression analysis evidenced reduction of 29% in the immunostaining of the anti-heparanase-1 antibody, in the samples obtained on the 15th day after induction of the disc degeneration process, maintaining slight reduction (6%) on the 30th day, in comparison with the control group. (Figure 3) Comparing immunostaining of the heparanase-2 isoform (HPSE2) with the control group, we also observed slight reduction in the expression (4%) on the 15th day and an increase of approximately 15% on the 30th day, after intervertebral degeneration induction. The expression levels were confirmed by the digital quantification of the images. (Figure 4)

Metalloproteinase-9 (MMP-9) presented a reduction of 36% in expression on the 15th day, in comparison to the non-degenerated discs. Once again, an increase of 31% in the MMP-9 expression could be observed on the 30th day, in relation to the control group.

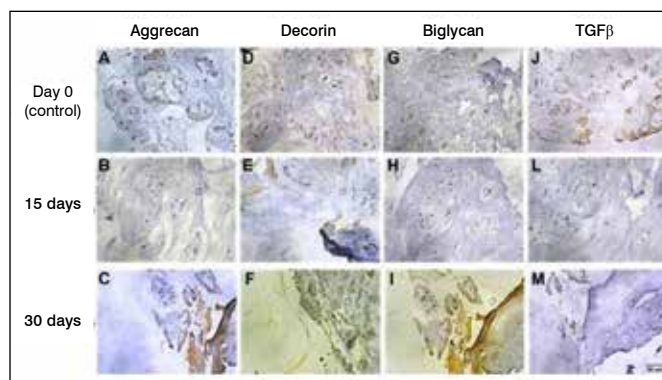


Figure 1. Immunohistochemistry reactions for analysis of expression of proteoglycans and TGF- β . (A, B and C), tissues marked with anti-aggrecan antibody 4F4; (D, E and F), tissues marked with primary antibody anti-decorin N-15; (G, H and I), Tissues marked with primary antibody anti-biglycan L-15; (J, L and M), tissues marked with primary antibody anti-TGF β 1(sc-146).

Table 1. Pathological evaluation after induction of intervertebral disc degeneration in rats.

Days after degeneration induction	Apoptosis	Regeneration	Fracture/Fissure	Calcification	Mixoid Degeneration	Eosinophilic degeneration	Inflammatory Infiltrate	Neovessels
0 days	(++)	(+++)	0	0	(+++)	0	0	0
15 days	(++)	(+++)	0	(+)	(+)	(+)	0	0
30 days	(++)	(+)	0	(+)	(+)	(++)	0	(+)

Grading of the alterations: 0, Absent; (+), Slight; (++) , Moderate; (+++), Intense.

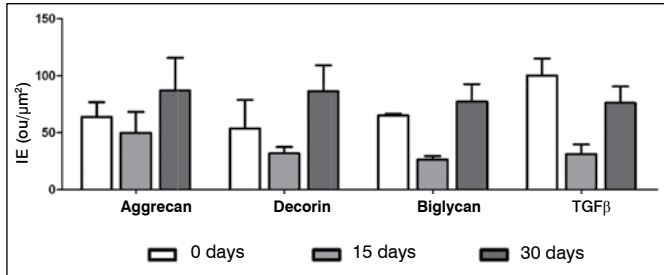


Figure 2. The values indicate the digital quantification of the immunohistochemistry reactions of the proximal and distal intervertebral discs of rats, after 0 days; 15 days and 30 days of degeneration. The values indicate the index of expression (IE), obtained by digital quantification after immunohistochemistry reactions.

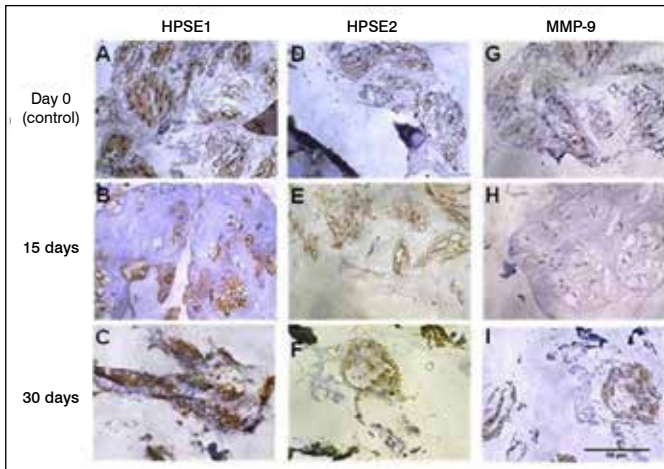


Figure 3. Immunohistochemistry reactions for analysis of expression of heparanase isoforms (HPSE1 and HPSE2) and metalloproteinase-9 (MMP-9). (A, B and C), tissues marked with primary antibody anti-HPSE1 (HPA1 L-19); (D, E and F), tissues marked with primary antibody anti-HPSE2 (HPA2 C-17); (G, H and I), tissues marked with primary antibody anti-MMP-9 (H-129).

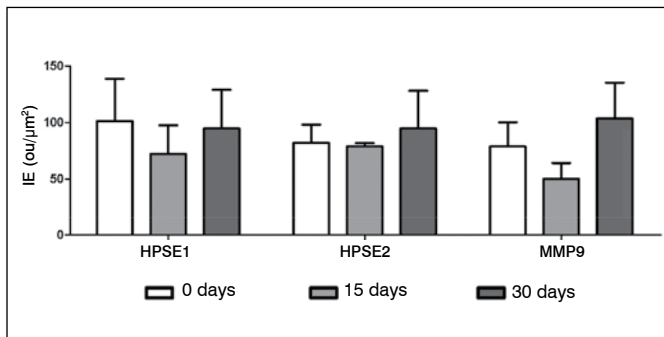


Figure 4. The values indicate the digital quantification of the immunohistochemistry reactions of the proximal and distal intervertebral discs of rats, after 0 days; 15 days and 30 days of degeneration. The values indicate the index of expression (IE), obtained by digital quantification after immunohistochemistry reactions.

As regards the molecules involved in the inflammatory process, the decrease of interleukin-6 (IL-6) expression was clearly evident in the intervertebral disc samples that underwent the degeneration process. Regardless of the time elapsed from induction of the degenerative process, 15 days or 30 days, the

observed decrease was, respectively, (15% and 3%), when compared with the control samples. (Figure 5)

The interleukin-10 (IL-10) expression presented notable reduction at 15 days and slight decrease at 30 days after the induction of the degenerative process, respectively, (51% and 1%) in relation to the control group, as shown in Figure 3. The digital quantification confirms the results obtained in the immunohistochemical reactions. (Figure 6) In general, the analyses of the immunostaining with specific antibodies in the intervertebral disc samples from rats evidenced reduction in the expression of the extracellular matrix components on the 15th day after degeneration induction and, on the 30th day, return to levels close to those observed in the non-degenerated disc samples obtained.

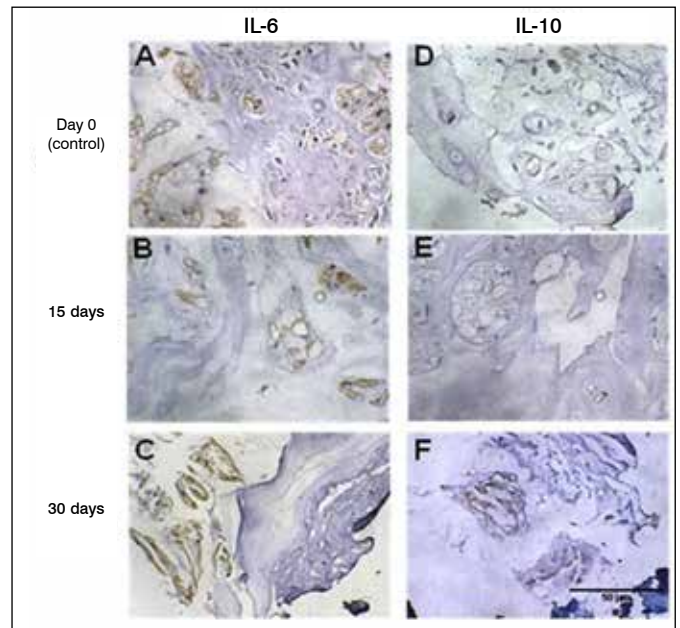


Figure 5. Immunohistochemistry reactions for analysis of the expression of interleukins (IL-6 and IL-10). (A, B and C), tissues marked with primary antibody anti-interleukin-6 (sc-130326); (D, E and F), tissues marked with primary antibody anti-interleukin-10 (H-160).

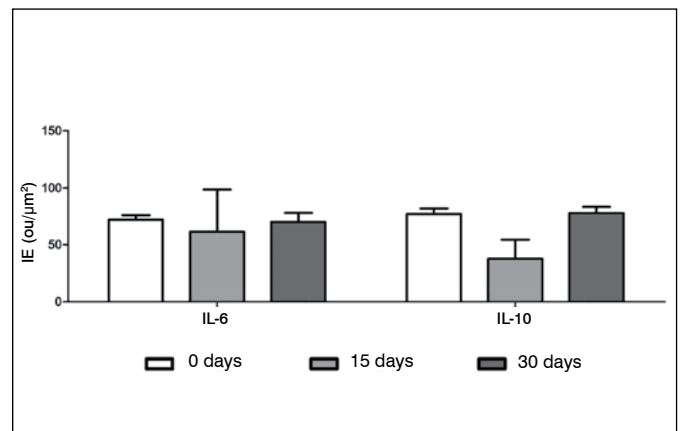


Figure 6. The values indicate the digital quantification of the immunohistochemistry reactions of the distal and proximal intervertebral discs of rats, after 0 days; 15 days and 30 days of degeneration. The values indicate the index of expression (IE), obtained by digital quantification after immunohistochemistry reactions.

DISCUSSION

The results observed in this pilot study of induction of intervertebral disc degeneration in rats show a variation in the expression of the extracellular matrix components in different periods. On the 15th day there was reduction of the expression of extracellular matrix components (proteoglycans, TGF- β), as well as of enzymes that take part in the matrix remodeling process (heparanase and MMP-9), while on the 30th day, the evaluation of the expression of such components was similar to the values obtained in the control group (without disc degeneration).

Thirty days after disc degeneration, we noticed a decrease in the regeneration, calcification and neovessel formation process, characterizing a tissue that had already undergone remodeling when compared at 15 days after the degeneration induction where we noticed intense tissue regeneration.

Data from the literature evidence a decrease in the activity of enzymes involved in degradation of the proteoglycan aggrecan, the aggrecanases, associated with the progression of intervertebral disc degeneration.¹⁴ The results obtained in this study corroborate data from the literature, since there was a significant decrease in the heparan sulfate proteoglycans on the 15th day. Melrose and collaborators also evidenced an increase in biglycan and fibromodulin (low molecular weight proteoglycans), six months after induction of intervertebral disc degeneration in sheep.¹⁵

There are signs that the growth factor TGF- β is associated with the regulation of the expression of low molecular weight proteoglycans, such as biglycan and decorin, resulting in alterations of the extracellular matrix components associated with fibrotic diseases.¹⁶

Sowa et al.¹⁷ demonstrated the difference between the natural aging process of the intervertebral disc and models that produce intervertebral disc degeneration. The behavior of TGF in the disc degeneration induction process was similar to that found in our study. Soon after the degeneration process was induced, a decrease could be noted in the expression levels of the extracellular matrix components, mainly of the proteoglycans decorin and biglycan, followed by an increase in the expression of such compounds as an attempt to repair the injury caused.

HPSE1 is involved in extracellular matrix remodeling processes as it cleaves heparan sulfate chains. The oligosaccharides generated by HPSE1 interact more intensely with growth factors, cytokines and angiogenic factors, and potentiate the action of such components, signaling pathological events. The enzyme HPSE1 also takes part in processes where cartilage is replaced by bone, during endochondral ossification, through the removal of heparan sulfate chains of the proteoglycans. This event is observed for the heparan sulfate proteoglycan, perlecan, directly related to bone remodeling and nucleus pulposus of the intervertebral disc.^{7,18,19}

These data described in the literature confirm the increase in HPSE1 expression observed in our study during the late intervertebral degeneration process (30 days). It is also possible to observe correlation between the expression of HPSE1 and MMP-9, reported by Purushothaman and collaborators.²⁰ Additionally, in a previous study conducted by our group we demonstrated the direct relationship between the degree of

degeneration of the intervertebral disc and HPSE1 expression.⁸ The outcome obtained in this previous study was the first to demonstrate the direct relationship between HPSE1, HPSE2 and the disc degeneration process in humans.⁸

HPSE2 does not have enzymatic activity and its function is still unknown. It was described that HPSE2 can modulate the enzymatic activity of HPSE1.²¹

The fact that the HPSE2 isoform does not present significant alteration of expression at 15 days after the degeneration process can explain the decrease of the HPSE1 isoform expression, which possibly suffers negative modulation by HPSE2.

Holm and collaborators and Akyol and collaborators reported an increase in levels of IL-1, IL-10 and cytokines in late degeneration processes.^{22,23}

Considering that the 30th day, in the experimental model of disc degeneration in adult rats, is equivalent to the late degeneration process, we can affirm that the results found confirm the findings obtained in the literature.

Interleukin-6 (IL-6) is a proinflammatory cytokine involved in symptomatic degenerative processes. A study carried out in 2009 by Holm and cols., with intervertebral disc degeneration in pigs, did not demonstrate increased levels of IL-6 during the degenerative process of the intervertebral disc.²² In this study the participants did not observe any significant alteration of the expression of IL-6 in the degenerated intervertebral discs when compared with the control group either. This result can be justified by the type of inflammation present in the intervertebral disc degeneration process, which corresponds to a chronic inflammatory process. When an acute inflammatory process is involved, there is usually a significant increase in IL-6, yet in chronic inflammatory states this increase is not always observed.

We observed a decrease in IL-10 on the 15th day after degeneration intervertebral induction, suggesting that an inflammatory process may occur in this phase. This result corroborates the literature that demonstrates IL-10 as an anti-inflammatory interleukin in the intervertebral disc.²²

This study demonstrates that in the proposed degeneration model there is a profound change in the various extracellular matrix components. Such results open up several possibilities for future studies for a better understanding of the various factors that act on the intervertebral disc during the development of the degeneration process, evidencing possibilities of future therapies and possible disease prognosis markers.

CONCLUSION

The results show that in the acute phase of the disease (15th day) there were significant alterations of the extracellular matrix components, while in a later phase (30th day), the tissue returned to a molecule expression profile similar to the normal tissue, probably due to the occurrence of an intense extracellular matrix remodeling process.

ACKNOWLEDGMENTS

We are grateful for the financial support that enabled us to conduct this study, granted by Fundação de Amparo à Pesquisa do Estado de São Paulo (FAPESP), Conselho Nacional de Desenvolvimento Científico e Tecnológico (CNPq) and Coordenação de Aperfeiçoamento de Pessoal de Nível Superior (CAPES).

REFERENCES

1. Liang C, Li H, Tao Y, Zhou X, Li F, Chen G, Chen Q. Responses of human adipose-derived mesenchymal stem cells to chemical microenvironment of the intervertebral disc. *J Transl Med*. 2012;10:49.
2. Rodrigues LM, Rachel TT, Mader AM, Milani C, Ueno FH, Pinhal MAS. Análise comparativa Histopatológica entre hernia de disco contida e extrusa. *Coluna/Columna*. 2011; 10 (1): 55-7.
3. Smith LJ, Chiaro JA, Nerurkar NL, Cortes DH, Horava SD, Hebela NM, et al. Nucleus pulposus cells synthesize a functional extracellular matrix and respond to inflammatory cytokine challenge following long-term agarose culture. *Eur Cell Mater*. 2011;22:291-301.
4. Cs-Szabo G, Ragasa-San Juan D, Turumella V, Masuda K, Thonar EJ, An HS. Changes in mRNA and protein levels of proteoglycans of the annulus fibrosus and nucleus pulposus during intervertebral disc degeneration. *Spine (Phila Pa 1976)*. 2002;27(20):2212-9.
5. Pearce RH, Grimmer BJ, Adams ME. Degeneration and the chemical composition of the human lumbar intervertebral disc. *J Orthop Res*. 1987;5(2):198-205.
6. Smith LJ, Nerurkar NL, Choi KS, Harfe BD, Elliott DM. Degeneration and regeneration of the intervertebral disc: lessons from development. *Dis Model Mech*. 2011;4(1):31-41.
7. Brown AJ, Alicknavitch M, D'Souza SS, Daikoku T, Kim-Safran CB, Marchetti D, et al. Heparanase expression and activity influences chondrogenic and osteogenic processes during endochondral bone formation. *Bone*. 2008;43(4):689-99.
8. Rodrigues LM, Theodoro TR, Matos LL, Mader AM, Milani C, Pinhal MA. Heparanase isoform expression and extracellular matrix remodeling in intervertebral disc degenerative disease. *Clinics (Sao Paulo)*. 2011;66(5):903-9.
9. Sela S, Natanson-Yaron S, Zcharia E, Vlodaysky I, Yagel S, Keshet E. Local retention versus systemic release of soluble VEGF receptor-1 are mediated by heparin-binding and regulated by heparanase. *Circ Res*. 2011;108(9):1063-70.
10. Sinclair SM, Shamji MF, Chen J, Jing L, Richardson WJ, Brown CR, et al. Attenuation of inflammatory events in human intervertebral disc cells with a tumor necrosis factor antagonist. *Spine (Phila Pa 1976)*. 2011;36(15):1190-6.
11. Wuertz K, Vo N, Kletsas D, Boos N. Inflammatory and catabolic signalling in intervertebral discs: the roles of NF-KB and MAP kinases. *Eur Cell Mater*. 2012;23:103-19;
12. Zhang H, La Marca F, Hollister SJ, Goldstein SA, Lin CY. Developing consistently reproducible intervertebral disc degeneration at rat caudal spine by using needle puncture. *J Neurosurg Spine*. 2009;10(6):522-30.
13. Masuda K, Aota Y, Muehleman C, Imai Y, Okuma M, Thonar EJ, et al. A novel rabbit model of mild, reproducible disc degeneration by an annulus needle puncture: correlation between the degree of disc injury and radiological and histological appearances of disc degeneration. *Spine (Phila Pa 1976)*. 2005;30(1):5-14.
14. Yurube T, Takada T, Suzuki T, Kakutani K, Maeno K, Doita M, et al. Rat tail static compression model mimics extracellular matrix metabolic imbalances of matrix metalloproteinases, aggrecanases, and tissue inhibitors of metalloproteinases in intervertebral disc degeneration. *Arthritis Res Ther*. 2012;14(2):R51.
15. Melrose J, Smith SM, Fuller ES, Young AA, Roughley PJ, Dart A, et al. Biglycan and fibromodulin fragmentation correlates with temporal and spatial annular remodelling in experimentally injured ovine intervertebral discs. *Eur Spine J*. 2007;16(12):2193-205.
16. Hildebrand A, Romaris M, Rasmussen LM, Heinegård D, Twardzik DR, Border WA, et al. Interaction of the small interstitial proteoglycans biglycan, decorin and fibromodulin with transforming growth factor beta. *Biochem J*. 1994;302 (Pt 2):527-34.
17. Sowa G, Vadalà G, Studer R, Kempel J, Iucu C, Georgescu H, et al. Characterization of intervertebral disc aging: longitudinal analysis of a rabbit model by magnetic resonance imaging, histology, and gene expression. *Spine (Phila Pa 1976)*. 2008;33(17):1821-8.
18. Kram V, Zcharia E, Yacoby-Zeevi O, Metzger S, Chajek-Shaul T, Gabet Y, et al. Heparanase is expressed in osteoblastic cells and stimulates bone formation and bone mass. *J Cell Physiol*. 2006;207(3):784-92.
19. Sanderson RD, Yang Y, Suva LJ, Kelly T. Heparan sulfate proteoglycans and heparanase--partners in osteolytic tumor growth and metastasis. *Matrix Biol*. 2004;23(6):341-52.
20. Purushothaman A, Chen L, Yang Y, Sanderson RD. Heparanase stimulation of protease expression implicates it as a master regulator of the aggressive tumor phenotype in myeloma. *J Biol Chem*. 2008;283(47):32628-36.
21. Levy-Adam F, Feld S, Cohen-Kaplan V, Shteingauz A, Gross M, Arvatz G, et al. Heparanase 2 interacts with heparan sulfate with high affinity and inhibits heparanase activity. *J Biol Chem*. 2010;285(36):28010-9.
22. Holm S, Mackiewicz Z, Holm AK, Kontinen YT, Kouri VP, Indahl A, et al. Pro-inflammatory, pleiotropic, and anti-inflammatory TNF-alpha, IL-6, and IL-10 in experimental porcine intervertebral disk degeneration. *Vet Pathol*. 2009;46(6):1292-300.
23. Akyol S, Eraslan BS, Etyemez H, Tanriverdi T, Hanci M. Catabolic cytokine expressions in patients with degenerative disc disease. *Turk Neurosurg*. 2010;20(4):492-9.