

# Transvaginal Ultrasound-Guided Methotrexate Instillation for Failed Medical Management of Ectopic Pregnancies in Subfertile Women

Nikita Naredi, Sumeet Ranjan Tripathy<sup>1</sup>, Rajesh Sharma<sup>2</sup>

Assisted Reproductive Technology Centre, Military Hospital, Bhopal, Madhya Pradesh, <sup>1</sup>Department of Obstetrics and Gynaecology, AFMC, Pune, Maharashtra, <sup>2</sup>ART Centre, Army Hospital, New Delhi, India

ABSTRACT

**Background:** Ectopic pregnancy (EP) defined as extrauterine implantation of the embryo can be managed medically or surgically. Medical management entails systemic administration of the antineoplastic drug methotrexate (MTX) which, if not successful, surgical management is resorted to. However, we carried out this study wherein the failed medical management cases were given intra-gestational sac MTX instead of surgery. **Aim:** The aim of this study was to assess the efficacy of intra-gestational MTX administration as a treatment modality for failed medical management of ectopic pregnancies. **Study Setting and Design:** It was a prospective interventional study carried out at the Reproductive Medicine Centre of a tertiary care hospital. **Materials and Methods:** It was a prospective interventional study wherein 12 patients of EP with failed medical management (as per established criteria) were administered intra-gestational MTX with follicle aspiration needle under transvaginal sonography guidance. **Statistical Analysis Used:** Data were collected in Microsoft Excel. Numerical continuous variables were expressed as mean  $\pm$  standard deviation. Categorical variables were expressed as count/percentage. **Results:** All the patients responded to the local administration of MTX, with none requiring rescue surgery. In addition, no one had any complication of the local instillation. However, one patient required an additional dose of MTX. **Conclusion:** Intra-gestational MTX administration is a viable non-surgical modality for treatment of ectopic pregnancies even in cases of failed medical management with an added benefit of tubal preservation.

**KEYWORDS:** Ectopic pregnancy, intragestational sac, methotrexate

## INTRODUCTION

Ectopic pregnancy (EP) which is defined as abnormal implantation of the blastocyst outside the endometrial cavity affects 1.5%–2% of all pregnancies increasing to 2%–8% in pregnancies achieved through various nil assisted reproductive techniques (ARTs).<sup>[1,2]</sup> Various risk factors and pathophysiological mechanisms have been postulated for this abnormal embryo implantation ranging from pelvic inflammatory disease, tubal pathology, previous pelvic surgery, to uterine cavity abnormalities.<sup>[3,4]</sup> In spite of its early diagnosis with the advent of high resolution transvaginal sonography (TVS) and highly sensitive beta-human chorionic gonadotropin ( $\beta$ -hCG) assay in the last two decades,

ectopic pregnancy (EP) continues to pose a significant threat to affected women increasing both the morbidity and mortality if not timely intervened and treated. This ectopic implantation of the embryo can occur in any of the sites such as fallopian tubes, ovaries, cervix and caesarean scars, but the fallopian tube continues to be the most common site of extrauterine implantation.<sup>[5]</sup>

EP can be managed both surgically and medically. Classically, treatment of EP involves surgical resection of the diseased tube, ovary or cornual region of the uterus

**Address for correspondence:** Dr. Nikita Naredi,

Assisted Reproductive Technology Centre, Military Hospital, Bhopal - 462 031, Madhya Pradesh, India.  
E-mail: nikitanaledi@gmail.com

Received: 02-01-2022

Revised: 18-02-2022

Accepted: 21-02-2022

Published: 31-03-2022

Access this article online

Quick Response Code:



Website:  
www.jhrsonline.org

DOI:  
10.4103/jhrs.jhrs\_1\_22

This is an open access journal, and articles are distributed under the terms of the Creative Commons Attribution-NonCommercial-ShareAlike 4.0 License, which allows others to remix, tweak, and build upon the work non-commercially, as long as appropriate credit is given and the new creations are licensed under the identical terms.

For reprints contact: WKHLRPMedknow\_reprints@wolterskluwer.com

**How to cite this article:** Naredi N, Tripathy SR, Sharma R. Transvaginal ultrasound-guided methotrexate instillation for failed medical management of ectopic pregnancies in subfertile women. J Hum Reprod Sci 2022;15:90-5.

be it by laparotomy or by laparoscopy. However, with the introduction of medical management and its application in appropriately selected cases, the results achieved are comparable to surgery.<sup>[6]</sup> This conservative or non-surgical management involves systemic administration of the antineoplastic drug methotrexate (MTX) which can be exhibited by various protocols: single-dose, double-dose or multidose protocols.<sup>[7]</sup> The chemotherapeutic agent prevents the proliferation of trophoblastic tissue by inhibiting DNA synthesis. Administration of MTX systemically has been successful in treating primarily cases of early, unruptured, tubal ectopic pregnancies, with a success rate of about 90%.<sup>[7,8]</sup> However, in cases of ectopic pregnancies with the presence of foetal cardiac activity, a failure rate of 30% has been reported using systemic MTX alone.<sup>[7]</sup>

In the event, there is a failed medical management with MTX the option resorted to; is surgery wherein the affected tube or the organ is removed by laparotomy or laparoscopically. In addition to the inherent failure rate with MTX, this antineoplastic drug is not without complications when administered systemically. The potential side effects are bone marrow depression, stomatitis, anorexia, nausea, vomiting and diarrhoea, with an incidence of up to 15%.<sup>[9]</sup> Many workers with the aim of reducing the side effects without compromising the therapeutic efficacy have modified the route of administration of MTX which entails direct intra-gestational sac instillation. This local injection is carried out under ultrasound guidance or laparoscopically.<sup>[10,11]</sup> Although many studies have been carried out on the effectiveness and efficacy of intra-gestational sac MTX administration, no study has been done to see its role in failed medical management.<sup>[10,11]</sup> Thus, we aimed to carry out a study to assess the efficacy of direct local injection of MTX under TVS guidance in cases of failed medical management of EP at our centre.

## MATERIALS AND METHODS

### Study period and study population

The study was conducted at the Assisted Reproductive Technology (ART) Centre of a tertiary care hospital over a period of 3 years from February 2017 to January 2020 after obtaining approval of the institutional Ethical Committee (approval number: AMC 42004/2017/IEC/2 dated January 25, 2017). It was performed in line with the principles of the Declaration of Helsinki (2013).

It was a prospective interventional study wherein all patients who had a failed medical management of EP were included as per the inclusion and exclusion criteria. Written informed consent was taken after the patients were counselled about the procedure, the other

treatment options available, complications and the long post-procedure follow-up period required for the management option and the need for surgery in case of failure or a complication of the drug.

### Inclusion and exclusion criteria

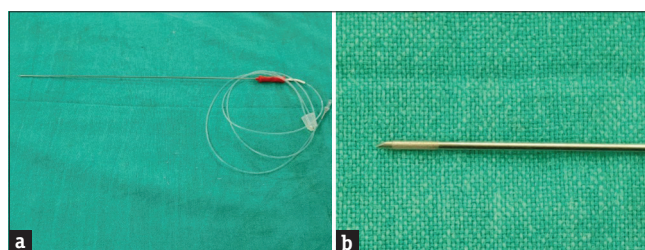
The inclusion criteria for the study were as follows: (a) haemodynamically stable patient and (b) patient consenting for the procedure. The exclusion criteria were as follows: (a) patient not amenable to follow-up and (b) contraindication to MTX (previous reaction, chronic liver or lung disease, blood dyscrasias and peptic ulcer disease).

### Failed medical management

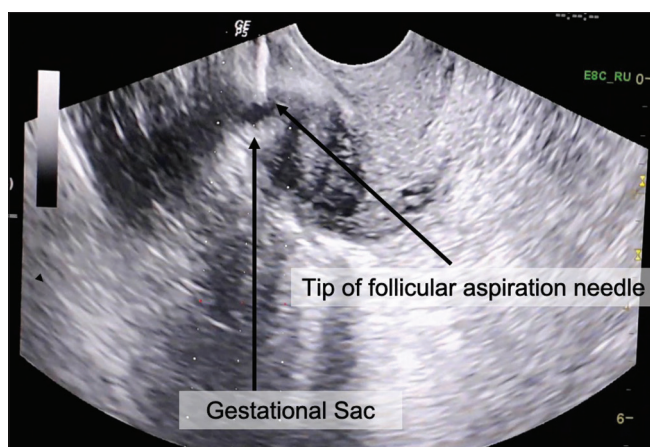
Failed medical management was defined as per the ACOG guidelines.<sup>[12]</sup> It was said to have occurred if the decrease in  $\beta$ -hCG levels was not  $>15\%$  from day 4 to day 7 in cases of single-dose protocol and if there was no decrease in  $\beta$ -hCG levels in spite of four doses.

### Intra-gestational sac methotrexate instillation

The procedure was undertaken under Monitored Anaesthesia Care. The pregnancy was first localised with the transvaginal ultrasound transducer on the ultrasound machine with guide attached to the transducer. A 17G follicular aspiration needle (Follicle Aspiration Set; Cook: Australia) [Figure 1a and b] through the needle guide under TVS guidance was used to advance it into the sac and inject MTX ( $50 \text{ mg/m}^2$ ) into the gestational sac. This dosage was used as per the single-dose protocol<sup>[12]</sup> [Figure 2]. The puncture site was then observed sonographically for 5–10 min to detect procedure-related bleeding and the patient was reassessed after 4 h for any hemoperitoneum. Thereafter, the patient was followed up with serial  $\beta$ -hCG done on days 3 and 7. If there was a fall of more than 15%, then the patient was subsequently followed up with weekly hCG and transvaginal ultrasound till levels were undetectable ( $<5 \text{ mIU/ml}$ ). In case the fall in hCG was  $<15\%$  or there was a rise in levels or there was rupture of the ectopic sac, it was considered treatment failure. In such a case, the patient would be planned for laparoscopic salpingectomy.



**Figure 1:** (a) Follicle aspiration needle. (b) Tip of the follicle aspiration needle



**Figure 2:** The needle in the gestational sac for methotrexate instillation

### Statistical analysis

The data were recorded in Microsoft Excel worksheet and analysed by using statistical software Statistical Package for the Social Sciences (SPSS) Version 24.0 (IBM Corp. Released 2016. IBM SPSS Statistics for Windows, Version 24.0. Armonk, NY, USA: IBM Corp.).

Numerical continuous variables were expressed as mean  $\pm$  standard deviation. Categorical variables were expressed as count/percentage.

### RESULTS

A total of 14 patients had failed medical management during the study period. Two patients underwent surgical management as they denied a long follow-up and hence only 12 were intervened and analysed [Table 1]. The mean age of the patients was 31.5 ( $\pm 3.75$ ) years. Although all the 12 study subjects were subfertile and at various stages of investigation and treatment, their various modes of conception were as follows: 6 (50%) were post-in vitro fertilisation while 4 (33%) were spontaneous conception and 2 (16.6%) had conceived via intrauterine insemination. In all the cases, the extrauterine gestation was tubal.

The mean gestational age at diagnosis was 44.5 ( $\pm 8.06$ ) days. The mean  $\beta$ -hCG value at diagnosis was 2437.5 mIU/ml (range: 890–10010 mIU/ml). Ten (83.6%) patients were managed with multidose MTX, while two (16.6%) were managed with a single-dose regimen prior to being labelled as treatment failure [Table 2].

All the patients underwent MTX instillation in the gestational sac at the dosage of 50 mg/m<sup>2</sup>.  $\beta$ -hCG levels were monitored on day 4 and day 7 post-procedure. In 11 cases, there was a decline in  $\beta$ -hCG levels of more than 15%. They were followed up with weekly  $\beta$ -hCG values. One case had a borderline fall in hCG

levels (14.97%). In view of the borderline decrease in  $\beta$ -hCG and that her initial pre-administration hCG levels were high (10010 mIU/ml), an additional rescue dose of MTX (1 mg/kg) was given by intramuscular route. Subsequent hCG levels in this patient also revealed a steady decline and normalised in 10 weeks' time. The mean time to resolution (hCG <5 mIU/ml) in our study was 39.6 ( $\pm 13.45$ ) days. None of our study group cases had any complication or required any surgical intervention.

### DISCUSSION

Early diagnosis of EP with the usage of sensitive quantitative  $\beta$ -hCG assays and high-resolution transvaginal ultrasound led to a paradigm shift in its management from primarily surgical to a conservative option.<sup>[13,14]</sup> The conservative modality comprised systemic administration of injection MTX, an antineoplastic drug and a folic acid antagonist which prevented the proliferation of trophoblastic tissue.<sup>[15,16]</sup> The status of this medical management protocol had been well established both in terms of cost and its efficacy as a treatment modality.<sup>[17]</sup> Hajenius *et al.* through the first randomised trial comparing MTX treatment and laparoscopic salpingostomy found no difference with respect to primary treatment success, tubal conservation or fertility outcome after completion of treatment.<sup>[18]</sup>

MTX administration as a treatment option for EP was primarily done through the systemic route. However, due to the associated side effects and failure rates, clinicians explored other routes of MTX administration. It was hypothesised and then studied that ultrasound- or laparoscopic-guided direct and local instillation of this chemotherapeutic drug into the gestational sac could enable the practitioner to minimise the use of systemic chemotherapy and its associated side effects.<sup>[10,11]</sup> In addition, it was observed that local instillation was more effective than systemic therapy with MTX in cases of more advanced ectopic gestations, especially if foetal cardiac activity was present.<sup>[19]</sup> This hypothesis of being more efficacious on being instilled locally into the gestational sac was utilised by us in cases with failed medical management.

We carried out intrasac MTX instillation in 12 patients of failed medical management and all of them responded to this rescue therapy. In the literature, most clinicians have used this modality for upfront live ectopic pregnancies and not as a rescue measure for failed medical therapy in contrast to ours where we used it for failed systemic administration. Monteagudo *et al.* in their case series treated 18 live ectopic pregnancies by intra-sac instillation of either potassium chloride (KCl)



or MTX.<sup>[19]</sup> Although MTX is the primary agent used for local administration, KCl has also been used in many centres and found to be equally efficacious.<sup>[19]</sup> However, in our study, we had used only MTX.

The effectiveness of local administration has been proven in many studies since its first application by Feichtinger.<sup>[20]</sup> In the study by Hafner *et al.* of the ten cornual (interstitial) pregnancies, five were treated with local injection and all were successful; the other five were treated with intramuscular injection and only 80% were successful.<sup>[21]</sup> Doubilet *et al.* in their report on the usage of sonographically guided treatment of 27 ectopic pregnancies found a success rate of 93%, with 25 of them being treated successfully.<sup>[22]</sup> Most of the studies and data reflect the use of this treatment tool in various types of ectopic implantation other than tubal, such as cornual, cervical, ovarian and even heterotopic gestation; however, in our case series, all ectopic implantations were tubal.<sup>[19,21,22]</sup>

**Table 1: Clinical characteristics of the study subjects**

Age (years)	Mode of conception	Site of EP	Period of gestation (days from LMP)
28	IVF	Tubal	34 (4 weeks + 6 days)
33	Spontaneous	Tubal	47 (6 weeks + 5 days)
30	IVF	Tubal	36 (5 weeks + 1 days)
31	Spontaneous	Tubal	51 (7 weeks + 2 days)
37	IVF	Tubal	40 (5 weeks + 5 days)
27	Spontaneous	Tubal	50 (7 weeks + 1 days)
30	IUI	Tubal	55 (7 weeks + 6 days)
36	IVF	Tubal	38 (5 weeks + 3 days)
33	IVF	Tubal	37 (5 weeks + 2 days)
25	IUI	Tubal	46 (6 weeks + 4 days)
32	IVF	Tubal	41 (5 weeks + 6 days)
36	Spontaneous	Tubal	59 (8 weeks + 3 days)

IVF=*In vitro* fertilisation, IUI=Intrauterine insemination, EP=Ectopic pregnancy, LMP=Last menstrual period

In spite of the conclusion by most workers that sonographically guided minimally invasive treatment of ectopic pregnancies is an efficacious and safe alternative to surgical and systemic medical therapy, rescue doses of systemic MTX is required in some cases, especially the ones with high  $\beta$ -hCG values. In the series of cases by Monteagudo *et al.*, nine cases required additional dose of intramuscular MTX, with two cases requiring a second dose.<sup>[19]</sup> In this series, the mean quantitative  $\beta$ -hCG level was 33,412 (range: 1239–88,955) mIU/ml as opposed to the mean  $\beta$ -hCG titre of 2,437.5 mIU/ml in our subjects. It has been documented that lower pre-treatment  $\beta$ -hCG values have better response as compared to higher titres explaining the better response in our study. In our series, we had to give an additional systemic dose to only one patient as her initial pre-administration  $\beta$ -levels were high (10,010 mIU/ml). Similar to our case series, Tuncay *et al.* also utilised local treatment under transvaginal ultrasonographic guidance using either KCL or MTX and the treatment was completed without any complications. In their study too, only one case required systemic MTX as an additional management method.<sup>[23]</sup>

A thorough counselling is a prerequisite before planning this procedure as intra-gestational sac puncture and drug instillation are not without risks and complications. Bleeding leading to hemoperitoneum, rupture of the ectopic and infection are a few commonly encountered complications which may require surgical intervention.<sup>[19,21]</sup> In the case series by Andres *et al.*, surgical intervention was required in 2 of their 14 cases as one had a post-puncture hemoperitoneum and the second one had a rupture cornual pregnancy during follow-up.<sup>[24]</sup> In our study group, we did not encounter any complication and did not have to resort to surgery for any of our study subjects. In addition, after the procedure, a prolonged follow-up is required varying

**Table 2: Treatment characteristics of the study group**

MTX regimen	$\beta$ -hCG at diagnosis (mIU/ml)	Pre-instillation $\beta$ -hCG (mIU/ml)	D7 HCG (mIU/ml)	Time to resolution (days)	Additional MTX required	Complications
Multidose regimen	1180	990	760	35	Nil	Nil
Multidose	3455	3320	2690	56	Nil	Nil
Multidose	1020	890	650	21	Nil	Nil
Single dose	1675	1524	1295	42	Nil	Nil
Multidose	1240	1098	850	35	Nil	Nil
Multidose	2360	2070	1560	42	Nil	Nil
Multidose	3215	2800	2010	49	Nil	Nil
Multidose	1050	900	675	28	Nil	Nil
Single dose	1170	1050	810	28	Nil	Nil
Multidose	1525	1280	905	35	Nil	Nil
Multidose	1350	1175	850	35	Nil	Nil
Multidose	10,010	9134	7766	70	Yes	Nil

MTX=Methotrexate, HCG=Human chorionic gonadotropin,  $\beta$ -hCG=Beta-HCG

from 45 to 60 days which might be psychologically distressing for the patient. In a series by Timor-Tritsch, four cases of cornual pregnancies which were managed non-surgically required follow-up with TVS for 47–64 weeks.<sup>[25]</sup> The time to resolution for the non-heterotopic ectopic pregnancies group injected with MTX was  $63 \pm 06$  days in the study by Monteagudo *et al.*<sup>[19]</sup> in contrast to  $39.6 \pm 13.45$  days in our series. This difference in our study population could be explained by the low pre-injection  $\beta$ -hCG titres in our group.

Our study along with the others prove that the local MTX treatment may be more effective in the faster control of trophoblastic proliferation and more cost-effective than surgery.<sup>[26-28]</sup> To the best of our knowledge, this study is the first study where intralesional MTX was used as a rescue therapy for patients with failed systemic MTX administration. Although intralesional MTX is found to be safe and effective, a prolonged follow-up period, delayed onset of infertility treatment in subfertile women, technical expertise for this interventional injection and non-availability of the prescribed dosage for the intra-sac instillation are its limitations. Hence, larger studies are required to firmly establish the protocol including the exact dosages for this modality besides validating its usefulness in the treatment of EP with failed medical management and difficult ectopic implantation sites such as cornual or cervical ectopics.

## CONCLUSION

Intralesional therapy has shown significant success rates. It presently holds the middle ground between radical surgical approaches on one side and the medical management on the other. Our study highlights its effectiveness even in cases of failed medical management, hence providing the clinicians with an additional option before the surgical modality is exercised.

## Financial support and sponsorship

Nil.

## Conflicts of interest

There are no conflicts of interest.

## Data availability statement

The data set used in the current study is available with the corresponding author and the authors are willing to share the data upon reasonable request.

## REFERENCES

- Decler W, Osmanagaoglu K, Meganck G, Devroey P. Slightly lower incidence of ectopic pregnancies in frozen embryo transfer cycles versus fresh *in vitro* fertilization-embryo transfer cycles: A retrospective cohort study. *Fertil Steril* 2014;101:162-5.
- Cheng LY, Lin PY, Huang FJ, Kung FT, Chiang HJ, Lin YJ, *et al.* Ectopic pregnancy following *in vitro* fertilization with embryo transfer: A single-center experience during 15 years. *Taiwan J Obstet Gynecol* 2015;54:541-5.
- Milki AA, Jun SH. Ectopic pregnancy rates with day 3 versus day 5 embryo transfer: A retrospective analysis. *BMC Pregnancy Childbirth* 2003;3:7.
- Refaat B, Dalton E, Ledger WL. Ectopic pregnancy secondary to *in vitro* fertilisation-embryo transfer: Pathogenic mechanisms and management strategies. *Reprod Biol Endocrinol* 2015;13:30.
- Practice Committee of American Society for Reproductive Medicine. Medical treatment of ectopic pregnancy. *Fertil Steril* 2008;90:S206-12.
- Barnhart K, van Mello NM, Bourne T, Kirk E, Van Calster B, Bottomley C, *et al.* Pregnancy of unknown location: A consensus statement of nomenclature, definitions, and outcome. *Fertil Steril* 2011;95:857-66.
- Lipscomb GH, McCord ML, Stovall TG, Huff G, Portera SG, Ling FW. Predictors of success of methotrexate treatment in women with tubal ectopic pregnancies. *N Engl J Med* 1999;341:1974-8.
- Ory SJ, Villanueva AL, Sand PK, Tamura RK. Conservative treatment of ectopic pregnancy with methotrexate. *Am J Obstet Gynecol* 1986;154:1299-306.
- Practice Committee of American Society for Reproductive Medicine. Medical treatment of ectopic pregnancy. *Fertil Steril* 2006;86:S96-102.
- Raughley MJ, Frishman GN. Local treatment of ectopic pregnancy. *Semin Reprod Med* 2007;25:99-115.
- Lin YS, Chen CL, Yuan CC, Wang PH. Successful rescue of an early interstitial pregnancy after failed systemic methotrexate treatment: A case report. *J Reprod Med* 2007;52:332-4.
- American College of Obstetricians and Gynecologists' Committee on Practice Bulletins-Gynecology. ACOG practice bulletin no. 193: Tubal ectopic pregnancy. *Obstet Gynecol* 2018;131:e91-103.
- Lehner R, Kucera E, Jirecek S, Egarter C, Husslein P. Ectopic pregnancy. *Arch Gynecol Obstet* 2000;263:87-92.
- Mol BW, Hajenius PJ, Engelsbel S, Ankum WM, Van der Veen F, Hemrika DJ, *et al.* Serum human chorionic gonadotropin measurement in the diagnosis of ectopic pregnancy when transvaginal sonography is inconclusive. *Fertil Steril* 1998;70:972-81.
- Fernandez H, Benifla JL, Leladier C, Baton C, Frydman R. Methotrexate treatment of ectopic pregnancy: 100 cases treated by primary transvaginal injection under sonographic control. *Fertil Steril* 1993;59:773-7.
- Glock JL, Johnson JV, Brumsted JR. Efficacy and safety of single dose systemic methotrexate in the treatment of ectopic pregnancy. *Fertil Steril* 1994;62:716-21.
- Barnhart KT, Gosman G, Ashby R, Sammel M. The medical management of ectopic pregnancy (a meta-analysis comparing "single dose" and "multidose" regimens). *Obstet Gynecol* 2003;101:778-84.
- Hajenius PJ, Engelsbel S, Mol BW, Van der Veen F, Ankum WM, Bossuyt PM, *et al.* Randomised trial of systemic methotrexate versus laparoscopic salpingostomy in tubal pregnancy. *Lancet* 1997;350:774-9.
- Monteagudo A, Minior VK, Stephenson C, Monda S, Timor-Tritsch IE. Non-surgical management of live ectopic pregnancy with ultrasound-guided local injection: A case series. *Ultrasound Obstet Gynecol* 2005;25:282-8.
- Feichtinger W, Kemeter P. Conservative treatment of ectopic

- pregnancy by transvaginal aspiration under sonographic control and methotrexate injection. *Lancet* 1987;1:381-2.
21. Hafner T, Aslam N, Ross JA, Zosmer N, Jurkovic D. The effectiveness of non-surgical management of early interstitial pregnancy: A report of ten cases and review of the literature. *Ultrasound Obstet Gynecol* 1999;13:131-6.
  22. Doubilet PM, Benson CB, Frates MC, Ginsburg E. Sonographically guided minimally invasive treatment of unusual ectopic pregnancies. *J Ultrasound Med* 2004;23:359-70.
  23. Tuncay G, Karaer A, Coskun EI, Melekoglu R. Treatment of unruptured cornual pregnancies by local injections of methotrexate or potassium chloride under transvaginal ultrasonographic guidance. *Pak J Med Sci* 2018;34:1010-3.
  24. Andrés MP, Campillos JM, Lapresta M, Lahoz I, Crespo R, Tobajas J. Management of ectopic pregnancies with poor prognosis through ultrasound guided intrasacular injection of methotrexate, series of 14 cases. *Arch Gynecol Obstet* 2012;285:529-33.
  25. Timor-Tritsch IE, Monteagudo A, Matera C, Veit CR. Sonographic evolution of cornual pregnancies treated without surgery. *Obstet Gynecol* 1992;79:1044-9.
  26. Oyawoye S, Chander B, Pavlovic B, Hunter J, Gadir AA. Heterotopic pregnancy: Successful management with aspiration of cornual/interstitial gestational sac and instillation of small dose of methotrexate. *Fetal Diagn Ther* 2003;18:1-4.
  27. Cerveira I, Costa C, Santos F, Santos L, Cabral F. Cervical ectopic pregnancy successfully treated with local methotrexate injection. *Fertil Steril* 2008;90:2005.e7-10.
  28. Tamarit G, Lonjedo E, González M, Tamarit S, Domingo S, Pellicer A. Combined use of uterine artery embolization and local methotrexate injection in interstitial ectopic pregnancies with poor prognosis. *Fertil Steril* 2010;93:1348.e1-4.