

Mid-term results of hybrid arch repair for DeBakey type I aortic dissection

Liang Zhang¹, Zhan Peng¹, Cuntao Yu², Xiubin Yang¹, Juntao Qiu², De Wang²

¹Department of Cardiac Surgery, Beijing Anzhen Hospital, Beijing Institute of Heart, Lung and Blood Vessel Disease, Capital Medical University, Beijing 100029, China;

²The State Key Laboratory of Cardiovascular Disease, Fuwai Hospital, National Center for Cardiovascular Disease, Chinese Academy of Medical Sciences and Peking Union Medical College, Beijing 100037, China.

To the Editor: Total aortic arch replacement (TAR) is a surgical procedure associated with significant perioperative risks, leading to a higher rate of mortality and neurologic complications. Ascending aortic or hemiarch replacement is associated with less complicated procedures, which can be used to effectively resect the proximal intimal tear and potentially improve the survival rates in these patients.^[1] Hybrid aortic repair, combining open-chest surgery and stent placement has been effectively used in patients with an aortic arch aneurysm.^[2] Although a hybrid technique is often followed, only a limited number of studies with a small number of cases have investigated the application of this procedure for the treatment of type I aortic dissection.^[1,2] This study aimed to evaluate the early and mid-term safety and efficacy of the hybrid technique in this cohort by analyzing a large sample size.

The study was approved by the Ethics Committee of Fuwai Hospital (No. 2015025) and complied with the *Declaration of Helsinki*. The study group obtained written informed consent from each patient before they participated in the study. The clinical data were collected during January 2010 and December 2016 from Fuwai Hospital. Patients were divided into two groups depending on the surgical techniques; the frozen elephant trunk (FET) group involved 815 (86.9%) patients who performed traditional TAR combined with FET; also, the hybrid group included 122 (13.1%) patients with hybrid TAR. The exclusion criteria for the hybrid procedure were as follows: (i) the patients' age <50 years and (ii) the patients who had severe compression for the true lumen of the descending aorta caused by the false lumen. The definition of the composite complication included new-onset kidney failure, operative death, and persistent nerve system damage. Our patients were followed up by standardized forms during telephone or face-to-face interview.

For the surgery techniques in the FET group, the clamp was removed after deep hypothermic circulatory arrest (DHCA), and the aortic arch was transected proximal to the left subclavian artery, then three brachiocephalic vessels were separately clamped. FET stent graft was implanted directly into the true lumen of the descending aorta, the distal end of a tetrafurcate graft was anastomosed to the distal end of the aortic arch, which incorporating FET stent graft. The left common carotid artery, the innominate artery, and the left subclavian artery were then respectively conducted. Finally, the artificial vessel was anastomosed to the ascending aorta [Figure 1A]. For the hybrid group, the aortic cross-clamp was used between the opening of the innominate artery and the left common carotid artery after the nasopharyngeal temperature lowered to 28°C, then the ascending aorta were removed. The tetrafurcate graft was then sutured to the aortic arch, subsequently sutured to the innominate artery and ascending aorta. The other two branches were sutured to the left common artery, and the left subclavian artery. The cardiopulmonary bypass (CPB) was discontinued, then the guiding wire and sheath were advanced retrogradely, the stent was implanted, and the proximal part was anchored to the artificial vessel [Figure 1B].

Statistical analyses were performed using SAS 9.4 software (SAS Institute Inc., Cary, NC, USA). Continuous variables were analyzed using a *t*-test or rank-sum test, whereas classification variables were analyzed using a Chi-square test and Fisher exact test. All tests were two-sided, with a confidence level of $\alpha = 0.05$; a *P* value < 0.05 was considered statistically significant. There were 109 pairs of patients selected from the two groups by using a 1:1 matched pair design. The composite of complications and post-operative death were analyzed by the Multivariable

Access this article online

Quick Response Code:



Website:
www.cmj.org

DOI:
10.1097/CM9.0000000000001556

Correspondence to: Cuntao Yu, The State Key Laboratory of Cardiovascular Disease, Fuwai Hospital, National Center for Cardiovascular Disease, Chinese Academy of Medical Sciences and Peking Union Medical College, 167 Beilishi Road, Beijing 100037, China
E-Mail: fwcuntao@126.com

Copyright © 2021 The Chinese Medical Association, produced by Wolters Kluwer, Inc. under the CC-BY-NC-ND license. This is an open access article distributed under the terms of the Creative Commons Attribution-Non Commercial-No Derivatives License 4.0 (CCBY-NC-ND), where it is permissible to download and share the work provided it is properly cited. The work cannot be changed in any way or used commercially without permission from the journal.

Chinese Medical Journal 2022;135(4)

Received: 21-03-2021; Online: 19-05-2021 Edited by: Lishao Guo

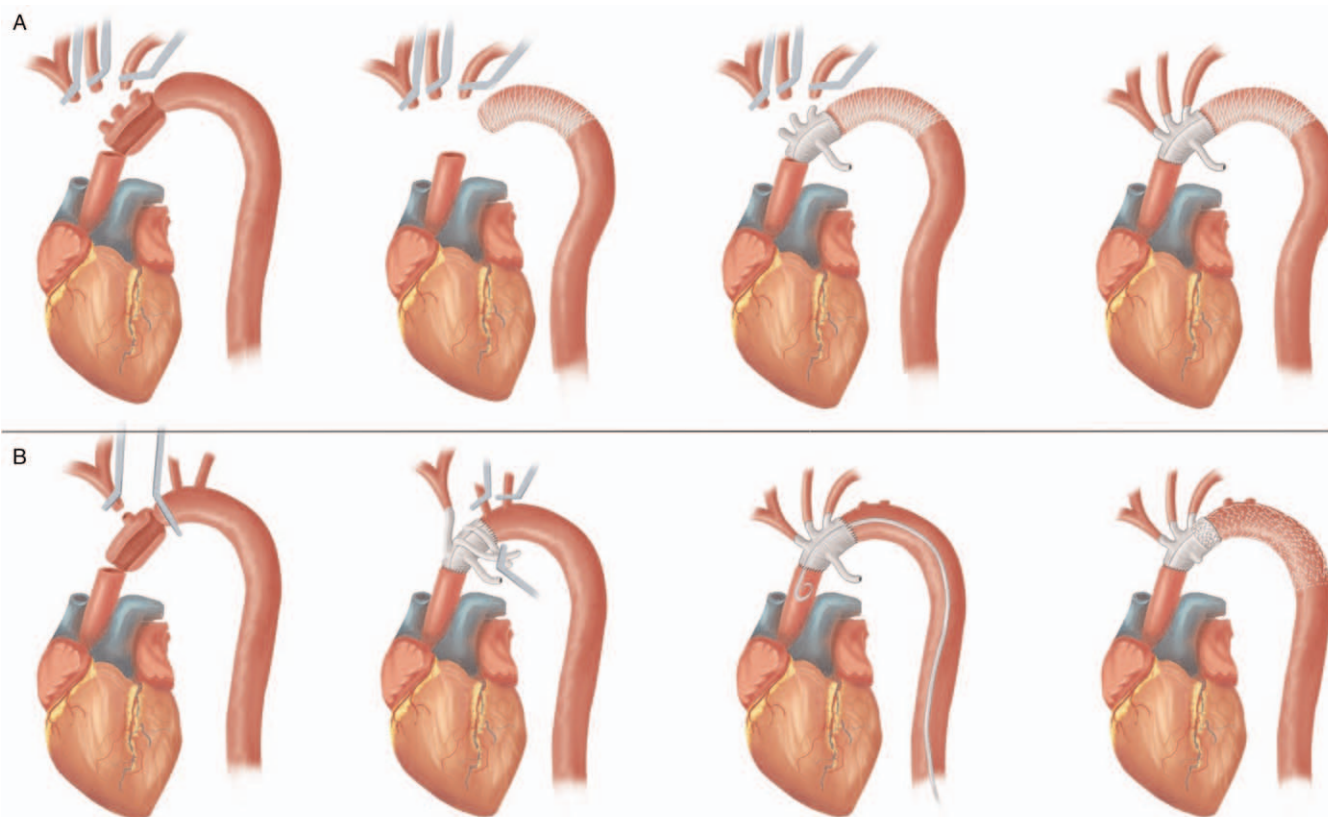


Figure 1: Surgery techniques in the Frozen elephant trunk (FET) group and the hybrid group. (A) After deep hypothermic circulatory arrest (DHCA) was instituted, the clamp on ascending aorta was removed and the aortic arch was transected proximal to the left subclavian artery, then three brachiocephalic vessels were separately clamped. FET stent graft was implanted into the true lumen of the descending aorta under direct vision. The distal end of a tetrafurcate graft was anastomosed to the distal end of the aortic arch, incorporating the stented graft. Anastomoses of the left common carotid artery, left subclavian artery, and innominate artery were then conducted. Finally, the proximal end of the artificial vessel was anastomosed to the ascending aorta. (B) After nasopharyngeal temperature was lowered to 28°C, the aortic cross-clamp was used between the opening of the innominate artery and the left common carotid artery, ascending aorta were removed. The distal end of a tetrafurcate graft was then sutured to the proximal aortic arch, subsequently the innominate artery and the proximal end of the graft to the ascending aorta. The other two branches were sequentially anastomosed with the left common artery, left subclavian artery. Then the guiding wire and sheath were advanced retrogradely, the stent was implanted and the proximal part was anchored to the artificial vessel to complete the arch repair.

logistic models for the two groups. The Kaplan-Meier analysis was used to estimate post-operative survival.

The patients' average age in the hybrid group was 61.3 years, which was significantly higher than the FET group (61.3 *vs.* 46.7 years, $P < 0.001$). Cardiac malperfusion and aortic valve insufficiency were more frequently observed in the FET group (9.3% *vs.* 3.3% and 14.4% *vs.* 4.9%). The other clinical manifestations had no significant differences between the two groups [Supplementary Table 1, <http://links.lww.com/CM9/A593>]. The average diameter and the length of the stent were 30.3 ± 6.4 and 190.5 ± 25.5 mm, respectively. There were no significant differences in combined surgical procedures after propensity score matching between the two groups, but time of surgery, cross-clamping, and CPB were shorter in the hybrid group ($P < 0.05$) [Supplementary Table 2, <http://links.lww.com/CM9/A593>]. The early mortality had no significant difference between the two groups (9.0% *vs.* 10.7%, $P = 0.577$). There was no spinal cord injury in the hybrid group, having a lower incidence of post-operative renal and liver insufficiency in the hybrid group ($P = 0.013$, $P = 0.022$, and $P = 0.014$, respectively) after matching. Additional information is displayed in Supplementary Table 3, <http://links.lww.com/CM9/A593>.

We followed up 778 patients for an average of 36.8 months; 28 (3.6%) patients underwent redo surgery and 40 (5.1%) died. For the patients who performed redo surgery, 19 (76%) underwent thoracoabdominal aortic replacement, five (20%) received ascending aorta anastomosis surgery, and one (4%) underwent root replacement in the FET group. One underwent repeat root replacement, and two underwent ascending aorta anastomosis surgery in the hybrid group. After propensity score matching, the post-operative 1-, 3-, and 5-year survival rates were 80.7%, 76.9%, and 74.6% in the FET group, respectively, and 87.9%, 86.3%, and 82.2% in the hybrid group, respectively ($P = 0.086$) [Supplementary Figure 1, <http://links.lww.com/CM9/A593>].

It was previously demonstrated that the hybrid procedure can be implemented for the treatment of true aortic arch aneurysms, pseudoaneurysms, and other aortic lesions under normal temperature.^[3] The intravascular placement of stents on zone 0 of the native aorta would increase the risk of dissection, especially when the diameter of the ascending aorta is higher than 40 mm.^[4] Hybrid TAR in our group eliminated those risks, due to the placement of the stent on the graft. However, the type Ia endoleaks are often inevitable because of the incomplete apposition of the

stent-grafts to the lesser curvature of the aortic arch, resulting in a bird beak defect.^[5] Besides, nine cases of type I endoleak were noted in our cohort; these endoleaks resolved without any further intervention, as shown by imaging evaluation 3 months post-surgery.

Our results showed a better trend for total mortality rate and the composite of complications in the hybrid group, although those differences were not statistically significant. Furthermore, the hybrid technique had less interfere on the liver and kidney function, which reduced the incidence of post-operative liver and kidney dysfunction. The association between DHCA and the risk of stroke has been controversial in the literature.^[6] In our center, we carried out moderate hypothermia to avoid potential damage from DHCA in the hybrid group. Because DHCA can increase CPB time and usage of blood products, both of which might cause neurologic injury. Placing a longer stent in the dissected descending aorta could effectively promote remodeling of distal false lumens but may increase the risk of spinal cord ischemia (SCI).^[7] Our results showed that there was no paraplegia in the hybrid group, although longer coverage of descending aorta was observed in the hybrid group compared with the FET group. Although we exactly did not know why a lower SCI occurred in the hybrid group than the FET group, we observed a lower CPB time and less usage of blood products, both of which might had protection for SCI.

To conclude, the one-stage hybrid arch repair is associated with acceptable early and mid-term morbidity and mortality rates, offering more options for patients with DeBakey type I aortic dissection, but the long-term clinical outcome still need to be explored.

Conflicts of interest

None.

References

1. Velayudhan BV, Idhrees M, Matalanis G, Park KH, Tang D, Sfeir PM, *et al.* Current status in decision making to treat acute type A dissection: limited versus extended repair. *J Cardiovasc Surg (Torino)* 2020;61:268–271. doi: 10.23736/S0021-9509.20.11397-1.
2. Bavaria J, Vallabhajosyula P, Moeller P, Szeto W, Desai N, Pochettino A. Hybrid approaches in the treatment of aortic arch aneurysms: postoperative and midterm outcomes. *J Thorac Cardiovasc Surg* 2013;145:S85–S90. doi: 10.1016/j.jtcvs.2012.11.044.
3. Zheng J, Xu SD, Zhang YC, Zhu K, Gao HQ, Zhang K, *et al.* Association between cardiopulmonary bypass time and 90-day postoperative mortality in patients undergoing arch replacement with the frozen elephant trunk: a retrospective cohort study. *Chin Med J* 2019;132:2325–2332. doi: 10.1097/CM9.0000000000000443.
4. Geisbüsch P, Kotelis D, Müller-Eschner M, Hyhlik-Dürr A, Böckler D. Complications after aortic arch hybrid repair. *J Vasc Surg* 2011;53:935–941. doi: 10.1016/j.jvs.2010.10.053.
5. Kotha VK, Herget EJ, Appoo JJ. Complications at the proximal landing zone of endovascular stent grafts deployed in surgically replaced ascending aorta. *Ann Thorac Surg* 2016;102:1490–1497. doi: 10.1016/j.athoracsur.2016.04.046.
6. Piazza M, Squizzato F, Milan L, Miccoli T, Grego F, Antonello M, *et al.* Incidence and predictors of neurological complications following thoracic endovascular aneurysm repair in the global registry for endovascular aortic treatment. *Eur J Vasc Endovasc Surg* 2019;58:512–519. doi: 10.1016/j.ejvs.2019.05.011.
7. Chung JC, Lodewyckx CL, Forbes TL, Chu MWA, Peterson MD, Arora RC, *et al.* Prevention and management of spinal cord ischemia following aortic surgery: a survey of contemporary practice. *J Thorac Cardiovasc Surg* 2020;159:e1–e8. doi: 10.1016/j.jtcvs.2020.03.034.

How to cite this article: Zhang L, Peng Z, Yu C, Yang X, Qiu J, Wang D. Mid-term results of hybrid arch repair for DeBakey type I aortic dissection. *Chin Med J* 2022;135:493–495. doi: 10.1097/CM9.0000000000001556