

^{18}F -Fluorodeoxyglucose-positron Emission Tomography/Computed Tomography Imaging of Metastatic Nasopharyngeal Cancer with Emphasis on the Distribution of Bone Metastases

Ammad Shanoon Al Tamimi, Sumbul Zaheer¹, David Chee Ng¹, Saabry Osmany²

Department of Radiology, Harvard Medical School, Division of Nuclear Medicine and Molecular Imaging, Massachusetts General Hospital, Boston, MA, USA, ¹Department of Nuclear Medicine and PET, Singapore General Hospital, ²RadLink PET and Cardiac Imaging Centre, RadLink Diagnostic Imaging, Singapore

Abstract

Distant metastases change the prognosis of patients with nasopharyngeal carcinoma (NPC) which most commonly metastasizes to the bone. ^{18}F -fluorodeoxyglucose (^{18}F -FDG) positron emission tomography/computed tomography (PET/CT) is reported as useful in imaging NPC metastases. Our study assesses the incidence and distribution of bone metastases detected by ^{18}F -FDG PET/CT in NPC. 717 ^{18}F -FDG PET/CT scan reports of histologically proven NPC patients imaged in Singapore General Hospital, Singapore, between 2003 and 2009 were reviewed for the total number of metastases (scanned from vertex to mid-thigh) and analyzed for distribution. Of the 709 FDG avid metastases in these reports, 357/709 (50.35%) were locoregional nodal metastasis and 352/709 (49.65%) were distant metastases of which 192/709 (27.08%) of total metastases and 54.54% of distant metastases (192/352) were in the bones. The majority of the bone lesions 125/192 (65.1%) were in the axial skeleton with 109/192 (56.77%) in the lower skeleton (thoracolumbar spine, sacrum, and pelvis). The incidence of bone metastases in our study (27.08%) was higher than that reported in other studies, for example, 15% by Liu *et al.* and 11% (230 patients) by Caglar *et al.* Bone metastases have been reported in the femurs and the feet and as such some metastases may have been outside the field of view of the scans. In our study, 27% of FDG avid NPC metastases are in the bones.

Keywords: Bone metastases, nasopharyngeal carcinoma, positron emission tomography/computed tomography

Introduction

Nasopharyngeal carcinoma (NPC) is an epithelial neoplasm that shows endemic distribution. The highest prevalence rates are in the South-Eastern Asia including Malaysia, Indonesia, Singapore, and South-Eastern China.^[1] It is

considered a rare tumor of head and neck occurring in 10–30 persons per 100,000 people per year.^[2] The etiology of the disease is linked with the Epstein-Barr virus (EBV).^[3]

NPC has the highest rate of lymph node and/or distant metastasis among the head and neck tumors^[4] with distant metastasis most commonly affecting the bones (approaching 70–80%) followed by the liver (30%) then the lungs (18%).^[3,5,6] Bone metastases are reported to be

Address for correspondence:

Dr. Ammad Shanoon Al Tamimi, Department of Radiology, Harvard Medical School, Division of Nuclear Medicine and Molecular Imaging, Massachusetts General Hospital, 55 Fruit Street, White 427, Boston, MA, USA.
E-mail: he77@hotmail.com

Access this article online

Quick Response Code:



Website:
www.wjnm.org

DOI:
10.4103/1450-1147.207273

This is an open access article distributed under the terms of the Creative Commons Attribution-NonCommercial-ShareAlike 3.0 License, which allows others to remix, tweak, and build upon the work non-commercially, as long as the author is credited and the new creations are licensed under the identical terms.

For reprints contact: reprints@medknow.com

How to cite this article: Al Tamimi AS, Zaheer S, Ng DC, Osmany S. ^{18}F -fluorodeoxyglucose-positron emission tomography/computed tomography imaging of metastatic nasopharyngeal cancer with emphasis on the distribution of bone metastases. World J Nucl Med 2017;16:192-6.

the most frequent site of distant failure causing 30% of deaths in advanced disease with studies suggesting that the sites and number of bone metastasis may be prognostic indicators for survival.^[7] Growing evidence shows that long-term survival and complete response can be obtained among a small proportion of patients with bone metastasis, especially those patients with a solitary lesion who received aggressive treatment.^[8] Hence, the detection of distant metastases including bone metastases is crucial in the management and prognosis of NPC patients.

NPC is usually investigated by physical examination and direct nasopharyngeal endoscopy with biopsy. Locoregional involvement is evaluated by computed tomography (CT) or magnetic resonance imaging (MRI) scans. Distant metastases are assessed by plain chest radiographs, ultrasonography of the liver and bone scintigraphy.^[9] Recently, positron emission tomography (PET)/CT with ¹⁸F-fluorodeoxyglucose (¹⁸F-FDG) is performed as a routine procedure for diagnosing, staging, recurrence, and follow-up of NPC patients. In addition, it is used to assess local residual disease and response to treatment.

The aim of this study is to evaluate the imaging of the distribution of bone metastases in NPC with ¹⁸F-FDG PET/CT.

Materials and Methods

The patients

We reviewed the reports of ¹⁸F-FDG PET/CT scans of histologically proven NPC patients performed in the Nuclear Medicine and PET Department, Singapore General Hospital, Singapore, between 2003 and 2009 using the Nuclear Medicine Information System. The study was approved by the SingHealth Centralized Institutional Review Board. The scans were interpreted by nuclear medicine physicians.

We excluded all patients with additional second malignancies from the study. We analyzed the reports of patients with more than one PET/CT scan between 2003 and 2009 individually. We analyzed the data from the reports for the following:

- Study indication (staging, response to treatment, recurrence, and follow-up)
- Locoregional nodal involvement
- Distant metastases, if any and their sites
- Sites of any bone lesions were carefully assessed and further analyzed for distribution.

¹⁸F-fluorodeoxyglucose positron emission tomography/computed tomography scan

All patients fasted overnight or at least 6 h prior to the scan and received between 333 and 518

MBq (9 and 14 mCi) of ¹⁸F-FDG calculated based on body weight. PET/CT system (Biograph, Siemens, LSO crystals) was utilized for image acquisition. A low dose single slice CT with a slice thickness of 5 mm, KVp from 80 to 130, and mAs range 200–400 was done from the vertex of the skull to mid-thigh followed by PET acquisition in the same area at 3 min per bed position. The CT data were utilized for attenuation correction and anatomical correlation. The PET data underwent iterative reconstruction (24 subsets, 3 iterations). Intravenous contrast was given when requested by the referring physician.

Metastases determination

We considered all metastasis to be present if noted on the report. We considered all the equivocal lesions as negative though follow-up reports within the targeted period were reassessed and were used to upgrade the equivocal lesions if later turn to be positive.

Results

Patient demographics

A total of 722 reports of ¹⁸F-FDG PET/CT scans performed on NPC patients imaged between 2003 and 2009 were reviewed. Five patients with additional concurrent primary malignancies were excluded, and a total of 717 reports (628 patients) were included in the final analysis. Five hundred and fourteen patients were male and 203 were female [Table 1]. The majority were between 45 and 55 years of age.

The ethnic groups of the patients are listed in [Table 2].

The noted indications for the FDG PET/CT studies are listed in [Table 3].

The total number of FDG avid metastatic lesions in these reports was 709. Of these, 357/709 (50.35%) were

Table 1: Age distribution of patients

Age	Number of reports	Percentage of total (%)
>35	41	5.72
35-44	181	25.24
45-55	291	40.59
>55	204	28.45
Total	717	100.00

Table 2: The patient ethnic groups

Ethnic group	Number of reports	Percentage of total (%)
Chinese	614	85.63
Malay	13	1.81
Indians	1	0.14
Others	89	12.41
Total	717	100.00

locregional nodal metastases (retropharyngeal 115, cervical 226, and supraclavicular 16) [Table 4].

Distant metastases represented 352 (49.65%) of the 709 lesions. Of these, 192 were bone lesions (27.08%).

The distribution of bone lesions is cervical spine (13/192, 6.77%), clavicles (7/192, 3.65%), ribs (23/192, 11.98%), sternum (8/192, 4.17%), scapulae (13/192, 6.77%), humerus (6/192, 3.13%), thoracic spine (26/192, 13.54%), lumbar spine (27/192, 14.06%), sacrum (28/192, 14.58%), pelvic bones (28/192, 14.58%), and femora (13/192, 6.77%) [Table 5].

Discussion

NPC is an epidermoid-origin malignant neoplasm classified by the World Health Organization in two histological types of differentiated nonkeratinizing carcinoma (type II) and undifferentiated carcinoma (type III).^[6] It is a squamous cell carcinoma with very aggressive behavior, high incidence of locoregional lymph node, and distant metastasis at presentation.

Although that NPC is considered radiosensitive and curable, the 1-year mortality rate can reach 90% when

distant metastasis is present at the presentation.^[9] In patients with NPC, the presence of distant metastasis influences prognosis and treatment, so accurate evaluation of distant metastases is essential for the management.

Our study showed that about half of the metastatic lesions are at distant sites and that 192 (27%) of the 709 FDG avid metastases were in the bones.

Our incidence of bone metastases is slightly higher than other existing studies, for example, 15% by Liu *et al.*^[6] and 11% (230 patients) by Caglar *et al.*^[10]

The majority of the bone lesions 125/192 (65%) are in the axial skeleton with 109/192 (57%) in the lower skeleton (thoracolumbar spine, sacrum, and pelvis) Figure 1.

Bone metastases have even been reported in the femora and the feet^[11] and as such some metastases in our study may have been outside the field of view of the scans.

¹⁸F-FDG PET/CT is reported as useful in imaging NPC bone metastases^[3,12] though there is controversy when comparing its usefulness relative to other modalities.

Vellayappan *et al.* conclude that for newly diagnosed NPC, ¹⁸F-FDG PET/CT is accurate in N and M staging but not T staging. They recommend using ¹⁸F-FDG PET/CT, together with MRI of the nasopharynx, in routine staging of NPC.^[13]

A study comparing ¹⁸F-FDG PET/CT with ¹⁸F-sodium fluoride (¹⁸F-NaF) PET/CT and bone scintigraphy showed that ¹⁸F-NaF PET/CT is superior in detecting bone metastases followed by ¹⁸F-FDG PET/CT which was superior to technetium-99m based bone scintigraphy.^[14]

Yang *et al.* showed that although ¹⁸F-FDG PET/CT is superior at lesion level, there was no statistical difference between ¹⁸F-FDG PET/CT and planar bone scintigraphy in detecting bone metastases in NPC.^[12]

Table 3: The indication for the scan

Indication	Number	Percentage of total (%)
Staging	217	30.26
Response	35	4.88
Recurrence	227	31.67
Follow-up	238	33.19
Total	717	100.00

Table 4: The distribution of locoregional nodes

Nodal station	Number	Percentage of total (%)
Retropharyngeal	115	32.21
Cervical	226	63.31
Supraclavicular	16	4.48
Total	357	100.00

Table 5: The distributions of bone metastases

Site	Number	Percentage of total
C-spine	13	7
Clavicles	7	3
Ribs	23	12
Sternum	8	4
Scapulae	13	7
Humerus	6	3
T-spine	26	13
L-spine	27	14
Sacrum	28	15
Pelvic bones	28	15
Femur	13	7

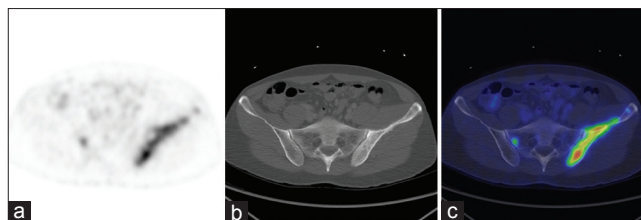


Figure 1: ¹⁸F-fluorodeoxyglucose positron emission tomography/computed tomography scan at the same transaxial level (a-c) show large fluorodeoxyglucose avid sclerotic lesion in the right pelvic bone and another small lesion in the sacrum

Recent meta-analysis by Wei *et al.* comparing ^{18}F -FDG PET/CT, MRI, and single photon emission computed tomography (SPECT) in the diagnosis of local residual/recurrent NPC showed that SPECT and PET/CT are superior to MRI for the detection of local residual/recurrent NPC, and the addition of CT to PET will not significantly improve the diagnostic accuracy. They also concluded that ^{201}Tl -SPECT and MIBI-SPECT have the same diagnostic accuracy.^[15]

Huang *et al.* evaluated the differences in prognostic values of static and dynamic PET/CT in NPC. The study concluded that the tumor volume from the static scan is useful in NPC prognosis, but they could not justify the role of dynamic scanning in their small study population.^[16]

The PET/CT is also having a role in the management of NPC patients who develop distant metastasis after initial radiation therapy. Chang *et al.* showed that combining ^{18}F -FDG PET/CT with aggressive treatment approach using locoregional modalities could be of benefit to NPC patients with favorable prognostic factors, even after distant metastasis.^[17]

The role of PET in evaluating NPC is growing through the use of new PET radiotracers, for example, ^{68}Ga -DOTA-TOC,^[18] ^{68}Ga -DOTA-NOC,^[19] ^{11}C -Choline,^[20] and ^{18}F -FLT^[21] which can evaluate bone metastases from different aspects.

Prognostic biomarkers, for example, osteopontin^[22] can have a crucial role in imaging and the management of bone metastases in NPC patients as well.

The study had few limitations as it is a retrospective study. Moreover, we did not account for the number of patients instead of the number of scans, albeit a minority did have multiple scans. Furthermore, the distant metastases were not proven histologically and we did not consider the SUV_{max} measurements. A recent study done by Xiao *et al.* showed that SUV_{max} at the primary site can be helpful biomarker in predicting distant metastasis of NPC patients treated with intensity modulated radiation therapy. Furthermore, combining SUV_{max} of the primary site with the overall tumor stage could be more precise to predict treatment outcome.^[23]

Another limitation for the study is not considering the ethnicity of the patients and other factors in regards to bone metastases distribution.

Future prospective study with a large sample size is recommended to correlate metastases with the EBV titers and the treatment modality which will be of great benefit in the management of patients with NPC.

Conclusion

^{18}F -FDG PET/CT has a role in the management of NPC and in evaluating bone metastases. A prospective study may help further assess the evolving role of PET/CT in NPC bone metastases particularly in light of the development of new PET/CT scanners, advances in scanning/processing technology, and the growing use of new PET tracers and prognostic biomarkers.

Financial support and sponsorship

Nil.

Conflicts of interest

There are no conflicts of interest.

References

1. Yang Z, Shi Q, Zhang Y, Pan H, Yao Z, Hu S, *et al.* Pretreatment ^{18}F -FDG uptake heterogeneity can predict survival in patients with locally advanced nasopharyngeal carcinoma – A retrospective study. *Radiat Oncol* 2015;10:4.
2. Yen RF, Hong RL, Tzen KY, Pan MH, Chen TH. Whole-body ^{18}F -FDG PET in recurrent or metastatic nasopharyngeal carcinoma. *J Nucl Med* 2005;46:770-4.
3. Liu FY, Lin CY, Chang JT, Ng SH, Chin SC, Wang HM, *et al.* ^{18}F -FDG PET can replace conventional work-up in primary M staging of nonkeratinizing nasopharyngeal carcinoma. *J Nucl Med* 2007;48:1614-9.
4. Chang JT, Chan SC, Yen TC, Liao CT, Lin CY, Lin KJ, *et al.* Nasopharyngeal carcinoma staging by ^{18}F -fluorodeoxyglucose positron emission tomography. *Int J Radiat Oncol Biol Phys* 2005;62:501-7.
5. Bensouda Y, Kaikani W, Ahbeddou N, Rahhali R, Jabri M, Mrabti H, *et al.* Treatment for metastatic nasopharyngeal carcinoma. *Eur Ann Otorhinolaryngol Head Neck Dis* 2011;128:79-85.
6. Liu FY, Chang JT, Wang HM, Liao CT, Kang CJ, Ng SH, *et al.* ^{18}F -fluorodeoxyglucose positron emission tomography is more sensitive than skeletal scintigraphy for detecting bone metastasis in endemic nasopharyngeal carcinoma at initial staging. *J Clin Oncol* 2006;24:599-604.
7. Kapoor A, Kalwar A, Kumar N, Maharia S, Nirban RK, Kumar HS. Detection of bone metastasis in nasopharyngeal carcinoma by bone scintigraphy: A retrospective study in perspective of limited resource settings. *Clin Cancer Invest J* 2015;4(1):17.
8. Shen L, Dong J, Li S, Wang Y, Dong A, Shu W, *et al.* M1 stage subdivision and treatment outcome of patients with bone-only metastasis of nasopharyngeal carcinoma. *Oncologist* 2015;20:291-8.
9. Yen TC, Chang JT, Ng SH, Chang YC, Chan SC, Lin KJ, *et al.* The value of ^{18}F -FDG PET in the detection of stage M0 carcinoma of the nasopharynx. *J Nucl Med* 2005;46:405-10.
10. Caglar M, Ceylan E, Ozyar E. Frequency of skeletal metastases in nasopharyngeal carcinoma after initiation of therapy: Should bone scans be used for follow-up? *Nucl Med Commun* 2003;24:1231-6.
11. Zhao CL, Qian GQ, Chen XY, Chen C. Retrograde analysis of clinical characteristics of bone metastasis in 1,031 cases of preliminarily diagnosed nasopharyngeal carcinoma. *Asian Pac J Cancer Prev* 2014;15:3785-8.

12. Yang Z, Zhang Y, Shi W, Zhu B, Hu S, Yao Z, *et al.* Is 18F-FDG PET/CT more reliable than 99mTc-MDP planar bone scintigraphy in detecting bone metastasis in nasopharyngeal carcinoma? *Ann Nucl Med* 2014;28:411-6.
13. Vellayappan BA, Soon YY, Earnest A, Zhang Q, Koh WY, Tham IW, *et al.* Accuracy of (18) F-fluorodeoxyglucose-positron emission tomography/computed tomography in the staging of newly diagnosed nasopharyngeal carcinoma: A systematic review and meta-analysis. *Radiol Oncol* 2014;48:331-8.
14. Iagaru A, Mitra E, Dick DW, Gambhir SS. Prospective evaluation of (99m) Tc MDP scintigraphy, (18)F NaF PET/CT, and (18)F FDG PET/CT for detection of skeletal metastases. *Mol Imaging Biol* 2012;14:252-9.
15. Wei J, Pei S, Zhu X. Comparison of 18F-FDG PET/CT, MRI and SPECT in the diagnosis of local residual/recurrent nasopharyngeal carcinoma: A meta-analysis. *Oral Oncol* 2016;52:11-7.
16. Huang B, Wong CY, Lai V, Kwong DL, Khong PL. Prognostic value of (18) F-FDG PET-CT in nasopharyngeal carcinoma: Is dynamic scanning helpful? *Biomed Res Int* 2015;2015:582614.
17. Chang JH, Ahn YC, Park H, Oh D, Noh JM, Sun JM, *et al.* Fate of patients with nasopharyngeal cancer who developed distant metastasis as first failure after definitive radiation therapy. *Head & neck* 2014. [DOI: 10.1002/hed.23988].
18. Schartinger VH, Dudás J, Url C, Reinold S, Virgolini IJ, Kroiss A, *et al.* 68Ga-DOTA-Tyr3-octreotide positron emission tomography in nasopharyngeal carcinoma. *Eur J Nucl Med Mol Imaging* 2015;42:20-4.
19. Khor LK, Loi HY, Sinha AK, Tong KT, Goh BC, Loh KS, *et al.* (68) Ga-DOTA-peptide: A novel molecular biomarker for nasopharyngeal carcinoma. *Head Neck* 2016;38:E76-80.
20. Jiang J, Wu H, Huang M, Wu Y, Wang Q, Zhao J, *et al.* Variability of gross tumor volume in nasopharyngeal carcinoma using 11C-choline and 18F-FDG PET/CT. *PLoS One* 2015;10:e0131801.
21. Zheng Y, Yang Z, Zhang Y, Shi Q, Bao X, Zhang J, *et al.* The preliminary study of 18F-FLT micro-PET/CT in predicting radiosensitivity of human nasopharyngeal carcinoma xenografts. *Ann Nucl Med* 2015;29:29-36.
22. Hou X, Wu X, Huang P, Zhan J, Zhou T, Ma Y, *et al.* Osteopontin is a useful predictor of bone metastasis and survival in patients with locally advanced nasopharyngeal carcinoma. *Int J Cancer* 2015;137:1672-8.
23. Xiao W, Xu A, Han F, Lin X, Lu L, Shen G, *et al.* Positron emission tomography-computed tomography before treatment is highly prognostic of distant metastasis in nasopharyngeal carcinoma patients after intensity-modulated radiotherapy treatment: A prospective study with long-term follow-up. *Oral Oncol* 2015;51:363-9.