

# Scrotal Hematoma of the Newborn in the Tropics: What Attitude?

Ello Nicolas Moh, Yapi Landry Ake, Kokoe Gonebo Midekor, Sohie Dria A. K. Kouassi, Leopold Azakpa, Rebecca Bonny

Department of Paediatric Surgery, UTHC of Cocody, Abidjan R.C.I., Abidjan 03, Côte d'Ivoire

## Abstract

Scrotal hematoma (SH) in newborn is a rare condition. It can occur secondary to adrenal hemorrhage which often is associated with birth trauma. Scrotal hematoma often raises the suspicion of testicular torsion leading to unnecessary surgery. We report two cases which improved our management approach.

**Keywords:** Adrenal hemorrhage, newborn, scrotal hematoma

## INTRODUCTION

In the neonatal period, the occurrence of an acute scrotum is a surgical emergency which cannot be postponed because the viability of the testis is involved.<sup>[1]</sup> Several diseases are dreaded, especially testicular torsion whose therapeutic care should not be delayed.<sup>[1,2]</sup> However, some diseases can simulate testicular torsion in the neonatal period including scrotal hematoma which should not be underestimated.<sup>[3]</sup> We report two cases to highlight the diagnostic process.

## CASE REPORTS

### Patient 1

A 2-day-old male neonate was referred to our institution on account of bilateral acute scrotum. He was born at term by a difficult vaginal delivery with breech presentation. His birth weight was 3250 g and Apgar score was 5 and 6 at 1 and 5 min, respectively. Resuscitation maneuvers were applied. Twenty-seven hours after birth, bilateral bluish discoloration and swelling appeared in the scrotum and groin [Figure 1a]. The swelling was nontender, and the spermatic cord was not palpable. The abdomen was distended, soft without palpable mass. He was anemic with hemoglobin concentration of 8.7 g/dl but not jaundiced. The C-reactive protein was negative and prothrombin rate was normal. The scrotal ultrasonographic examination suspected bilateral testicular torsion. Surgical

exploration revealed normal testes and appendices with significant intravaginal and inguinal hematoma [Figure 1b and c]. We thought of scrotal hematoma (SH) in newborn retrospectively. Abdominal ultrasound performed 2 weeks later found neither intra-abdominal nor adrenal hematoma. The outcome after 1 year was good.

### Patient 2

We received a full-term male newborn for right inguinoscrotal hernia. He was 8 h old and was born by normal vaginal delivery in cephalic presentation. His birth weight was 4450 g and Apgar score was 6 and 8, respectively, at 1 and 5 min. A swelling and bluish discoloration of the scrotum appeared in the right scrotum and groin at the 6<sup>th</sup> h of life [Figure 2a]. The swelling was nontender, and the right testis and the spermatic cord were palpable without pain. The right scrotum did not transilluminate. The abdomen was soft without palpable mass. There was low prothrombin rate (70%). The hemoglobin was normal (17.7 g/dl). The Doppler ultrasonography of the scrotum revealed two vascularized testes with significant hematoma in the right hemiscrotum extended to the inguinal canal [Figure 2b]. Abdominal ultrasonography done at the same time revealed right adrenal hemorrhage [Figure 2c]. Conservative treatment was done successfully.

**Address for correspondence:** Dr. Yapi Landry Ake,  
03 BP 2172 Abidjan 03, Cote d'Ivoire.  
E-mail: akeyapilandry@yahoo.fr

Received: 15-02-2017 Accepted: 06-02-2018 Available Online: 16-09-2020

### Access this article online

#### Quick Response Code:



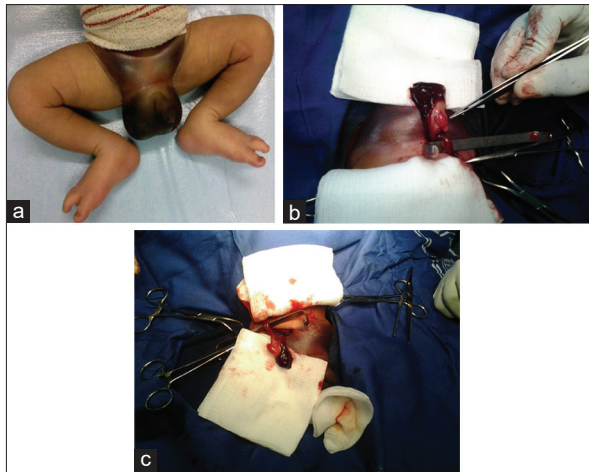
**Website:**  
www.afrijpaedsurg.org

**DOI:**  
10.4103/ajps.AJPS\_17\_17

This is an open access journal, and articles are distributed under the terms of the Creative Commons Attribution-NonCommercial-ShareAlike 4.0 License, which allows others to remix, tweak, and build upon the work non-commercially, as long as appropriate credit is given and the new creations are licensed under the identical terms.

**For reprints contact:** WKHLRPMedknow\_reprints@wolterskluwer.com

**How to cite this article:** Moh EN, Ake YL, Midekor KG, Kouassi SD, Azakpa L, Bonny R. Scrotal Hematoma of the Newborn in the Tropics: What Attitude? Afr J Paediatr Surg 2019;16:40-2.



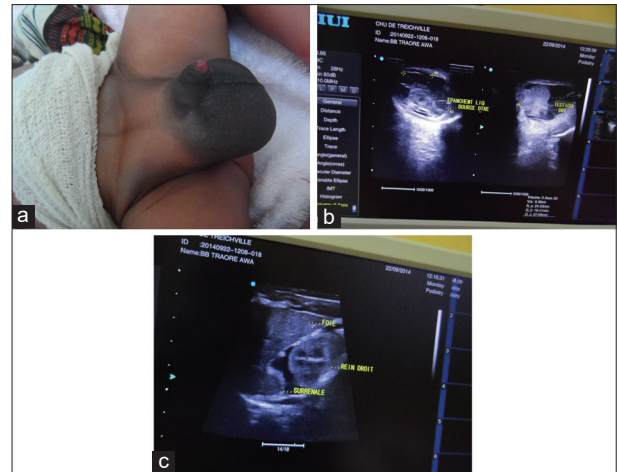
**Figure 1:** (a) Bilateral scrotal hematoma. (b) Normal macroscopic appearance of right testis and spermatic cord. (c) Normal macroscopic appearance of left testis and spermatic cord

## DISCUSSION

Bluish discoloration and swelling of the scrotum in newborns can arise from a number of diseases including hydrocele, orchitis, meconium peritonitis, hematocele, testicular tumor, traumatic hematoma, and torsion of the testes.<sup>[4]</sup> This latter condition is feared by the pediatric surgeon because of the risk of anorchia.<sup>[2]</sup> It is common until proven otherwise to consider a bluish discoloration of the scrotum accompanied by swelling as testicular torsion.<sup>[3,5]</sup> Perinatal testicular torsion may be unilateral or bilateral.<sup>[2]</sup> In postnatal torsion, emergency testicular surgery is not controverted. The testis salvage, even if uncommon, has been reported with veritable follow-up.<sup>[1]</sup>

SH is an uncommon condition in the newborn which raises the suspicion of testicular torsion.<sup>[3]</sup> That is unknown in our daily practice. SH may originate from the testis, it may descend from inside the peritoneum in the tunica vaginalis, presenting as hematocele, or retroperitoneal bleed may dissect along the subcutaneous and muscular tissue.<sup>[5]</sup>

In newborns, retroperitoneal bleed is often caused by adrenal hemorrhage.<sup>[5]</sup> Their adrenal gland is very large and vulnerable to vascular damage.<sup>[4]</sup> The right adrenal gland is the frequent (38%–100%) site of neonatal adrenal hemorrhage (NAH).<sup>[6]</sup> It easily becomes trapped between the liver and spine, causing hemorrhage.<sup>[7]</sup> In addition, the right adrenal vein drains generally directly into the inferior vena cava and is exposed to changes in venous pressure.<sup>[7]</sup> NAH is more commonly associated with perinatal hypoxia, difficult or traumatic delivery, coagulopathy, shock, or septicemia.<sup>[4,8]</sup> It can also occur spontaneously.<sup>[9]</sup> Adrenal hemorrhage is a relatively uncommon condition (0.2%–0.55%) during the neonatal period.<sup>[4,8]</sup> Clinical manifestations of NAH are variable, depending on the degree and rate of hemorrhage, as well as the amount of adrenal cortex compromised by hemorrhage.<sup>[8]</sup> The most frequent clinical manifestations



**Figure 2:** (a) moderate swelling and bluish discoloration of the right scrotum. (b) Scrotal hematoma at the ultrasonography of the right scrotum. (c) Right adrenal hemorrhage

are anemia, jaundice, abdominal distention, and palpable flank mass.<sup>[4,6,8,9]</sup> Some cases are asymptomatic.<sup>[4,8]</sup> Massive bilateral adrenal hemorrhage may present in shock.<sup>[10]</sup> Adrenal insufficiency does not occur until at least 90% of adrenal tissue is destroyed.<sup>[10]</sup> It is an extremely rare manifestation of NAH.<sup>[4]</sup> Ultrasonography is the modality of choice for the evaluation of an adrenal mass in a neonate.<sup>[10]</sup> SH due to NAH allows conservative treatment.<sup>[8]</sup>

The differential diagnosis between testicular torsion and SH in newborns is challenging, and unnecessary surgical exploration has often been performed because of diagnostic uncertainty.<sup>[8,9]</sup> In our first patient, the suspicion of testicular torsion led to unnecessary surgery. On the contrary, an emergency scrotal and abdominal ultrasonography performed in our second patient showed right SH with right adrenal hemorrhage. The patient received conservative treatment successfully.

## CONCLUSION

In a newborn with scrotal swelling and bluish discoloration, the possibility of NAH association with SH should be considered. Appropriate clinical information and ultrasonographic examination of the abdomen and scrotum should be used on a routine basis in all neonates presenting with acute scrotal swelling to reduce unnecessary surgical exploration.

## Declaration of patient consent

The authors certify that they have obtained all appropriate patient consent forms. In the form the patient(s) has/have given his/her/their consent for his/her/their images and other clinical information to be reported in the journal. The patients understand that their names and initials will not be published and due efforts will be made to conceal their identity, but anonymity cannot be guaranteed.

## Financial support and sponsorship

Nil.

## Conflicts of interest

There are no conflicts of interest.

## REFERENCES

1. Van Glabeke E, Philippe-Chomette P, Gall O, Oro H, Larroquet M, Audry G, *et al.* Spermatic cord torsion in the newborn: Role of surgical exploration. *Arch Pediatr* 2000;7:1072-6.
2. Riaz-Ul-Haq M, Mahdi DE, Elhassan EU. Neonatal testicular torsion; a review article. *Iran J Pediatr* 2012;22:281-9.
3. Diamond DA, Borer JG, Peters CA, Cilento BG Jr., Sorcini A, Kaefer M, *et al.* Neonatal scrotal haematoma: Mimicker of neonatal testicular torsion. *BJU Int* 2003;91:675-7.
4. Gonçalves R, Abuabara A, Abuabara RF, Feron CA. Scrotal hematoma as a sign of adrenal hemorrhage in newborns. *Sao Paulo Med J* 2011;129:113-5.
5. Kreeftenberg HG Jr., Zeebregts CJ, Tamminga RY, de Langen ZJ, Zijlstra RJ. Scrotal hematoma, anemia, and jaundice as manifestations of adrenal neuroblastoma in a newborn. *J Pediatr Surg* 1999;34:1856-7.
6. Mutlu M, Karagüzel G, Aslan Y, Cansu A, Okten A. Adrenal hemorrhage in newborns: A retrospective study. *World J Pediatr* 2011;7:355-7.
7. Abdu AT, Kriss VM, Bada HS, Reynolds EW. Adrenal hemorrhage in a newborn. *Am J Perinatol* 2009;26:553-7.
8. Lai LJ, Chen LM, Chu PY, Tseng MH, Chang CC, Lu CW, *et al.* Neonatal adrenal hemorrhage associated with scrotal hematoma: An unusual case report and literature review. *Pediatr Neonatol* 2012;53:210-2.
9. Avolio L, Fusillo M, Ferrari G, Chiara A, Bragheri R. Neonatal adrenal hemorrhage manifesting as acute scrotum: Timely diagnosis prevents unnecessary surgery. *Urology* 2002;59:601.
10. Qureshi UA, Ahmad N, Rasool A, Choh S. Neonatal adrenal hemorrhage presenting as late onset neonatal jaundice. *J Indian Assoc Pediatr Surg* 2009;14:221-3.