

## Case Report

# COVID-19 Pneumonia After SARS-CoV-2 Vaccination with CoronaVac: A Case Series from Turkey

Mehmet Meriç Çoban<sup>1</sup>, Mehmet Nuri Yakar<sup>2</sup>, Murat Küçük<sup>3</sup>, Bişar Ergün<sup>3</sup>, Muammer Çelik<sup>4</sup>, Begüm Ergan<sup>5</sup>, Erdem Yaka<sup>6</sup>, Necati Gökmen<sup>2</sup>

<sup>1</sup>Department of Internal Medicine, Dokuz Eylül University, Faculty of Medicine, İzmir, Turkey

<sup>2</sup>Division of Intensive Care, Department of Anaesthesiology and Reanimation, Dokuz Eylül University, Faculty of Medicine, İzmir, Turkey

<sup>3</sup>Division of Intensive Care, Department of Internal Medicine, Dokuz Eylül University, Faculty of Medicine, İzmir, Turkey

<sup>4</sup>Department of Infectious Diseases and Clinical Microbiology, Dokuz Eylül University, Faculty of Medicine, İzmir, Turkey

<sup>5</sup>Division of Intensive Care, Department of Chest Diseases, Dokuz Eylül University, Faculty of Medicine, İzmir, Turkey

<sup>6</sup>Division of Intensive Care, Department of Neurology, Dokuz Eylül University, Faculty of Medicine, İzmir, Turkey

**Cite this article as:** Meriç Çoban M, Nuri Yakar M, Küçük M, et al. COVID-19 pneumonia after SARS-CoV-2 vaccination with CoronaVac: A case series from turkey. *Turk Thorac J.* 2022;23(2):185-191.

## Abstract

Coronavirus disease 2019 is a novel viral infection that has caused a pandemic globally. Many kinds of vaccine development studies were conducted to prevent the spread and deaths. The CoronaVac is the most commonly used vaccine in Turkey. Phase 3 trials from various countries revealed that CoronaVac efficacy ranged from 50.7% to 91.25% but increased in moderate or severe cases to 100%. Additionally, it was remarkable owing to high seroconversion rates achieving up to 100%. After the vaccine campaign began in Turkey, critically ill patients continued to admit to our center's intensive care unit though they had been vaccinated with 2 doses of CoronaVac. The clinical course of these patients revealed that they are still at high risk of severe disease and death. Therefore, we aimed to share these patients' clinical characteristics and disease course, laboratory, and radiologic data.

**KEYWORDS:** COVID-19, CoronaVac, pneumonia, SARS-CoV-2, vaccination

**Received:** August 10, 2021

**Accepted:** December 6, 2021

## INTRODUCTION

On December 8, 2019, the researchers defined the first coronavirus disease 2019 (COVID-19) case as unexplained pneumonia in China.<sup>1</sup> Afterward, the disease has spread rapidly, and the World Health Organization (WHO) declared the outbreak as a pandemic.<sup>2</sup> To date, COVID-19 caused more than 4.2 million deaths and almost 200 million confirmed cases worldwide.<sup>3</sup>

The researchers conducted many kinds of vaccine development studies designed in different methods. To date, WHO approved the emergency use authorization for Pfizer/BioNTech, AstraZeneca-SK Bio, Covishield, Janssen, Moderna, Sinopharm, and CoronaVac.<sup>4,5</sup> In Turkey, CoronaVac, Pfizer/BioNTech, and Sputnik V were approved by the Ministry of Health for emergency use.<sup>6-8</sup> CoronaVac is the most commonly used vaccine in Turkey. Studies from different countries determined the efficacy and seroconversion of the CoronaVac in various doses. In phase 1 or 2 trials, the seroconversion rate changed between 92.4% and 100% after 2 doses.<sup>9-12</sup> Additionally, phase 3 trials revealed that CoronaVac efficacy ranged from 50.7% to 91.25%,<sup>13-15</sup> but it increased in moderate or severe cases to 100%.<sup>15</sup>

CoronaVac was initially administered in 2 doses 4 weeks apart to risky groups and individuals over 65 years old in Turkey. Despite the high prevention rates, especially for severe disease, we realized that critically ill COVID-19 patients over 65 years old were still admitted to our center's intensive care unit (ICU) though they had been vaccinated with 2 doses. In this paper, we aimed to assess critically ill COVID-19 cases admitted to ICU after the second CoronaVac dose.

In this case series, we assessed the patients admitted to ICU in a tertiary hospital between March and May 2021 due to COVID-19 after the second CoronaVac dose. Before ICU admission, severe acute respiratory syndrome coronavirus 2 (SARS-CoV-2) nucleic acid tests were performed on nasopharyngeal swabs using the reverse transcriptase-polymerase chain reaction (RT-PCR) test for all patients according to the local guidelines.<sup>16</sup> The date of the first RT-PCR test positivity was recorded on ICU admission. All data were collected prospectively. Patient characteristics, laboratory, and radiologic data, Acute Physiology and Chronic Health Evaluation (APACHE) II score, and Charlson Comorbidity Index (CCI) were recorded. Written informed consent was obtained for each case.

The Statistical Package for the Social Sciences Statistics software (SPSS Version 24.0; IBM Corporation, Armonk, NY, USA) was used to perform statistical analysis. The data were expressed as the median and interquartile range for continuous variables and counts and percentages for categorical variables. We did not need any uni- or multivariate analysis.

**Corresponding author:** Necati Gökmen, e-mail: necatigokmen@yahoo.com

**Table 1.** Baseline Characteristics of the Patients

Patient Characteristics	All Cases (n = 12)	Patients								
		1	2	3	4	5	6	7	8	9
Age, years	77.0 (71.0-78.5)	76	77	75	78	79	66	84	77	67
Gender	Male, 5 (55.6)	Male	Male	Male	Female	Female	Female	Male	Female	Male
BMI, kg/m <sup>2</sup>	28.0 (26.7-32.2)	27.6	41.5	27.3	33.2	31.2	31.1	28.0	26.1	25.6
APACHE II score	16 (12-26)	12	15	19	16	18	11	33	33	10
CCI	5 (4-6)	4	6	4	5	5	4	6	8	2
Smoking history	2 (22.2)	-	N/A	+	+	-	N/A	-	-	-
Comorbidities										
Hypertension	6 (66.7)	+	+	+	+				+	+
Immunosuppression	0 (0.0)									
Diabetes mellitus	4 (44.4)	+	+				+		+	
Coronary artery disease	2 (22.2)				+			+		
Congestive heart failure	3 (33.3)		+		+				+	
Chronic kidney disease	4 (44.4)		+		+	+			+	
COPD	2 (22.2)		+	+						
Malignancy*	1 (11.1)					+				
Cerebrovascular diseases	1 (11.1)						+			
Duration after second vaccine dose, days	29 (17-57)	17	22	17	29	54	7 <sup>‡</sup>	60	42	59
Mortality	6 (66.7)	+	+	+	-	+	-	+	+	-

All values are expressed as numbers (percentages) or median (interquartile range).

BMI, body mass index; APACHE II, Acute Physiology and Chronic Health Evaluation II; CCI, Charlson Comorbidity Index; N/A, not applicable; COPD, chronic obstructive pulmonary disease.

\*Solid-organ malignancies.

<sup>‡</sup>The patient had a contact history with a person diagnosed with COVID-19 2 days after vaccination.

## CASE PRESENTATIONS

We identified 9 cases with COVID-19 diagnosis confirmed by the RT-PCR test. We described their clinical characteristics, disease course (Table 1), laboratory data, and radiologic findings (Table 2).

### Patient 1

A 76-year-old male with hypertension (HT), type II diabetes mellitus (DM), hypothyroidism, and retinitis pigmentosa

was admitted to the hospital due to falling down at home 17 days after the second CoronaVac dose. The computed tomography (CT) excluded pathologies related to trauma but revealed multilobar involvement in both lungs with multiple subpleural consolidations and ground-glass opacities suspicious for COVID-19 (Figure 1A). The RT-PCR test confirmed the diagnosis. Favipiravir therapy was started. Methylprednisolone was given with a dose of 1 mg/kg/day and discontinued by gradually reducing in 10 days. The patient was transferred to the ICU due to severe hypoxemia 3 days after admission. High flow nasal oxygen (HFNO) and non-invasive mechanical ventilation (NIMV) therapies were applied alternately, but he was intubated on the 10th day. The patient underwent cardiopulmonary resuscitation for 3 minutes after intubation. Seven days after intubation, the patient was diagnosed with ventilator-associated pneumonia (VAP) caused by *Acinetobacter baumannii*. On the 23rd day of ICU admission, the patient died due to septic shock.

### Patient 2

A 77-year-old male with HT, DM, congestive heart failure (CHF), chronic kidney disease (CKD), and chronic obstructive pulmonary disease (COPD) was admitted to the hospital with complaints of dry cough 22 days after the second CoronaVac dose. Reverse transcriptase-polymerase chain reaction test confirmed the COVID-19 diagnosis. The patient

## MAIN POINTS

- CoronaVac has been approved by many countries and World Health Organization for emergency use to prevent coronavirus disease 2019 (COVID-19), and it is the most commonly used vaccine in Turkey.
- Phase 3 trials revealed that the efficacy of the CoronaVac vaccine ranged from 50.7% to 91.25% but increased to 100% in moderate or severe cases.
- Despite the high prevention rates achieving 100%, especially in moderate and severe cases, critically ill COVID-19 patients vaccinated with 2 doses of CoronaVac are still admitted to the intensive care unit in our center.
- The present data point that patients vaccinated with 2 doses of the CoronaVac are still at high risk and precautions for disease transmission are still essential for these patients.

**Table 2.** Laboratory and Radiologic Data of the Patients

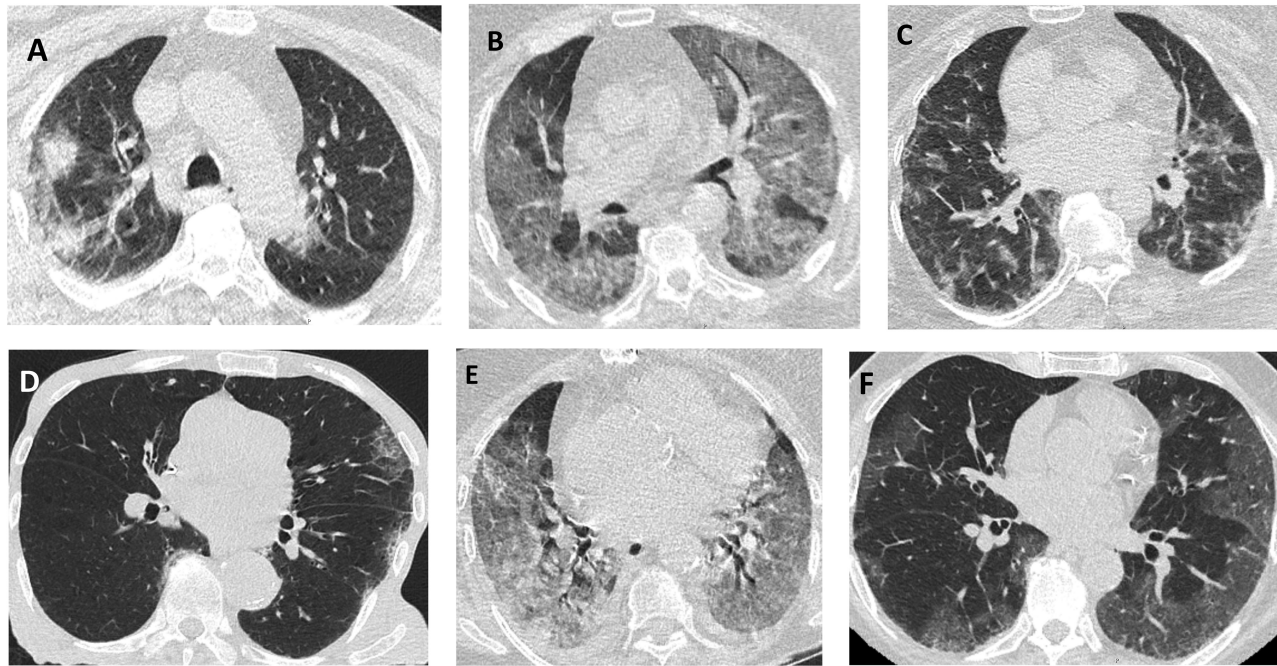
	All Cases (n = 12)	Patients								
		1	2	3	4	5	6	7	8	9
RT-PCR positivity	9 (100.0)	+	+	+	+	+	+	+	+	+
Laboratory data*										
WBC, $\times 10^3/\mu\text{L}$	14.9 (10.4-19.5)	9.3	14.9	8.2	11.4	13.5	16.9	16.2	31.2	22.1
Neutrophil, $\times 10^3/\mu\text{L}$	13.5 (9.8-17.0)	8.9	13.5	7.7	10.7	12.8	15.0	14.4	30.1	19.0
Hemoglobin, g/dL	11.0 (8.9-11.9)	11.8	12.0	11.2	8.1	9.6	14.7	8.7	9.0	11.0
Lymphocyte, $\times 10^3/\mu\text{L}$	0.5 (0.3-0.8)	0.2	0.5	0.2	0.4	0.4	0.9	0.7	0.7	1.6
Lymphocyte, %	3.4 (2.3-4.9)	2.3	3.4	2.3	3.8	2.9	5.5	4.2	2.2	7.4
Platelet, $\times 10^3/\mu\text{L}$	305 (207-368)	294	330	171	242	305	353	128	383	516
BUN, mg/dL	32.6 (25.5-52.5)	25.0	30.4	39.4	55.0	50.0	26.0	32.6	111.5	22.6
Creatinine, mg/dL	1.42 (0.84-2.43)	1.16	1.42	0.86	2.55	1.68	0.81	2.3	3.03	0.72
Total bilirubin, mg/dL	0.81 (0.67-1.29)	2.04	0.81	1.41	0.61	0.69	0.69	0.65	0.81	1.17
CRP, mg/L	163 (61-310)	323	297	69	352	102	16	163	238	52
AST, U/L	44 (31-75)	49	44	113	17	42	26	35	101	44
ALT, U/L	34 (23-54)	25	34	83	14	28	38	21	46	61
LDH, U/L	453 (348-590)	399	619	560	229	453	480	297	895	431
Ferritin, ng/mL	283 (124-2500)	246	1145	136	112	3854	283	106	9878	418
HS troponin I, ng/L	29 (13-73)	12.0	29.0	29.0	84.0	14.0	6.0	30.5	61.4	145.0
D-Dimer, $\mu\text{g/mL}$	1.24 (0.67-2.72)	2.17	0.52	0.55	13.02	0.93	1.24	2.68	0.79	2.75
Procalcitonin, ng/mL	0.23 (0.08-1.87)	2.73	0.23	0.09	26.91	0.09	0.06	0.79	1.01	0.07
BNP (plasma), pg/mL	290 (84-854)	290	233	84	854	N/A	N/A	729	3098	73
Arterial blood gas analysis*										
pH	7.43 (7.33-7.51)	7.53	7.43	7.51	7.32	7.43	7.42	7.33	7.23	7.51
PaCO <sub>2</sub> , mmHg	31 (30-37)	27	32	31	31	29	41	51	30	32
PaO <sub>2</sub> , mmHg	52 (47-57)	52	49	56	70	49	57	46	36	57
HCO <sub>3</sub> , mmol/L	24.6 (19.0-25.7)	24.6	22.5	26.4	17.0	21.0	25.0	24.9	13.3	26.8
Lactate, mmol/L	2.4 (1.5-2.8)	2.4	2.6	1.6	1.3	1.8	3.0	0.6	4.4	2.6
SO <sub>2</sub> , %	88 (85-91)	93	86	89	92	84	88	86	50	89
PaO <sub>2</sub> /FiO <sub>2</sub>	81 (67-94)	73	82	93	159	75	81	60	60	95
Chest CT compatibility‡										
Typical	6 (66.7)	+	+				+	+	+	+
Indeterminate appearance	2 (22.2)			+		+				
Not applicable	1 (11.1)				+					
Chest CT severity										
Mild	0 (0.0)									
Moderate	3 (33.3)	+						+		+
Severe	3 (33.3)		+	N/A	N/A	N/A	+		+	

All values are expressed as median (interquartile range).

RT-PCR, real time-polymerase chain reaction; WBC, white blood cell; BUN, blood urea nitrogen; CRP, C-reactive protein; AST, aspartate aminotransferase; ALT, alanine aminotransferase; LDH, lactate dehydrogenase; HS troponin I, high-sensitive troponin I; BNP, brain natriuretic peptide; PaCO<sub>2</sub>, partial pressure of arterial carbon dioxide; PaO<sub>2</sub>, partial pressure of arterial oxygen; SO<sub>2</sub>, arterial oxygen saturation; FiO<sub>2</sub>, fraction of inspired oxygen; CT, computed tomography; N/A, not applicable.

\*Tested on the day of ICU admission.

‡Performed on hospital admission.



**Figure 1.** Axial thorax computed tomography findings of the patients are shown in (A-F). (A) Multiple subpleural consolidations and ground-glass opacities, (B) widespread ground-glass opacities and consolidations, (C) ground-glass opacities and reticular densities, (D) subpleural multicentric ground glass opacities prominently in left the lung and diffuse emphysema in both lungs, (E) widespread ground-glass opacities and consolidations in both lungs, and (F) ground-glass opacities and reticular densities prominently in the left lung. CT, computed tomography.

had a mild illness and was discharged home with favipiravir therapy. Two days later, he was readmitted to the hospital with dyspnea, and oxygen saturation ( $\text{SpO}_2$ ) was 85% in room air. Chest CT scan revealed basal-localized bronchocentric nodular consolidations with ground-glass opacities and crazy-pawing pattern bilaterally compatible with severe COVID-19 pneumonia (Figure 1B). The patient was transferred to ICU on the day of hospital admission due to respiratory failure. Methylprednisolone was started with a dose of 1 mg/kg/day as an addition to favipiravir. Also, levofloxacin therapy was added empirically. Two days later, the disease progressed, and the methylprednisolone dose was increased by 250 mg/day for 3 days and then decreased to 1 mg/kg/day. On the 14th day, the patient was intubated due to severe hypoxemia. Five days after intubation, he was diagnosed with VAP caused by *Klebsiella pneumoniae*. Additionally, *A. baumannii* was detected in percutaneous blood sample culture. The patient died on the 30th day of the ICU stay due to septic shock.

#### Patient 3

A 75-year-old male patient with HT and COPD was admitted to the emergency unit with a complaint of dyspnea 17 days after the second CoronaVac dose. On admission, the  $\text{SpO}_2$  was 68%. The chest CT scan revealed peripheral ground-glass opacities with the signs of interstitial lung disease and was reported as indeterminate appearance for COVID-19. The reverse transcriptase-polymerase chain reaction test resulted in positive. Then the patient was transferred to the ICU on the day of admission. Favipiravir and levofloxacin were started. Methylprednisolone was initiated with a dose of 250 mg/day for 3 days, then decreased to 1 mg/kg/day, and discontinued by gradually reducing in 10 days. High flow nasal oxygen therapy was started. Despite the HFNO, respiratory failure progressed, and the patient was intubated due to deterioration of mental status. On the 14th day of intubation,

the patient underwent bedside percutaneous tracheostomy. The patient died on the 37th day of ICU admission due to septic shock.

#### Patient 4

A 78-year-old woman with HT, coronary artery disease (CAD), CHF, CKD, and a history of aortic valve replacement was admitted to the emergency unit with a complaint of abdominal pain. Physical examination and laboratory data indicated acute pancreatitis. During the gastroenterology ward stay, the disease became complicated due to acute kidney injury. Before the ICU admission, the RT-PCR test resulted in positive. Although the patient got the second dose of CoronaVac 29 days ago, the RT-PCT test was positive. On the third day of hospital admission, the patient was transferred to the ICU. Favipiravir was initiated for the treatment of COVID-19 and there was no need for methylprednisolone therapy. The patient only needed conventional oxygen therapy during the ICU stay. She was discharged on the sixth day from ICU with no complications.

#### Patient 5

A 79-year-old woman with CKD was admitted to the emergency unit due to dyspnea. The patient had a history of non-Hodgkin lymphoma diagnosed in 2016, received chemotherapy, and was followed up for 5 years with no recurrence. She also had undergone a mastectomy in 2000 due to breast cancer and used hormone therapy for only 5 years. The chest CT scan indicated consolidations, air bronchograms, ground-glass opacities on the mid-peripheral zones, and bilaterally pleural effusion. It was reported as an indeterminate appearance for the diagnosis of COVID-19 pneumonia. Although the patient was vaccinated almost 2 months ago, the RT-PCR test resulted in positive. Despite routine therapies including favipiravir, methylprednisolone (1 mg/kg/day), anti-biotherapy,



oxygen therapy via non-rebreather reservoir mask, and prone position, the respiratory failure worsened on the seventh day of admission, and the patient was admitted to ICU to provide advanced respiratory therapies. The methylprednisolone therapy was revised with a dose of 250 mg for 3 days and then decreased to 1 mg/kg/day with a discontinuation plan after gradually reducing in 10 days. High-flow nasal oxygen and NIMV therapies were applied alternately. On the seventh day of ICU admission, she was intubated due to refractory hypoxemia. Then, she was diagnosed with acute kidney injury. During the third hemodialysis therapy, she underwent cardiopulmonary resuscitation due to cardiac arrest and did not achieve the return of spontaneous circulation.

#### Patient 6

A 66-year-old woman with DM and a history of ischemic cerebrovascular event was diagnosed with COVID-19 by RT-PCR test by the filiation team 7 days after the second CoronaVac dose. She had a contact history 2 days after the last vaccine dose with her nephew, who was diagnosed with COVID-19. Favipiravir therapy was started on the day of diagnosis, and 4 days later, the patient was admitted to the emergency department with complaints lasting 2 days of dry cough, back pain, and dyspnea. The chest CT scan revealed a severe involvement with the ground glass opacities and reticular densities in all pulmonary lobes (Figure 1C). Oxygen saturation was 87% in room air. After admission to the pandemic ward, methylprednisolone was started with a dose of 1 mg/kg/day. On the eighth day of the hospital admission, the patient was transferred to the ICU due to severe respiratory failure. Methylprednisolone dose was changed to 250 mg/day for 3 days and then decreased to 1 mg/kg/day with a discontinuation plan in 10 days after gradually reducing. Respiratory support was provided with HFNO and NIMV alternately. On the fifth day of ICU admission, the patient was diagnosed with macrophage activation syndrome, and tocilizumab was administered with a dose of 400 mg once. Gradually, the respiratory support decreased. On the eighth day of ICU admission, respiratory support was converted to conventional oxygen therapy. She was discharged on the 11th day of ICU admission.

#### Patient 7

An 84-year-old male patient with CAD and dementia who lives at a nursing home was diagnosed with COVID-19 by the filiation team 2 months after the last CoronaVac dose. Favipiravir was prescribed for an ambulatory treatment process. Twenty days later, he was admitted to the emergency unit due to clouding of consciousness and tachypnea. Chest CT scan revealed a moderate pulmonary involvement with diffuse peripheral ground-glass areas more prominent in the left lung and diffuse emphysema in both lungs (Figure 1D). The laboratory tests showed metabolic acidosis with a normal partial oxygen pressure, clearly indicating acute renal failure. The patient needed repeated hemodialysis therapies, and on the fourth day of admission, oxygen therapy was started via a simple oxygen mask due to hypoxemia. On the sixth day of admission, he was transferred to ICU for advanced respiratory support. On the day of ICU admission, methylprednisolone was started with a dose of 1 mg/kg/day, and the patient was intubated due to HFNO failure. On the

fifth day of intubation, endotracheal aspirate sample culture indicated VAP diagnosis due to *K. pneumoniae*. Although the administration of appropriate medications according to antimicrobial resistance results, the patient died on the 15th day of ICU admission due to pneumosepsis.

#### Patient 8

A 77-year-old woman with HT, DM, CHF, CKD, and a history of aortic valve replacement was diagnosed with COVID-19 by the filiation team 42 days after the second CoronaVac dose. She used favipiravir therapy for 5 days, and on the seventh day of diagnosis, she was admitted to the emergency unit due to severe dyspnea. On admission, SpO<sub>2</sub> was 78% in room air. There was widespread involvement of bilateral middle and upper lobes in the chest CT scan, including ground-glass opacities and consolidations (Figure 1E). She was transferred to ICU for HFNO therapy on the day of emergency unit admission. Levofloxacin therapy was started. Methylprednisolone was initiated with a dose of 1 mg/kg/day, then increased to 250 mg/day for 2 days, and decreased to 1 mg/kg/day again for 10 days. On the 10th day of ICU admission, the patient was intubated due to altered mental status caused by hypoxemia. The culture of tracheal aspirate samples collected on the day of intubation revealed *A. baumannii* pneumonia, and the patient died on the 13th day of ICU admission due to septic shock.

#### Patient 9

A 67-year-old man with HT was admitted to the emergency unit due to dry cough and dyspnea 59 days after the second CoronaVac dose. Chest CT scan revealed the ground glass opacity with moderate involvement (Figure 1F), and the RT-PCR test was positive for COVID-19. Favipiravir was started. On the fifth day of admission, methylprednisolone was started with a dose of 1 mg/kg/kg due to increased oxygen requirement. On the eighth day of admission, respiratory failure progressed, and the patient was transferred to ICU. The patient was supported with HFNO, and an awake prone position was provided for at least 12 h/day. Methylprednisolone dose was increased to 250 mg/day for 3 days and then decreased to 1 mg/kg/day. The patient was transferred to the ward without any complication on the seventh day of ICU admission.

## DISCUSSION

In the present case series, we assessed 9 critically ill patients with laboratory-confirmed COVID-19 after the second dose of CoronaVac vaccination. The median age of the patients was 77.0 years (71.0-78.5), and most of them were male (55.6%). The median APACHE II score was 16 (12-26). All patients had at least one or more comorbidities, and the median CCI was 5 (4-6). The most common comorbidities were HT (66.7%), DM (44.4%), and CKD (44.4%). None of the patients had immunosuppression. The laboratory data revealed high rates of infectious parameters and decreased global oxygen delivery with a low partial pressure of arterial oxygen (PaO<sub>2</sub>)/fraction of inspired oxygen (FiO<sub>2</sub>) values. Radiologic findings showed various levels of pulmonary involvement ranging from moderate to severe, but none had a mild involvement. The median duration after the second

dose of vaccination to PCR positivity was 29 days (17-57). Despite the high seroconversion rates up to 100%<sup>9-12</sup> and efficacy rates achieving 100%, especially in moderate or severe cases,<sup>13-15</sup> the mortality was 66.6% in the present data. Additionally, the rate of mortality was relatively similar to a previous study from the same center.<sup>17</sup> The presented data demonstrated that patients vaccinated with 2 doses of the CoronaVac vaccine are still at risk of severe COVID-19, and death and precautions for disease transmission are still essential for these patients.

All patients were vaccinated with 2 doses of CoronaVac. The duration from the second vaccine dose to COVID-19 diagnosis ranged between 7 and 60 days. In phase 1 or 2 trials of CoronaVac vaccine, the seroconversion rates after different follow-up periods such as 14 or 28 days were 97% in healthcare workers,<sup>9</sup> 96.8%-100% in healthy children and adolescents,<sup>10</sup> 92.4%-97.4% in healthy individuals aged between 18 and 59 years,<sup>12</sup> and 95.7%-100% in healthy volunteers aged 60 years or over.<sup>11</sup> None of our cases had a documented seroconversion rate measurement between COVID-19 diagnosis and vaccination. Previous studies determined that the CoronaVac vaccine achieves higher efficacy rates with higher neutralizing antibody levels on the 28th day than on the 14th day after the second dose.<sup>11,12</sup> In this case series, COVID-19 was diagnosed 14 days after the last CoronaVac dose in 8 patients and 28 days after in 5. Additionally, the contact history of the patient 6, 2 days after the last dose of vaccination was notable, although she was diagnosed 7 days after the vaccination with COVID-19.

The phase 3 trials from Brazil, Indonesia, and Turkey showed the CoronaVac efficacy with the rates of 50.7%, 65.3%, and 91.25%, respectively,<sup>13-15</sup> but it increased in cases requiring assistance to 83.7% and in moderate or severe cases to 100%.<sup>15</sup> However, in 8 cases, the disease progressed to severe respiratory failure, and 6 patients died. In the deceased cases, the laboratory and radiologic data revealed severe hypoxemia, decreased global oxygen delivery, a lower PaO<sub>2</sub>/FiO<sub>2</sub> ratio than 100 mmHg, and moderate or severe involvement in chest CT images. Additionally, in 2 deceased patients, on ICU admission, a high level of procalcitonin indicating secondary infection was notable.

Recent studies showed that individuals vaccinated with CoronaVac had a reduced neutralizing capacity against the new variants, especially for the B.1.617.2 (Delta) strain.<sup>18,19</sup> However, all patients included in the present case series were diagnosed with COVID-19 between March and May 2021 when B.1.617.2 strain had not been detected in Turkey yet,<sup>20</sup> but the patients in the present case series were not tested to determine any kinds of strain. Thus, any of them might also be an undefined delta variant case from Turkey.

In conclusion, we defined 9 critically ill cases with severe COVID-19, who all were diagnosed after 2 doses of CoronaVac vaccination and presented their clinical characteristics, laboratory, and radiologic data in this paper. Although it is still debating whether CoronaVac is effective against the variants such as B.1.617.2, individuals vaccinated with 2 doses of CoronaVac might also be infected by

a non-Delta variant. Also, patients admitted to the hospital due to any reason except COVID-19 may potentially have the risk of asymptomatic COVID-19, though they had been vaccinated with 2 doses of CoronaVac. We hope that the data presented in this paper contribute to improving outcomes of the postvaccination COVID-19 cases. However, it is clear that new randomized, controlled trials are needed on this topic.

**Informed Consent:** Written informed consent was obtained from the patients or the patients' next of kin who agreed to take part in the study.

**Peer-review:** Externally peer-reviewed.

**Author Contributions:** Concept – M.M.Ç., M.N.Y., M.K., B.E., M.Ç.; Design – M.M.Ç., M.N.Y.; Supervision – B.E., E.Y., N.G.; Resources – M.M.Ç., M.N.Y.; Materials – M.M.Ç., M.N.Y., M.K., B.E., M.Ç.; Data Collection and/or Processing – M.M.Ç., M.N.Y., M.K., B.E.; Analysis and/or Interpretation – M.N.Y.; Literature Search – M.M.Ç., M.N.Y., M.Ç.; Writing Manuscript – M.M.Ç., M.N.Y., M.K., B.E., M.Ç.; Critical Review – M.N.Y., M.Ç., B.E., E.Y., N.G.

**Declaration of Interests:** The authors have no conflict of interest to declare.

**Funding:** The authors declared that this study has received no financial support.

## REFERENCES

- Chen N, Zhou M, Dong X, et al. Epidemiological and clinical characteristics of 99 cases of 2019 novel coronavirus pneumonia in Wuhan, China: a descriptive study. *Lancet*. 2020; 395(10223):507-513. [CrossRef]
- World Health Organization (WHO). *WHO Director-General's Opening Remarks at the Media Briefing on COVID-19 - March 11, 2020*. Available at: <https://www.who.int/director-general/speeches/detail/who-director-general-s-opening-remarks-at-the-media-briefing-on-covid-19---11-march-2020>.
- World Health Organization. *Coronavirus (COVID-19) Dashboard*. 2020. Available at: <https://covid19.who.int/>.
- World Health Organization. *WHO Lists Additional COVID-19 Vaccine for Emergency Use and Issues Interim Policy Recommendations*. 2021. Available at: <https://www.who.int/news/item/07-05-2021-who-lists-additional-covid-19-vaccine-for-emergency-use-and-issues-interim-policy-recommendations>.
- World Health Organization. *CoronaVac - WHO Validates Sinovac COVID-19 Vaccine for Emergency Use and Issues Interim Policy Recommendations*. 2021. Available at: <https://www.who.int/news/item/01-06-2021-who-validates-sinovac-covid-19-vaccine-for-emergency-use-and-issues-interim-policy-recommendations>.
- Türkiye İlaç ve Tıbbi Cihaz Kurumu. *CoronaVac - Emergency Use Authorization*. 2021. Available at: <https://www.titck.gov.tr/haber/kamuoyunun-dikkatine-13012021185623>.
- Türkiye İlaç ve Tıbbi Cihaz Kurumu. *Sputnic V - Emergency Use Authorization*. 2021. Available at: <https://www.titck.gov.tr/haber/kamuoyunun-dikkatine-13012021185623>.
- T.C. Sağlık Bakanlığı. *Pfizer/BioNTech - The Use of the Vaccine in Turkey*. 2021. Available at: <https://www.saglik.gov.tr/TR,81815/28-milyon-doz-bion-tech-asisi-turkiyeye-getirildi-31032021.html>.
- Bochnia-Bueno L, De Almeida SM, Raboni SM, et al. Dynamic of humoral response to SARS-CoV-2 anti-Nucleocapsid and

- Spike proteins after CoronaVac vaccination. *Diagn Microbiol Infect Dis.* 2022;102(3):115597. doi: 10.1016/j.diagmicrobio.2021.115597. [CrossRef]
10. Han B, Song Y, Li C, et al. Safety, tolerability, and immunogenicity of an inactivated SARS-CoV-2 vaccine (CoronaVac) in healthy children and adolescents: a double-blind, randomised, controlled, phase 1/2 clinical trial. *Lancet Infect Dis.* 2021;21(12):1645-1653. [CrossRef]
  11. Wu Z, Hu Y, Xu M, et al. Safety, tolerability, and immunogenicity of an inactivated SARS-CoV-2 vaccine (CoronaVac) in healthy adults aged 60 years and older: a randomised, double-blind, placebo-controlled, phase 1/2 clinical trial. *Lancet Infect Dis.* 2021;21(6):803-812. [CrossRef]
  12. Zhang Y, Zeng G, Pan H, et al. Immunogenicity and safety of a SARS-CoV-2 inactivated vaccine in healthy adults aged 18-59 years: report of the randomized, double-blind, and placebo-controlled phase 2 clinical trial. *medRxiv.* Published online on August 10, 2020. <https://doi.org/10.1101/2020.07.31.20161216> (preprint). [CrossRef]
  13. Tanriover MD, Doğanay HL, Akova M, et al. Efficacy and safety of an inactivated whole-virion SARS-CoV-2 vaccine (CoronaVac): interim results of a double-blind, randomised, placebo-controlled, phase 3 trial in Turkey. *Lancet.* 2021;398(10296): 213-222. [CrossRef]
  14. Nature news. China COVID vaccine reports mixed results — what does that mean for the pandemic? *January 15, 2021.* Available at: <https://www.nature.com/articles/d41586-021-00094-z>. [CrossRef]
  15. Palacios R, Batista AP, Albuquerque CSN, et al. Efficacy and safety of a COVID-19 inactivated vaccine in healthcare professionals in Brazil: the PROFISCOV study. *SSRN*; published online on April 11, 2021. <https://doi.org/10.2139/ssrn.3822780> (preprint). [CrossRef]
  16. T.C. Sağlık Bakanlığı. *COVID-19 (SARS-CoV-2 Infection) General Information, Epidemiology and Diagnosis.* 2021. Available at: <https://covid19.saglik.gov.tr/Eklenti/39551/0/covid-19rehberigenelbilgilerepidemiyojivetanipdf.pdf>.
  17. Yakar MN, Ergun B, Ergun B, et al. Clinical characteristics and risk factors for 28-day mortality in critically ill patients with COVID-19: a retrospective cohort study. *Turk J Med Sci.* 2021;51(5):2285-2295. [CrossRef]
  18. Vacharathit V, Aiewsakun P, Manopwisedjaroen S, et al. CoronaVac induces lower neutralising activity against variants of concern than natural infection. *Lancet Infect Dis.* 2021;21(10):1352-1354. doi: 10.1016/S1473-3099(21)00568-5. [CrossRef]
  19. Hu J, Wei X, Xiang J, et al. Reduced neutralization of SARS-CoV-2 B.1.617 variant by inactivated and RBD-subunit vaccine. *bioRxiv.* published online on July 09, 2021. <https://doi.org/10.1101/2021.07.09.451732> (preprint). [CrossRef]
  20. Anadolu Agency. *Delta Variant in Turkey.* 2021. Available at: <https://www.aa.com.tr/tr/koronavirus/turkiyenin-koronavirusl-e-mucadelesinde-son-24-saatte-yasananlar/2283480>.