



Accuracy of High- and Low-Resolution Cone-Beam Computed Tomographic Scans in the Detection of Impacted Tooth-Induced External Root Resorption: An Ex-Vivo Study

Arash Dabbaghi¹, Sanaz Sharifi¹, Masoud Esmaeili^{2*}

1. Department of Oral and Maxillofacial Radiology, School of Dental Medicine, Ahvaz Jundishapur University of Medical Sciences, Ahvaz, Iran
2. Department of Oral and Maxillofacial Radiology, Faculty of Dentistry, Shahid Sadoughi University of Medical Sciences, Yazd, Iran

Article Info

Article type:
Original Article

Article history:
Received: 5 March 2019
Accepted: 10 October 2019
Published: 20 December 2019

*** Corresponding author:**
Department of Oral and Maxillofacial Radiology, Faculty of Dentistry, Shahid Sadoughi University of Medical Sciences, Yazd, Iran
Email: masoudesmaeili65@gmail.com

ABSTRACT

Objectives: Cone-beam computed tomography (CBCT) is used in diagnostic situations, as well as tooth impaction and its complications. A possible sequela of tooth impaction is resorption of adjacent teeth, complicating the treatment plans. This study aimed to determine the diagnostic accuracy of high- and low-resolution CBCT scans in the detection of external root resorptions (ERRs), caused by an adjacent impacted tooth in the cemento-enamel junction (CEJ), mid-root, and apical areas.

Materials and Methods: Forty-five intact single-rooted teeth were divided into three groups of 15. Each group was dedicated to each zone of the root. Slight, moderate, and severe ERRs were formed, and CBCT scans were taken before and after the formation of ERRs. The diagnostic accuracy was assessed, and the Proportion test was used to compare the results.

Results: The statistical analyses of high- and low-resolution images showed a significant difference ($P < 0.05$), which implies the higher accuracy of high-resolution images. The highest diagnostic accuracy among different zones was related to the mid-root, and the lowest was related to the apical zone. In terms of the size of ERRs, the diagnostic accuracy was the lowest for slight ERRs.

Conclusion: The most reliable and accurate diagnostic mode was found in high-resolution images, in the mid-root zone, and with severe ERRs. The lowest diagnostic accuracy was found in low-resolution images, in the apical zone, and with slight ERRs.

Keywords: Root Resorption; Cone-Beam Computed Tomography; Diagnosis; Accuracy; Impacted Teeth

- **Cite this article as:** Dabbaghi A, Sharifi S, Esmaeili M. Accuracy of High- and Low-Resolution Cone-Beam Computed Tomographic Scans in the Detection of Impacted Tooth-Induced External Root Resorption: An Ex-Vivo Study. *Front Dent.* 2019;16(6):429-435. doi: 10.18502/ffd.v16i6.3442

INTRODUCTION

Tooth impaction is a pathological condition in which a tooth “fails to erupt into the dental arch

within the expected period” [1]. An impacted tooth, apart from its aesthetic and functional disruption, has the potential to cause more

severe and serious problems such as development of dentigerous cysts or root resorption of adjacent teeth [2]. Therefore, treatment of impacted teeth is of utmost importance. Diagnosis, treatment planning, and various methods of managing impacted teeth depend on the position of the impacted tooth, surgical accessibility, prognosis of the intervention on the impacted tooth and adjacent teeth, and the impact of treatment on the final functional occlusion [3].

The selection of appropriate analytical treatment approaches requires careful clinical examination and radiographic screening [3]. Panoramic, periapical, and occlusal radiographs are the most common conventional radiographic techniques used for imaging examination. Conventional radiographic techniques have the potential to produce vast amounts of diagnostic imaging information, but each has its limitations [4]. Conventional radiographs depict a two-dimensional (2D) perspective of a three-dimensional (3D) anatomy, creating an obscured anatomy of the teeth and adjacent structures [1,3,4].

Cone-beam computed tomography (CBCT), as a 3D imaging modality, has become the standard in the examination of impacted teeth and their potential complications [2,3,5]. Dosimetric examinations have shown a noticeably high spatial resolution and low radiation doses of CBCT compared to CT scans [1,2,5]. This modality visualizes the precise location of the impacted tooth, helps in determining the proximity to adjacent anatomical structures and landmarks, and provides primary reconstructed images in three orthogonal planes (axial, sagittal, and coronal) [2,3,5]. Various studies have shown CBCT to be significantly more effective than conventional radiography in determining external and internal inflammatory root resorptions (IRRs) [6]. Therefore, CBCT has high diagnostic reliability in the localization of impacted teeth and their local complications [2,3,6].

Few in-vitro studies have examined the role of CBCT in the diagnosis of external root resorptions (ERRs), and most in-vivo studies of ERRs have been mainly conducted using 2D

radiographs. Due to the lack of an in-vivo “gold standard” for measurements of the mechanical indicators, the diagnostic accuracy of this method is questionable. Furthermore, there are limited data in the literature on the efficacy of CBCT in the detection of root resorption at the cemento-enamel junction (CEJ), mid-root, and apical areas, separately [7-9].

The present study aimed to determine the diagnostic accuracy of high- and low-resolution CBCT scans in the detection of ERRs at the CEJ, mid-root, and apical areas caused by an adjacent impacted tooth.

MATERIALS AND METHODS

Forty-five intact single-rooted teeth, extracted due to orthodontic or periodontal treatments, were selected for this study. The inclusion criteria included teeth without secondary decay and fracture of the filling material or the tooth structure. The teeth were randomly divided into three groups (n=15). Each group was used for simulating the resorption on one region of the root (the CEJ, mid-root, and apical regions). To simulate ERRs, three round diamond burs (SS White Burs Inc., Lakewood, NJ, USA) of 0.25-, 0.5-, and 1-mm diameters were used with a low-speed handpiece equipped with internal water coolant. Three types of artificial ERR defects were created: slight (half the diameter of a V4 bur, 0.25 mm), moderate (0.5 mm), and severe (1 mm). Distances less than 1 mm between the impacted tooth crown and the adjacent root were considered as contact proximity [10,11]. The teeth were mounted and fixed in wax blocks such that the crown of the impacted tooth was in close contact with the resorbed area of the adjacent tooth. To simulate the bone density, the teeth were mounted in a mold made of equal portions of plaster and acrylic powder (Fig. 1).

To minimize the effect of the location of the teeth in the field of view (FOV) of the scans, the molds were designed such that the distances of the samples to the center of the mold and the center of the FOV were approximately the same.

The teeth were scanned twice (two trials) before and after forming the ERRs using the


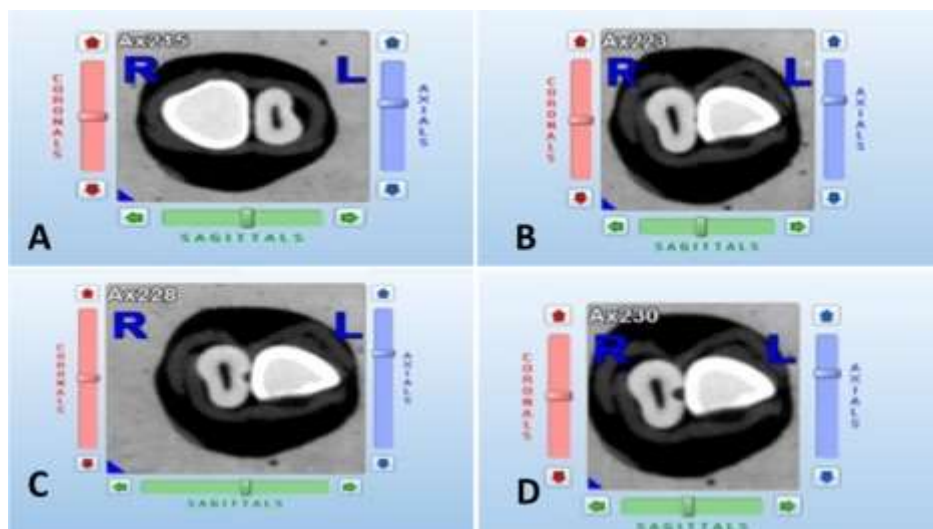


Fig. 1. The mold made of equal portions of plaster and acrylic powder in which the sample teeth and their adjacent impacted teeth were mounted. To minimize the effect of tooth location in the field of view (FOV), the distances of the samples to the center of the mold and the center of the FOV were designed to be approximately the same

NewTom VGi unit (Quantitative Radiology, Verona, Italy) with an FOV of 8×8 cm, once with high-resolution parameters [110 kilovoltage peak (kVp), 1.4 milliamperes (mA), 5.4 seconds, and 0.125-mm voxel size] and once with low-resolution parameters (110 kV, 0.55 mA, 3.6 seconds, and 0.125-mm voxel size). In each scan, four mounted teeth were imaged and then cropped, coded, reconstructed, and examined in the axial, coronal, and sagittal planes using NNT Viewer software (version.3.0; Quantitative Radiology, Verona, Italy; Fig. 2. A-D). In total, 360 CBCT images (180 high-resolution and 180 low-resolution images) were

examined before and after the preparation of ERRs. Three blinded, experienced oral and maxillofacial radiologists evaluated the presence or absence of resorption. They viewed the images in a dimly lit room and scored each image as 0 (no ERRs) or 1 (ERRs diagnosed). The knowledge of the presence or absence of simulated ERRs was considered as the gold standard. The sensitivity, specificity, positive predictive value (PPV), and negative predictive value (NPV) were calculated, as well as the diagnostic accuracy for all the variables (the severity of ERRs, the location of ERRs, and the resolution of the scans).



Figs. 2. Axial high-resolution cone-beam computed tomography (CBCT) slices from the contact area between the adjacent impacted tooth and the midroot zone of a sample tooth. (A) Intact root. (B) Slight external root resorption (ERR). (C) Moderate ERR. (D) Severe ERR

The significance level was set at 0.05 with a 95% confidence interval (CI). The Proportion test with SPSS (version 23.0; IBM Corp., Armonk, NY, USA) and Minitab 17 (Minitab Inc., State College, PA, USA) were used for analysis.

RESULTS

The variables in the present study included high- and low- resolution CBCT scans, the location of ERRs (CEJ, mid-root, and apical areas), and the degree or severity of ERRs (slight, moderate, and severe). A total number of 360 CBCT images were examined. The sensitivity, specificity, PPV, NPV, and diagnostic accuracy were calculated for all the variables (Table 1). The lowest sensitivity, PPV, NPV, and accuracy were related to low-resolution images. The lowest specificity was associated with low-resolution images in the middle of the root. The diagnostic accuracy in high- and low-resolution images was 0.885 and 0.824,

respectively. The statistical analyses showed a significant difference between the two levels of resolution (P=0.006), which indicates the higher accuracy of high-resolution images compared to low-resolution images.

Statistical analyses of ERRs in the apical, mid-root, and CEJ zones showed that the highest and lowest accuracies were related to the mid-root zone (0.911) and the apical zone (0.825), respectively. The difference between these two parts was significant (P<0.05). There also was a difference between the CEJ zone (0.828) and the mid-root zone. No significant difference was found between the apical and CEJ zones (P>0.05, Table 2). According to the obtained results, the severity of ERRs was associated with diagnostic accuracy, i.e. slight ERRs with the accuracy of 0.722 were related to the lowest diagnostic accuracy compared to moderate (0.892) and severe (0.898) ERRs.

Table 1. Sensitivity, specificity, positive predictive value (PPV), negative predictive value (NPV), and accuracy (Az) related to high- and low-resolution scans and the location of simulated external root resorption (ERR; N=15)

Resolution	Region of ERR	Severity of ERR	Sensitivity	Specificity	PPV	NPV	Az
High	Apical	Slight	0.56	0.93	0.89	0.68	0.74
		Moderate	0.93	0.93	0.93	0.93	0.93
		Severe	1.00	0.93	0.94	1.00	0.97
	Midroot	Slight	0.87	0.82	0.83	0.86	0.84
		Moderate	1.00	0.82	0.85	1.00	0.91
		Severe	1.00	0.93	0.85	1.00	0.91
	Cementoenamel junction	Slight	0.64	0.89	0.85	0.71	0.77
		Moderate	0.98	0.89	0.9	0.8	0.93
		Severe	1.00	0.89	0.9	1.00	0.94
Low	Apical	Slight	0.42	0.8	0.68	0.58	0.61
		Moderate	1.00	0.8	0.83	1.00	0.9
		Severe	1.00	0.8	0.84	0.95	0.88
	Midroot	Slight	0.87	0.73	0.76	0.85	0.8
		Moderate	1.00	0.73	0.79	1.00	0.87
		Severe	1.00	0.73	0.79	1.00	0.87
	Cementoenamel junction	Slight	0.49	0.64	0.58	0.56	0.57
		Moderate	0.98	0.64	0.73	0.97	0.81
		Severe	1.00	0.64	0.74	1.00	0.82

The differences in the diagnostic accuracy of resorption of different severities were significant when slight ERRs were compared with moderate and severe ERRs. There was a difference of less than 1% between the accuracy

of moderate (0.892) and severe (0.898) ERRs, which was not statistically significant (P>0.05; Table 2). The overall agreements between reviewers one and two, one and three, and two and three were 0.8, 0.85, and 0.81, respectively.

Table 2. Diagnostic accuracy in different root regions and various severities of external root resorption (ERR)

	Variables	Accuracy	P value
Region of Resorption	Apical-Midroot	0.825-0.911	0.001
	Apical-Cementoenamel junction	0.825-0.828	0.999
	Midroot- Cementoenamel junction	0.911-0.828	0.001
Severity of ERR	Slight-Moderate	0.722-0.892	<0.001
	Slight-Severe	0.722-0.898	<0.001
	Moderate-Severe	0.892-0.898	0.21

Inter-observer agreements between reviewers one and two, one and three, and two and three were 0.0547, 0.601, and 0.58, respectively.

The most reliable and accurate diagnostic mode was found in high-resolution images, in the mid-root zone, and with severe ERRs. The lowest diagnostic accuracy was found in low-resolution images, in the apical zone, and with slight ERRs.

DISCUSSION

Root resorption is a multifactorial (physiological, pathological, and idiopathic) process, which results in the loss of dentin, cementum, or alveolar bone by the action of osteoclasts [12-15]. Root resorption can be transient or progressive. Transient root resorption is a self-limiting process and is normally not detected clinically or radiographically. Progressive root resorption leads to irreversible dental loss and requires treatment and follow-up [16,17]. Different factors are involved in the onset of ERRs, including impacted teeth [18,19]. An incorrect diagnosis of root resorption can lead to inappropriate management, ineffective treatment, and even clinical complications. Accurate diagnosis is the basis of appropriate treatment; together, they form the basis of a favorable prognosis. For instance, early and accurate detection of ERRs during orthodontic treatment is essential for identifying teeth at risk of severe resorption [20,21]. The present study evaluated the diagnostic performance of CBCT scans of 45 intact single-rooted teeth adjacent to an impacted tooth for ERR detection. The most reliable and accurate diagnostic mode was found in high-resolution images, in the mid-root zone, and with severe ERRs, whereas the lowest diagnostic accuracy was found in low-resolution images, in the apical zone, and with slight ERRs. Liedke et al [8] examined the diagnostic ability

of CBCT scans with different voxel resolutions in the detection of simulated ERRs and concluded that voxel resolution did not affect specificity and sensitivity. Contrary to the cited study, we found that a lower resolution results in less diagnostic accuracy for ERRs. The difference in the results of these two studies could be due to the use of larger cavities (0.6, 1.2, and 1.8 mm in diameter) in the study by Liedke et al [8], which made it easier to detect ERRs at different resolutions. Kamburoğlu and Kursun [22] examined two different CBCT units with different voxel resolutions for the detection of simulated internal resorptions using a 0.5-mm-diameter round bur at the cervical and apical regions of the labial wall of 60 single-rooted mandibular incisors and canines. They showed that the two CBCT units performed similarly and better than low-resolution images in the detection of internal resorptions [22]. The difference between the present study and the mentioned study can be attributed to different zones of root resorption and different levels of resolution in the detection of root resorption. Westphalen et al [23] compared the efficacy of conventional and digital radiographic methods in diagnosing simulated ERR cavities. They detected a larger number of cavities by the digital method for all depths of lesions and concluded that the digital method was more sensitive than conventional radiography in the detection of simulated ERR cavities [23]. Neves et al [24] compared the efficacy of CBCT using different voxel sizes in the diagnosis of simulated ERRs and concluded that ERRs were more easily diagnosed when a smaller voxel size was used. This was consistent with the results obtained in the present study. Ponder et al [9] studied the quantification of

ERRs by low- and high-resolution CBCT and periapical radiography and concluded that high-resolution CBCT scans lead to more accurate volumetric quantifications of lateral resorption defects than low-resolution scans, which is in line with the result of the present study. However, the results of the study by Ponder et al [9] showed a high diagnostic accuracy of linear measurements of apical defects in both low- and high-resolution modes, which is inconsistent with our findings.

Estrela et al [25] evaluated IRRs using CBCT. The results of their study showed that IRRs were found in 68.8% (83 root surfaces) of the radiographs and 100% (154 root surfaces) of the CBCT scans. The extension of IRRs was detected in 95.8% of the CBCT images and 52.1% of the images obtained by the conventional method [25]. They concluded that CBCT was a powerful tool in the evaluation of IRRs, and its diagnostic performance was better than that of periapical radiography. In the present study, the high-resolution images showed a better diagnostic accuracy for slight ERRs. Similarly, Alqerban et al [5] examined two CBCT systems (Accuitomo and Scanora) and panoramic imaging for detecting simulated canine impaction-induced ERRs in maxillary lateral incisors and reported that the imaging performance of both CBCT systems was significantly better than that of panoramic radiography for determining all sizes of root resorption (slight to severe) [5]. Ideally, a diagnostic test for ERRs should be valid and reliable, i.e. it should be able to reasonably categorize the presence/absence of different types of root resorption and be repeatable to produce the same result, respectively.

The CBCT software allows the clinician to select the most suitable orthogonal views for each particular lesion. Although CBCT lacks ideal diagnostic accuracy in some cases, it is non-invasive and has high diagnostic accuracy in detecting root lesions even at their earliest stages; therefore, CBCT has become an important technique for detection of ERRs.

CONCLUSION

High-resolution CBCT images have higher diagnostic accuracy than low-resolution

images. The most reliable and accurate diagnostic mode was found in high-resolution images, in the mid-root zone, and with severe ERRs, whereas the lowest diagnostic accuracy was in low-resolution images, in the apical zone, and with slight ERRs. Similarly, the severity of resorption affects the diagnostic accuracy; slight ERRs are related to lower diagnostic accuracy compared to moderate and severe ERRs.

ACKNOWLEDGMENTS

This article has been derived from postgraduate thesis no. u-94203 funded by Ahvaz Jundishapur University of Medical Sciences, Ahvaz, Khuzestan, Iran.

CONFLICT OF INTEREST STATEMENT

None declared.

REFERENCES

1. Liu DG, Zhang WL, Zhang ZY, Wu YT, Ma XC. Localization of impacted maxillary canines and observation of adjacent incisor resorption with cone-beam computed tomography. *Oral Surg Oral Med Oral Pathol Oral Radiol Endod.* 2008 Jan;105(1):91-8.
2. Tamimi D, ElSaid K. Cone beam computed tomography in the assessment of dental impactions. *Semin Orthod.* 2009 Mar;15(1):57-62.
3. Haney E, Gansky SA, Lee JS, Johnson E, Maki K, Miller AJ, et al. Comparative analysis of traditional radiographs and cone-beam computed tomography volumetric images in the diagnosis and treatment planning of maxillary impacted canines. *Am J Orthod Dentofacial Orthop.* 2010 May;137(5):590-7.
4. Oberoi S, Knueppel S. Three-dimensional assessment of impacted canines and root resorption using cone beam computed tomography. *Oral Surg Oral Med Oral Pathol Oral Radiol.* 2012 Feb;113(2):260-7.
5. Alqerban A, Jacobs R, Souza PC, Willems G. In-vitro comparison of 2 cone-beam computed tomography systems and panoramic imaging for detecting simulated canine impaction-induced external root resorption in maxillary lateral incisors. *Am J Orthod Dentofacial Orthop.* 2009 Dec;136(6):764.e1-11.

6. Alqerban A, Jacobs R, Fieuws S, Willems G. Comparison of two cone beam computed tomographic systems versus panoramic imaging for localization of impacted maxillary canines and detection of root resorption. *Eur J Orthod.* 2011 Feb;33(1):93-102.
7. Lermen CA, Liedke GS, da Silveira HE, da Silveira HL, Mazzola AA, de Figueiredo JA. Comparison between two tomographic sections in the diagnosis of external root resorption. *J Appl Oral Sci.* 2010 May-Jun;18(3):303-7.
8. Liedke GS, da Silveira HE, da Silveira HL, Dutra V, de Figueiredo JA. Influence of voxel size in the diagnostic ability of cone beam tomography to evaluate simulated external root resorption. *J Endod.* 2009 Feb;35(2):233-5.
9. Ponder SN, Benavides E, Kapila S, Hatch NE. Quantification of external root resorption by low-vs high-resolution cone-beam computed tomography and periapical radiography: a volumetric and linear analysis. *Am J Orthod Dentofacial Orthop.* 2013 Jan;143(1):77-91.
10. Shokri A, Mortazavi H, Salemi F, Javadian A, Bakhtiari H, Matlabi H. Diagnosis of simulated external root resorption using conventional intraoral film radiography, CCD, PSP, and CBCT: a comparison study. *Biomed J.* 2013 Jan-Feb;36(1):18-22.
11. Yan B, Sun Z, Fields H, Wang L. Maxillary canine impaction increases root resorption risk of adjacent teeth: a problem of physical proximity. *Am J Orthod Dentofacial Orthop.* 2012 Dec;142(6):750-7.
12. Leach HA, Ireland AJ, Whaites EJ. Radiographic diagnosis of root resorption in relation to orthodontics. *Br Dent J.* 2001 Jan 13;190(1):16-22.
13. Kamburoğlu K, Kurşun Ş, Yüksel S, Öztaş B. Observer ability to detect ex vivo simulated internal or external cervical root resorption. *J Endod.* 2011 Feb;37(2):168-75.
14. Lyroudia KM, Dourou VI, Pantelidou OC, Labrianidis T, Pitas IK. Internal root resorption studied by radiography, stereomicroscope, scanning electron microscope and computerized 3D reconstructive method. *Dent Traumatol.* 2002 Jun;18(3):148-52.
15. Hamilton RS, Gutmann JL. Endodontic-orthodontic relationships: a review of integrated treatment planning challenges. *Int Endod J.* 1999 Sep;32(5):343-60.
16. Trope M. Root resorption due to dental trauma. *Endod Topics.* 2002 Mar;1(1):79-100.
17. Bakland LK. Root resorption. *Dent Clin North Am.* 1992 Apr;36(2):491-507.
18. Otto RL. Early and unusual incisor resorption due to impacted maxillary canines. *Am J Orthod Dentofacial Orthop.* 2003 Oct;124(4):446-9.
19. Milberg DJ. Labially impacted maxillary canines causing severe root resorption of maxillary central incisors. *Angle Orthod.* 2006 Jan;76(1):173-6.
20. Patel S, Dawood A, Wilson R, Horner K, Mannocci F. The detection and management of root resorption lesions using intraoral radiography and cone beam computed tomography - an in vivo investigation. *Int Endod J.* 2009 Sep;42(9):831-8.
21. Eraso FE, Parks ET, Roberts WE, Hohlt WF, Ofner S. Density value means in the evaluation of external apical root resorption: an in vitro study for early detection in orthodontic case simulations. *Dentomaxillofac Radiol.* 2007 Mar;36(3):130-7.
22. Kamburoğlu K, Kursun S. A comparison of the diagnostic accuracy of CBCT images of different voxel resolutions used to detect simulated small internal resorption cavities. *Int Endod J.* 2010 Sep;43(9):798-807.
23. Westphalen VP, Gomes de Moraes I, Westphalen FH, Martins WD, Souza PH. Conventional and digital radiographic methods in the detection of simulated external root resorptions: a comparative study. *Dentomaxillofac Radiol.* 2004 Jul;33(4):233-5.
24. Neves FS, de Freitas DQ, Campos PS, de Almeida SM, Haiter-Neto F. In vitro comparison of cone beam computed tomography with different voxel sizes for detection of simulated external root resorption. *J Oral Sci.* 2012 Sep;54(3):219-25.
25. Estrela C, Bueno MR, De Alencar AH, Mattar R, Valladares Neto J, Azevedo BC, et al. Method to evaluate inflammatory root resorption by using cone beam computed tomography. *J Endod.* 2009 Nov;35(11):1491-7.