

# A diagnostic conundrum; Kimura's disease mimicking eosinophilic granulomatosis with polyangiitis

SAGE Open Medical Case Reports  
Volume 10: 1–5  
© The Author(s) 2022  
Article reuse guidelines:  
sagepub.com/journals-permissions  
DOI: 10.1177/2050313X211070522  
journals.sagepub.com/home/sco



Mythily Aravinthan<sup>1</sup> , Inoshi Atukorala<sup>2</sup> and Chandu De Silva<sup>3</sup>

## Abstract

Kimura's Disease (KD) is a benign, relapsing chronic inflammatory condition often seen in young Asian males, manifesting as recurrent swellings in skin and subcutaneous tissues especially in the head and neck region. Eosinophilic granulomatosis with polyangiitis (EGPA) is a debilitating multisystem vasculitic condition which causes high morbidity due to cavitating lung lesions, neuropathy and renal impairment. Eosinophilia is common to both conditions. We, herein present a young Asian male with KD who presented with isolated recurrent nasopharyngeal mucosal swelling with eosinophilia. Biopsy of the lesion showed necrotizing vasculitis and eosinophilic granulomata mimicking EGPA. Nevertheless, he did not have any other characteristic systemic features of EGPA. Targeted evaluation through multidisciplinary approach helped secure the diagnosis of KD. KD has a wide range of presentation. The three cardinal histopathologic features in KD are eosinophilic inflammation, vascular proliferation and stromal fibrosis. However, vasculitis, granulomata and variable degree of necrosis can be present as in this case. He responded well to a course of steroids followed by Mycophenolate Mofetil. This minimized iatrogenic morbidity to the patient resulting from use of highly toxic immunomodulators which are not necessary in KD unlike in EGPA.

## Keywords

Case report, Kimura's, eosinophilic granulomatosis with polyangiitis, eosinophilia, pharyngeal swelling

Date received: 27 September 2021; accepted: 14 December 2021

## Introduction

Kimura's disease (KD) is a rare chronic inflammatory disorder which presents as multiple subcutaneous swellings in the head and neck region. It can be variably associated with peripheral eosinophilia, elevated IgE levels and renal involvement.<sup>1</sup> Owing to the benign natural course, keeping under observation or simple surgical or medical therapies often suffice.<sup>2</sup> Eosinophilic Granulomatosis with Polyangiitis (EGPA) on the other hand is a disabling multisystem necrotizing vasculitic disorder requiring aggressive immunomodulatory therapy. It is fatal without timely intervention.<sup>3</sup> We present a case where KD manifested with isolated extra cutaneous swellings of nasopharyngeal mucosa demonstrating eosinophilic granulomatous inflammation on background of chronic sinusitis. This led to a diagnostic dilemma between EGPA and KD. Having been described more than 60 years ago,<sup>4</sup> KD continues to be an ambiguous entity and a challenging diagnosis to make. There is considerable overlap between KD and its close mimicker Angiolymphoid hyperplasia with eosinophilia

(ALHE). Several studies have demonstrated the distinguishing features between the two.<sup>5,6</sup> However, this is the first report highlighting the potential overlap between KD and EGPA.

## Case report

A 30-year-old south Asian man presented with dysphagia for 3 months duration. The dysphagia was attributed to a right sided pharyngeal wall swelling. He gave a previous history

<sup>1</sup>University Medical Unit, National Hospital of Sri Lanka, Colombo, Sri Lanka

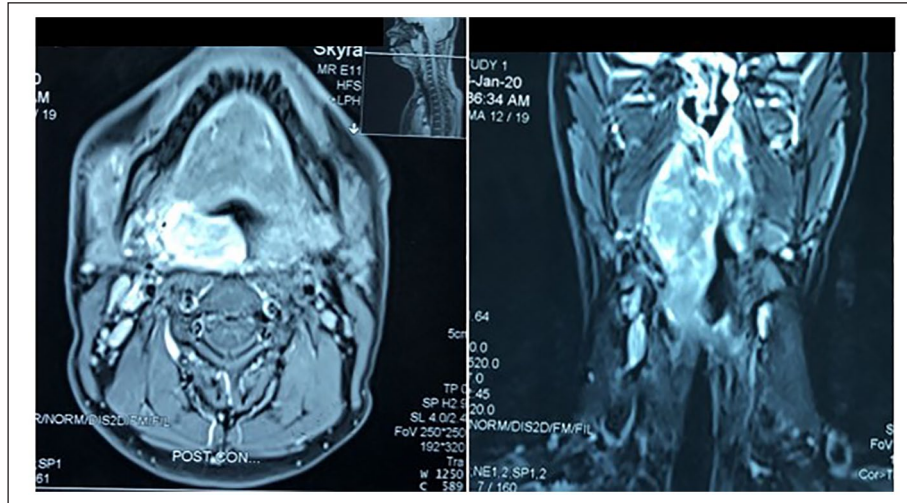
<sup>2</sup>Department of Clinical Medicine, Faculty of Medicine, University of Colombo, Colombo, Sri Lanka

<sup>3</sup>Department of Pathology, Faculty of Medicine, University of Colombo, Colombo, Sri Lanka

## Corresponding Author:

Mythily Aravinthan, University Medical Unit, National Hospital of Sri Lanka, Ward Place, Borella, Colombo 00800, Sri Lanka.  
Email: mailmythi@gmail.com





**Figure 1.** (Left-Axial plane; Right- Coronal plane)—MRI images showing the homogeneously enhancing right pharyngeal wall mass.

of recurrent and disabling sinusitis during the previous 4 years. Two years before, the patient had a swelling involving the right nasal mucosa and nasal bridge after an episode of sinusitis. This nasal swelling had responded to a short course of oral steroids. There had been recurrent swelling of the same nasal mucosal area for the next 14 months leading to nasal blockade accompanied by pansinusitis demonstrated on Contrast-enhanced Computed Tomography (CT). Each episode had responded to multiple antibiotic combinations, nasal sprays, and steroids.

Examination at current presentation demonstrated bilateral cervical lymph-node enlargement. The rest of his examination was unremarkable. Complete evaluation showed mild eosinophilia (800 cells/ $\mu$ L) and ESR of 23 mm/h. Magnetic resonance imaging demonstrated a homogeneously enhancing mass lesion (10 x 3.7 x 2.6 mm) extending from the base of the skull along the pharyngeal wall up-to the posterior larynx (as seen in Figure 1) with pansinusitis and regional lymphadenopathy.

The first biopsy of the lesion was reported as eosinophilic granulomatosis with polyangiitis based on the presence of eosinophilic infiltration, granulomatous inflammation and occasional fibrinoid necrosis. The patient was referred to the current center for specialized rheumatologic management. Antineutrophil cytoplasmic antibodies (cANCA; PR3 ANCA) were not detected. Urine full report did not show proteinuria or active sediment. Although the chest X-ray was normal, high-resolution CT of the chest demonstrated few non-specific ground-glass opacifications in the lung, which were deemed insignificant after a multidisciplinary discussion with the radiologist and the chest physician. Serum IgE level was 622 U/mL.

A repeat biopsy was done due to the atypical nature of the presentation, sites of lesions and absence of other organ system involvement. This biopsy showed (shown in Figure 2) vascular hyperplasia with prominent

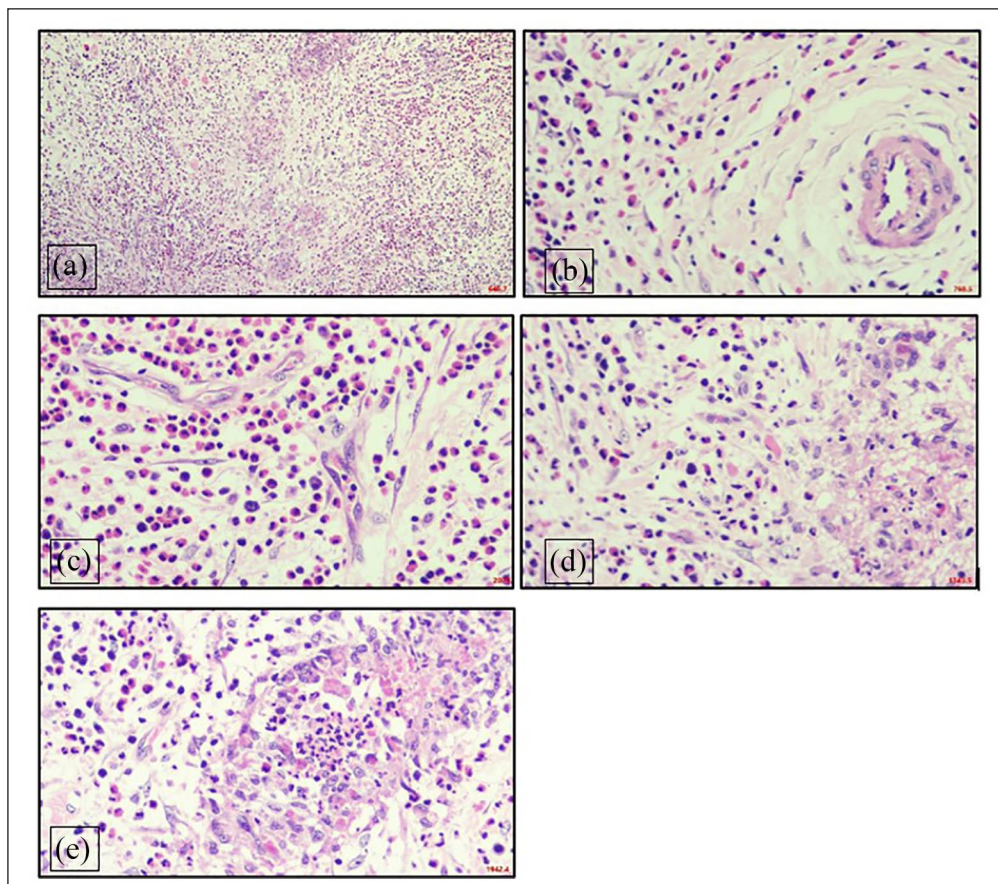
endothelial cells, dense mixed inflammatory infiltrate with eosinophilic predominance and granulomas with eosinophilic necrosis. Special stains with PAS, Grocott, Ziehl–Neelsen and Wade-fite excluded fungal or mycobacterial infective etiology. A clinico-pathological diagnosis of Kimura’s disease was made.

The patient responded to a second course of oral prednisolone at a dose of 30 mg daily for 3 months tapering down over one month. Eight months later at last follow up he remains in remission while on steroid sparing with Mycophenolate-mofetil.

## Discussion

### Kimura’s disease

Kimura’s disease (KD), was first described as a pathological entity in 1948 by Kimura et al.<sup>4</sup> It refers to a rare, benign, chronic inflammatory disorder seen commonly in young Asian men manifesting as subcutaneous swellings of the head and neck region. The disease characteristically involves swelling in the skin and subcutaneous tissues including salivary glands, lacrimal glands and lymph nodes. Only a minority of cases as depicted above present with isolated extracutaneous involvement of the oral cavity, palate, larynx or nasopharyngeal mucosa.<sup>7</sup> Peripheral eosinophilia and elevated IgE levels are characteristically seen. The possible pathogenesis from autoimmune or allergic hypersensitivity reaction is postulated partly because of this association.<sup>8</sup> However in cases of isolated oral cavity involvement compared to other extra-oral regions, eosinophilia and IgE response can be modest.<sup>7</sup> The only known organ involvement is renal disease with proteinuria occurring in approximately 16%; some of whom will develop glomerulonephritis in the form of minimal change disease or more aggressive forms like mesangioproliferative glomerulonephritis.<sup>1</sup>



**Figure 2.** Histology of the nasopharyngeal swelling. H&E stain. (a) Scanner view showing the granulomas and the background inflammatory infiltrate. (b) Perivascular inflammatory infiltrate with eosinophils. (c) Capillaries with plump endothelial cells surrounded by eosinophils. (d) Ill-defined Eosinophilic granuloma. (e) Granuloma with central eosinophilic necrosis.

### *Eosinophilic granulomatosis with polyangiitis*

On the other hand, EGPA is characterized by the classic triad of asthma, eosinophilia and multisystemic necrotizing vasculitis. Disease onset can be from 7 to 74 years and no gender or ethnic preponderance has been noted.<sup>9</sup> EGPA presents in three distinct phases. A first phase characterized by a prodromal illness with asthma, allergic rhinitis or rhinosinusitis for years preceding the more sinister manifestations is typical. This feature was demonstrated in our patient's presentation as well. The second phase of EGPA is characterized by eosinophilia and target organ damage involving the lungs, heart and gastro-intestinal tract. This patient had mild eosinophilia (800 cells/ $\mu$ L). However in EGPA eosinophilia, as per the American College of Rheumatology diagnostic criteria eosinophilia should be more than 1500 cells/ $\mu$ L. Further the few groundglass opacifications noted in the patient's HRCT chest were also deemed insignificant by the specialists ruling out lung involvement. The third and most sinister phase in EGPA is the vasculitic phase where mononeuritis multiplex, renal and skin involvement occur. While papular or nodular lesions involving the skin is the typical finding, a case with isolated subconjunctival swelling has been reported.<sup>3,10</sup>

### *Discriminating between KD and EGPA*

There is considerable histopathologic overlap between the two conditions as well. Eosinophilic infiltration is common to both entities which occurs in the background of dense mixed inflammatory infiltrate. Other two cardinal features in KD are vascular proliferation most prominent in the post capillary venules in case of the lymph-nodes and varying degree of stromal fibrosis.<sup>2</sup> The diagnostic feature in EGPA is the presence of necrotizing vasculitis of small-medium vessels and eosinophilic granulomas.<sup>3</sup> While the presence of granuloma is not characteristic of KD it is well-recognized.<sup>11-13</sup> Table 1 shows some of the discriminatory features between EGPA and KD.

This patient caused a clinical conundrum as he had features which overlapped between KD and EGPA. It was quite important to differentiate between the two because KD is largely a benign and self-limiting entity. Therefore, a meticulous multi-disciplinary approach was required. The modest eosinophilia seen in this patient, the absence of other organ involvement, the histopathological findings, the benign disease course and dramatic response to steroids helped corroborate the diagnosis.

**Table 1.** Discriminatory features between KD, EGPA and ALHE.

Characteristic	Kimura's Disease	Eosinophilic granulomatosis with polyangiitis	Angiolymphoid Hyperplasia with Eosinophilia
Epidemiology	Asian men; Age 20–50 y <sup>7</sup>	No gender or ethnic predilection; Age 7–74 y <sup>9</sup>	Women, 20–50 y <sup>5</sup>
Aetiopathogenesis	Self-limited aberrant allergic response to possible infective trigger patchy eosinophilic chronic inflammation <sup>1</sup>	Exaggerated Th2 allergic response to various allergens causing antibody and cytokine mediated vasculitis <sup>9</sup>	Unknown. Possible post-infectious, post-traumatic benign vascular proliferation <sup>5</sup>
Clinical features	Triad of painless subcutaneous head and neck masses + eosinophilia + high IgE <sup>1</sup>	Triphasic—Asthmatic prodrome to eosinophilia to small-medium vessel vasculitis <sup>3</sup>	Erythematous, unilateral papules and nodules in the head and neck <sup>6</sup>
Complications	Renal involvement in upto 16% with a wide spectrum of glomerulonephritis types <sup>1</sup>	Eosinophilia affecting lungs (86%), heart (27%–47%) and Gastrointestinal tract and vasculitis affecting nervous system (70%), kidneys (25%) and skin <sup>9</sup>	Generally no systemic involvement <sup>5</sup>
Laboratory investigation	Eosinophilia (> 5% or > 0.5 × 10 <sup>9</sup> /L) <sup>14</sup> High IgE level	Eosinophilia (> 10% or > 1.5 × 10 <sup>9</sup> /L) P-ANCA (in 40%) <sup>9</sup>	Eosinophilia or elevated IgE are rare <sup>6</sup>
Histology	Triad of eosinophil predominant cellular infiltrate, stromal fibrosis and vascular hyperplasia. Necrotizing vasculitis and granuloma are atypical but can be present <sup>8</sup>	Fibrinoid necrosis of small and medium vessels with vascular and extravascular eosinophilic granulomata <sup>9</sup>	Florid proliferation of vessels with plump endothelial cells containing vacuoles. Fibrinoid necrosis, atypia and fibrosis not seen. <sup>6</sup>
Prognosis	Benign course with good response to treatment but relapse is common. No malignant transformation <sup>8</sup>	Upto 92% remission rate with treatment, but disabling end organ damage may impair quality of life <sup>9</sup>	Resolution spontaneously or with treatment; Recur in upto 30%. But no metastatic lesions <sup>15</sup>

A reasonable differentiation could be made between KD and EGPA based on above findings, but there was a second dilemma making a close call between KD and Angiolymphoid hyperplasia with eosinophilia (ALHE). The latter two share a myriad of common features and it is exceedingly difficult to distinguish such that some authors conclude they may be representing different spectra of the same entity.<sup>5</sup> However there are a few characteristic differentiating features (Refer Table 1). In above case, starting from the male gender and the extracutaneous location of the lesion to the presence of lymphadenopathy, eosinophilia and elevated IgE were more supportive of KD. ALHE lesions typically involve skin and subcutaneous tissue. While lymphadenopathy and eosinophilia may be seen in a minority of ALHE, elevated IgE levels is exceedingly rare. Further, in the histology, the predominant finding was mixed, eosinophil predominant granulomatous inflammation with some degree of vascular proliferation and fibrosis which was in keeping with KD. Necrotizing vasculitis, granulomata and fibrosis seen in this case are not seen in ALHE. In ALHE florid vascular proliferation with “hobnail” type cells containing abundant cytoplasm is the cardinal finding.<sup>16</sup> Mere presence of plump or cuboidal endothelial cells can be seen in KD.<sup>5,6,15</sup>

The distinction between the latter two, from the patient's perspective remained comparatively less critical as the treatment options for KD and ALHE remain largely the same and both have a benign course (Table 1). Therapeutic options for KD include surgical excision, steroids, steroid sparing with cyclosporin/mycophenolate or other cytotoxic therapy and

radiotherapy all of which have shown variable response with around one in four cases recurring despite resolution.<sup>2,17</sup>

A definitive diagnosis addressed the patient's concern significantly as, lack of a diagnosis over two years was his biggest concern.

## Conclusion

KD is a benign relapsing chronic inflammatory condition which is often confused with other inflammatory diseases due to its rarity. We present this case to emphasize the importance of considering conditions like KD in the differentials of atypical presentation of EGPA and related conditions.

## Acknowledgements

The Authors would like to acknowledge the members of the multidisciplinary team involving the Radiology, Pathology and medical units who actively participated in securing the diagnosis. We also acknowledge the timely referral by the ENT surgeon which helped avoid unnecessary burden in the form of surgery or strong immunomodulators for the patient.

## Declaration of conflicting interests

The author(s) declared no potential conflicts of interest with respect to the research, authorship, and/or publication of this article.

## Funding

The author(s) received no financial support for the research, authorship, and/or publication of this article.

## Ethics approval

Our institution does not require ethical approval for reporting individual cases or case series.

## Informed consent

Written informed consent was obtained from the patient for their anonymized information to be published in this article.

## ORCID iD

Mythily Aravinthan  <https://orcid.org/0000-0002-2335-8553>

## References

1. Shetty AK, Beaty MW, Mcguirt WF, et al. Kimura's disease: a diagnostic challenge. *Pediatrics* 2002; 110(3): E39.
2. Chen H, Thompson LDR, Aguilera NSI, et al. Kimura disease: a clinicopathologic study of 21 cases. *Am J Surg Pathol* 2004; 28(4): 505–513.
3. Greco A, et al. Churg–Strauss syndrome. *Autoimmun Rev* 2015; 14(4): 341–348.
4. Kimura T, Yoshimura S and Ishikawa E. Unusual granulation combined with hyperplastic changes of lymphatic tissue. *Trans Soc Pathol Jpn* 1948; 37: 179–180.
5. Buder K, Ruppert S, Trautmann A, et al. Angiolymphoid hyperplasia with eosinophilia and Kimura's disease—a clinical and histopathological comparison. *J Dtsch Dermatol Ges* 2014; 12(3): 224–228.
6. Chong W, Thomas A and Goh C. Kimura's disease and angiolymphoid hyperplasia with eosinophilia: two disease entities in the same patient: case report and review of the literature. *Int J Dermatol* 2006; 45(2): 139–145.
7. Terakado N, Sasaki A, Takebayashi T, et al. A case of Kimura's disease of the hard palate. *Int J Oral Maxillofac Surg* 2002; 31(2): 222–224.
8. Khoo B-P and Chan R. Kimura disease: 2 case reports and a literature review. *Cutis* 2002; 70(1): 57–64.
9. Piram M, Maldini C and Mahr A. Effect of race/ethnicity on risk, presentation and course of connective tissue diseases and primary systemic vasculitides. *Curr Opin Rheumatol* 2012; 24(2): 193–200.
10. Manzouri B, et al. Bilateral subconjunctival masses as a rare presentation of Churg–Strauss syndrome. *Ocul Immunol Inflamm* 2013; 21(4): 333–336.
11. Hosaka N, et al. Kimura's disease with unusual eosinophilic epithelioid granulomatous reaction: a finding possibly related to eosinophil apoptosis. *Hum Pathol* 2002; 33(5): 561–564.
12. Wade B, Arteaga C, Kraemer P, et al. Soft tissue eosinophilic granuloma or Kimura's disease: a case report. *Med Trop* 1998; 58(4 Suppl): 482–484.
13. Amemiya T. Eosinophilic granuloma of the soft tissue in the orbit. *Ophthalmologica* 1981; 182(1): 42–48.
14. Liu L, Chen Y, Fang Z, et al. Kimura's disease or IgG4-related disease? A case-based review. *Clin Rheumatol* 2015; 34(2): 385–389.
15. Ramchandani PL, Sabesan T and Hussein K. Angiolymphoid hyperplasia with eosinophilia masquerading as Kimura disease. *Br J Oral Maxillofac Surg* 2005; 43(3): 249–252.
16. Alexiev BA. Epithelioid haemangioma—Pathology Outlines.com. <https://www.pathologyoutlines.com/topic/softtissueepithelioidhemangioma.html>
17. Hobeika CM, Mohammed TLH, Johnson GL, et al. Kimura's disease: case report and review of the literature. *J Thorac Imaging* 2005; 20(4): 298–300.