



## Case Report

# Acute acalculous cholecystitis in a pediatric dengue hemorrhagic fever patient: A case report, lesson learned from limited resource setting

Amallia Nuggetsiana Setyawati<sup>a,b,c,\*</sup>, Kusmiyati Tjahjono DK<sup>a</sup>, Melissa Angela Chionardes<sup>a</sup>, Nahwa Arkhaesi<sup>b</sup>

<sup>a</sup> Department of Medical Biology and Biochemistry, Faculty of Medicine Diponegoro University, Semarang, Indonesia

<sup>b</sup> Department of Pediatrics, National Diponegoro Hospital, Semarang, Indonesia

<sup>c</sup> Division of Pediatrics, Williambooth General Hospital, Semarang, Indonesia



## ARTICLE INFO

## Keywords:

DHF  
Acalculous cholecystitis  
Abdominal pain  
Atypical symptoms

## ABSTRACT

**Introduction:** Dengue fever (DF) is endemic in numerous regions of Indonesia with primary clinical features such as high fever as well as pullout of intravascular fluid and albumin leakage, which provokes pleural effusion, hypoproteinemia, and blood hemoconcentration. However, the incidence of abdominal pain as a clinical manifestation of DF, which refers to acalculous cholecystitis, is rare.

**Case presentation:** An 11-year-old female was admitted to the hospital with fever, headache, and myalgia. Blood examination resulted in low platelet count and positive IgM Dengue antibody test. On the third day, the patient felt sharp abdominal pain. Abdominal ultrasound showed cholecystitis, cholestasis, pleural effusion, ascites, and laboratory finding showed increased C-reactive protein. The management was conservative and discharged at the 7th day.

**Discussion:** The acalculous cholecystitis in Dengue Fever/Dengue Hemorrhagic fever (DF/DHF) is challenging in diagnosis due to atypical presentations. Several proposed mechanisms are critical illness, including direct invasion of the gallbladder epithelial cells, vasculitis, stasis of biliary flow, obstruction of the biliary tree, ischemia, and sequestration. The actual mechanism of the dengue virus has been proposed that direct viral incursion of the gallbladder may yield edema and exudation. Abdominal ultrasonography is considered to diagnose acute acalculous cholecystitis (AAC) in children.

**Conclusion:** Understanding pathophysiology of the acalculous cholecystitis in DF/DHF patients and atypical presentation of sharp abdominal pain help physicians for early diagnosis and management both in monitoring and patient care management. Abdominal ultrasonography can help physicians to diagnose AAC.

## 1. Introduction

Dengue fever (DF) is a febrile illness caused by dengue viruses (DENV). This viral infection varies clinically from asymptomatic to severe illness that may lead to death if it is not properly managed. Undifferentiated febrile illness, dengue fever, dengue hemorrhagic fever, dengue shock syndrome, and unusual dengue or expanded dengue syndrome are categories of fever [1]. The mortality rate of dengue hemorrhagic fever (DHF) has dramatically decreased up to 1% in several countries in the past 20 years [2]. There are classical signs of dengue

infection such as vomiting, abdominal pain, sweating, and breathlessness as well as elevated ALT (alanine aminotransferase) [3]. Atypical presentations of DF and DHF are increasingly identified in endemic areas. The thickening gallbladder wall is a non-classical finding that is often found in severe dengue [4]. Diarrhea and other possible findings of neurological manifestations are categorized as possible signs and symptoms of coinfections, comorbidities, or difficulties [5]. Mild hepatitis and dysregulation of transaminase without jaundice may also occur in DF [6]. In DF there may be secondary acalculous cholecystitis and it might be challenging to determine the diagnosis. The need for surgical

**Abbreviations:** AAC, Acute acalculous cholecystitis; DF, Dengue fever; DHF, Dengue hemorrhagic fever; DSS, Dengue shock syndrome; AST, Aspartate transferase; ALT, Alanine aminotransferase.

\* Corresponding author. Department of Medical Biology and Biochemistry, Faculty of Medicine Diponegoro University, Semarang, Indonesia.

**E-mail addresses:** [amallia.setyawati@fk.undip.ac.id](mailto:amallia.setyawati@fk.undip.ac.id) (A.N. Setyawati), [kusmiceria@gmail.com](mailto:kusmiceria@gmail.com) (K. Tjahjono DK), [melissaangelac@gmail.com](mailto:melissaangelac@gmail.com) (M.A. Chionardes), [narkhaesi@yahoo.co.id](mailto:narkhaesi@yahoo.co.id) (N. Arkhaesi).

<https://doi.org/10.1016/j.amsu.2022.104437>

Received 2 June 2022; Received in revised form 4 August 2022; Accepted 12 August 2022

Available online 19 August 2022

2049-0801/© 2022 The Authors. Published by Elsevier Ltd on behalf of IJS Publishing Group Ltd. This is an open access article under the CC BY-NC-ND license (<http://creativecommons.org/licenses/by-nc-nd/4.0/>).

intervention has not been recommended for this case [7]. Acute acalculous cholecystitis (AAC) is the condition of an inflamed gallstone with the absence of a gallstone. This condition occurs in 50%–70% of childhood acute cholecystitis. Several viral illnesses (cytomegalovirus, hepatitis, herpes, Epstein-Barr virus) may cause AAC in children [8]. This case report has been reported in line with the SCARE Criteria [9].

## 2. Case presentation

An 11-year-old female was admitted to the hospital with a high fever, nausea, severe weakness, myalgia, and main body ache. On initial examination at the emergency room, the patient was conscious but pale and ill. The body temperature was 39.5 °C, pulse 120 beats per minute (bpm), and blood pressure 110/75 mmHg. There was neither rash, spontaneous bleeding nor jaundice. The laboratory findings showed hemoglobin 14.8 g/dl, hematocrit 40%, and platelet count 140000/mm<sup>3</sup>. Dengue IgM antibodies were positive. The SARS-COV2 antigen nasopharynx test was negative. The other laboratory findings are shown in Table 1. A clinical diagnosis suspect of Dengue fever was made. The patient was given the standard diet. On the 2nd day, the patient was still feverish, looked ill, and short of breath. The patient felt nausea and abdominal bloating. The platelet count showed 78000/mm<sup>3</sup>. On the 3rd day, the platelet count decreased dramatically to 15000/mm<sup>3</sup>. Blood pressure was 110/90 mmHg, and pulse was 90 bpm. The chest X-ray on 3rd day revealed a remarkable pleura effusion with a pleural effusion index (PEI) of 38.13%, as shown in Fig. 1, and the patient was managed in the intensive care unit.

The platelet count decreased dramatically on the 4th day and severe abdominal pain emerged. Abdominal ultrasonography is shown in Fig. 2. Liver function test on the 5th day showed elevated AST 151 IU/L and ALT 59 IU/L. The C-reactive protein level increased by 14.4 mg/L. The patient was managed as a patient with DHF and AAC complications. The patient received conservative treatment. Intravenous antibiotics were given on the 7th day of fever onset for 4 days. No blood transfusion was performed, and there was no hematoma. The abdominal pain and bloating sensation lasted for 3 days. The patient's condition improved gradually. The patient was discharged from the hospital on the 7th day and came for a follow-up post-treatment. The liver function enzyme was restored after treatment.

## 3. Discussion

Dengue hemorrhagic fever is emerging as an endemic disease in Indonesia, with an increasing incidence trend over the past 50 years. However, the fatality rate of DHF has decreased since 1980. The highest incidence of DHF occurred in Java Island. *Aedes aegypti* mosquito breeds on relatively clean static water and it is a daylight feeder. Both characteristics make it difficult to be controlled. In this case, an 11-year-old female with DHF and AAC complications was presented.

In this patient, platelet count decreased until the 4th day of admission. Thrombocytopenia is assumed due to bone marrow suppression, destruction, as well as lengthening of the platelet life cycle. It is generally observed in both mild and severe dengue syndrome, associated with clinical outcomes. Dengue infection is correlated with thrombocytopenia and causes hemorrhage, which is assumed due to the binding of DENV NS1 to TLR4 on platelets. Because of increased capillary

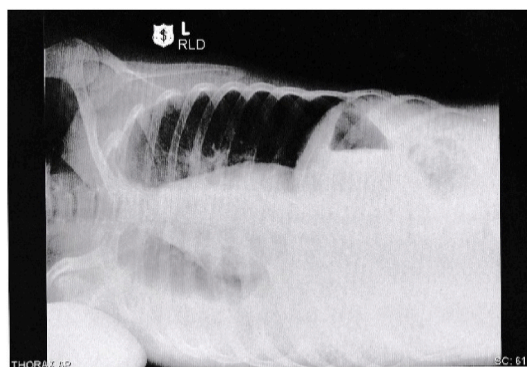


Fig. 1. Chest X-ray on 3rd day showed a remarkable pleura effusion with PEI 38.13%.

permeability, the fluid shift may cause hemoconcentration, cavitory effusions, and hypoproteinemia in DHF patients.

In this case, liver function test on the 5th day elevated. Liver dysfunction may vary from mild injury marked with elevated transaminase enzymes to severe injury with jaundice and it appears more in DHF and Dengue Shock Syndrome (DSS) cases than in the DF group. The liver enzymes may increase up to >10 fold increase in the liver enzymes in by 17.27% of cases. However, previous study observed there was no association between the magnitude of liver enlargement, hepatic tenderness, and abnormalities of liver functions [10].

The patient developed sharp acute abdominal pain on day 3–5 and the abdominal ultrasonography showed acalculous cholecystitis. An acute acalculous cholecystitis is the inflammation of the gallbladder without evidence of calculi or sludge, which occurs in 5–10% of all acute cholecystitis cases. Liver involvement in AAC with the fulminant course is high mortality due to gangrene, perforation, and empyema. This type of cholecystitis occurs in critically ill patients, postoperative patients, after severe trauma, prolonged fasting, or sepsis. The pathophysiology of AAC in critical illness is poorly understood. There are several proposed mechanisms, namely critical illness, including direct invasion of the gallbladder epithelial cells, gallbladder vasculitis, obstruction of the biliary tree, and sequestration [11]. Stasis of biliary flow may cause changes in bile composition and injury of gallbladder mucosa. Occlusion of multiple arteries and derangement of microcirculatory lead to ischemia of the gallbladder, which is considered the hallmark of AAC development. Proinflammatory mediators, namely eicosanoids, may induce coagulation and inflammation. The actual mechanism of AAC pathology from the dengue virus remains unknown. However, it has been proposed that direct viral incursion of the gallbladder may yield edema and exudation [12]. The acalculous cholecystitis in this patient was confirmed based on the absence of abdominal pain in the patient's history, the thickened gallbladder wall of over 3.5 mm of ultrasonography finding with an increased wall thickness of the gallbladder, increased CRP marker and abnormal liver function test.

The acalculous cholecystitis in DF/DHF is challenging in diagnosis due to atypical presentations, causes lack of detection and late diagnosis in severe condition. Sharp clinical suspicion and early dengue serological assessment are recommended in questionable cases of AAC with fever in dengue-endemic areas to confirm the infection, so unnecessary

Table 1  
Serial blood analysis.

Day of febrile	3	4	5	6	7	8	9
Admission day	1	2	3	4	5	6	7
Hemoglobin (gr/dL)	14.8	13.5	16.1	16.1	16.9	16.4	13.0
Hematocrit (%)	40	39.4	46.7	46.7	48.3	45.8	37.6
Leucocyte (10 <sup>3</sup> /mm <sup>3</sup> )	4300	2700	3700	3700	5300	10200	7600
Platelet (10 <sup>3</sup> /mm <sup>3</sup> )	140000	78000	15000	15000	29000	45000	183000

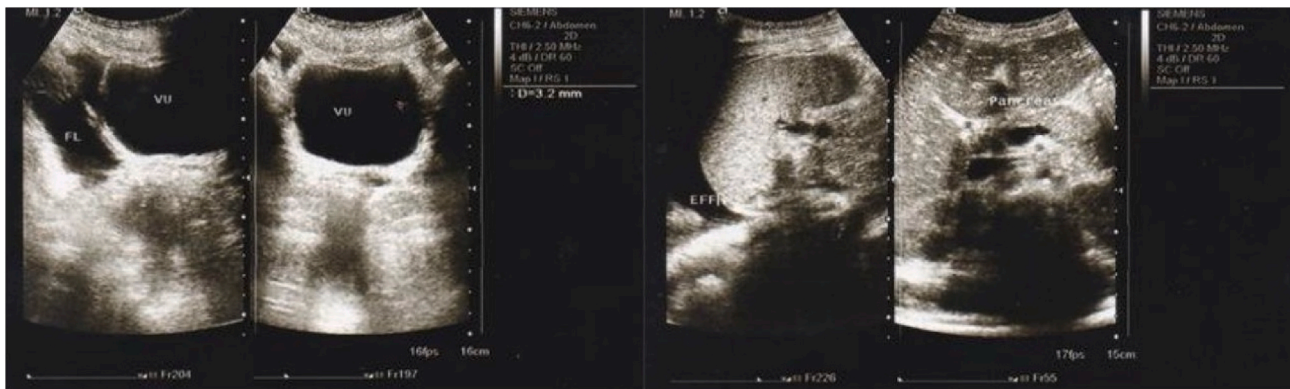

Fig. 2. Abdominal ultrasonography showed acalculous cholecystitis, right cholestasis, ascites on 5th day.

surgical morbidity due to the presence of DF can be avoided [13]. Initial hematological laboratory result which is inconjunct with abdominal ultrasonography findings can help physicians to consider this diagnosis [14]. The involvement of cholecystitis may lead to gallbladder wall thickening (GBWT). This sign appears due to increased capillary permeability. The hallmarks of ultrasonography findings on AAC diagnosis in pediatrics rely on diagnostic criteria as follows: (1) increment of gallbladder wall thickness ( $\geq 3.5$  mm), (2) Pericholecystic fluid, (3) Appearance of mucosal membrane sludge, (4) Gall bladder distension. The thickness of the gallbladder above 3 mm is significantly associated with more severe dengue cases, whereas the thickness greater than 5 mm is associated with the risk of threatening hypovolemic shock [15]. Computerized tomography (CT) is considered as accurate as ultrasonography in diagnosing AAC. However, its radiological exposure restricts its use in the pediatric age and CT is not always available, more expensive and cannot be performed bedside [13]. Ultrasonography findings and laboratory parameters could not identify the causative agent of AAC. Bacterial AAC usually manifests with leukocytosis and increased inflammatory markers. Acute acalculous cholecystitis due to viruses has better prognosis than bacterial and improved with a conservative therapy, such as adequate intravenous fluid therapy, analgesic, and antibiotics [16].

#### 4. Conclusion

Understanding the pathophysiology of acalculous cholecystitis in DF/DHF patients and atypical presentation of sharp abdominal pain help physicians with early diagnosis and management both in monitoring and patient care management. Abdominal ultrasonography can help physicians to diagnose AAC.

#### Ethical approval

This article type (case report) does not require a formal ethical committee approval. Access to data was approved by the head of the department.

#### Sources of funding

No Source of Funding

#### Author contribution

Amallia Nuggetsiana Setyawati: study concept, data collection and interpretation, drafting and editing the manuscript.

Melissa Angela Chionardes: data collection, drafting and editing the paper.

Kusmiyati Tjahjono DK: Data collection, drafting and editing the paper.

Nahwa Arkhaesi: Data collection, final editing of the manuscript.

#### Registration of research studies

This is not an original research project involving human participants in an interventional or an observational study but a case report. This registration was not required.

#### Guarantor

Amallia Nuggetsiana Setyawati.

#### Consent

Written informed consent was obtained from parents of the patient for publication of this case report and accompanying images. A copy of the written consent is available for review by the Editor-in-Chief of this journal on request.

#### Patient perspective

The patient did not present his point of view.

#### Provenance and peer review

Not commissioned, externally peer-reviewed.

#### Declaration of competing interest

No Conflicts of Interest.

#### Appendix A. Supplementary data

Supplementary data to this article can be found online at <https://doi.org/10.1016/j.amsu.2022.104437>.

#### References

- [1] S. Kalayanarooj, Clinical manifestations and management of dengue/DHF/DSS, *Trop. Med. Health* 39 (2011) 83–87, <https://doi.org/10.2149/tmh.2011-S10>.
- [2] K.M. Tomashek, C.J. Gregory, A. Rivera Sánchez, M.A. Bartek, E.J. Garcia Rivera, E. Hunsperger, J.L. Muñoz-Jordán, W. Sun, Dengue deaths in Puerto Rico: lessons learned from the 2007 epidemic, *PLoS Neglected Trop. Dis.* 6 (2012), <https://doi.org/10.1371/journal.pntd.0001614>.
- [3] S. Badreddine, F. Al-Dhaheri, A. Al-Dabbagh, A. Al-Amoudi, M. Al-Ammari, N. Elatassi, H. Abbas, R. Magliah, A. Malibari, H. Almoallim, Dengue fever: clinical features of 567 consecutive patients admitted to a tertiary care center in Saudi Arabia, *Saudi Med. J.* 38 (2017) 1025–1033, <https://doi.org/10.15537/smj.2017.10.20965>.
- [4] M. de Araújo Tavares, G.A. Pivoto João, M.S. Bastos, J.B. Lima Gimaque, A. C. Gomes Almeida, T.T. Ngo, C. Bahamon, D.C. Baia-Da-Silva, W.M. Monteiro, M. P. Gomes Mourão, M.V. Guimaraes Lacerda, Clinical relevance of gallbladder wall

- thickening for dengue severity: a cross-sectional study, PLoS One 14 (2019) 1–10, <https://doi.org/10.1371/journal.pone.0218939>.
- [5] A. Laul, P. Laul, V. Merugumala, R. Pathak, U. Miglani, P. Saxena, Clinical profiles of dengue infection during an outbreak in Northern India, *J. Trop. Med.* 2016 (2016), <https://doi.org/10.1155/2016/5917934>.
- [6] J. Yudhishdran, R. Navinan, A. Ratnatilaka, S. Jeyalakshmy, Dengue haemorrhagic fever presenting with cholestatic hepatitis: Two case reports and a review of literature, *BMC Res. Notes* 7 (2014) 1–5, <https://doi.org/10.1186/1756-0500-7-568>.
- [7] M. Shamim, Frequency, pattern and management of acute abdomen in dengue fever in Karachi, Pakistan, *Asian J. Surg.* 33 (2010) 107–113, [https://doi.org/10.1016/S1015-9584\(10\)60019-X](https://doi.org/10.1016/S1015-9584(10)60019-X).
- [8] D. Poddighe, V. Sazonov, Acute acalculous cholecystitis in children, *World J. Gastroenterol.* 24 (2018) 4870–4879, <https://doi.org/10.3748/wjg.v24.i43.4870>.
- [9] R.A. Agha, T. Franchi, C. Sohrabi, G. Mathew, A. Kerwan, The SCARE 2020 guideline: updating consensus surgical CAse REport (SCARE) guidelines, *Int. J. Surg.* 84 (2020) 226–230, <https://doi.org/10.1016/j.ijssu.2020.10.034>, 2020.
- [10] K. Jagadishkumar, P. Jain, V.G. Manjunath, L. Umesh, Hepatic involvement in dengue fever in children, Iran, *J. Pediatr.* 22 (2012) 231–236.
- [11] I. Markaki, A. Konsoula, L. Markaki, N. Spervasilis, M. Papadakis, Acute acalculous cholecystitis due to infectious causes, *World J. Clin. Cases.* 9 (2021) 6674–6685, <https://doi.org/10.3280/PU2021-003009>.
- [12] P.S. Barie, S.R. Eachempati, Acute acalculous cholecystitis, *Gastroenterol. Clin. N. Am.* 39 (2010) 343–357, <https://doi.org/10.1016/j.gtc.2010.02.012>.
- [13] B. Jayasundara, L. Perera, A. de Silva, Dengue fever may mislead the surgeons when it presents as an acute abdomen, *Asian Pac. J. Trop. Med.* 10 (2017) 15–19, <https://doi.org/10.1016/j.apjtm.2016.12.010>.
- [14] S. Pothapregada, B. Kamalakannan, M. Thulasingham, Clinical profile of atypical manifestations of dengue fever, *Indian J. Pediatr.* 83 (2016) 493–499, <https://doi.org/10.1007/s12098-015-1942-9>.
- [15] M.W. Setiawan, T.K. Samsi, T.N. Pool, D. Sugianto, H. Wulur, Gallbladder wall thickening in dengue hemorrhagic fever: an ultrasonographic study, *J. Clin. Ultrasound* 23 (1995) 357–362, <https://doi.org/10.1002/jcu.1870230605>.
- [16] D. Poddighe, M. Tresoldi, A. Licari, G.L. Marseglia, Acalculous acute cholecystitis in previously healthy children: general overview and analysis of pediatric infectious cases, *Int. J. Hepatol.* 2015 (2015), <https://doi.org/10.1155/2015/459608>.