

Efficacy of *Acorus calamus* on collagen maturation on full thickness cutaneous wounds in rats

Thangavel Ponrasu, Karuppanan Natarajan Madhukumar¹, Moorthy Ganeshkumar, Kuttalam Iyappan², Vilvanathan Sangeethapriya, Vinaya Subramani Gayathri³, Lonchin Suguna

Departments of Biochemistry, and ²Chemical Engineering Division, Council of Scientific and Industrial Research-Central Leather Research Institute, ¹Shirmpex Biotech Services, ³Department of Chemistry, SSN College of Engineering, Kalavakkam, Chennai, Tamil Nadu, India

Submitted: 19-06-2013

Revised: 17-08-2013

Published: 28-05-2014

ABSTRACT

Background: The rhizomes of *Acorus calamus* and their essential oil are widely used in the flavoring industry and production of alcoholic beverages in Europe. Recent reports have confirmed the presence of several pharmacological components in the rhizomes of *A. calamus*. **Objective:** The objective of this study was to find out the efficacy of topical administration of ethanolic extract of *A. calamus* on dermal wound healing in rats. Wound healing is a natural process occurring in living organisms, which results in a complete or partial remodeling of injured tissue and ultimately progresses to the formation of a fibrous scar. Several natural products have been reported to augment the wound healing process. **Materials and Methods:** An ethanolic extract of *A. calamus* was prepared and its wound-healing efficacy was studied. An excision wound was made on the back of the rat and 200 μ L (40 mg/kg body weight) of the *A. calamus* extract was applied topically once daily for the treated wounds. The control wounds were treated with 200 μ L of phosphate buffered saline. **Results:** The granulation tissues formed were removed at 4, 8 and 12 days and biochemical parameters such as deoxyribonucleic acid, total protein, total collagen, hexosamine and uronic acids were measured. The amount of type I/III collagen formed in control and treated wound tissues was evaluated by sodium dodecyl sulfate-polyacrylamide gel electrophoresis. The epithelialization time, tensile strength and histological examination of the wounds were also studied. Biochemical analyses of the granulation tissues revealed a significant increase in collagen, hexosamine and uronic acid when compared with the control. The tensile strength of extract treated wounds was found to increase by 112%. A significant reduction in lipid peroxide levels suggested that *A. calamus* possesses antioxidant components. **Conclusions:** The results strongly confirm the beneficial effects of *A. calamus* in augmenting the wound healing process.

Key words: *Acorus calamus*, collagen, epithelialization, sodium dodecyl sulfate-polyacrylamide gel electrophoresis, tensile strength, wound healing

INTRODUCTION

Healing is a multifaceted and intricate process initiated in response to tissue injury that restores the function and integrity of damaged tissues.^[1] Wound healing involves continuous cell-cell and cell-matrix interactions that allow the process to proceed in three overlapping phases such as inflammation (0-3 days), cellular proliferation (3-12 days) and remodeling (3-6 months).^[2] Several other natural products and medicinal plants enhance the process of

wound healing.^[3,4] The therapeutic benefits of secondary metabolites of plants have also been focused in many investigations.^[5] We have been screening topical evergreen plants as agents for wound healing since two decades. Here, we report the efficacy of alcoholic extract of *A. calamus* on dermal wound healing in rats.

A. calamus (Family: *Acoraceae*) is a perennial plant, the rhizome has many pharmacological activities; the ethanol extract has anticellular and immunosuppressive properties.^[6] The rhizomes of *A. calamus* and their essential oil (*calamus* oil) are widely used in the flavoring industry and production of alcoholic beverages in Europe. Recent reports have confirmed the presence of several pharmacological components in the alcoholic extract of rhizomes of *A. calamus*.^[7]

Address for correspondence:

Dr. Lonchin Suguna, Department of Biochemistry, Council of Scientific and Industrial Research-Central Leather Research Institute, Adyar, Chennai - 600 020, India.
E-mail: slonchin@yahoo.co.uk

Access this article online

Website:

www.phcog.com

DOI:

10.4103/0973-1296.133283

Quick Response Code:



Conventionally, it is used as a constituent for many mixture preparations used for the treatment and management of headache, migraine, body ache, severe inflammatory pain and vincristine-induced painful neuropathy.^[8] Phytochemical analyses have shown that *A. calamus* possesses glycosides, flavonoids, saponins, tannins, polyphenols, mucilage, volatile oil and few bitter principles.^[8] The aqueous and hydro-alcoholic extracts have also been shown to possess lipid lowering and neuropharmacological actions.^[9]

Recently, the role of β -asarone, a component of *A. calamus*, has been reported for its inhibitory effect on adipogenesis in 3T3-L1 cells.^[10] Wound healing activity of ethanolic extract of *A. calamus* leaves has been studied and reported wherein, the wounds were treated with the plant extract in an ointment form and the results were compared with a standard drug, povidone-iodine.^[11] However, in this investigation, experiments were carried out to find out the efficacy of ethanolic extract of the rhizomes of *A. calamus* on wound repair process by measuring various biochemicals, biophysical parameters related to wound healing. Histological evaluation of wounds was also studied to confirm the results. The efficacy of the extract on collagen characteristics has also been carried out. The ratio of Type I/III collagen has also been studied and found out that the alcoholic extract of *A. calamus* enhances all phases of wound healing.

MATERIALS AND METHODS

Chemicals

Acrylamide, ammonium per sulfate, bovine serum albumin, calf thymus deoxyribonucleic acid (DNA), chloramine-T D-glucuronic acid and L-hydroxyproline were from Sigma Chemical Company, St. Louis, USA. *p*-dimethyl aminobenzaldehyde and Folin's Phenol reagent were from Loba Chemie, Mumbai, India. Methyl cellosolve was obtained from Merck, Darmstadt, Germany. All other reagents were high analytical grade.

Extract preparation

The rhizome of *A. calamus* obtained locally were minced, weighed, powdered and homogenized in 10-20 volumes (by weight) of 70% ethanol and filtered to yield a viscous supernatant. This was used as the crude extract. An aliquot of the extract was lyophilized and weighed. About 75% by weight of the starting dry material was recovered in this fraction. The lyophilized powder was reconstituted in phosphate buffered saline (PBS).

Animals

Male rats of Wistar strain weighing 180-200 g were chosen and divided into two groups of 6 each for the present

study. The animals were maintained on clean, sterile, polyvinyl cages and fed with commercial rat feed from M/S Hindustan Lever Ltd., India (mixed with wheat flour in the ratio of 1:1 (w/w)). Food and water were provided *ad libitum* to the animals. All procedures were carried out according to the Institutional Animal Care and Use Committee. A formal approval from the Animal Ethical Committee of our institute has also been obtained.

Wound creation and drug administration

A 2 cm² (4 cm) full thickness open excision wound was made on the back of the rat as reported in our earlier studies.^[12] A total number of 48 animals were used for the whole study. The animals were divided into two groups (control and treated), each group containing six rats. Each animal was given a light ether anesthesia and shaved on its back under aseptic conditions. Wound was created with a sterile scalpel as per the rules of Committee for the Purpose of Control and Supervision of Experiments on Animals under sterile conditions. About 200 μ l of the plant extract (lyophilized powder reconstituted in PBS at a concentration of 40 mg/Kg body weight) was applied topically on the wounds once daily until the wounds healed completely. The control wounds were treated with 200 μ l of PBS.

The animals were sacrificed at different time point intervals such as 4th, 8th and 12th day. The wound tissues formed were removed and used for various biochemical estimations. Separate groups of animals, 6 each for control and experiment were maintained to find out the period of epithelialization and rate of wound contraction.

For tensile strength determination, a 6 cm long linear full thickness incision wound was made on either side of the midline. After the wounds had been wiped off to remove blood, if any, intermittent sutures were placed 1 cm apart. The sutures were removed after the 7th day post-wounding and the tissues were removed on 10th day to determine the tensile strength of the wound tissues according to the method of Vogel.^[13]

Biochemical estimations

Protein and DNA of wet granulation tissues were extracted in 5% trichloroacetic acid (TCA) as per Porat *et al.*^[14]. Briefly, 10 mL of 5% TCA was added to the tissue (100 mg wet weight of tissue) maintained at 90°C for 30 min in a water bath to extract protein and DNA. The solution was centrifuged and the supernatant was used to estimate DNA by the method of Burton^[15] and protein by the method of Lowry *et al.*^[16] To estimate the collagen and hexosamine, the tissue samples were defatted in chloroform: methanol (2:1) and dried in acetone, before use. Weighed tissues was first hydrolyzed in 6 N HCl for 18 h at 110°C, evaporated to dryness and then made up with a known volume of water.

Collagen and hexosamine were estimated by the method of Woessner^[17] and Elson and Morgan,^[18] respectively. Lipid peroxide levels in granulation tissues were determined by the thiobarbituric acid reaction.^[19]

Fractionation of collagen was performed by the method of Piez.^[20] Briefly, for the neutral salt soluble collagen, the wound tissue was minced well, homogenized in 10 volumes of a neutral salt solvent (1.0 mol/L NaCl, 0.05 mol/L Tris, pH 7.5) containing 20 mmol/L ethylenediaminetetraacetic acid and 2.0 mmol/L N-ethyl maleimide and stirred for 24 h. The suspension was then centrifuged at 35,000 g for 1 h at 4°C and the extraction was repeated with the pellet. The supernatants were pooled and an aliquot was used for the assay of hydroxyproline^[17] and for the acid-soluble collagen, the residue obtained was resuspended in 10 volumes of 0.5 mol/L acetic acid and extracted for 24 h with constant stirring, after which the contents were centrifuged at 35,000 g for 1 h at 4°C. The pellet was re-extracted with acetic acid, the supernatants were pooled and an aliquot was used for the determination of hydroxyproline.^[17] Finally, for the pepsin-soluble collagen, the residue obtained after acid extraction was resuspended in 0.5 mol/L acetic acid containing 100 mg pepsin/g wet tissue. Digestion was performed for 24 h, followed by centrifugation at 35,000 g for 1 h at 4°C and reextraction. Aliquots of pooled supernatants were used for hydroxyproline measurement.^[17] The susceptibility of insoluble collagen to denaturing agents like urea and potassium thiocyanate was analyzed by the method of Adam *et al.*^[21]

Interrupted sodium dodecyl sulfate-polyacrylamide gel electrophoresis

The sub-unit composition of the isolated collagen was investigated by interrupted sodium dodecyl sulfate-polyacrylamide gel electrophoresis (SDS-PAGE.^[22] Briefly, collagen bands were separated by SDS-PAGE) using 3% stacking gel with 5% separating gel and Coomassie brilliant blue staining.

Biophysical analyses

The wounds were also inspected for the extent of epithelialization and calculated as days required for shedding of eschar without any raw wound left behind. The excision wounds were traced on a transparent graph paper and changes in wound size were measured planimetrically. Reduction in wound size (reflecting the rate of wound contraction) was calculated as a percentage of the original wound size. The tensile strength of wound tissues was measured by the method of Vogel.^[13]

Histology

The rats were sacrificed and tissues in the wound site of the individual animal were removed. These samples were

then separately fixed in 10% formalin, dehydrated through graded alcohol series, cleared in xylene and embedded in paraffin wax (melting point 56°C). Serial sections of 5 µm were cut and stained with hematoxylin and eosin and Van Gieson's. The sections were examined under light microscope and photomicrographs were taken.

Statistics

Data are expressed as mean ± SD and the results were statistically evaluated using Students paired and unpaired *t*-test and nonparametric Mann-Whitney test. All statistical analyses were executed using GraphPad Prism (version 5.0; GraphPad software Inc. San Diego CA, California, USA).

RESULTS

Biochemical and biophysical analyses

The biochemical evaluations such as DNA, total protein, hexosamine and total collagen content in the wound tissues of control and treated rats are depicted in Table 1. The DNA content was significantly elevated to 46% on day 4 further increased to 60% on day 8 and then decreased. A similar pattern (29% increase on day 4, 34% on day 8) was observed in protein content also. The collagen content was 43% on day 4, which further rose up to 73% for day 8 and then reduced to 66% on day 12. Level of hexosamine in the wound tissues of treated rats was also elevated by 34% on day 4 and decreased to 16% and 15% on day 8 and 12 respectively.

Table 2 and Figure 1 show the percentage wound contraction on various days of control and *A. calamus* treated rats on different days. Wounds that received *A. calamus* extract contracted a very fast and healed completely by day 14 whereas, the control wounds took 21 days for complete healing [Figure 2a]. Figure 2b illustrates the tensile strength of control and treated wound tissues measured on day 10. There is more than two fold increase in tensile strength in the *A. calamus* treated wounds.

Figure 3 imparts levels of lipid peroxide in control and treated rats. *A. calamus* treated rats showed lower free radical levels and oxidative tissue damage (as represented as malondialdehyde level) than control.

Solubility pattern of collagen and susceptibility of insoluble collagen in denaturing agents are depicted in Tables 3a and b. There is about 39% increase in the insoluble collagen in *A. calamus* treated wounds, which confirm that collagen is more cross-linked than the collagen from control wounds. Similarly, when the susceptibility of insoluble collagen to denaturing agents was measured in the presence of 2 M KCNS and 6 M urea, there was about 33% and 22% decrease respectively in the *A. calamus* treated wound collagen further confirming the increased cross-linking of collagen.

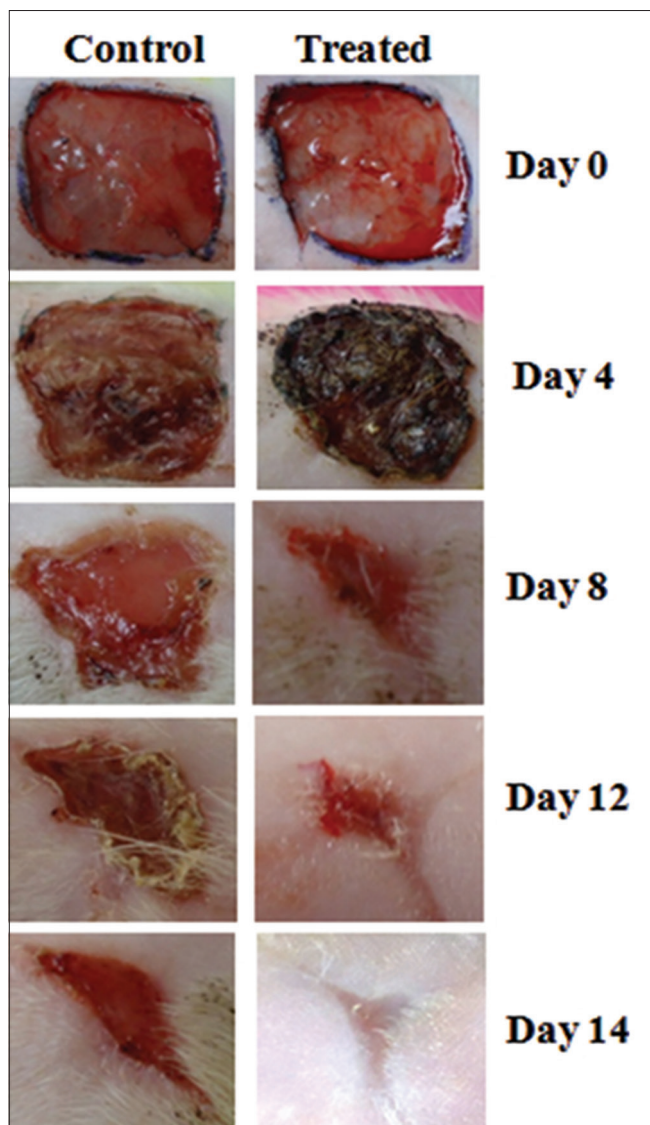


Figure 1: Photographical illustration of wound contraction rate on different days of control and *Acorus calamus* treated wounds. Scale bar 1 cm

Histopathological analysis

The histological examination displayed that the tissue regeneration was much faster in the *A. calamus* treated rats. On day 4, less number of cellular infiltration and proliferating blood capillaries was observed along with lesser fibroblasts in control wound tissue [Figure 4a]. Whereas, *A. calamus* treated wound tissue showed increased fibroblasts and macrophages with reasonable collagen fibers. Budding of new blood capillaries in wound tissues and prominent re-epithelialization were also detected in *A. calamus* treated wound tissues [Figure 4b]. On day 8, in control, irregularly arranged collagen fibers and less fibrosis could be seen with incomplete epithelialization [Figure 4c]. But *A. calamus* treated wound tissues showed complete epithelialization, increased fibrosis, uniform thick collagen deposition and macrophages at the wound site [Figure 4d].

Table 1: Effect of *A. calamus* on various biochemical parameters (mg/100 mg tissue)

Group	Post wounding days		
	4	8	12
DNA			
Control	1.51±0.13	3.52±0.29	5.02±0.43
<i>A. calamus</i> treated	2.20±1.19*	5.62±0.43*	5.32±0.51
Protein			
Control	15.42±1.2	21.43±1.9	17.95±1.4
<i>A. calamus</i> treated	19.95±1.6*	28.79±2.3*	23.79±2.0
Hexosamine			
Control	0.86±0.08	0.84±0.07	0.53±0.04
<i>A. calamus</i> treated	1.11±0.92**	0.98±0.080	0.6±0.05*
Total collagen			
Control	1.23±0.12	2.31±0.18	4.77±0.35
<i>A. calamus</i> treated	1.61±0.18*	3.20±0.02*	5.61±0.42*

Values are expressed as mean±SD of six animals in each group. Level of significance * $P < 0.05$; ** $P < 0.01$ when compared to control. SD: Standard deviation; DNA: Deoxyribonucleic acid; *A. calamus*: *Acorus calamus*

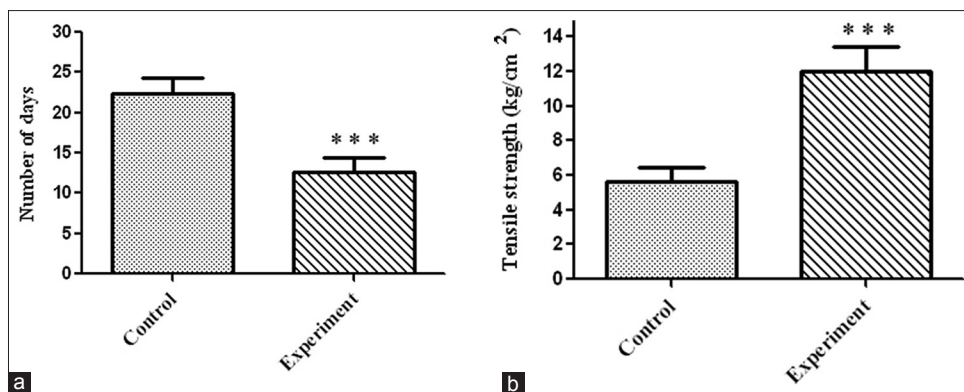


Figure 2: (a) Period of epithelialization (measured as the number of days required for shedding of eschar without any raw wound left behind) in control and treated rats. Values are expressed as mean ± standard deviation (SD) for six animals *** $P < 0.001$ was significant compared with the control. (b) Tensile strength of tissues from control and treated wounds. Values are expressed as mean ± SD for six animals *** $P < 0.001$ was significant when compared with the corresponding control

SDS-PAGE

Figure 5 shows the interrupted SDS-PAGE pattern of acid-soluble collagen of wound tissues. A significant increase in the $\alpha 1$ of type III collagen could be observed in the *A. calamus* treated wounds.

Table 2: Rate of wound contraction as percentage of original wound size

Group	Post-wounding days		
	4	8	12
Control	30±3.2	54±3.9	72±6.8
<i>A. calamus</i> treated	55±5.2	83±7.2*	99±9.1**

Values are expressed as mean±SD of six animals in each group. Level of significance * $P < 0.05$; ** $P < 0.01$ when compared to control. SD: Standard deviation; *A. calamus*: *Acorus calamus*

Table 3a: Solubility pattern of collagen from 8th day wound tissue ($\mu\text{g}/100 \text{ mg}$ tissue)

Group	Neutral salt soluble	Acid soluble	Insoluble
Control	352±18	436±25	1912±120
<i>A. calamus</i> treated	486±43**	590±38**	2650±380**

Values are expressed as mean±SD of six animals in each group. Level of significance ** $P < 0.01$; *** $P < 0.001$ when compared to control. *A. calamus*: *Acorus calamus*; SD: Standard deviation

Table 3b: Susceptibility of insoluble collagen (8th day tissue) to denaturing agents ($\text{mg}/100 \text{ mg}$ tissue)

Group	2 M KCNS	6 M urea
Control	6.78±0.80	8.62±0.76
<i>A. calamus</i> treated	5.08±0.50*	7.02±0.66*

Values are expressed as mean±SD of six animals in each group. Level of significance * $P < 0.05$ when compared to respective control. *A. calamus*: *Acorus calamus*; SD: Standard deviation

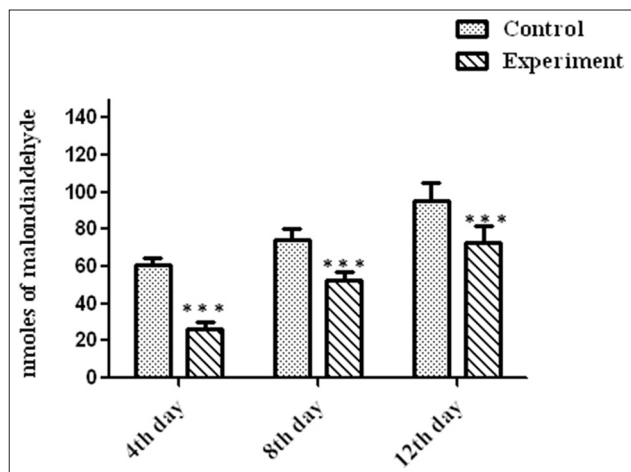


Figure 3: Levels of lipid peroxidation in wound tissues on various days. Values are expressed as mean ± standard deviation for six animals and level of significance is expressed as *** $P < 0.001$ with the respective control

DISCUSSION

Medicinal plants in wound healing are used for disinfection, debridement and the stipulation of appropriate environment for natural healing process. Indeed, alternate medicines are of less toxicity and with fewer side-effects compared with modern medicine and hence, it is significant to introduce a scientific validation for the medicinal values of plants used in traditional medicine.^[23]

Wound healing is a complex natural renewal process of skin cells to curtail or eliminate scarring as well to help healing and repairing damage.^[24] The major events include cellular migration, proliferation, adhesion and phenotypic differentiation.^[25] The present investigation of *A. calamus* administration on wounds has produced a positive outcome in the healing process. Plant products are potential agents for wound healing and are mainly chosen because of their extensive availability, non-toxicity, ease of administration, absence of unwanted side-effects and their efficiency as crude preparations.^[26] *A. calamus* is widely used as traditional medicine by various cultures world-wide, although applications vary by region.^[7,27] In this study, we have evaluated the efficacy of the alcoholic extract of the rhizomes of *A. calamus* on wound healing in rats.

The increase in DNA and total protein content in the treated wounds reflect mitogenic potential of *A. calamus* extract and hyperplasia of the cells. Hexosamine is the matrix molecule, present in the extracellular matrix, which acts as the ground

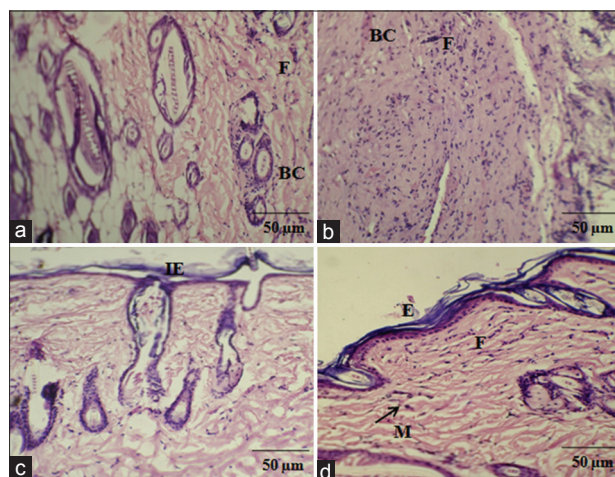


Figure 4: Histological examination showing control and *Acorus calamus* treated wound tissues on day 4 and day 8 of post wounding, respectively (H and E and Van Gieson's, $\times 20$). On day 4, control showing loosely packed collagen with irregular epithelialization and less fibroblasts (a). Whereas, treated tissue showing new blood vessels formation and high fibroblasts with dense collagen deposition (b). On day 8, control depicts thin epithelial layer with less collagen (c) and treated shows complete epithelialization with regularly arranged dense collagen (d). Scale bar 50 μm . BC: Blood capillaries; F: Fibroblast; IE: Incomplete epithelialization; E: Epithelialization; M: Macrophages

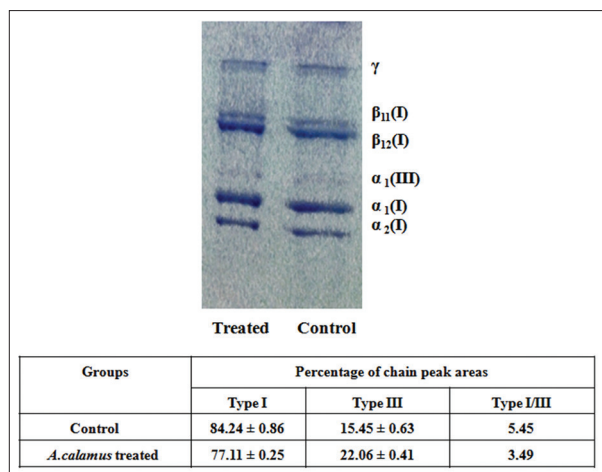


Figure 5: Interrupted sodium dodecyl sulfate-polyacrylamide gel electrophoresis showing the distribution of type I and III collagen of acid soluble fraction of day 8 wound tissues from control and *Acorus calamus* treated. All lanes were loaded with equal concentration of collagen (25 µg)

substratum for the synthesis of new collagen scaffold. The early increase in hexosamine shows the active synthesis of ground substratum by fibroblasts on which collagen is laid down. The elevated level of hexoasamine in treated rats could provide a strength to regenerated tissues.^[28] Collagen deposition is an another important event in the wound tissue formation. The healing process depends to a large extent, on the regulated biosynthesis and deposition of new collagens and their subsequent maturation,^[29] which was also increased by *A. calamus* treatment. Appropriate healing of wounds is a crucial event for the renovation of disrupted skin for its normal functional status. Higher rate of wound contraction in *A. calamus* treated rats might be attributed to increased proliferation and transformation of fibroblasts into myofibroblasts.^[28] This could be attributed by the enhanced contractile property of myofibroblast resulting in the shorter epithelialization period. Histological findings firmly substantiate the increased proliferation of fibroblasts and reepithelialization in *A. calamus* treated rats.

Evaluation of collagen content in wound tissues of control and *A. calamus* treated wounds, obviously confirms that *A. calamus* promotes collagen synthesis and deposition. The increase in solubility of collagen is relative to the synthesis of new collagen and leads to greater potential for cross-link formation.^[28] Thus, the increased solubility and decreased susceptibility of insoluble collagen in treated wounds, strongly substantiates that *A. calamus* accelerates the collagen synthesis, then maturation and cross-linking. The increase in tensile strength of treated wounds could be due to the increase in the collagen concentration per unit area and stabilization of the collagen fibers.^[6] The early tissue deposition and increased tensile strength may be contributed by terpenoid constituents of *A. calamus*.^[11]

Reactive oxygen species are noxious to wound healing process due to their damaging effects on cells and tissues. The increase in free radical production and diminished antioxidant activities may worsen the condition and account for the delay in healing.^[28] *A. calamus* enhances wound healing by reducing the level of free radicals and hence the oxidative damage. Thiem and Goślińska^[30] have reported that the topical administration of compounds with free radical scavenging properties in patients have shown to improve wound healing significantly and protect tissues from oxidative damage.

High amount of type III collagen proportional to type I was observed in *A. calamus* treated wounds. The ratio between type I/type III is very low in *A. calamus* treated rats showing that more amount of type III collagen is synthesized. Dermal wound tissue in the early phase of healing resembles embryonic skin in that type III collagen present in elevated proportions relative to type I collagen.^[31] The increase in type III collagen is derived from local fibroblasts, which are activated by the wound healing process. The early appearance of type III collagen is connected with an early increase in collagen synthesis that may function in offering wound structure and promote wound healing. Type III collagen has a far greater platelet aggregating activity than type I collagen and it plays a vital role in the configuration of homeostatic plug.^[32]

Topically administered drugs are effective in faster wound contraction and healing due to the larger availability of the drug at the wound site.^[12] Hence, the rate of wound contraction in treated rats was considerably higher. Furthermore, the period of epithelialization was shorter in the treated wounds. These results firmly support the feasible and productive approach of *A. calamus* in dermal wound healing.

CONCLUSION

Topical administration of *A. calamus* accelerates wound repair, which involves different steps such as collagen synthesis and maturation, wound contraction and epithelialization. These results firmly support the feasible and productive approach of *A. calamus* in dermal wound healing in rats.

ACKNOWLEDGEMENTS

The authors would like to thank the Director, CSIR-Central Leather Research Institute for the facility provided. T. Ponrasu and M. Ganeshkumar acknowledge Council of Scientific and Industrial Research (CSIR), New Delhi, for the award of Senior Research Fellowship.

REFERENCES

- Kumar B, Vijayakumar M, Govindarajan R, Pushpangadan P. Ethnopharmacological approaches to wound healing – Exploring medicinal plants of India. *J Ethnopharmacol* 2007;114:103-13.
- Gallo RL, Bernfield M. Proteoglycan and their role in wound repair. In: Clark RA, editor. *The Molecular and Cellular Biology of Wound Repair*. New York: Plenum Press; 1996. p. 475-92.
- Karodi R, Jadhav M, Rub R, Bafna A. Evaluation of the wound healing activity of a crude extract of *Rubia cordifolia* L. (Indian madder) in mice. *Int J Appl Res Nat Prod* 2009;2:12-8.
- Sumitra M, Manikandan P, Gayathri VS, Mahendran P, Suguna L. *Embllica officinalis* exerts wound healing action through up-regulation of collagen and extracellular signal-regulated kinases (ERK1/2). *Wound Repair Regen* 2009;17:99-107.
- Ozgen U, Ikbal M, Hacimuftuoglu A, Houghton PJ, Gocer F, Dogan H, et al. Fibroblast growth stimulation by extracts and compounds of *Onosma argentatum* roots. *J Ethnopharmacol* 2006;104:100-3.
- Parab RS, Mengi SA. Hypolipidemic activity of *Acorus calamus* L. in rats. *Fitoterapia* 2002;73:451-5.
- Muthuraman A, Singh N, Jaggi AS. Protective effect of *Acorus calamus* L. in rat model of vincristine induced painful neuropathy: An evidence of anti-inflammatory and anti-oxidative activity. *Food Chem Toxicol* 2011;49:2557-63.
- Dong W, Yang D, Lu R. Chemical constituents from the rhizome of *Acorus calamus* L. *Planta Med* 2010;76:454-7.
- Parab RS, Mengi SA. Evaluation of hypolipidemic activity of *Acorus calamus* Linn in rats. *Indian Drugs* 2003;40:25-9.
- Lee MH, Chen YY, Tsai JW, Wang SC, Watanabe T, Tsai YC. Inhibitory effect of β -asarone, a component of *Acorus calamus* essential oil, on inhibition of adipogenesis in 3T3-L1 cells. *Food Chem* 2011;126:1-7.
- Jain N, Jain R, Jain A, Jain DK, Chandel HS. Evaluation of wound-healing activity of *Acorus calamus* Linn. *Nat Prod Res* 2010;24:534-41.
- Ponrasu T, Suguna L. Efficacy of *Annona squamosa* on wound healing in streptozotocin-induced diabetic rats. *Int Wound J* 2012;9:613-23.
- Vogel HG. Antagonistic effect of aminoacetonitrile and prednisolone on mechanical properties of rat skin. *Biochim Biophys Acta* 1971;252:580-5.
- Porat S, Rousso M, Shoshan S. Improvement of gliding function of flexor tendons by topically applied enriched collagen solution. *J Bone Joint Surg Br* 1980;62-B:208-13.
- Burton K. A study of the conditions and mechanism of the diphenylamine reaction for the colorimetric estimation of deoxyribonucleic acid. *Biochem J* 1956;62:315-23.
- Lowry OH, Rosebrough NJ, Farr AL, Randall RJ. Protein measurement with the Folin phenol reagent. *J Biol Chem* 1951;193:265-75.
- Woessner JF Jr. The determination of hydroxyproline in tissue and protein samples containing small proportions of this imino acid. *Arch Biochem Biophys* 1961;93:440-7.
- Elson LA, Morgan WT. A colorimetric method for the determination of glucosamine and chondrosamine. *Biochem J* 1933;27:1824-8.
- Santos MT, Valles J, Aznar J, Vilches J. Determination of plasma malondialdehyde-like material and its clinical application in stroke patients. *J Clin Pathol* 1980;33:973-6.
- Piez KA. The amino acid chemistry of some calcified tissues. *Ann N Y Acad Sci* 1963;109:256-68.
- Adam M, Fietzek P, Kühn K. Investigations on the reaction of metals with collagen *in vivo*. 2. The formation of cross-links in the collagen of lathyritic rats after gold treatment *in vivo*. *Eur J Biochem* 1968;3:411-4.
- Hering TM, Marchant RE, Anderson JM. Type V collagen during granulation tissue development. *Exp Mol Pathol* 1983;39:219-29.
- Priya KS, Gnanamani A, Radhakrishnan N, Babu M. Healing potential of *Datura alba* on burn wounds in albino rats. *J Ethnopharmacol* 2002;83:193-9.
- Eming SA, Werner S, Bugnon P, Wickenhauser C, Siewe L, Utermöhlen O, et al. Accelerated wound closure in mice deficient for interleukin-10. *Am J Pathol* 2007;170:188-202.
- Raghow R. The role of extracellular matrix in postinflammatory wound healing and fibrosis. *FASEB J* 1994;8:823-31.
- Sandhya S, Kumar PS, Vinod KR, Banji D, Kumar K. Plants as potent anti diabetic and wound healing agents-A review. *Hygeia JD Med* 2011;3:11-9.
- Lee MR, Yun BS, Park SY, Ly SY, Kim SN, Han BH, et al. Anti-amnesic effect of Chong-Myung-Tang on scopolamine-induced memory impairments in mice. *J Ethnopharmacol* 2010;132:70-4.
- Gupta A, Upadhyay NK, Sawhney RC, Kumar R. A poly-herbal formulation accelerates normal and impaired diabetic wound healing. *Wound Repair Regen* 2008;16:784-90.
- Siegel RC. Collagen cross-linking. Synthesis of collagen cross-links *in vitro* with highly purified lysyl oxidase. *J Biol Chem* 1976;251:5786-92.
- Thiem B, Goślińska O. Antimicrobial activity of *Rubus chamaemorus* leaves. *Fitoterapia* 2004;75:93-5.
- Barnes MJ, Morton LF, Bennett RC, Bailey AJ, Sims TJ. Presence of type III collagen in guinea-pig dermal scar. *Biochem J* 1976;157:263-6.
- Bazin S, Delaunay A. Biochemistry of inflammation. VI. Fluctuations in the levels of collagen and nonfibrillar proteins in different types of inflammatory foci. Comparative studies. *Ann Inst Pasteur (Paris)* 1964;107:163-72.

Cite this article as: Ponrasu T, Madhukumar KN, Ganeshkumar M, Iyappan K, Sangeethapriya V, Gayathri VS, Suguna L. Efficacy of *Acorus calamus* on collagen maturation on full thickness cutaneous wounds in rats. *Phcog Mag* 2014;10:299-305.

Source of Support: Nil, **Conflict of Interest:** None declared.