

Novel transcatheter treatment for staged closure of Abernethy malformation with portal hypoplasia

Deepa Sasikumar¹, Jineesh Valakkada², Harshith Kramadhari², Anoop Ayyappan², Kavasseri M Krishnamoorthy¹

Departments of ¹Cardiology and ²Interventional Radiology and Imaging Sciences, Sree Chitra Tirunal Institute for Medical Sciences and Technology, Trivandrum, Kerala, India

ABSTRACT

Portosystemic shunts are rare congenital malformations that come to attention due to various hepatic and extrahepatic manifestations. Management of this malformation is dictated by the presence and adequacy of intrahepatic portal radicals. Staged occlusion of the shunt is recommended in patients with severely hypoplastic portal radicals. We describe a novel transcatheter technique that we improvised for staged occlusion of Abernethy malformation in a 2-year-old girl.

Keywords: Fenestrated device, portosystemic shunt, pulmonary hypertension

INTRODUCTION

Abernethy malformations or congenital portosystemic shunts are rare anomalies with myriad hepatic and extrahepatic manifestations. The choice of treatment of this anomaly depends on the extent of hypoplasia of the intrahepatic portal radicals. Various techniques have been described to stimulate the growth of the portal venous radicals while partially or totally occluding the abnormal portosystemic shunt. We describe a novel transcatheter technique that was used to treat a 2-year-old girl with a large portosystemic shunt with severely hypoplastic portal radicals.

CASE REPORT

A 2-year-old girl was diagnosed to have severe pulmonary artery hypertension (PAH) during evaluation of an earlobe hemangioma [Figure 1a]. Computed tomographic scan of the brain showed a small cerebellar pial arteriovenous malformation (AVM) [Figure 1b]. As the AVM was too small to account for the PAH, she

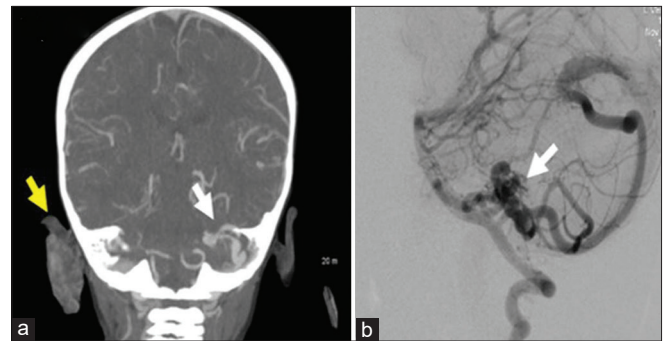


Figure 1: (a) Computed tomography angiogram showing earlobe hemangioma (arrow). (b) Computed tomography angiogram of the brain showing small cerebellar pial arteriovenous malformation (arrow)

underwent further evaluation to look for the etiology of PAH. Ultrasonogram of the abdomen revealed a large portosystemic shunt between the left portal vein and the suprahepatic part of the inferior vena cava. The intrahepatic portal venous radicals were barely

Videos Available on: www.annalspc.com

Access this article online

Quick Response Code:



Website:

www.annalspc.com

DOI:

10.4103/apc.APC_189_20

This is an open access journal, and articles are distributed under the terms of the Creative Commons Attribution-NonCommercial-ShareAlike 4.0 License, which allows others to remix, tweak, and build upon the work non-commercially, as long as appropriate credit is given and the new creations are licensed under the identical terms.

For reprints contact: WKHLRPMedknow_reprints@wolterskluwer.com

How to cite this article: Sasikumar D, Valakkada J, Kramadhari H, Ayyappan A, Krishnamoorthy KM. Novel transcatheter treatment for staged closure of Abernethy malformation with portal hypoplasia. *Ann Pediatr Card* 2021;14:419-21.

Address for correspondence: Dr. Deepa Sasikumar, Department of Cardiology, Sree Chitra Tirunal Institute for Medical Sciences and Technology, Trivandrum, Kerala, India. E-mail: deepaskumar@yahoo.com

Submitted: 10-Aug-2020

Revised: 27-Jan-2021

Accepted: 27-May-2021

Published: 11-Aug-2021

discernible and computed tomography of the abdomen confirmed these findings. Gastroenterology evaluation including esophagogastroduodenoscopy and liver tissue elastography were done to rule out portal hypertension. As there was no evidence of portal hypertension and the liver function was normal, the child was subjected to cardiac catheterization. PA pressure was 60/32 mmHg with mean PA pressure of 44 mmHg. Hepatic venous pressure was 6 mmHg. The portal vein was entered through the portosystemic communication and the portal pressure was 8 mmHg. On balloon occlusion of the portal vein with 6 Tyshak balloon, the distal portal venous pressure rose to 28 mmHg. Selective angiogram into the portosystemic shunt through internal jugular venous access showed diminutive portal radicals with good arborization [Figure 2a and Video 1].

The abnormal portosystemic communication measured 5 mm and a size 6 mm muscular ventricular septal defect (VSD) occluder was chosen for occlusion. As there was a significant hepatportal gradient on occlusion of the malformation, we decided to manually fenestrate the device. An 8 Fr Flexor sheath was introduced into the shunt over a 0.035" exchange length Teflon wire. The muscular VSD device was fenestrated near the screw with a puncture needle followed by serial dilatations with increasing size of short dilators up to 7 Fr [Figure 2b]. The device was then screwed to the cable and loaded in a standard manner into the sheath. After deployment of the device [Figure 2c and Video 2], a selective superior mesenteric artery angiogram was done to show patency of portal venous flow and flow through the fenestration. The flow was also confirmed with an ultrasonogram of the abdomen [Figure 3 shows a schematic representation of the procedure]. It was planned to close the fenestration percutaneously on follow-up.

Three months later, ultrasonogram showed spontaneous occlusion of the fenestration in the device [Figure 4a] and excellent growth of the portal venous radicals [Figure 4b]. At 18 months of follow-up, the mean PA pressure had dropped to 22 mmHg and the portal radicals had grown to normal size. The child's mother reported that the earlobe hemangioma had reduced in size. She is on a tapering dose of sildenafil and is asymptomatic.

DISCUSSION

Abernethy malformation or congenital portosystemic shunts lead to various hepatic and extrahepatic manifestations, which are mostly reversible if diagnosed and treated early.^[1,2] The malformation leads to portal hypoplasia due to diversion of blood from the portal system to the systemic veins, the degree of which determines the line of management. Evaluation of a patient with Abernethy malformation

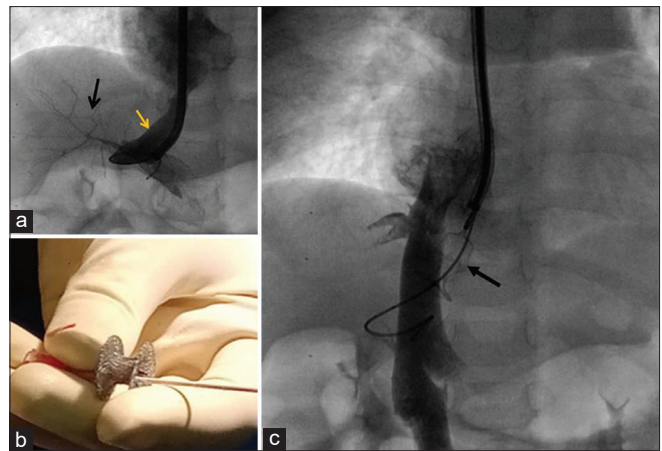


Figure 2: (a) Venogram from inferior vena cava showing the shunt (yellow arrow) with reduced caliber distal portal vein radicals (black arrow). (b) Dilation of the manually created fenestration with short 7F dilator. (c) Muscular ventricular septal defect occluder deployed (arrow), wire through the fenestration seen

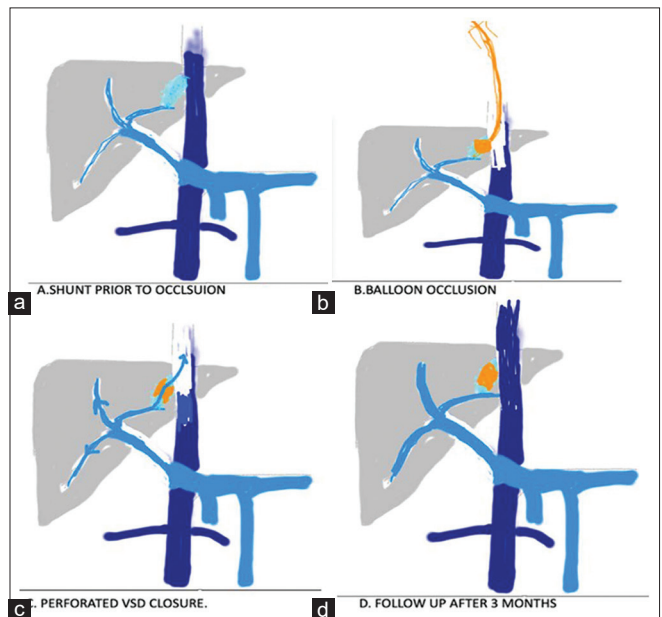


Figure 3: Schematic representation of the procedure showing the shunt (light green in a) prior to procedure which was balloon occluded (b) to measure the portal pressure. Perforated ventricular septal defect closure device deployed (orange in c) with growth of distal portal vein radicals (d) after 3 months

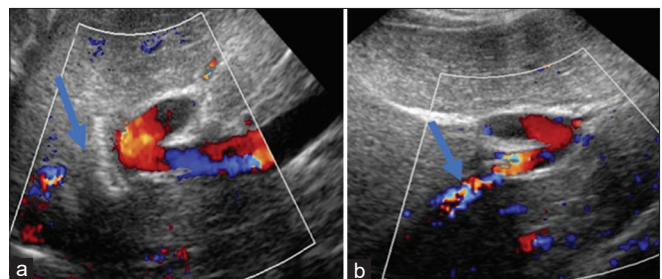


Figure 4: (a) Ultrasound done after 3 months showing complete occlusion of shunt (arrow). (b) Improved caliber of distal portal vein radicals after 3 months (arrow)

begins with the assessment of presence of intrahepatic portal radicals, their size, and the adequacy of their arborization in the liver.^[2,3] Even if the portal venous radicals are not visualized by imaging like computed tomography, effort should be made to look for rudimentary portal system by invasive balloon occlusion angiogram.^[3] This confirmation is important as the existence of even a miniscule portal system makes surgical or interventional occlusion of the portosystemic shunt worthwhile, as the plasticity of the portal system to grow and develop normally after such interventions has been demonstrated in numerous studies. Single-stage occlusion of the shunt is advised if, on balloon occlusion of the shunt, the portal pressure rises to <32 mmHg.^[3] Staged closure of the shunt is advised if the portal pressure rises to more than 32 mmHg on balloon occlusion. Various methods of staged occlusion have been described such as surgical banding, use of reducing stents,^[4,5] and total occlusion of the shunt with placement of smaller transjugular intrahepatic portosystemic shunt (TIPSS)^[6] in the first stage followed by occlusion of the TIPSS in the second stage after the portal radicals have attained significant growth.

In our child, portal pressure on balloon occlusion rose to 28 mmHg. As the portal radicals were significantly hypoplastic on angiogram, it was felt that complete occlusion may lead to an acute rise in portal venous pressure. We used an innovative and simple technique of partial occlusion of the shunt by manually fenestrating a muscular VSD occluder. The fenestration was big enough to allow retrograde flow to the systemic veins if the portal pressure rose alarmingly. At 3 months of follow-up, the fenestration closed spontaneously making a second procedure to percutaneously close the fenestration unnecessary.

CONCLUSIONS

The hepatic and extrahepatic manifestations of Abernethy malformation are eminently reversible if the shunt is detected early and managed promptly. Staged closure of the shunt in patients with high portal pressures or poorly developed portal radicles helps to prevent the

acute rise in portal pressures and aids rehabilitation of hypoplastic portal radicals.

Declaration of patient consent

The authors certify that they have obtained all appropriate patient consent forms. In the form, the patient's guardian has given consent for patient's images and other clinical information to be reported in the journal. The patient's guardian understands that patient's name and initials will not be published and due efforts will be made to conceal identity, but anonymity cannot be guaranteed.

Financial support and sponsorship

Nil.

Conflicts of interest

There are no conflicts of interest.

REFERENCES

1. Witters P, Maleux G, George C, Delcroix M, Hoffman I, Gewillig M, *et al.* Congenital veno-venous malformations of the liver: Widely variable clinical presentations. *J Gastroenterol Hepatol* 2008;23:e390-4.
2. Sokollik C, Bandsma RH, Gana JC, van den Heuvel M, Ling SC. Congenital portosystemic shunt: Characterization of a multisystem disease. *J Pediatr Gastroenterol Nutr* 2013;56:675-81.
3. Franchi-Abella S, Branchereau S, Lambert V, Fabre M, Steimberg C, Losay J, *et al.* Complications of congenital portosystemic shunts in children: Therapeutic options and outcomes. *J Pediatr Gastroenterol Nutr* 2010;51:322-30.
4. Bruckheimer E, Dagan T, Atar E, Schwartz M, Kachko L, Superina R, *et al.* Staged transcatheter treatment of portal hypoplasia and congenital portosystemic shunts in children. *Cardiovasc Intervent Radiol* 2013;36:1580-5.
5. Marx M, Huber WD, Crone J, Lammer J, Perneczky-Hintringer E, Heller S, *et al.* Interventional stent implantation in a child with patent ductus venosus and pulmonary hypertension. *Eur J Pediatr* 2001;160:501-4.
6. Kuo MD, Miller FJ, Lavine JE, Peterson M, Finch M. Exploiting phenotypic plasticity for the treatment of hepatopulmonary shunting in Abernethy malformation. *J Vasc Interv Radiol* 2010;21:917-22.