

CASE REPORT

OPEN ACCESS

Full open access to this and thousands of other papers at <http://www.la-press.com>.

Isolated Bilateral Trigeminal Neuropathy in Sarcoidosis Presenting with Neurotrophic Corneal Ulcers

M. Gupta¹, G. Lascaratos¹, A. Syrogiannis¹ and L. Esakowitz²

¹Ophthalmology Department, Princess Alexandra Eye Pavilion, Edinburgh, UK. ²Ophthalmology Department, Royal Alexandra Eye Hospital, Paisley, UK. Corresponding author email: maniishgupta@yahoo.co.uk

Abstract: Sarcoidosis is a multisystem granulomatous disease that may affect various organs. Nevertheless, involvement of the trigeminal nerve is exceedingly uncommon. This report presents a rare case of isolated bilateral trigeminal neuropathy presenting with neurotrophic corneal ulcers. The patient was treated with topical chloramphenicol and lubricants, as well as botulinum toxin injection to the upper eyelid to induce ptosis. Our case illustrates the importance of recognizing that bilateral corneal ulceration might be a manifestation of sarcoidosis. Physicians should be aware of this rare association, when treating sarcoidosis patients with eye related symptoms.

Keywords: sarcoidosis, trigeminal neuropathy, neurotrophic ulcers

Ophthalmology and Eye Diseases 2010:2 69–73

doi: [10.4137/OED.S5612](https://doi.org/10.4137/OED.S5612)

This article is available from <http://www.la-press.com>.

© the author(s), publisher and licensee Libertas Academica Ltd.

This is an open access article. Unrestricted non-commercial use is permitted provided the original work is properly cited.

Introduction

Neurotrophic keratopathy is a rare degenerative corneal disease caused by an impairment of trigeminal corneal innervation, leading to a decrease or absence of corneal sensation. This is most commonly due to viral infection (herpes simplex and herpes zoster) followed by chemical burns, physical injuries and corneal surgery.¹ Intracranial space-occupying lesions, such as neuroma, meningioma and aneurysms, may also determine a compression of the trigeminal nerve or ganglion and produce an impairment of corneal sensitivity.² Interestingly, experimental section of the trigeminal nerve has been shown to lead to neurotrophic ulceration.³ Systemic diseases, such as diabetes, multiple sclerosis, syphilis and leprosy may also damage sensory nerve fibres leading to corneal anaesthesia.⁴ Other causes of facial and corneal anaesthesia may include neoplasms in the nasopharynx, vertebrobasilar disease, collagen vascular disease, infections, including sinusitis, and sarcoidosis.⁵

Sarcoidosis is an idiopathic, systemic, granulomatous disease whose onset is usually unifocal, but with a strong predilection for systemic involvement, characterized by alternating periods of remission and relapse.⁶ The nervous system is affected in about 5 percent of patients with sarcoidosis,⁷ although post-mortem studies suggest that ante-mortem diagnosis is only made in 50% of those with nervous system involvement.⁸ Sarcoid usually affects the facial nerve, either because of meningitic reaction or secondary to inflammation in the parotid gland. Sarcoid of the trigeminal nerve is exceedingly rare.⁹ To the best of our knowledge, this case is the first in the literature to report isolated involvement of both trigeminal nerves with resultant neurotrophic ulcers in a patient with sarcoidosis. This case also illustrates the importance of recognizing that corneal ulceration might be a manifestation of sarcoidosis.

Case Report

An individual with a 25-year history of biopsy-proven cutaneous sarcoidosis complained of pain, redness and reduced vision in the left eye for 3 days. Ocular examination showed a neurotrophic ulcer in the left eye. The individual was treated with chloramphenicol ointment and preservative free artificial tears (carmellose sodium 1% and liquid paraffin). Botulinum toxin was injected to the upper lid to

induce ptosis. There was complete recovery. After five months, the individual returned with similar complaints in the right eye. Ocular examination revealed reduced corneal sensation in both eyes with a neurotrophic ulcer in the right eye and stromal haze in the left (Figs. 1 and 2). The right corneal ulcer resolved on chloramphenicol ointment and preservative free artificial tears.

On systemic examination, no abnormalities were identified in the respiratory and cardiovascular systems. Neurologically, decreased sensation to light touch was noted involving all branches of the trigeminal nerve on both sides. All other cranial nerves, including the facial nerve, were intact. Motor strength, peripheral sensory function, and deep tendon reflexes were normal.

At the time of corneal involvement, the patient was on a low dose of systemic steroids (4 mg oral prednisolone a day) and methotrexate (15 mg a week) for cutaneous sarcoidosis and on antihypertensives for raised blood pressure.

All blood investigations, including serum ACE, were normal. Chest x-ray and T2 weighted cranial magnetic resonance imaging (MRI) without contrast, performed at the time of trigeminal nerve involvement, were normal. In view of the above and in the absence of other acute neurological involvement, lumbar puncture was not performed. Repeat of the positive skin biopsy was not considered by the dermatologists at the time of ocular involvement, since the patient, despite 25 years of treatment with systemic

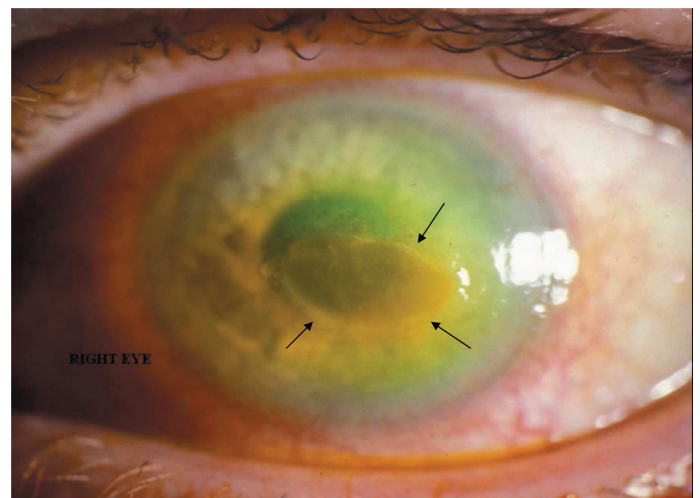

Figure 1. Enhanced fluorescein uptake and central corneal ulceration (black arrows) in the right eye.

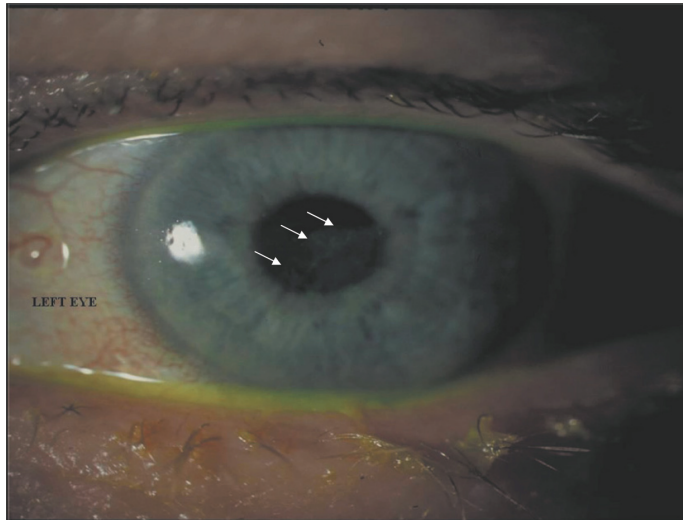


Figure 2. Corneal scarring of the left eye (white arrows), consistent with resolution of the corneal ulcer.

steroids and methotrexate, demonstrated chronic skin lesions and experienced recurrent skin involvement, and there was no reason to challenge the diagnosis of cutaneous sarcoidosis.

The trigeminal neuropathy was thought to be secondary to sarcoidosis after all other causes of trigeminal nerve involvement were ruled out. There was no history of trauma and other more common causes of trigeminal involvement, such as schwannoma, meningioma or cavernous-carotid aneurysm, were not detected by the central nervous system imaging. Our patient described no symptoms suggestive of lymphoma and systemic examination revealed no features of neurofibromatosis.

The patient is currently under regular review by both physicians and dermatologists with no evidence of recurrence of ocular symptoms after three years of follow-up.

Discussion

According to the Mackie classification, it is possible to classify neurotrophic keratopathy into three stages.¹⁰ Stage 1 is characterized by punctate keratopathy, epithelial hyperplasia and irregularity, superficial neovascularization and stromal scarring. In our patient (Stage 2) a persistent epithelial defect is noted with a surrounding area of poorly adherent opaque and oedematous epithelium that can spontaneously detach leading to an enlargement of the defect. Epithelial healing in Stage 2 is often inadequate and

the edges of the defect become smooth and rolled. Descemet's membrane folds and stroma swelling may also be observed with an inflammatory reaction in the anterior chamber and, rarely, sterile hypopyon. With stromal involvement (Stage 3), the ulcer may progress to melting and eventually perforation.

Sarcoid mononeuropathy is relatively rare and may occur at different stages of sarcoidosis. It could be an initial symptomatic manifestation, or it could occur in the context of chronic sarcoidosis. It usually does not determine the outcome and course of treatment.¹¹ Three cases of isolated trigeminal nerve involvement in sarcoidosis have been reported, all being unilateral and not involving the eyes.^{12–14} In another case, sinonasal sarcoidosis had spread in a perineural fashion along the infraorbital and vidian nerves, as well as along the right maxillary nerve, resulting in enlargement and erosion of the bony canals.¹⁵ Cavernous sinus syndrome with involvement of the trigeminal nerve has also been described recently in a 54-year-old man with pulmonary sarcoidosis, who presented with complete unilateral ophthalmoplegia.¹⁶ Moreover, neurosarcoidosis of Gasser's ganglion has been associated with trigeminal neuralgia in a patient whose MRI scan demonstrated a mass in the Meckel's diverticulum.¹⁷ Finally, a single case of bilateral sarcoid involvement of Gasser's ganglion cisternae has been reported in a patient with mediastinal and parotid sarcoidosis, with no associated ocular symptoms.¹⁸

Serological testing is of limited value in patients with known sarcoidosis, and in reported cases of sarcoid neuropathy, serum ACE level has been elevated in approximately one third of patients.¹¹ The role of cerebrospinal fluid ACE level in the evaluation of neurosarcoidosis remains uncertain.^{19,20} The criteria upon which a diagnosis of neurosarcoidosis is made in the absence of central nervous system (CNS) histology are not firmly established, but a clinically compatible picture, exclusion of other neurological disease and histological confirmation of disease elsewhere, such as the skin in our case, are generally required.²¹

More recently, positron emission tomography (PET) imaging with [18F]-fluorodeoxyglucose (FDG) has been recognized as an efficient modality in evaluating the extent of the disease in patients with known or suspected sarcoidosis and to target an optimal site for biopsy. [18F]-FDG is a radiotracer that is widely used for the management of cancer patients, but is



not specific for malignant tumours, since it is actively taken up in inflammatory processes. However, the main drawback of [18F]-FDG imaging in detecting CNS lesions is its high physiological uptake in the brain, which thus minimizes the lesion/brain ratio.²² As such, [18F]-FDG PET is considered to be of little interest in the above settings and more often the brain is not included in the so-called “whole body” PET images. PET scan was not considered in our case. Nevertheless, several cases of increased brain parenchymal²³ and spinal cord²⁴ [18F]-FDG uptake or focal brain hypometabolism²⁴ have been reported in symptomatic patients with neurosarcoidosis corresponding to the MRI lesions. Moreover, recently in a neurosarcoidosis patient with bitemporal and multiple spinal MRI lesions, FDG-PET was able to show hypermetabolic foci corresponding to these lesions.²⁵ Gallium (67Ga) scintigraphy has also been used in the assessment of sarcoidosis,²⁶ but clinical studies suggest that 18F-FDG PET is more accurate and more suitable to detect extrapulmonary involvement in these patients.^{27–28}

MRI has greatly aided the investigation of patients with inflammatory brain disease and has proved to be more sensitive than Computed Tomography (CT) in the diagnosis of neurosarcoidosis.²⁹ MRI with gadolinium has increased sensitivity and is considered the optimal diagnostic imaging modality for neurosarcoidosis, as it is thought to enhance visualization of granulomatous infiltration in neural tissue.³⁰ It is possible that the lack of contrast in our case was responsible for the difficulty to detect neurosarcoidosis lesions, although clinically our patient was otherwise neurologically well, apart from the fifth cranial nerve involvement. Also, the normal neuroimaging in our study could be explained by the fact that in a recent large case series of confirmed neurosarcoidosis up to 10% of the patients had normal brain imaging and another 33% showed only non-specific white-matter changes,³¹ making the distinction of neurosarcoidosis from multiple sclerosis very difficult. Although none of the appearances are specific for neurosarcoidosis, meningeal enhancement or persistent enhancement (more than a few weeks) of parenchymal lesions are much more suggestive of a granulomatous process, and are not expected in multiple sclerosis. Other MRI findings in neurosarcoidosis patients presenting with

relevant neurological symptoms include multiple supratentorial and infratentorial brain lesions that may be difficult to distinguish from metastases, solitary intraaxial lesions that may mimic high grade astrocytomas and solitary extraaxial lesions that may mimic meningiomas.³² Overall, these findings are not specific for sarcoidosis and one must consider appropriate clinical circumstances in arriving at the correct diagnosis. Moreover, biopsy of cranial nerves is not commonly performed, so the physician often relies on the history of histologically confirmed systemic sarcoidosis and the clinical findings, as in this case.²¹

In summary, neurosarcoidosis should be considered in any patient with a known history of sarcoidosis that presents with corneal ulceration.

Disclosures

This manuscript has been read and approved by all authors. This paper is unique and is not under consideration by any other publication and has not been published elsewhere. The authors and peer reviewers of this paper report no conflicts of interest. The authors confirm that they have permission to reproduce any copyrighted material.

References

1. Groos Jr EB. Neurotrophic keratitis. In: Krachmer JH, Mannis MJ, Holland EJ (eds.) *Cornea: Clinical Diagnosis and Management*. Mosby: St Louis, 1997.
2. Puca A, Meglio M, Vari R, Tamburrini G, Tancredi A. Evaluation of fifth nerve dysfunction in 136 patients with middle and posterior cranial fossae. *Eur Neurol*. 1995;35:33–7.
3. de Haas EBH. Desiccation of cornea and conjunctiva after sensory denervation. *Arch Ophthalmol*. 1962;67:79–92.
4. Hyndiuk RA, Kazarian EL, Schultz RO, Seideman S. Neurotrophic corneal ulcers in diabetes mellitus. *Arch Ophthalmol*. 1977;95:2193–6.
5. Brust JCM. Neurosarcoidosis. In: Rowland LP (ed). *Merritt's textbook of neurology*. 9th ed. Media, Pa: Williams and Wilkins. 1995.
6. James DJ, Jones Williams W (eds). *Sarcoidosis and Other Granulomatous Diseases*. Philadelphia: Saunders, 1984.
7. Delaney P. Neurologic manifestations in sarcoidosis: review of the literature, with a report of 23 cases. *Ann Intern Med*. 1977;87:336–45.
8. Iwai K, Tachibana T, Takemura T, et al. Pathological studies on sarcoidosis autopsy. I. Epidemiological features of 320 cases in Japan. *Acta Pathol Jpn*. 1993;43:372–6.
9. Stern BJ, Krumholz A, Johns C, et al. Sarcoidosis and its neurological manifestations. *Arch Neurol*. 1985;42:909–17.
10. Mackie IA. Neuroparalytic keratitis. In: Fraunfelder F, Roy FH, Meyer SM (eds). *Current Ocular Therapy*. WB Saunders: Philadelphia, PA. 1995.
11. Zivkovic Sasa A, Lacomis D. Sarcoid Neuropathy: Case report and review of literature. *Journal of Clinical Neuromuscular Disease*. 2004;5:184–9.
12. Dupuy M, Leger JM, Rebelo F, et al. Trigeminal sensory neuropathy disclosing sarcoidosis [in French]. *Presse Med*. 1985;14:426–7.
13. Bonnet F, Mercie P, Morlat P, et al. Isolated involvement of the trigeminal nerve of Sarcoidosis origin [in French]. *Rev Neurol (Paris)*. 1997;155:59–61.



14. Quinones-Hinojosa A, Chang E, Khan SA, et al. Isolated Trigeminal Nerve Sarcoid Granuloma Mimicking Trigeminal Schwannoma. *Neurosurgery*. 2003;52(3):700–5.
15. Mazziotti S, Gaeta M, Blandino A, Vinci S, Pandolfo I. Perineural spread in a case of sinonasal sarcoidosis: case report. *Am J Neuroradiol*. 2001;22(6):1207–8.
16. Chang CS, Chen WL, Li CT, Wang PY. Cavernous sinus syndrome due to sarcoidosis: a case report. *Acta Neurol Taiwan*. 2009;18(1):37–41.
17. Arias M, Iglesias A, Vila O, Brasa J, Conde C. MR imaging findings of neurosarcoidosis of the gasserian ganglion: an unusual presentation. *Eur Radiol*. 2002;12(11):2723–5.
18. Braido F, Zolezzi A, Stea F, et al. Bilateral Gasser's ganglion sarcoidosis: diagnosis, treatment and unsolved questions. *Sarcoidosis Vasc Diffuse Lung Dis*. 2005;22(1):75–7.
19. Gullapalli D, Phillips L. Neurologic manifestations of sarcoidosis. *Neurol Clin*. 2002;20:59–83.
20. Dale JC, O'Brien JF. Determination of angiotensin-converting enzyme levels in cerebrospinal fluid is not a useful test for the diagnosis of neurosarcoidosis. *Mayo Clinic Proc*. 1999;74:535.
21. FG Joseph, NJ Scolding. Neurosarcoidosis: a study of 30 new cases. *J Neurol Neurosurg Psychiatry*. 2009;80:297–304.
22. Aide N, Benayoun M, Kerrou K, Khalil A, Cadranet J, Talbot JN. Impact of [18F]-fluorodeoxyglucose ([18F]-FDG) imaging in sarcoidosis: unsuspected neurosarcoidosis discovered by [18F]-FDG PET and early metabolic response to corticosteroid therapy. *Br J Radiol*. 2007;80(951):e67–71.
23. Sponsler JL, Werz MA, Maciunas R, Cohen M. Neurosarcoidosis presenting with simple partial seizures and solitary enhancing mass: case reports and review of the literature. *Epilepsy Behav*. 2005;6:623–30.
24. Dubey N, Miletich RS, Wasay M, Mechtler LL, Bakshi R. Role of fluorodeoxyglucose positron emission tomography in the diagnosis of neurosarcoidosis. *J Neurol Sci*. 2002;205:77–81.
25. Bolat S, Berding G, Dengler R, Stangel M, Trebst C. Fluorodeoxyglucose positron emission tomography (FDG-PET) is useful in the diagnosis of neurosarcoidosis. *J Neurol Sci*. 2009;287(1–2):257–9.
26. Lebtahi R, Crestani B, Belmatoug N, et al. Somatostatin receptor scintigraphy and gallium scintigraphy in patients with sarcoidosis. *J Nucl Med*. 2001;42(1):21–6.
27. Nishiyama Y, Yamamoto Y, Fukunaga K, Takinami H, Iwado Y, Satoh K, Ohkawa M. Comparative evaluation of 18F-FDG PET and 67Ga scintigraphy in patients with sarcoidosis. *J Nucl Med*. 2006;47(10):1571–6.
28. Prager E, Wehrsuetz M, Bisail B, et al. Comparison of 18F-FDG and 67Ga-citrate in sarcoidosis imaging. *Nuklearmedizin*. 2008;47(1):18–23.
29. Miller DH, Kendall BE, Barter S, et al. Magnetic resonance imaging in central nervous system sarcoidosis. *Neurology*. 1988;38:378–83.
30. Terushkin V, Stern BJ, Judson MA, et al. Neurosarcoidosis: presentations and management. *Neurologist*. 2010;16(1):2–15.
31. Zajicek JP, Scolding NJ, Foster O, et al. Central nervous system sarcoidosis—diagnosis and management. *QJM*. 1999;92:103–17.
32. Pickuth D, Heywang-Köbrunner SH. Neurosarcoidosis: evaluation with MRI. *J Neuroradiol*. 2000;27(3):185–8.

Publish with Libertas Academica and every scientist working in your field can read your article

"I would like to say that this is the most author-friendly editing process I have experienced in over 150 publications. Thank you most sincerely."

"The communication between your staff and me has been terrific. Whenever progress is made with the manuscript, I receive notice. Quite honestly, I've never had such complete communication with a journal."

"LA is different, and hopefully represents a kind of scientific publication machinery that removes the hurdles from free flow of scientific thought."

Your paper will be:

- Available to your entire community free of charge
- Fairly and quickly peer reviewed
- Yours! You retain copyright

<http://www.la-press.com>