



Birmingham Royal Orthopaedic Hospital (BROH) Femoral Offset—An Ancillary Measure of Adult Dysplasia of the Hip

Karthikeyan P. Iyengar¹ John D. Fitzpatrick² Michail Michalos³ Callum McBryde³
 Angelos Politis³ Ed Bache³ Peter Wall³ Rajesh Botchu²

¹Department of Orthopedics, Southport & Ormskirk NHS Trust, Southport, United Kingdom

²Department of Musculoskeletal Radiology, Royal Orthopedic Hospital, Birmingham, United Kingdom

³Department of Young Adult Hip, Royal Orthopedic Hospital, Birmingham, United Kingdom

Address for correspondence Rajesh Botchu, MRCS, FRCR, Department of Musculoskeletal Radiology, Royal Orthopedic Hospital, Bristol Road South, Northfield, Birmingham B312AP, United Kingdom (e-mail: drbrajesh@yahoo.com).

Indian J Radiol Imaging 2023;33:471–477.

Abstract

Introduction Adult dysplasia of the hip (ADH) is a disorder of abnormal development of the hip joint resulting in a shallow acetabulum and uncovering of the femoral head. Several radiological measurements such as the Tönnis angle (acetabular index), lateral center edge angle of Wiberg, and cross-sectional imaging parameters exist to calculate hip dysplasia.

Aims The aim of this article was to describe a new ancillary linear measure of ADH on cross-sectional imaging, the Birmingham Royal Orthopaedic Hospital (BROH) Femoral offset.

Patients and Methods Anteroposterior radiographs of the pelvis and computed tomography imaging of 100 consecutive patients with suspected hip dysplasia were reviewed. Demographic details and clinical indications were recorded. Tönnis angle was utilized to measure hip slope on radiographs and the BROH femoral offset was calculated for each patient. Student's *t*-test and one-way analysis of variance (ANOVA) were performed. Intraclass correlation coefficient analysis was evaluated to assess the reliability between observers.

Results There was a total of 100 patients (128 hips) included in the study (60 with normal Tönnis angle, 53 had dysplasia, and 15 had decreased Tönnis angle). The average BROH femoral offset in the dysplastic cohort was increased in comparison to the normal cohort with a statistically significant *p*-Value of 0.0001. The *p*-value was 0.00031 on ANOVA. The BROH femoral offset calculation revealed good intra- and interobserver reliability of 0.9 and 0.9, respectively.

Conclusion The BROH femoral offset can be an additional index for measuring ADH that is easier to calculate, and reproducible with good intra- and inter-observer reliability on cross-sectional imaging.

Keywords

- ▶ adult hip dysplasia
- ▶ acetabular dysplasia
- ▶ radiography
- ▶ pelvic radiograph
- ▶ Tönnis angle
- ▶ computed tomography

article published online
 June 16, 2023

DOI <https://doi.org/10.1055/s-0043-1769501>.
 ISSN 0971-3026.

© 2023. Indian Radiological Association. All rights reserved.
 This is an open access article published by Thieme under the terms of the Creative Commons Attribution-NonDerivative-NonCommercial-License, permitting copying and reproduction so long as the original work is given appropriate credit. Contents may not be used for commercial purposes, or adapted, remixed, transformed or built upon. (<https://creativecommons.org/licenses/by-nc-nd/4.0/>)
 Thieme Medical and Scientific Publishers Pvt. Ltd., A-12, 2nd Floor, Sector 2, Noida-201301 UP, India

Introduction

Adult dysplasia of the hip (ADH) encompasses a spectrum of disordered development of the hip joint resulting in a shallow acetabulum with a lack of anterior and lateral coverage of the femoral head.¹ The incidence of hip dysplasia is reported to range from 3 to 5% with a female preponderance and it is a well-recognized risk factor for early osteoarthritis. Hip osteoarthritis in up to 20 to 40% of patients is thought to be secondary to dysplasia.²⁻⁴ ADH typically presents with hip pain in the groin area or lateral aspect with or without a limp. This is often exacerbated with activity and may be associated with a sensation of catching or popping. Radiographs and cross-sectional imaging including computed tomography (CT) and magnetic resonance imaging (MRI) play a key role in assessing coverage of the femoral head, acetabular deficiency, and any associated soft tissue damage of the cartilage, ligamentum teres, and labrum.⁵⁻⁸ Radiographs tend to be the preliminary investigation for diagnosis in hip dysplasia with a spectrum of useful radiographic measurements including Tönnis angle (acetabular index), lateral center edge angle of Wiberg, femoral neck-shaft angle, and delta angle to evaluate deficient coverage of the femoral head or assess the slope of the acetabulum^{6,9,10} (►Table 1; ►Figs. 1 and 2). However, the aforementioned radiographic calculations are based on angular and are susceptible to variability resulting from the

position of the pelvis. Furthermore, research has demonstrated poor interobserver and intraobserver reliability of these radiographic measurements in the estimation of hip dysplasia.^{11,12}

CT allows a clinician to evaluate hip dysplasia more thoroughly in three-dimensional (3D) and is unaffected by pelvis position¹³ (►Table 2).

We have designed and investigated the use of a new ancillary measure of ADH on cross-sectional CT imaging, the Birmingham Royal Orthopaedic Hospital (BROH) femoral offset. The BROH femoral offset is a linear measure, easy to calculate on axial-CT, and allows evaluation of the anterior femoral head coverage in patients with ADH.

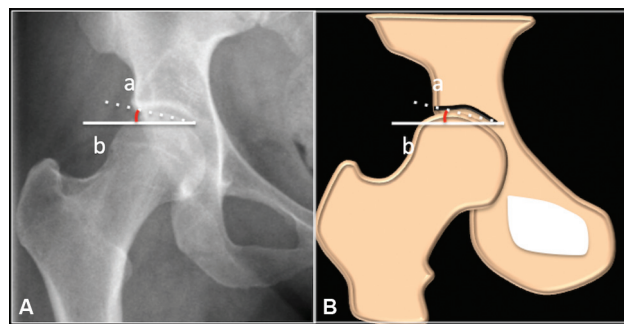


Fig. 1 Anteroposterior radiograph (A) and schematic (B) showing measurement of Tönnis angle.

Table 1 Traditionally used radiological indices to assess and measure adult dysplasia of the hip (ADH) on plain radiography

	Radiological measurement	Radiological technique calculation method	Measures	Normal values	Abnormal values
1	Lateral center edge angle (LCEA) of Wiberg	Anteroposterior plain pelvis radiograph - Angle between a vertical, perpendicular line through the center of femoral head of interest (Line A) and a tangential line to lateral margin of the acetabulum (Line B)	Coverage of femoral head	Between 25 and 35 degrees	Dysplasia <20 degrees Severe < 5 degrees
2	Tönnis angle (acetabular index)	Anteroposterior plain pelvis radiograph - Angle between a horizontal line at the level medial edge of "sourcil" (Line A) and a line tangential to medial and lateral edges of sourcil (Line B) (►Fig. 1)	Slope of acetabulum socket	Between 3 and 13 degrees	Dysplasia > 13 degrees
3	Femoral neck-shaft angle	Anteroposterior plain pelvis radiograph - Angle between a line along the femoral neck axis through the center of head and intersecting line drawn along the femoral shaft axis	Angle of Inclination	Between 120 and 135 degrees	Coxa Valga > 135 degrees Coxa Vara < 120 degrees
4	Delta angle	Anteroposterior plain pelvis radiograph - Angle between a line through the femoral head center to medial edge of sourcil (Line A) and superior edge of Fovea capitis (Line B)	Sphericity of femoral head	More than > 10 degrees	Fovea Alta ≤ 10 degrees

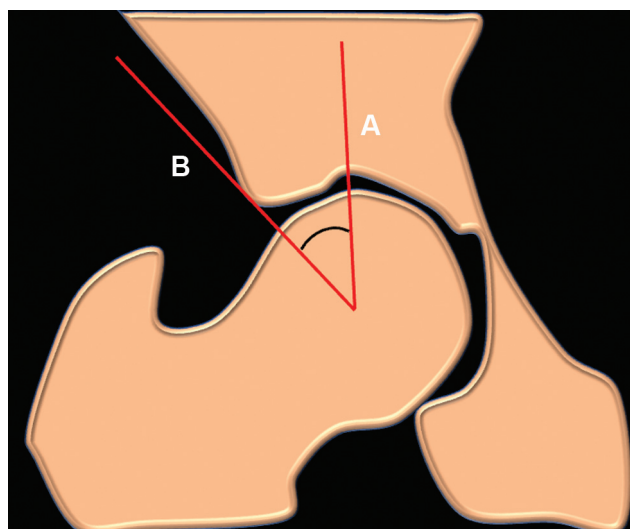


Fig. 2 Schematic showing measurement of lateral center edge angle. The angle between a vertical line from the center of the femoral head (A) and the line connecting the center of the femoral head and the lateral edge of the acetabulum (B).

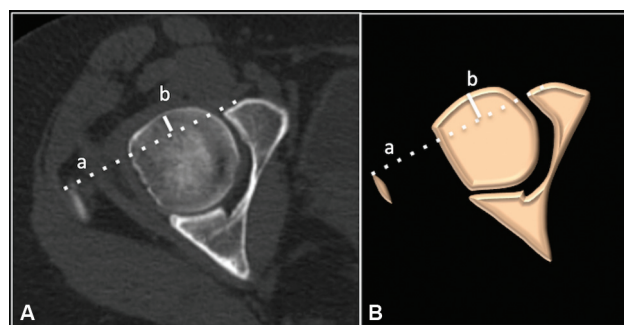


Fig. 3 Axial computed tomography (A) and schematic (B) showing BROH femoral offset measurement.

Patients and Methods

Study Design and Patients

Following local hospital committee approval as a service evaluation, a retrospective evaluation of our Radiology Information System and Picture Archiving and Communication System was performed to identify 100 consecutive patients with suspected ADH and have both anteroposterior radiograph and CT of the pelvis. Patients with trauma, previous surgery and with hip replacements were excluded. The imaging protocol included anteroposterior radiographs of the pelvis. All the CTs were obtained in the axial plane (1 mm slice thickness) and multiplanar reformats were created (64 slice, Siemens Somatom Sensation AS [Siemens Medical Systems; Erlangen, Germany]).

Image Analysis

The radiological images of all the patients were reviewed by two independent experienced clinicians. Tönnis angle was calculated on an anteroposterior radiograph and BROH femoral offset on axial CT images. One reader repeated measurement after 2 weeks to assess interobserver reliability.

Calculation of the Tönnis angle: Tönnis angle is calculated by measuring the angle between a horizontal line at the level of the medial edge of “sourcil” (Line A) and a line tangential to the medial and lateral edges of sourcil (Line B) (►Fig. 1).^{6,14}

Calculation of BROH Femoral Offset

This was calculated on the axial CT images. The cranial most slice of the hip at the level of the tip of the greater trochanter was identified. A line was drawn from the anterior-most tip of the greater trochanter to the anterior-most part of the acetabulum. (Line A). A line was drawn perpendicular to Line “A” to the anterior most part of the femoral head that is termed the BROH femoral offset (Line B; ►Fig. 3).

Table 2 Computed tomography (CT) imaging measurements of adult dysplasia of the hip (ADH)

	CT scan measurement	Imaging technique calculation method	Measures	Normal values	Abnormal values
1	Anterior acetabular sector angle (AASA)	Axial CT scan taken one cut above greater trochanter Angle between lines through centers of both femoral heads and another line tangential to the anterior lip of the acetabulum	Anterior coverage	>50 degrees	Dysplasia ≤ 50 degrees
2	Posterior acetabular sector angle (PASA)	Axial CT scan taken one cut above greater trochanter Angle between lines through centers of both femoral heads and another line tangential to the posterior lip of the acetabulum	Posterior coverage	>90 degrees	Dysplasia ≤ 90 degrees
3	Horizontal acetabular sector angle (HASA)	Axial CT scan taken one cut above greater trochanter Angle between lines from anterior lip of acetabulum going through the center of the femoral head and the posterior lip of the acetabulum		>140 degrees	Dysplasia ≤ 140 degrees

Data Collection

We recorded patient demographics details, Tönnis angle, and BROH femoral offset for each hip for every patient in the cohort. Data collection was undertaken using Microsoft Excel data spreadsheet and analyzed using SPSS 24.0 software (SPSS Inc; Chicago, Illinois, United States).

Statistical Analysis

Mean, standard deviation or median (range), and standard error of mean were used to summarize data. Analysis of variance (ANOVA) test was performed between the three cohorts: normal Tönnis angle and those with reduced or increased Tönnis angle. Student's *t*-test was used to assess significance between normal and abnormal Tönnis angle cohort. Intraclass correlation coefficient (ICC) analysis was undertaken to assess reliability. The ICC is a value between 0 and 1, in which score of excellent reliability is over 0.9, good reliability of 0.75 to 0.9, moderate reliability of 0.5 to 0.75 moderate, and poor reliability less than 0.5.¹⁵ A *p*-value of less than 0.05 was considered significant in this study.

Results

There was a total of 100 patients (128 hips) included in the study (60 had normal Tönnis angle, 53 had dysplasia, and 15 had decreased Tönnis angle). The average age among all three cohorts was comparable and there was a female predominance in all three cohorts. The average BROH femoral offset in the dysplastic cohort was increased in comparison to the normal cohort and this was statistically significant with a *p*-value of 0.0001 (Student's *t*-test; ▶Figs. 4, 5) ANOVA was performed between all three cohorts, and this was also statistically significant with a *p*-Value of 0.00031. The BROH femoral offset was shown to be reliable with good intra- and interobserver reliability of 0.9 and 0.9, respectively. Bland–Altman plots also demonstrated good intra- and interobserver reliability (▶Figs. 6 and 7). Demographic details, BROH femoral offset, and Tönnis angle measurements in the study group with descriptive statistics are depicted in ▶Tables 3 and 4.

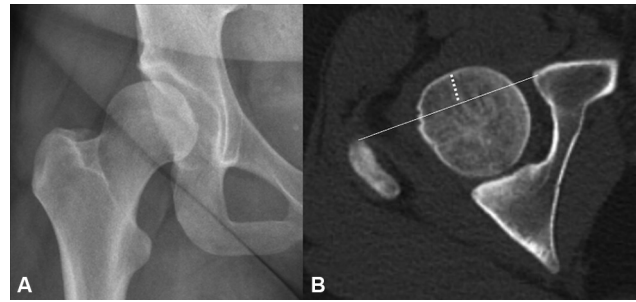


Fig. 4 Anteroposterior radiographs of the right hip (A) of dysplastic hips with increased Tönnis angle with corresponding computed tomography (B) showing increased femoral offset.

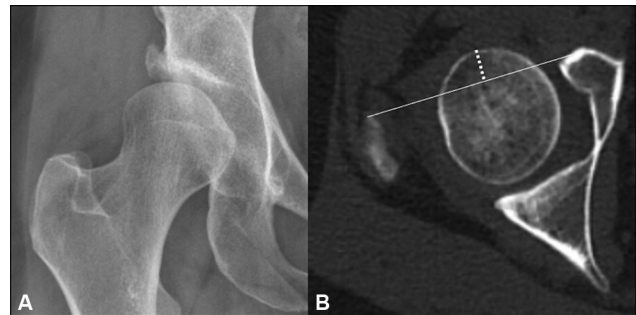


Fig. 5 Anteroposterior radiographs of the right hip (A) of dysplastic hips with increased Tönnis angle with corresponding computed tomography (B) showing increased femoral offset.

Discussion

ADH is characterized by morphological abnormality of congruity of the hip joint, ranging from a shallow acetabulum, uncovering of the femoral head to a completely dislocated hip. It is a well-recognized cause of adult hip pain.¹⁶ Untreated, ADH has been reported to contribute to the development of symptomatic hip osteoarthritis in 20 to 40% of patients with osteoarthritis of the hip requiring surgical intervention such as total hip replacement.^{3,6} Despite the attempts of widespread screening for hip dysplasia at birth or during

Bland-altman plot (interobserver reliability - reader 1 vs reader 2)

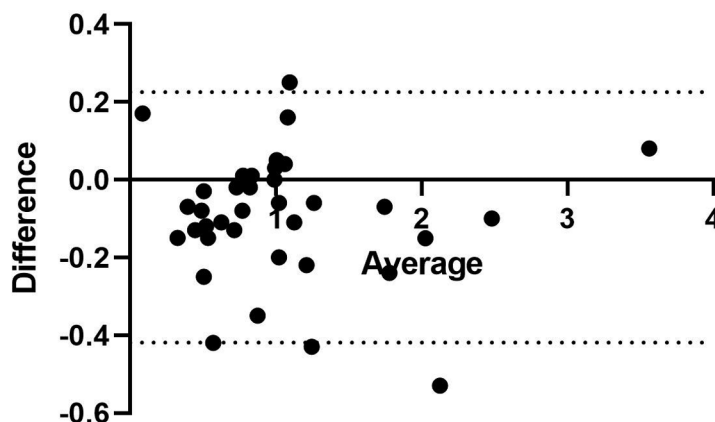


Fig. 6 Bland–Altman plot shows correlation between two readers with good interobserver reliability.

Bland-altman plot - intraobserver reliability - reader 1 vs reader 1 repeat

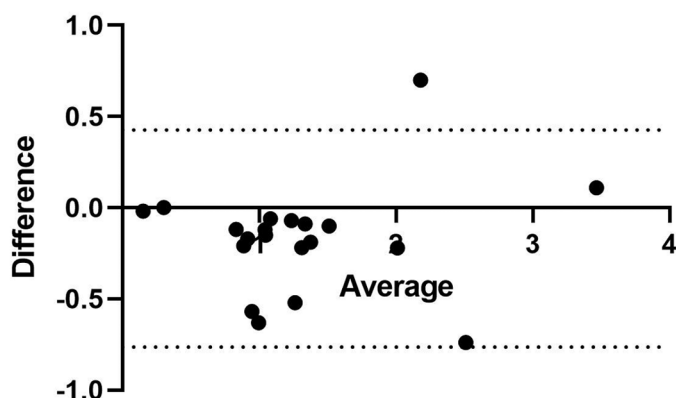


Fig. 7 Bland–Altman plot showing good intraobserver reliability.

Table 3 Demographics of the study group of 100 patients ($n = 128$ hips)

Age in years			
Tönnis angle			
	>10 degrees	0–10 degrees	<10 degrees
Male	21	16	6
Female	32	44	9
Mean	29.3	25.6	28.5
Maximum	69	52	16
Minimum	16	11	14

infancy, a considerable number of patients go undetected until adulthood due to the later onset of symptoms or delayed diagnosis.¹⁷ Since periacetabular osteotomy and hip preservation procedures at an early age when acetabular remodeling is possible may prevent the need for hip replacement surgery, early detection, and treatment of acetabular dysplasia have been emphasized.¹⁸

Radiological imaging plays a key role in the diagnosis, monitoring, and deciding management strategies in patients with ADH.^{3,5–7,13}

Plain radiography is the preliminary investigation in the assessment of hip dysplasia. An anteroposterior radiograph of the pelvis, a lateral “false profile” view, and an abduction view of the hip is commonly performed views.^{5,6} Plain radiography evaluation has the advantage of affordability, better accessibility, and universal availability. Traditional measurements undertaken include the LCEA of Wiberg, Tönnis angle (acetabular index), femoral neck-shaft angle, and the delta angle.^{6,9,10} These angles can assess the coverage of the femoral head, the slope of the acetabulum, and the femoral version to guide the management of ADH. However, these angular measurements are prone to measurement errors with variable reliability.^{11,12} Plain radiographs also lack the sensitivity to detect early osteoarthritis of the hip.

Table 4 BROH femoral offset and Tönnis angle measurements in the study group of 100 patients ($n = 128$ hips)

	Tönnis angle		
	>10 degrees	0–10 degrees	<10 degrees
Femoral offset in centimeters (cm)			
Mean	1.2	0.78	0.96
SD	0.65	0.41	0.45
SEM	0.09	0.05	0.11
Number	53	60	15
Median	1.1	0.76	0.85
95%CI	1.02–1.37	0.68–0.89	0.71–1.2

Abbreviations: CI, confidence interval; SD, standard deviation; SEM, standard error of mean.

The LCEA of Wiberg remains the oldest, widely used measurement in the evaluation of hip dysplasia.¹⁹ It measures the coverage of the femoral head; however, it has had modifications undertaken over the years to improve its accuracy. Ogata et al suggest their “refined” LCEA can more accurately determine head coverage, especially in younger children with dysplastic hips.²⁰ Though there is a general agreement that an LCEA more than 25 degrees is normal and less than 20 degrees is consistent with dysplasia, debate remains about the characterization of hips with LCEA between 20 and 25 degrees and its application in patients undergoing periacetabular osteotomy.^{21,22}

The Tönnis angle (acetabular index) or horizontal “toit externe angle” measures the slope of the weight-bearing surface of the acetabulum or “sourcil”.¹⁴ A normal hip has values between 3–13 and more than 10 degrees suggestive of a dysplastic hip.⁶ However, Tönnis angle is unable to evaluate anterior femoral coverage and cannot be measured if the medial edge of the acetabular sourcil on the pelvic radiograph is blurred.¹²

ADH has been established to be a 3D deformity and hence radiographic evaluation has its inherent limitation bearing this concept in mind. There is an increased use of cross-

sectional imaging (CT and MRI) in the management of hip dysplasia. This involves assessment of the coverage of the femoral head, cartilage, labrum, femoral and acetabular version, and periarticular soft tissues. CT or MRI also provides 3D assessment of the hip joint allowing clarification of size, shape, and orientations of the acetabular deficiencies if present in patients with ADH.¹³ It is thus helpful in surgical planning and preoperative assessment of the dysplastic hip.⁹ Various studies have highlighted the utility of cross-sectional imaging in evaluating coverage of the femoral head and analysis of acetabular deficiencies in patients with ADH.^{6,9,13,23} The angles mentioned in the CT evaluation of hip dysplasia include anterior acetabular sector angle (AASA), posterior acetabular sector angle (PASA), and the horizontal acetabular sector angle. Some of the radiographic measurements crucial in the diagnosis of dysplasia mentioned before can be used to some extent in cross-sectional imaging. However, the main limiting factor is the identification of the exact slice to measure the angles. AASA and PASA are anterior and posterior coverage angles of the femoral head that have been described on cross-sectional imaging and are assessed on axial images (normal AASA <50 degrees and PASA <90 degrees).^{24,25} The measurements of these angles for hip dysplasia on MRI and CT are, however, found to be comparable.²⁶

There is an intrinsic advantage of cross-sectional imaging in the assessment of ADH due to its versatility, 3D characterization of the hip abnormality, and use in surgical planning. The BROH femoral offset is a linear measurement that is measured on axial images at the tip of the greater trochanter and found to increase proportionally with the degree of hip dysplasia. We measured these on CT but believe that this can be analyzed on MRI too. The BROH femoral offset can be used in the diagnosis and management of hip dysplasia. Based on our results, we propose a normal BROH femoral offset to be less than 1 cm. BROH femoral offset of more than 1 cm should be considered as dysplasia.

Limitations of the Study

There were a few limitations to this study. This was a small retrospective study. However, the application of ICC analysis has allowed us to reinforce the reliability of the BROH femoral offset. Also, we used only the Tönnis angle (acetabular index) for the assessment of hip dysplasia. Further larger, prospective, cohort studies comparing other described angular measurements will be useful to strengthen our findings and applicability of the BROH femoral offset in the assessment of ADH.

Conclusion

The BROH femoral offset is a new, ancillary measure on cross-sectional imaging that can be used to supplement existing indices to assess ADH. Since it is a linear measure, it is easy to calculate and has the potential of being included as another useful parameter in the CT scan evaluation of ADH. It has shown good intra- and interobserver reliability in the current

study in measuring anterior coverage of the femoral in ADH. Further studies are needed to understand how the BROH femoral offset can be validated as an additional measure in the diagnosis and monitoring of patients with ADH.

Funding

None.

Conflict of Interest

None declared.

References

- 1 Wyles CC, Heidenreich MJ, Jeng J, Larson DR, Trousdale RT, Sierra RJ. The John Charnley award: redefining the natural history of osteoarthritis in patients with hip dysplasia and impingement. *Clin Orthop Relat Res* 2017;475(02):336–350
- 2 Engesæter IØ, Laborie LB, Lehmann TG, et al. Prevalence of radiographic findings associated with hip dysplasia in a population-based cohort of 2081 19-year-old Norwegians. *Bone Joint J* 2013;95-B(02):279–285
- 3 Gala L, Clohisy JC, Beaulé PE. Hip dysplasia in the young adult. *J Bone Joint Surg Am* 2016;98(01):63–73
- 4 Jacobsen S, Sonne-Holm S. Hip dysplasia: a significant risk factor for the development of hip osteoarthritis. A cross-sectional survey. *Rheumatology (Oxford)* 2005;44(02):211–218
- 5 Garbuz DS, Masri BA, Haddad F, Duncan CP. Clinical and radiographic assessment of the young adult with symptomatic hip dysplasia. *Clin Orthop Relat Res* 2004;(418):18–22
- 6 Beltran LS, Rosenberg ZS, Mayo JD, et al. Imaging evaluation of developmental hip dysplasia in the young adult. *AJR Am J Roentgenol* 2013;200(05):1077–1088
- 7 Kim HT, Kim IB, Lee JS. MR-based parameters as a supplement to radiographs in managing developmental hip dysplasia. *Clin Orthop Surg* 2011;3(03):202–210
- 8 Starr V, Ha BY. Imaging update on developmental dysplasia of the hip with the role of MRI. *Am J Roentgenol* 2014;203(06):1324–1335
- 9 Delaunay S, Dussault RG, Kaplan PA, Alford BA. Radiographic measurements of dysplastic adult hips. *Skeletal Radiol* 1997;26(02):75–81
- 10 Popat R, Lee S, George DA, Amiras D, Sarraf KM. Assessment of the young adult hip joint using plain radiographs. *Musculoskelet Surg* 2020;104(03):245–255
- 11 Kraeutler MJ, Safran MR, Scillia AJ, Ayeni OR, Garabekyan T, Meidan O. A contemporary look at the evaluation and treatment of adult borderline and frank hip dysplasia. *Am J Sports Med* 2020;48(09):2314–2323
- 12 Fa L, Wang Q, Ma X. Superiority of the modified Tönnis angle over the Tönnis angle in the radiographic diagnosis of acetabular dysplasia. *Exp Ther Med* 2014;8(06):1934–1938
- 13 van Bosse H, Wedge JH, Babyn P. How are dysplastic hips different? A three-dimensional CT study. *Clin Orthop Relat Res* 2015;473(05):1712–1723
- 14 Tönnis D. Normal values of the hip joint for the evaluation of X-rays in children and adults. *Clin Orthop Relat Res* 1976;(119):39–47
- 15 Koo TK, Li MY. A guideline of selecting and reporting intraclass correlation coefficients for reliability research. *J Chiropr Med* 2016;15(02):155–163. Doi: 10.1016/j.jcm.2016.02.012 Erratum in: *J Chiropr Med* 2017 Dec;16(4):346
- 16 Schmitz MR, Murtha AS, Clohisy J, ANCHOR Study Group. Developmental dysplasia of the hip in adolescents and young adults. *J Am Acad Orthop Surg* 2020;28(03):91–101
- 17 Leide R, Bohman A, Wenger D, Overgaard S, Tiderius CJ, Rogmark C. Hip dysplasia is not uncommon but frequently overlooked: a

- cross-sectional study based on radiographic examination of 1,870 adults. *Acta Orthop* 2021;92(05):575–580
- 18 Kosuge D, Yamada N, Azegami S, Achan P, Ramachandran M. Management of developmental dysplasia of the hip in young adults: current concepts. *Bone Joint J* 2013;95-B(06):732–737
 - 19 Werner CM, Ramseier LE, Ruckstuhl T, et al. Normal values of Wiberg's lateral center-edge angle and Lequesne's acetabular index—a coxometric update. *Skeletal Radiol* 2012;41(10):1273–1278
 - 20 Ogata S, Moriya H, Tsuchiya K, Akita T, Kamegaya M, Someya M. Acetabular cover in congenital dislocation of the hip. *J Bone Joint Surg Br* 1990;72(02):190–196
 - 21 McClincy MP, Wylie JD, Yen YM, Novais EN. Mild or borderline hip dysplasia: are we characterizing hips with a lateral center-edge angle between 18° and 25° appropriately? *Am J Sports Med* 2019;47(01):112–122
 - 22 Puloski SK, Leunig M, Ganz R. Acetabular centre-edge angles revisited: applications and limitations in patients with acetabular dysplasia undergoing periacetabular osteotomy. *Hip Int* 2006;16(01):1–7
 - 23 Haddad FS, Garbuz DS, Duncan CP, Janzen DL, Munk PL. CT evaluation of periacetabular osteotomies. *J Bone Joint Surg Br* 2000;82(04):526–531
 - 24 Mimura T, Mori K, Kitagawa M, et al. Multiplanar evaluation of radiological findings associated with acetabular dysplasia and investigation of its prevalence in an Asian population: a CT-based study. *BMC Musculoskelet Disord* 2017;18(01):50
 - 25 Tallroth K, Lepistö J. Computed tomography measurement of acetabular dimensions: normal values for correction of dysplasia. *Acta Orthop* 2006;77(04):598–602
 - 26 Subramanian A, Hegde G, Azzopardi C, et al. TI VIBE inversion MRI – an alternative to CT for imaging of hip pain. *J Clin Orthop Trauma* 2021;19:196–199