

Osteomyelitis: A Descriptive Study

Laura Prieto-Pérez, MD, Ramón Pérez-Tanoira, PhD*, Elizabet Petkova-Saiz, MD,
Concepción Pérez-Jorge, PhD*, Cristina Lopez-Rodriguez, MD,
Beatriz Alvarez-Alvarez, MD, Jorge Polo-Sabau, MD, Jaime Esteban, MD*

Departments of Internal Medicine and *Clinical Microbiology, IIS-Fundación Jiménez Díaz, Madrid, Spain

Background: To analyze the incidence and clinical-microbiological characteristics of osteomyelitis (OM) in a tertiary Spanish hospital.

Methods: All cases diagnosed with OM between January 2007 and December 2010 were retrospectively reviewed. The variables examined include epidemiological characteristics, risk factors, affected bone, radiographic changes, histology, microbiological culture results, antibiotic treatment, and the need for surgery.

Results: Sixty-three cases of OM were diagnosed. Twenty-six patients (41.3%) had acute OM whereas 37 patients (58.7%) were classified as chronic OM. OM may result from haematogenous or contiguous microbial seeding. In this group, 49 patients (77.8%) presented with OM secondary to a contiguous source of infection and 14 patients had hematogenous OM (22.2%). *Staphylococcus aureus* was the most commonly found microorganism.

Conclusions: OM mainly affected patients with risk factors related to the presence of vascular diseases. Antibiotic treatment must be guided by susceptibility patterns of individual microorganisms, although it must be performed together with surgery in most of the cases.

Keywords: *Osteomyelitis, Bone infection, Antimicrobial therapy, Staphylococcus aureus, Debridement*

Osteomyelitis (OM) is an inflammatory process accompanied by bone destruction and caused by an infecting microorganism.^{1,2)} It is an infectious disease that is difficult to diagnose, and treatment is complex because of its heterogeneity, pathophysiology, clinical presentation, and management.³⁻⁵⁾

There are several ways to classify OM. The two major classification schemes are those described by Lew and Waldvogel²⁾ and Cierny et al.⁶⁾ The Cierny-Mader OM classification combines both anatomic factors (medullar,

superficial, localized, or diffuse OM) and physiological classes (healthy host, systemic and/or local compromise, and treatment worse than the disease).^{1,3)} This classification applies best to long and large bones and it is not very useful for the digits, small bones, or the skull.^{2,6,7)}

The Waldvogel scheme was used in this study, and our cases were classified according to the duration of the disease (acute or chronic), the mechanism of infection (hematogenous or contiguous seeding), and the presence of vascular insufficiency. Chronic OM is defined as long-standing infection that evolves over months or even years, characterized by the persistence of microorganisms, low-grade inflammation, and the presence of dead bone (sequestrum) and fistulous tracts.^{8,9)} Clinical signs persisting for longer than 10 days are associated with the development of necrotic bone and chronic OM.^{2,7)} Chronic OM may also present as a recurrent or intermittent disease, with periods of quiescence of variable duration.⁸⁾

The increasing age of the general population has led to a rise in the prevalence of diabetes and peripheral

Received April 4, 2013; Accepted June 24, 2013

This work was presented at the 10th Congress of the European Federation of Internal Medicine and 32nd National Congress of the Spanish Society of Internal Medicine.

Correspondence to: Ramón Pérez-Tanoira, PhD

Department of Clinical Microbiology, IIS-Fundación Jiménez Díaz, Av. Reyes Católicos 2, Madrid, Spain

Tel: +34-915504900, Fax: +34-915494764

E-mail: ramontanoira@hotmail.com

vascular disease, both predisposing and complicating OM, which if not managed adequately, may result in amputation, sepsis, or death.^{10,11} The timing of its diagnosis and treatment is crucial in the diabetic patient in order to avoid later amputation.¹²

The different kinds of OM often require diverse treatments, such as surgical debridement or resection and/or prolonged antibiotic therapy.¹³ The cornerstone of effective management of OM is early diagnosis and aggressive treatment with thorough debridement and culture-directed antibiotic therapy.^{1,5,9,14} In order to obtain accurate pathogen identification, the treating surgeon should take appropriate tissue samples. The gold standard for OM diagnosis consists of a biopsy specimen and its culture in order to identify the infecting organism.^{4,8}

In chronic OM, the antibiotic choice should be based on sensitivity data: a short course of intravenous antibiotics, followed by a prolonged course of oral antibiotics is the usual therapy.¹⁴

Staphylococcus aureus represents the most common isolated microorganism in most types of OM, affecting 50% to 70% of cases.^{15,16} Other microorganisms commonly found in cases of OM include aerobic Gram-positive cocci like coagulase-negative *staphylococci*, and also aerobic Gram-negative bacilli and anaerobes, these latter ones are often isolated as part of mixed infections.¹⁷

METHODS

Patients appearing in hospital records as having diagnosis of OM between January 1, 2007 and December 31, 2010 were reviewed. Patients with implant-related OM were excluded from the study. The clinical records and radiographs of every patient were retrospectively studied using a predefined protocol, which included age, sex, site of infection, and response to treatment. These variables were all compared. A summary of the findings is shown in Table 1.

Diagnosis of OM was based on the assessment of the Infectious Disease Department of the hospital, taking into account both clinical assessment and physical examination, along with wound or blood cultures, histology, and radiographic examinations.

During the studied period, cultures from different samples were performed according to commonly accepted techniques. Isolated microorganisms were identified by common biochemical tests (coagulase and oxidase) and commercial identification kits (API System, bioMérieux, Marcy L'Etoile, France). Susceptibility testing was performed using a disc-plate assay according to the EUCAST protocols.¹⁸ The study was approved by the Ethics Re-

Table 1. Symptoms, Mechanisms of Infections, Risk Factors, and Results of Radiographic and Histologic Investigations in the 63 Patients

Variable	Acute (26)	Chronic (37)
Symptom		
Duration (wk)	< 2	> 2
Skin change	3	9
Pain	18	22
Fever	4	3
Rhabdomyolysis	-	2
Sepsis	1	1
Mechanism of infection		
Hematogenous	8	6
Bacteriemia	2	2
Skin lesion	4	3
Trauma	2	-
Odontogena	-	1
Contiguous	18	31
Bacteriemia	9	19
Skin lesions	7	11
Trauma	2	-
Odontogena	-	1
Risk factor		
Vascular insufficiency	4	7
Diabetes mellitus	7	7
Atherosclerosis	2	7
History of chronic liver disease	1	6
Chronic renal failure	1	3
History of tuberculosis	-	2
Human immunodeficiency virus	1	2
Cancer	3	3
Protheses	1	9
Radiographic change		
Unknown	4	4
Ultrasonography	1	-
Bone scintigraphy	1	-
Nuclear magnetic resonance	6	14
X-ray	11	16
Computed tomography	3	3
Histological study		
Positive	5 (19*)	4

*Test not done on remaining patients.

search Committee of the hospital.

Data Analysis

For the statistical study, frequency analysis was used to obtain a distribution of age and treatment for acute or chronic OM. Fisher exact test was used to examine the significance of the association (contingency) between patient outcomes (favorable or unfavorable) and treatment (antimicrobial, surgical, and combined therapy). EPI-Info ver. 3.5.1. (Centers for Disease Control and Prevention, Atlanta, GA, USA) was used in order to perform the statistical studies.

RESULTS

A total of 63 patients were included in the study. Forty-six of them were males (73.01%). Acute OM was common in the 1st–2nd decades of life whereas chronic OM frequency increased with age, as is shown in Fig. 1. Age distribution for both acute and chronic OM is also shown in Fig. 1.

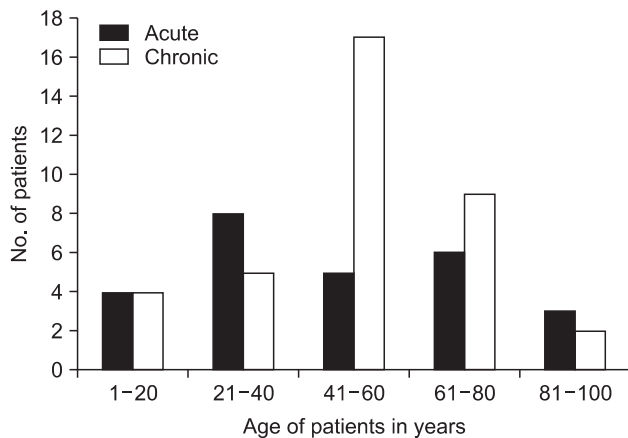


Fig. 1. Age of 63 patients with osteomyelitis.

Site of Infection

Both phalanges and long bones of the lower extremities were the most commonly involved sites (55.6% each). Chronic OM occurred more frequently than acute OM in the metatarsus, calcaneus, and hip (Fig. 2). No significant differences were found in other bones regarding acute and chronic conditions of the disease. Other bones included the talus, scaphoid, clavicle, occipital, ribs, frontal, ischium, and radius. Fifty-five patients (87.3%) had recent history of trauma or skin lesions that were considered the source of the infection.

Microbiological Results

Twenty-eight patients (44.4%) had 1 positive sample whereas 14 patients (22.2%) had 2 or more positive samples. A summary of microbiological data is shown in Table 2. Among the 20 patients with past history of trauma, 13 patients (65.0%) had a positive culture, and among the 35 patients with previous history of a skin lesion, 23 patients

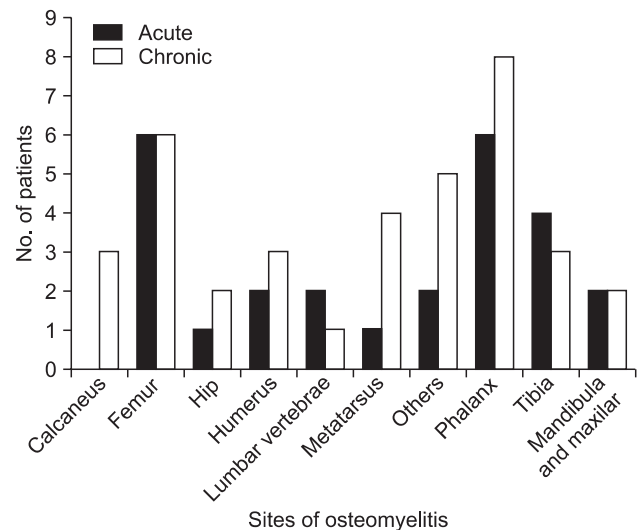


Fig. 2. Sites of osteomyelitis in 63 patients.

Table 2. Frequency of Microbiological Isolates from Acute and Chronic Osteomyelitis

Variable	Acute (26)				Chronic (37)				
	Bacteriemia	Skin lesion	Trauma	Odontogena	Bacteriemia	Skin lesion	Trauma	Odontogena	Sinusitis
<i>Staphylococcus aureus</i>	1	4	4	-	1	2	3	-	-
Other gram-positive cocci	1	3	-	-	-	2	2	1	1
Gram-negative bacilli	-	4	-	-	1	1	2	-	-
<i>Candida spp.</i>	-	-	-	-	-	-	1	-	-
Polymicrobial	-	-	1	-	-	7	-	-	-

(65.7%) had a positive culture.

Treatment and Outcome

Fourteen patients (22.2%) received antimicrobial therapy alone, 5 patients (7.9%) received surgical therapy alone, whereas 44 patients (69.84%) were given a combination of antimicrobial and surgical therapy.

Acute osteomyelitis

Twenty-four patients (92.31%) were initially managed with antibiotics, and 14 of these cases (53.84%) were treated with surgery as well. Every other case was treated with surgery alone. Among patients who received medical treatment, antibiotics were given over a minimum of 4 weeks in 13 cases (54.17%). A combination of antibiotics was administered in 14 cases (58.33%), whereas monotherapy was used in 9 cases (37.5%). Ciprofloxacin was given in combination with other antibiotics in 7 cases (50%) and amoxicillin/clavulanic acid, cloxacillin, or ciprofloxacin was used as a single-agent antimicrobial in 6 cases (25.0%). Complications developed in 4 cases, including amputation of the toe phalanx in two of them. The distribution according to treatment with antimicrobial therapy alone, using frequency analysis, was 27.8% for a favorable outcome (95% confidence interval [CI], 9.7 to 53.59) and 25% for an unfavorable outcome (95% CI, 0.6 to 80.6). For surgical therapy, rates were 11.1% (95% CI, 1.4 to 34.7) and 0% (95% CI, 0.0 to 60.2); finally, for combined therapy 61.1% (95% CI, 35.7 to 82.7) and 75% (95% CI, 19.4 to 99.4), respectively. No statistical differences in outcomes were found between antimicrobial, surgery, or combined therapy ($p = 0.53$, Fisher exact test).

Chronic osteomyelitis

These patients were initially managed with antibiotics in 34 cases (91.9%); 30 cases (81.1%) also required surgery, while the remaining 2 patients were treated with surgery alone. Antimicrobial therapy was administered for a minimum of 4 weeks in 21 cases (61.8%). A combination of antibiotics was used in 19 cases (55.9%), with ciprofloxacin the antibiotic most frequently used in these combinations (10 cases, 52.6%). Monotherapy was used in 14 cases (41.2%) and amoxicillin/clavulanic acid, cloxacillin, or ciprofloxacin were used in 9 cases (26.5%). Complications were reported in 13 cases (35.1%), and amputation was performed in 7 cases (18.9%). Three of these cases were foot phalanxes. The frequency distribution according to treatment, using frequency analysis, was 6.7% for antimicrobial therapy alone in patients who had a favorable outcome (95% CI, 0.2 to 31.9) and 7.7% in patients with

an unfavorable outcome (95% CI, 0.2 to 36.0). For surgical therapy, rates were 13.3% (95% CI, 1.7 to 40.5) and 7.7% (95% CI, 0.2 to 36.0). For combined treatment, they were 80.01% (95% CI, 51.9 to 95.7) and 84.6% (95% CI, 54.6 to 98.1), respectively. There were no statistical differences in outcome between antimicrobial, surgical, or combined therapy ($p = 0.50$, Fisher exact test).

DISCUSSION

Traditionally, chronic OM has been considered a condition that follows a hematogenous spread of microorganisms.¹⁹⁾ In this series, as in recent reports, this category has been considerably substituted by posttrauma and device-related chronic OM, as well as contiguous disease from diabetic foot infections and skin lesions.²⁰⁾

During childhood, hematogenous OM is more commonly found than contiguous seeding, and it is characterized by an acute febrile illness in addition to pain and immobility of the affected limb.^{3,21,22)} In this study, every patient under 18 years had hematogenous OM (6 patients).

In contrast, bacteremia in adults rarely results in OM, and secondary spread from a contiguous focus of infection, such as from a surgical wound, is more common.^{9,21)} In hematogenous OM in childhood, shorter courses of parenteral antibiotics followed by oral therapy for several weeks obtain a good success rate; provided that the organism is known and adherence with treatment is good, the clinical signs subside rapidly.^{1,2)}

There were no statistical differences in outcome regarding the metatarsus, found between antimicrobial, surgical, or combined therapy, probably because of the use of antibiotics with high activity against the causative microorganisms. However, the relatively low number of cases included must be considered as a possible cause of these results. The high proportion of patients with an unfavorable outcome following combined therapy (82.4%) might be explained by this therapy since it was the treatment chosen in the majority of the studied cases (69.9%).

Treatment of acute OM usually requires adequate debridement, drainage of pus, and prolonged courses of antimicrobial therapy. In the presence of acute infection there are no evidence-based guidelines to dictate whether hardware should be removed or retained.

Single-agent antimicrobial therapy is generally adequate for the treatment of OM except for infections of prosthetic joints (for which an antimicrobial combination including rifampicin is commonly used) and chronic OM. As a general principle, these antibiotics should be given

for 4–6 weeks and, if possible, endovenously. Where quinolones are used, an early switch to oral administration is appropriate.²⁾ Treatment requires isolation of the causative pathogen or pathogens as well as significant debridement for removal of all infective and necrotic material, both originating in the bone origin and in soft tissue.^{15,23)}

One of the reasons why results for chronic OM were worse in this study could be the increased rate of positive polymicrobial cultures compared to acute OM, and the elevated use of monotherapy.

Fifty-five patients (87.30%) had previous history of trauma or skin infection, a significant risk factor for bone and joint infections caused by *S. aureus*. The seriousness of this risk factor is presumably because of the high frequency with which this bacteria causes skin and soft-tissue infections.^{21,22)}

Amputation is an accepted form of treatment for some cases of OM. In our series, 4 out of the 9 patients who required amputation (44.4%) had vascular disease or diabetes mellitus. These factors become a substantial risk of failure for a single course of antimicrobial therapy in cases of OM which are complicated by vascular disease or diabetes; indeed, signs of recurrence in these patients

may call for earlier amputation or for excision of infected bone.^{10,17)} In our series, 5 patients were amputees of foot phalanxes; surgery is more likely to be appropriate and cost-effective when infection involves a bone that is not essential to the foot's architecture.²⁴⁾ Limited limb-saving surgery and prolonged antibiotic therapy directed toward the definitive causative bacteria constitute a more appropriate approach for all other cases. This may decrease limb loss through amputations.^{10,23)}

CONFLICT OF INTEREST

No potential conflict of interest relevant to this article was reported.

ACKNOWLEDGEMENTS

The authors wish to thank for the assistance of the program CONSOLIDER-INGENIO 2010 FUNCOAT-CSD2008-00023 to carry out this study. We also wish to thank Mr. Oliver Shaw for editing the manuscript in English.

REFERENCES

1. Chihara S, Segreti J. Osteomyelitis. *Dis Mon.* 2010;56(1):5-31.
2. Lew DP, Waldvogel FA. Osteomyelitis. *Lancet.* 2004;364(9431):369-79.
3. Sia IG, Berbari EF. Infection and musculoskeletal conditions: osteomyelitis. *Best Pract Res Clin Rheumatol.* 2006;20(6):1065-81.
4. Brady RA, Leid JG, Costerton JW, Shirliff ME. Osteomyelitis: clinical overview and mechanisms of infection persistence. *Clin Microbiol Newsl.* 2006;28(9):65-72.
5. Trampuz A, Zimmerli W. Diagnosis and treatment of implant-associated septic arthritis and osteomyelitis. *Curr Infect Dis Rep.* 2008;10(5):394-403.
6. Cierny G 3rd, Mader JT, Penninck JJ. A clinical staging system for adult osteomyelitis. *Clin Orthop Relat Res.* 2003;(414):7-24.
7. Berbari EF, Steckelberg JM, Osmon DR. Osteomyelitis. In: Mandell GL, Bennett JE, Dolin R, eds. *Mandell, Douglas, and Bennett's principles and practice of infectious diseases.* 7th ed. Philadelphia, PA: Churchill Livingstone, 2010. 1457-68.
8. Mouzopoulos G, Kanakaris NK, Kontakis G, Obakponovwe O, Townsend R, Giannoudis PV. Management of bone infections in adults: the surgeon's and microbiologist's perspectives. *Injury.* 2011;42 Suppl 5:S18-23.
9. Gentry LO. Management of osteomyelitis. *Int J Antimicrob Agents.* 1997;9(1):37-42.
10. Tice AD, Hoaglund PA, Shoultz DA. Outcomes of osteomyelitis among patients treated with outpatient parenteral antimicrobial therapy. *Am J Med.* 2003;114(9):723-8.
11. Maldonado-Rodriguez M, Cajigas-Feliciano Y, Torres-Torres N. Outcomes of osteomyelitis in patients with diabetes: conservative vs. combined surgical management in a community hospital in Puerto Rico. *P R Health Sci J.* 2011;30(2):51-7.
12. Schinabeck MK, Johnson JL. Osteomyelitis in diabetic foot ulcers: prompt diagnosis can avert amputation. *Postgrad Med.* 2005;118(1):11-5.
13. Lipsky BA, Berendt AR, Cornia PB, et al. 2012 Infectious Diseases Society of America clinical practice guideline for the diagnosis and treatment of diabetic foot infections. *Clin Infect Dis.* 2012;54(12):e132-73.
14. Salvana J, Rodner C, Browner BD, Livingston K, Schreiber

- J, Pesanti E. Chronic osteomyelitis: results obtained by an integrated team approach to management. *Conn Med*. 2005; 69(4):195-202.
15. Mruk AL, Record KE. Antimicrobial options in the treatment of adult staphylococcal bone and joint infections in an era of drug shortages. *Orthopedics*. 2012;35(5):401-7.
 16. Berdajs DA, Trampuz A, Ferrari E, Ruchat P, Hurni M, von Segesser LK. Delayed primary versus late secondary wound closure in the treatment of postsurgical sternum osteomyelitis. *Interact Cardiovasc Thorac Surg*. 2011;12(6):914-8.
 17. Lipsky BA. Osteomyelitis of the foot in diabetic patients. *Clin Infect Dis*. 1997;25(6):1318-26.
 18. European Committee on Antimicrobial Susceptibility Testing (EUCAST). Breakpoint tables for interpretation of MICs and zone diameters [Internet]. EUCAST; 2011 [cited 2014 Jan 5]. Available from: http://www.eucast.org/fileadmin/src/media/PDFs/EUCAST_files/Disk_test_documents/EUCAST_breakpoints_v1.3_pdf.pdf.
 19. Sheehy SH, Atkins BA, Bejon P, et al. The microbiology of chronic osteomyelitis: prevalence of resistance to common empirical anti-microbial regimens. *J Infect*. 2010;60(5):338-43.
 20. Trampuz A, Zimmerli W. Diagnosis and treatment of infections associated with fracture-fixation devices. *Injury*. 2006;37 Suppl 2:S59-66.
 21. Cunningham R, Cockayne A, Humphreys H. Clinical and molecular aspects of the pathogenesis of *Staphylococcus aureus* bone and joint infections. *J Med Microbiol*. 1996;44(3): 157-64.
 22. Dubey L, Krasinski K, Hernanz-Schulman M. Osteomyelitis secondary to trauma or infected contiguous soft tissue. *Pediatr Infect Dis J*. 1988;7(1):26-34.
 23. Ertugrul BM, Oncul O, Tulek N, et al. A prospective, multi-center study: factors related to the management of diabetic foot infections. *Eur J Clin Microbiol Infect Dis*. 2012;31(9): 2345-52.
 24. Tan JS, Friedman NM, Hazelton-Miller C, Flanagan JP, File TM Jr. Can aggressive treatment of diabetic foot infections reduce the need for above-ankle amputation? *Clin Infect Dis*. 1996;23(2):286-91.