



# A case of laparoscopic adhesiotomy for urodynia caused by bladder wall adhesion to the anterior abdominal wall after vesicoscopic ureteral reimplantation for vesicoureteral reflux

Yutaro Sasaki<sup>a</sup>, Masayuki Takahashi<sup>a,\*</sup>, Mitsuki Nishiyama<sup>a,b</sup>, Saki Kobayashi<sup>c</sup>, Keito Shiozaki<sup>a,c</sup>, Hiroomi Kanayama<sup>a</sup>

<sup>a</sup> Department of Urology, Tokushima University Graduate School of Biomedical Sciences, 3-18-15 Kuramoto, Tokushima, 770-8503, Japan

<sup>b</sup> Kochi Takasu Hospital, 2705-1 Otsu, Kochi, 781-5103, Japan

<sup>c</sup> Department of Urology, Tokushima Prefectural Central Hospital, 1-10-3 Kuramoto, Tokushima, 770-8539, Japan

## ARTICLE INFO

### Keywords:

Bladder wall adhesion  
Laparoscopic adhesiotomy  
Vesicoscopic ureteral reimplantation  
Vesicoureteral reflux

## ABSTRACT

We herein report an extremely rare case of urodynia caused by bladder wall adhesion to the anterior abdominal wall after vesicoscopic ureteral reimplantation for vesicoureteral reflux with resolution of the urodynia by laparoscopic adhesiotomy. A 13-year-old girl who had undergone vesicoscopic cross-trigonal ureteral reimplantation for bilateral grade IV vesicoureteral reflux subsequently experienced severe urodynia for 5 years until her self-report to the attending physician. Magnetic resonance imaging suggested that bladder wall adhesion to the anterior abdominal wall may have caused the urodynia. Therefore, laparoscopic adhesiotomy of the bladder was performed. Notably, her urodynia disappeared immediately after surgery.

## 1. Introduction

In vesicoscopic ureteral reimplantation, anchoring the bladder wall to the anterior abdominal wall for bladder port placement and bladder port closure are important steps for successful surgery and reduced perioperative complications. We herein report an extremely rare case of severe urodynia caused by bladder wall adhesion to the anterior abdominal wall resulting from the above-mentioned surgical steps; fortunately, the urodynia subsided by laparoscopic adhesiotomy.

## 2. Case presentation

A 13-year-old Japanese girl presented to our institution with severe urodynia. She had undergone vesicoscopic cross-trigonal ureteral reimplantation for bilateral grade IV vesicoureteral reflux (VUR) 5 years previously. Although her VUR had been cured as confirmed by voiding cystourethrography, she developed urodynia shortly after surgery. At 5 years after surgery, she discussed her symptom with the attending physician for the first time. She also experienced mild lower abdominal pain after defecation. Her vital signs and abdominal examination

findings were normal. Her urinalysis results were also normal. Magnetic resonance imaging (MRI) indicated bladder wall adhesion to the anterior abdominal wall in three places where the ports had been inserted during the previous vesicoscopic ureteral reimplantation (Fig. 1a). We suspected that bladder wall adhesion may have caused the urodynia. Therefore, laparoscopy was performed for both diagnosis and treatment. Concurrent cystoscopy revealed a recess in the dome of the bladder (Fig. 1b). The surgical procedure was performed using a three-port transperitoneal approach with the patient in the lithotomy position. No bowel adhesions were present. When the peritoneum immediately above the bladder dome was incised and the retroperitoneal space was opened, we found that the bladder wall had become adhered to the anterior abdominal wall at three places corresponding to the previous laparoscopic ports (Fig. 2). We performed adhesiotomy of the bladder with an electric scalpel. After suturing the peritoneum, the wound was closed. The operation time was 223 minutes, and the estimated blood loss was minimal. No urinary catheter was placed after surgery. Notably, the patient's urodynia disappeared immediately after surgery.

\* Corresponding author.

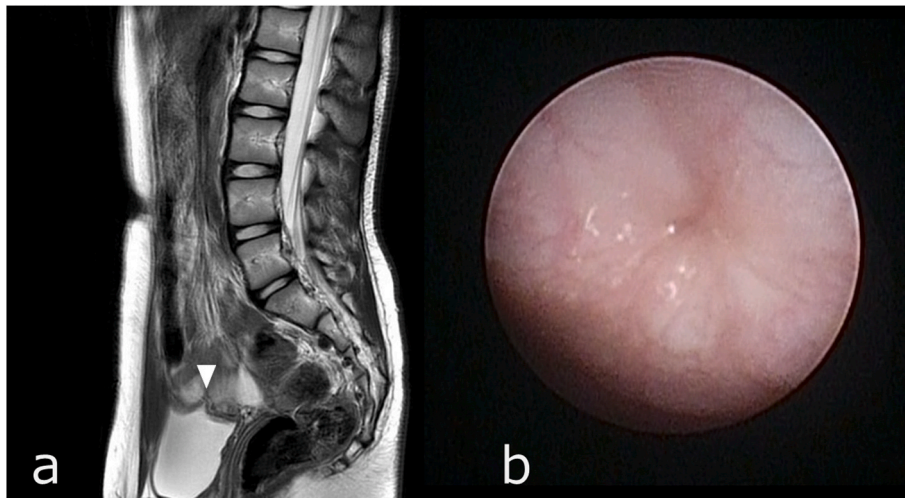
E-mail addresses: [yutaro\\_sasaki@tokushima-u.ac.jp](mailto:yutaro_sasaki@tokushima-u.ac.jp) (Y. Sasaki), [takahashi.masayuki@tokushima-u.ac.jp](mailto:takahashi.masayuki@tokushima-u.ac.jp) (M. Takahashi), [19900730mn@gmail.com](mailto:19900730mn@gmail.com) (M. Nishiyama), [s.akazawa.83@gmail.com](mailto:s.akazawa.83@gmail.com) (S. Kobayashi), [shiohishioo727@yahoo.co.jp](mailto:shiohishioo727@yahoo.co.jp) (K. Shiozaki), [kanayama.hiroomi@tokushima-u.ac.jp](mailto:kanayama.hiroomi@tokushima-u.ac.jp) (H. Kanayama).

<https://doi.org/10.1016/j.eucr.2022.102216>

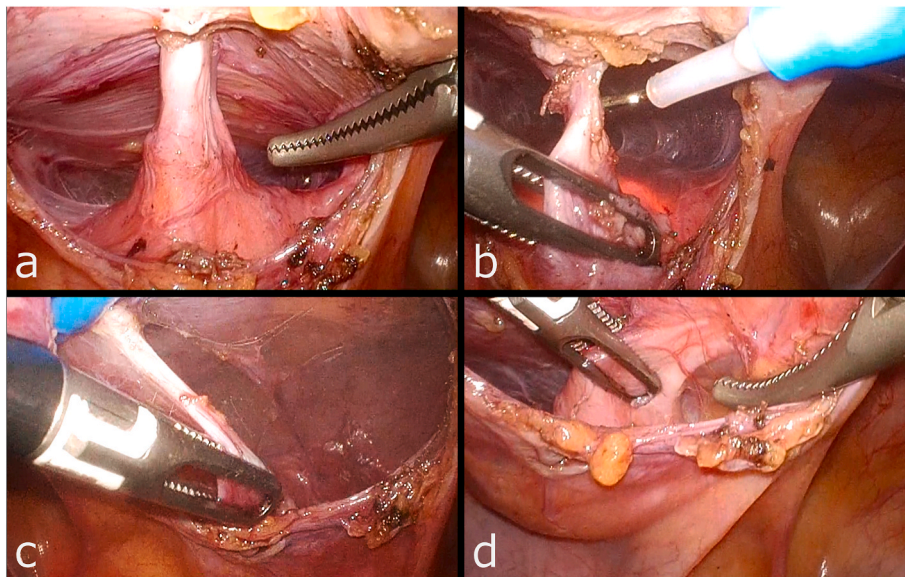
Received 2 August 2022; Accepted 3 September 2022

Available online 7 September 2022

2214-4420/© 2022 The Authors. Published by Elsevier Inc. This is an open access article under the CC BY-NC-ND license (<http://creativecommons.org/licenses/by-nc-nd/4.0/>).



**Fig. 1.** (a) Magnetic resonance image showing bladder wall adhesion to the anterior abdominal wall at the previous port site (arrowhead). (b) Cystoscopic image showing a recess in the dome of the bladder.



**Fig. 2.** Images showing that the bladder wall adheres to the anterior abdominal wall at the previous port sites during laparoscopy. (a) Adhesion at the central camera port site. (b) Adhesiotomy with an electric scalpel. (c) Adhesion at the left port site. (d) Adhesion at the right port site.

### 3. Discussion

Ureteral reimplantation is the gold standard for surgical treatment of VUR. Since the first report of vesicoscopic ureteral reimplantation by Yeung et al.<sup>1</sup> in 2005, use of the vesicoscopic approach has been gradually increasing. Vesicoscopic surgery offers many benefits compared with traditional surgery, including improved cosmesis, reduced postoperative pain and postoperative ileus, fewer wound complications, and shorter hospital stays.<sup>2</sup> However, specific problems can occur during vesicoscopic surgery, such as gas leaks around the bladder and dislodgement of ports. These problems sometimes make it difficult to continue the surgery. Furthermore, the main perioperative complications of vesicoscopic ureteral reimplantation include extraperitoneal urinary leakage, peritoneal injury, and emphysema.<sup>2,3</sup> These complications may also result from improper port placement and dislodgement of ports. Anchoring the bladder wall to the anterior abdominal wall for bladder port placement and port closure are important steps for successful surgery and reduced perioperative complications. Several surgical techniques have been developed to anchor the bladder wall to the

anterior abdominal wall.<sup>2</sup> We perform a technique in which the suture is introduced into the bladder through a spinal needle under cystoscopic guidance and pulled out through a looped suture introduced through another spinal needle,<sup>4</sup> as performed in many institutions. Once the reimplantation is complete, we carefully tie the bladder–anterior abdominal wall fixation sutures to close the hole in the bladder wall.

In the present case, the medical record of the vesicoureteral reimplantation performed 5 years previously was retrospectively reviewed. Intraoperative port placement was performed under cystoscopic guidance. The operation time was 334 minutes (of which 299 minutes was the pneumoperitoneum time). The patient developed no intraoperative complications such as peritoneal injury or gas leaks. On the second day after surgery, no urinary leak was found on cystography; therefore, the urinary catheter was removed. She was discharged 3 days postoperatively. However, she thereafter developed a serious problem with urination but did not report her symptoms to anyone. After she discussed her symptoms with us 5 years later, we performed MRI and suspected that the patient's urodynia was due to bladder wall adhesions based on the MRI results. Therefore, adhesiotomy was performed. As mentioned

above, complications of vesicoscopic surgery include urinary leakage, peritoneal injury, and emphysema. However, postoperative severe urodynia has not been described. This complication is not generally recognized, and a certain number of patients who have undergone vesicoscopic surgery may develop this complication and resultant urodynia. At our institution, we assess patients using a visual analogue scale for postoperative pain for approximately 1 week to collect objective data on perioperative outcomes. In the present case, however, this approach did not help in the early detection of urodynia. It is necessary for physicians to actively ask questions about urodynia for patients who have undergone vesicoscopic surgery because this symptom may not be reported to others.

#### 4. Conclusion

To the best of our knowledge, this is the first report of laparoscopic adhesiotomy for urodynia caused by bladder wall adhesion to the anterior abdominal wall after vesicoscopic ureteral reimplantation for VUR. Although extremely rare, physicians should consider bladder wall adhesion when severe urodynia is detected during follow-up visits after vesicoscopic ureteral reimplantation.

#### Ethics

This research conforms to the provisions of the Declaration of Helsinki.

#### Funding

This research did not receive any specific grant from funding

agencies in the public, commercial, or not-for-profit sectors.

#### Consent statement

We obtained consent from the patient for publication of this case report.

#### Declarations of competing interest

None.

#### Acknowledgment

We thank Angela Morben, DVM, ELS, from Edanz (<https://jp.edanz.com/ac>), for editing a draft of this manuscript.

#### References

1. Yeung CK, Sihoe JD, Borzi PA. Endoscopic cross-trigonal ureteral reimplantation under carbon dioxide bladder insufflation: a novel technique. *J Endourol.* 2005;19: 295–299.
2. Tae BS, Choi H, Park JY, Bae JH. Laparoscopic approach for intravesical surgery using pneumovesicum in urology: literature review. *Int Neurourol J.* 2018;22:S10–S22.
3. Canon SJ, Jayanthi VR, Patel AS. Vesicoscopic cross-trigonal ureteral reimplantation: a minimally invasive option for repair of vesicoureteral reflux. *J Urol.* 2007;178: 269–273.
4. Jayanthi VR. Vesicoscopic cross-trigonal ureteral reimplantation: high success rate for elimination of primary reflux. *J Pediatr Urol.* 2018;14:324. e1–324.e5.